

Thieme Clinical Companions

# Ultrasound

G. Schmidt

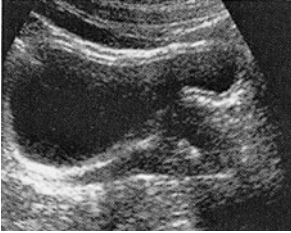

Thieme

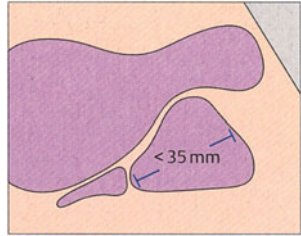
## Important Sonographic Dimensions\*

The values indicated are mean values drawn from the literature. It should be noted that organ dimensions may vary substantially from one individual to the next. Generally the values are not correlated with age, height, or constitution and therefore should be treated as **guidelines**. Vascular dimensions refer to **inside diameters**.

### ► Prostate and bladder in transverse section

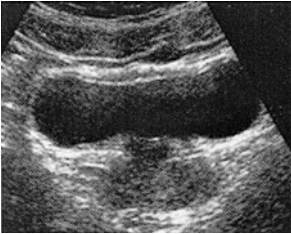


**Prostate:** Length < 35 mm, width < 45 mm

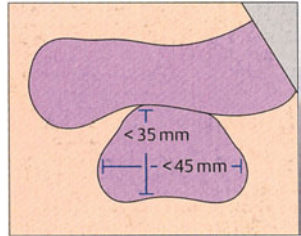


Depth < 35 mm, volume < 25 ml

### ► Prostate and bladder in longitudinal section

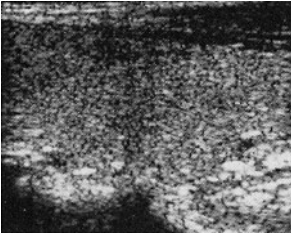


**Bladder:** Volume: length × width × height × 0.5

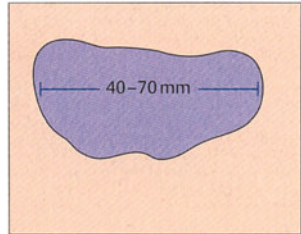


Male 350–750 ml; female 250–550 ml

### ► Thyroid gland in transverse section

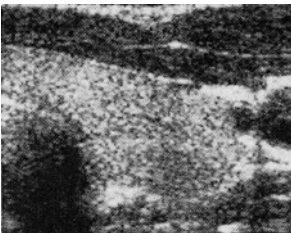

Length 40–70 mm, width 10–30 mm

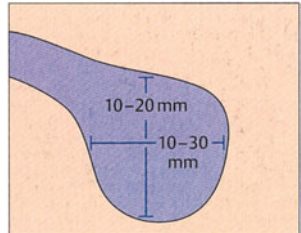


Depth 10–20 mm, isthmus < 5 mm

### ► Thyroid gland in longitudinal section

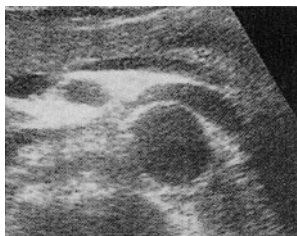

Volume: male < 25 ml, female < 20 ml

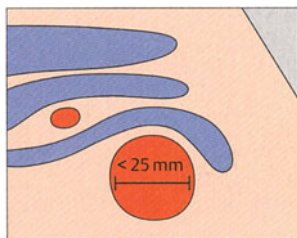


\* From Schmidt G, *Course Book in Ultrasound*, 4th ed. Stuttgart: Thieme; 2004.

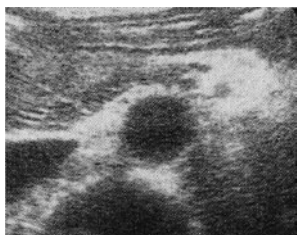
► **Aorta**



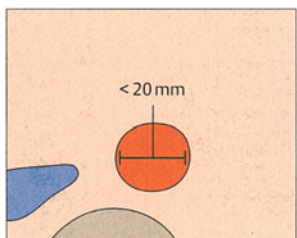
Subdiaphragmatic < 25 mm



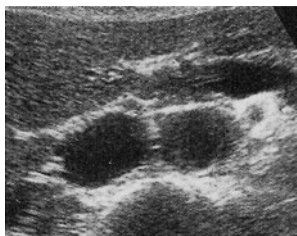
► **Aorta**



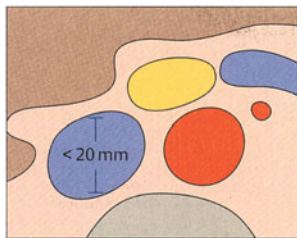
Above the bifurcation < 20 mm



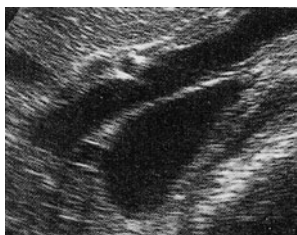► **Vena cava**



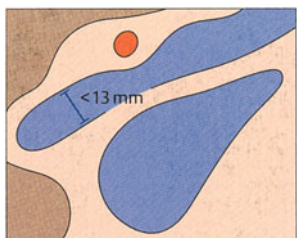
Subdiaphragmatic < 20 mm



► **Portal vein**



Hepatoduodenal ligament < 13 mm



Intrahepatic < 11 mm

# Contents

## *Gray Part: Basic Principles*

---

- 1 Basic Physical and Technical Principles ▶ 1
- 2 The Ultrasound Examination ▶ 16
- 3 Documentation and Reporting ▶ 46
- 4 Function Studies ▶ 49
- 5 Interventional Ultrasound ▶ 53

## *Green Part: Ultrasound Investigation of Specific Signs and Symptoms*

---

- 6 Principal Signs and Symptoms ▶ 62

## *Blue Part: Ultrasonography of Specific Organs and Organ Systems, Postoperative Ultrasound, and the Search for Occult Tumors*

---

- 7 Arteries and Veins ▶ 188
- 8 Cervical Vessels ▶ 214
- 9 Liver ▶ 231
- 10 Kidney and Adrenal Gland ▶ 262
- 11 Pancreas ▶ 293
- 12 Spleen ▶ 312
- 13 Bile Ducts ▶ 322
- 14 Gallbladder ▶ 334
- 15 Gastrointestinal Tract ▶ 352
- 16 Urogenital Tract ▶ 375
- 17 Thorax ▶ 400
- 18 Thyroid Gland ▶ 412
- 19 Major Salivary Glands ▶ 425
- 20 Postoperative Ultrasound ▶ 431
- 21 Search for Occult Tumors ▶ 437





Thieme Clinical Companions

# Ultrasound

---

Günter Schmidt, MD

Formerly Evangelisches Krankenhaus Kredenbach  
Kreuztal, Germany

With contributions by

B. Beuscher-Willems, L. Brüggemann, C. Görg, T. Grebe, L. Greiner

1091 illustrations

Georg Thieme Verlag  
Stuttgart · New York

Schmidt, Ultrasound © 2007 Thieme

All rights reserved. Usage subject to terms and conditions of license.

*Library of Congress Cataloging-in-Publication Data* is available from the publisher.

This book is an authorized and revised translation of the 3rd German edition published and copyrighted 2005 by Georg Thieme Verlag, Stuttgart, Germany. Title of the German edition: Checklist: Sonographie

1st German edition 1997

2nd German edition 1999

Translator: Terry Telger, Translations for the Health Sciences, Fort Worth, TX, USA

**Important note:** Medicine is an ever-changing science undergoing continual development. Research and clinical experience are continually expanding our knowledge, in particular our knowledge of proper treatment and drug therapy. Insofar as this book mentions any dosage or application, readers may rest assured that the authors, editors, and publishers have made every effort to ensure that such references are in accordance with **the state of knowledge at the time of production of the book.**

Nevertheless, this does not involve, imply, or express any guarantee or responsibility on the part of the publishers in respect to any dosage instructions and forms of applications stated in the book. **Every user is requested to examine carefully** the manufacturers' leaflets accompanying each drug and to check, if necessary in consultation with a physician or specialist, whether the dosage schedules mentioned therein or the contraindications stated by the manufacturers differ from the statements made in the present book. Such examination is particularly important with drugs that are either rarely used or have been newly released on the market. Every dosage schedule or every form of application used is entirely at the user's own risk and responsibility. The authors and publishers request every user to report to the publishers any discrepancies or inaccuracies noticed. If errors in this work are found after publication, errata will be posted at [www.thieme.com](http://www.thieme.com) on the product description page.

Some of the product names, patents, and registered designs referred to in this book are in fact registered trademarks or proprietary names even though specific reference to this fact is not always made in the text. Therefore, the appearance of a name without designation as proprietary is not to be construed as a representation by the publisher that it is in the public domain.

This book, including all parts thereof, is legally protected by copyright. Any use, exploitation, or commercialization outside the narrow limits set by copyright legislation, without the publisher's consent, is illegal and liable to prosecution. This applies in particular to photostat reproduction, copying, mimeographing, preparation of microfilms, and electronic data processing and storage.

© 2007 Georg Thieme Verlag,  
Rüdigerstrasse 14, 70469 Stuttgart, Germany

<http://www.thieme.de>

Thieme New York, 333 Seventh Avenue,  
New York, NY 10001, USA

<http://www.thieme.com>

Cover design: Thieme Marketing  
Typesetting by Hagedorn Kommunikation, Viernheim  
Printed in Germany by Druckhaus Götz, Ludwigsburg

10-ISBN 3-13-142711-6 (GTV)

13-ISBN 978-3-13-142711-3 (GTV)

10-ISBN 1-58890-552-7 (TNY)

13-ISBN 978-1-58890-552-9 (TNY)

1 2 3 4 5 6

# Preface

Rapid advances in ultrasound imaging have resulted not only from continual improvements in equipment and new technologies, but also from expanded diagnostic capabilities. Color Doppler sonography and ultrasound contrast agents, combined with advances in standardizing diagnostic criteria and defining guidelines, have led to dramatic progress in sonographic diagnosis.

For example, it is now possible to use contrast-enhancing agents in nearly all areas of ultrasonography, although the examiner's experience and equipment availability continue to limit these applications. For those who are still learning how to use ultrasound, however, it is first necessary to acquire a sound basic knowledge of this modality in order to take advantage of these new and expanded methods.

This book presents a comprehensive collection of B-mode scans, but also a quantity of color Doppler images, as well as several examples of the uses of contrast-enhanced sonography. For ease of use in different situations, it is divided into three parts (gray: Basic Principles, green: Ultrasound Investigation of Principal Signs and Symptoms, blue: Ultrasound of Specific Organs and Organ Systems).

The editor and two other authors (Prof. Dr. Ch. Görg, Prof. Dr. L. Greiner) are regular leaders of seminars run by the German Society for Ultrasound in Medicine (DEGUM) and co-authors of three German editions of a similar text, and of other books on sonography. Each of them has an area of interest and expertise in their daily experience and on courses on ultrasound from which the current imaging approaches have been developed.

I extend special thanks to the staff at Thieme Medical Publishers, particularly Ms. Stefanie Langner, Dr. Christiane Brill-Schmid, Ms. Anja Dessauvague, Ms. Elisabeth Kurz, and Mr. Stephan Konnry. They worked with the authors tirelessly and patiently (and at times, with gentle insistence) to bring this book to completion. A number of other men and women at Thieme Medical Publishers helped with the artwork, image reproductions, and production of the book, and their help is gratefully acknowledged. To all those who read this book, delve deeply into its contents, and use it as a practical reference, I wish much success in their dealings with ultrasonography.

Günter Schmidt

## Contributors

B. Beuscher-Wilhelms, MD  
Medizinische Klinik  
Krankenhaus Bethesda  
Freudenberg  
Germany

L. Brüggemann, MD  
Evangelisches Krankenhaus  
Bernhard-Weiss-Klinik  
Kreuztal-Kredenbach  
Germany

C. Görg, MD  
Professor  
Medizinische Klinik  
Klinikum der Universität  
Department of Hematology/Oncology  
Marburg  
Germany

T. Grebe, MD  
Evangelisches Krankenhaus  
Bernhard-Weiss-Klinik  
Kreuztal-Kredenbach  
Germany

L. Greiner, MD  
Professor  
Klinikum Barmen  
Medizinische Klinik A  
Wuppertal  
Germany

# Contents

## **Gray Part: Basic Principles**

- 1 Basic Physical and Technical Principles ▶ 1**
  - 1.1 Physics of Ultrasound ▶ 1
  - 1.2 Ultrasound Techniques ▶ 3
  - 1.3 Color Duplex Sonography (CDS) ▶ 7
  - 1.4 Imaging Artifacts ▶ 8
  
- 2 The Ultrasound Examination ▶ 16**
  - 2.1 Abdominal Sonography ▶ 16
  - 2.2 Ultrasound Imaging of Joints (Arthrosonography) ▶ 31
  
- 3 Documentation and Reporting ▶ 46**
  - 3.1 Requirements for Documentation ▶ 46
  - 3.2 Guideline-Oriented Documentation ▶ 46
  - 3.3 Sonographic Nomenclature ▶ 47
  
- 4 Function Studies ▶ 49**
  - 4.1 Basic Principles ▶ 49
  - 4.2 Sonographic Measurements ▶ 49
  
- 5 Interventional Ultrasound ▶ 53**
  - 5.1 Fine-Needle Aspiration Biopsy (FNAB) ▶ 53
  - 5.2 Therapeutic Aspiration and Drainage ▶ 58

## **Green Part: Ultrasound Investigation of Specific Signs and Symptoms**

- 6 Principal Signs and Symptoms ▶ 62**
  - 6.1 Upper Abdominal Pain ▶ 62
  - 6.2 Lower Abdominal Pain ▶ 75
  - 6.3 Diffuse Abdominal Pain ▶ 81
  - 6.4 Diarrhea and Constipation ▶ 87
  - 6.5 Unexplained Fever ▶ 92
  - 6.6 Palpable Masses ▶ 99
  - 6.7 Enlarged Lymph Nodes ▶ 107
  - 6.8 Edema ▶ 116
  - 6.9 Renal Insufficiency and Acute Renal Failure ▶ 124
  - 6.10 Jaundice ▶ 139
  - 6.11 Hepatosplenomegaly ▶ 148
  - 6.12 Ascites ▶ 155
  - 6.13 Joint Pain and Swelling ▶ 163
  - 6.14 Goiter, Hyper- and Hypothyroidism ▶ 179

**Blue Part: Ultrasonography of Specific Organs and Organ Systems, Postoperative Ultrasound, and the Search for Occult Tumors**

- 7 Arteries and Veins ▶ 188**
  - 7.1 Examination ▶ 188
  - 7.2 Aorta and Arteries ▶ 194
  - 7.3 Vena Cava and Peripheral Veins ▶ 208
  
- 8 Cervical Vessels ▶ 214**
  - 8.1 Examination ▶ 214
  - 8.2 Abnormal Findings ▶ 221
  
- 9 Liver ▶ 231**
  - 9.1 Examination ▶ 231
  - 9.2 Diffuse Changes ▶ 234
  - 9.3 Circumscribed Changes ▶ 241
  - 9.4 Changes in the Portal Venous System ▶ 257
  
- 10 Kidney and Adrenal Gland ▶ 262**
  - 10.1 Examination ▶ 262
  - 10.2 Diffuse Renal Changes ▶ 267
  - 10.3 Circumscribed Changes in the Renal Parenchyma ▶ 272
  - 10.4 Circumscribed Changes in the Renal Pelvis and Renal Sinus ▶ 283
  - 10.5 Evaluation and Further Testing ▶ 289
  - 10.6 Perirenal Masses and Adrenal Tumors ▶ 292
  
- 11 Pancreas ▶ 293**
  - 11.1 Examination ▶ 293
  - 11.2 Diffuse Changes ▶ 295
  - 11.3 Circumscribed Changes ▶ 301
  
- 12 Spleen ▶ 312**
  - 12.1 Examination ▶ 312
  - 12.2 Sonographic Findings ▶ 313
  
- 13 Bile Ducts ▶ 322**
  - 13.1 Examination ▶ 322
  - 13.2 Intrahepatic Ductal Changes ▶ 325
  - 13.3 Extrahepatic Ductal Changes ▶ 330
  - 13.4 Evaluation and Further Testing ▶ 333
  
- 14 Gallbladder ▶ 334**
  - 14.1 Examination ▶ 334
  - 14.2 Changes in Size, Shape, and Location ▶ 335
  - 14.3 Wall Changes ▶ 339
  - 14.4 Intraluminal Changes ▶ 346
  - 14.5 Evaluation and Further Testing ▶ 350

- 15 Gastrointestinal Tract ▶ 352**
  - 15.1 Examination ▶ 352
  - 15.2 Stomach ▶ 355
  - 15.3 Small Intestine ▶ 360
  - 15.4 Large Intestine ▶ 366
  
- 16 Urogenital Tract ▶ 375**
  - 16.1 Examination ▶ 375
  - 16.2 Renal Pelvis, Ureter, and Bladder ▶ 380
  - 16.3 Male Genital Tract ▶ 389
  - 16.4 Female Genital Tract ▶ 395
  
- 17 Thorax ▶ 400**
  - 17.1 Examination ▶ 400
  - 17.2 Chest Wall ▶ 402
  - 17.3 Pleura ▶ 403
  - 17.4 Lung Parenchyma ▶ 408
  
- 18 Thyroid Gland ▶ 412**
  - 18.1 Examination ▶ 412
  - 18.2 Diffuse Changes ▶ 414
  - 18.3 Circumscribed Changes ▶ 417
  
- 19 Major Salivary Glands ▶ 425**
  - 19.1 Examination ▶ 425
  - 19.2 Abnormal Findings ▶ 427
  
- 20 Postoperative Ultrasound ▶ 431**
  - 20.1 Normal Postoperative Changes ▶ 431
  - 20.2 Postoperative Complications ▶ 434
  
- 21 Search for Occult Tumors ▶ 437**
  - 21.1 Principal Signs and Symptoms ▶ 437
  - 21.2 Sonographic Criteria for Malignancy ▶ 442
  - 21.3 Evaluation and Further Testing ▶ 449
  
- Subject Index ▶ 454**

## Sources of Illustrations

- ▶ **From Schmidt, G., *Ultraschall-Kursbuch*, 3rd ed.** Stuttgart: Thieme Medical Publishers, 1999: Fig. 2.207 = Fig. 288; Fig. 2.86a, b = Fig. 336a, b.
- ▶ **From Schmidt, G., *Ultraschall-Kursbuch*, 4th ed.** Stuttgart: Thieme Medical Publishers, 2004: Fig. 1.9 = Fig. 4; Fig. 1.3 = Fig. 6; Fig. 1.2 = Fig. 10; Fig. 1.7 = Fig. 12; Fig. 1.8 = Fig. 14; Fig. 1.4 = Fig. 16; Fig. 2.100 = Fig. 334d; Fig. 2.85 = Fig. 336; Fig. 2.107a, b = Fig. 338a, b; Fig. 2.189 = Fig. 387; Fig. 3.52a = Fig. 435b; Fig. 3.136 = Fig. 444a; Fig. 3.141 = Fig. 444b; Fig. 1.84 = 490a; Fig. 1.80 = Fig. 490b; Fig. 3.213a = Fig. 494d; Fig. 3.213b = Fig. 494e; Fig. 2.55 = Fig. 495; Fig. 2.78a = Fig. 496a; Fig. 3.33b = Fig. 516b; Fig. 3.63a, b = Fig. 533a, b; Fig. 3.225 = Fig. 538a; Fig. 3.88 = Fig. 547; Fig. 2.266a, b = Fig. 577a, b; Fig. 2.270 a = Fig. 579a; Fig. 2.270b = Fig. 279b; Fig. 2.271 = Fig. 579c; Fig. 2.272 = Fig. 580a; Fig. 2.279a = Fig. 588a; Fig. 3.16 = Fig. 621b; Fig. 3.7 = Fig. 631; Fig. 2.142 = Fig. 665a; Fig. 2.143 = Fig. 668; Fig. 3.205a, b = Fig. 671a, b; Fig. 2.175 b = Fig. 274b; Fig. 3.222a = Fig. 244
- ▶ **From Schmidt, G., *Sonographische Differentialdiagnose*, 1st ed.**, Stuttgart: Thieme Medical Publishers, 2002: Fig. 9.69a = Fig. 100a; Fig. 9.69b = Fig. 100b; Fig. 7.36 b = Fig. 105; Fig. 9.27 = Fig. 161; Fig. 1.26 = Fig. 254; Fig. 1.12a, b = Fig. 255a, b; Fig. 1.10 = Fig. 256; Fig. 1.11b = Fig. 257; Fig. 1.9 = Fig. 262; Fig. 1.27a = Fig. 263b; Fig. 1.27 b = Fig. 263c; Fig. 1.28 = Fig. 263d; Fig. 1.1a, b = Fig. 265a, b; Fig. 1.18 = Fig. 266a; Fig. 1.19b = Fig. 266b; Fig. 1.40 = Fig. 272a; Fig. 1.29b = Fig. 272b; Fig. 1.35 = Fig. 273a; Fig. 1.1f = Fig. 277; Fig. 1.49a, b = Fig. 278a, b; Fig. 1.50 = Fig. 279a; Fig. 1.51 = Fig. 279b; Fig. 1.55a = Fig. 281a; Fig. 9.7 = Fig. 374a; Fig. 9.15 = Fig. 374b; Fig. 9.24 = Fig. 382a; Fig. 9.93 = Fig. 390b; Fig. 9.93 = Fig. 390b; Fig. 9.3g = Fig. 391b; Fig. 9.74a, b = Fig. 396a, b; Fig. 9.69a-c = Fig. 420a, b; Fig. 4.19b = Fig. 431; Fig. 4.19a = Fig. 432a; Fig. 4.9 = Fig. 434b; Fig. 4.43 = Fig. 440a; Fig. 4.37 = Fig. 449a; Fig. 7.1h = Fig. 528b; Fig. 12.25 = Fig. 557; Fig. 11.1 (first illustration from the top) = Fig. 565; Fig. 11.1 (second illustration from the top) = Fig. 566; Fig. 11.1 (second illustration from the bottom) = Fig. 567; Fig. 11.1 (first illustration from the bottom) = Fig. 568; Fig. 11.95a = Fig. 570b; Fig. 11.71 = Fig. 571b; Fig. 11.75a = Fig. 571c; Fig. 11.74a = Fig. 571d; Fig. 11.98 = Fig. 572; Fig. 11.84a = Fig. 573c; Fig. 11.82a, b = Fig. 574a, b; Fig. 11.67 = Fig. 575b; Fig. 11.79 = Fig. 576a; Fig. 11.77 = Fig. 576b; Fig. 12.20 = Fig. 582; Fig. 12.29 = Fig. 583; Fig. 12.30 = Fig. 584a; Fig. 12.32b = Fig. 585a; Fig. 12.32c = Fig. 585b; Fig. 12.28 = Fig. 586a; Fig. 12.36a = Fig. 586b; Fig. 12.33b = Fig. 587a; Fig. 13.34 = Fig. 589a; Fig. 13.33b = Fig. 590a; Fig. 13.7 = Fig. 590b; Fig. 13.42 = Fig. 591a; Fig. 13.43 = Fig. 591b; Fig. 13.46 = Fig. 592; Fig. 13.47 = Fig. 593a; Fig. 13.48 = Fig. 593b; Fig. 13.53 = Fig. 595; Fig. 14.13 = Fig. 618; Fig. 14.10 = Fig. 619c; Fig. 14.2k = Fig. 624; Fig. 14.64 = Fig. 628b; Fig. 14.41a = Fig. 629a; Fig. 14.41b = Fig. 629b; Fig. 14.42a = Fig. 629c; Fig. 14.46 = Fig. 629d; Fig. 14.51 = Fig. 630; Fig. 11.2e = Fig. 652a; Fig. 11.2f = Fig. 652b; Fig. 8.43 = Fig. 675; Fig. 8.6a = Fig. 676a; Fig. 8.6d = Fig. 676b

# 1 Basic Physical and Technical Principles

## 1.1 Physics of Ultrasound

### Properties of Sound Waves

- ▶ **Propagation characteristics:** Sound waves have several essential properties:
  - *Propagation of ultrasound waves:* Sound waves travel through air, fluids, and human tissue almost exclusively as longitudinal waves. These are zones in which the molecules that make up the medium are alternately rarefied and condensed. Thus, sound waves must propagate through matter and cannot exist in a vacuum.
  - *Propagation speed:* The speed of sound is relatively slow in all materials (in tissue about 1540 m/s). Consequently, its transit time can be accurately determined by electronic measurements and correlated with the distance traveled by applying the time–distance principle.
  - *Reflection (partial or complete) of sound waves at interfaces:* The degree of reflection of incident sound waves at an interface depends on the acoustic resistance (“impedance”) of the medium:
    - Impedance = the ratio of the incident sound intensity to the portion that is transmitted.
    - Acoustic resistance = the product of the density times the speed of sound.
- ▶ **Doppler effect:** The Doppler effect states that the frequency of the returning (received) sound waves changes when the source of the sound is moving toward or away from the receiver. According to the time–distance law, the product of time and velocity equals the distance traveled. Thus, the frequency changes in the sound waves reflected from moving red blood cells can be analyzed to determine the direction and velocity of blood flowing through vessels and in the heart.

### Resolution

- ▶ **Ultrasound frequency:** The quality of an ultrasound examination depends on two criteria relating to the properties of the sound waves:
  - The highest possible resolution (high transducer frequency).
  - An adequate depth of sound penetration (low transducer frequency).
  - *Rule:* Shorter wavelengths improve resolution but decrease the penetration depth of the ultrasound beam.
  - *Tradeoff:* The optimum frequency range for diagnostic ultrasound is 1–10 MHz. The optimum range of wavelengths is 0.15–1.5 mm (Table 1).

**Table 1 · Reference values for resolution and penetration depth as a function of frequency**

Frequency (MHz)	Resolution (mm)		Penetration depth (mm)
	Axial	Lateral	
3.5	1	2	160
5	0.6	1.2	100
7.5	0.4	0.8	50

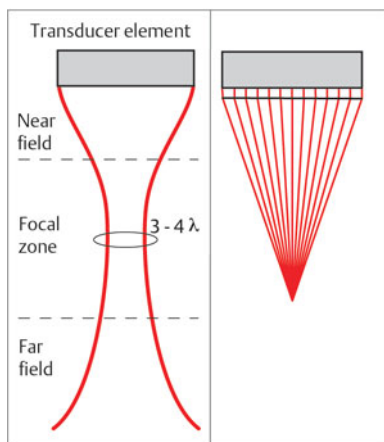


Fig. 1 Ultrasound beam shape and electronic focusing (after Röthlin, Bouillon, and Klotter)

- ▶ **Velocity of sound propagation:** This depends on the density of the medium (approximately 1500–1600 m/s in soft tissues and fluids, 331 m/s in air, and 3500 m/s in bone). Ultrasound instruments are calibrated to a mean sound velocity of 1540 m/s.
- ▶ **Axial resolution:** A sound pulse composed preferably of two (or three) wavelengths is emitted in the longitudinal (axial) direction. The maximum ability to resolve two separate points in the longitudinal direction is equal to one-half the pulse length, or approximately one wavelength. For example, the resolution at an operating frequency of 3.5 MHz is approximately equal to 0.5(–1) mm.
- ▶ **Lateral resolution:** The ultrasound beam initially converges with increasing depth, and then widens out again with decreasing intensity and resolution. The focal zone (“waist”) of the beam is 3–4 wavelengths wide and is the area where lateral resolution is highest (Fig. 1). The lateral resolution at a frequency of 3.5 MHz is approximately 2 mm, meaning that two adjacent points can be distinguished as separate points when they are at least 2 mm apart.
- ▶ **Focusing:** The purpose of beam focusing in sonography is to achieve maximum resolution and improve the ability to recognize fine details.
  - **Technical options:**
    - Make the transducer face concave to produce a convergent beam (concave mirror effect).
    - Use a collecting lens.
  - **Mechanical focusing:** This creates a fixed focal zone that cannot be moved (fixed-focus system), although it can be modified somewhat by scanning through a fluid offset.
  - **Electronic focusing:** With this option, the focal zone can be set to any desired depth (Fig. 1). For example, the focal zone can be positioned to give a sharp image of the gallbladder, or it can be extended over the full depth of the image field.
  - **Adjusting the focus during an ultrasound examination:** This is the hallmark of a proficient examiner. One feature of a high-quality ultrasound system is that a definite change in resolution is seen as the focal zone is moved.

## Propagation Characteristics of Sound Waves

---

The propagation of ultrasound waves obeys the laws of wave physics. The following terms have been adopted from radiation optics and wave optics.

- ▶ **Reflection:** Sound waves are partially reflected and partially transmitted in biological tissues. An image of an organ is generated from the returning echo signals by analyzing the impedance differences at acoustic interfaces. The higher the acoustic impedance, the greater the degree of reflection, with total reflection occurring at interfaces with a very high **impedance mismatch** (e.g., between soft tissue and bone, calcium, or air, producing a high-amplitude echo). Interfaces with a high acoustic impedance (e.g., gallstones) reflect all of the incident sound and cast an **acoustic shadow**.
- ▶ **Scattering:** This consists of randomly directed reflections that occur at tissue interfaces and rough surfaces. The echoes generated by scattering centers contribute significantly to medical imaging (e.g., the imaging of rounded organ contours).
- ▶ **Refraction:** This phenomenon is most pronounced at smooth interfaces with a high acoustic impedance. The sound waves are deflected at an oblique angle relative to the direction of the main beam.
- ▶ **Absorption and attenuation:** These describe the “loss” of sound waves due to their spatial distribution in the tissue and the conversion of sound energy to heat. According to the findings of a WHO commission, the conversion of sound energy to heat is within safe limits at the low energy levels used in diagnostic ultrasound. Even so, it is prudent to use the lowest possible ultrasound energy when scanning children and pregnant women. Sound waves are also attenuated in tissues as a result of reflection, scattering, and refraction. This leads to a significant energy loss, which is offset by adjusting the **time gain compensation (TGC)** on the scanner.

## 1.2 Ultrasound Techniques

### A-Mode, B-Mode, and M-Mode Scanning

---

- ▶ **A-mode scanning (Fig. 2a):** In this technique the **amplitudes (A-mode)** of the echo signals returned from tissue interfaces are displayed as a series of amplitude deflections along a horizontal axis, as on an oscilloscope.
- ▶ **B-mode scanning (brightness mode, Fig. 2b):**
  - **Principle:** Reflected ultrasound pulses are displayed on the monitor as spots of varying brightness in proportion to their intensity. The sound waves are transmitted into the tissue in a parallel scan or a fan-shaped beam, and the echoes are reflected back to the transducer and assembled line-by-line according to their arrival time.
  - **Signal display and image reconstruction:** Approximately 120 image lines are assembled to make a two-dimensional sectional image. The various echo intensities are converted by electronic processing into image spots of varying density or shades of gray (**gray-scale display, brightness modulation**).
- ▶ **M-mode scanning (time-motion):** This technique generates a time-motion trace that records the motion of acoustic reflectors such as heart valves and myocardial walls over time.

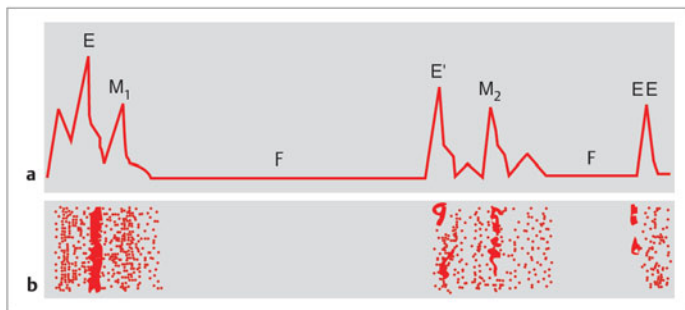


Fig. 2a, b A-mode and B-mode scans, illustrated for the maxillary sinus. **a** A-mode signal. **b** B-mode display: echo amplitudes are converted to spots of varying brightness. E = entry echoes (bone), E' = entry echo (bony ridge or polyp), M<sub>1</sub> = mucosa, M<sub>2</sub> = thickened mucosa, F = fluid, EE = exit echo

## Doppler and Duplex Sonography

### ▶ Continuous-wave (CW) Doppler:

- *Principle:* Two piezoelectric crystals are used, one for the continuous transmission of ultrasound pulses (continuous wave) and one for the reception of reflected ultrasound signals.
- *Signal display:* The frequency spectra of returning echoes are displayed acoustically and also visually if desired. The frequency shifts can be used to calculate the direction and velocity of blood flow. This technique does not, however, provide information on the depth or range of the echo source.

### ▶ Pulsed Doppler:

- *Principle:* This technique employs one piezoelectric crystal that functions alternately as a transmitter and receiver (pulsed wave).
- *Signal display:* Echo signals are recorded from a designated sample volume during the receiving phase of the scan. This makes it possible to determine the depth and width of the sample volume and investigate blood flow within a circumscribed area.

### ▶ Duplex sonography:

- *Principle:* CW or pulsed Doppler is combined with B-mode imaging, providing visual feedback for positioning the Doppler beam and the sample volume.

### ▶ Power Doppler:

This technique demonstrates the spatial distribution of blood flow but cannot determine flow direction. It is most useful in establishing the presence or absence of vascularity and evaluating the quantity of blood flow. Power Doppler is excellent for detecting increased vascularity due to inflammation, for example.

### ▶ Spectral Doppler:

The spectral analysis of blood flow patterns is used to determine the time course and velocity distribution of the flow, i.e., its mean and maximum velocities. This is of key importance in the diagnosis of vascular stenosis.

## Ultrasound Transducers

### ▶ Linear scanner:

This type of transducer consists of a linear array of up to 512 piezoelectric elements that are electronically activated in groups. Parallel beam scanning creates a geometrically true image, but the large footprint may be a

problem (e.g., in the presence of bowel gas). A linear array is best for imaging superficial structures.

- ▶ **Convex scanner:** The piezoelectric elements are the same as those used in a linear array, but they are arranged along a curved surface, resulting in a fan-shaped beam.
- ▶ **Sector scanner:** This may be mechanical or electronic. In a mechanical sector scanner, the elements are mechanically rotated to produce a radial-format scan. With an electronic sector scanner, the crystals are pulsed in phases (phased array) to produce a sectoral, pie-shaped scan. The advantage of a sector scanner is its small footprint, which makes it easier to scan around obstructions such as ribs and bowel gas. It is particularly useful for imaging deeper structures.

## Signal Processing

- ▶ **Preprocessing:** Electronic enhancement of signal quality and resolution at the time the echoes are received.
- ▶ **Postprocessing:** Improving the contrast between weak signals (soft tissues) and strong signals (calcified or bony structures) by amplifying or suppressing certain gray-scale ranges.
- ▶ **Time gain compensation (TGC):** Signals arriving later (from greater depths) are amplified more than earlier signals to compensate for the attenuating effect of tissues (e.g., the attenuation of deeper echoes in a fatty liver).
- ▶ **Transmitted power:** The maximum power output set on the machine, designated as 0. To avoid swamping or washing out the gray-scale image, the power should be set as low as possible, e.g., 3–9% below the maximum setting (this also avoids potential adverse effects in children and pregnant women).
- ▶ **Overall gain:** Amplifies the returning signals. The gain setting should be matched to the transmitted power (the power emitted by the transducer).

## Digital Image Processing

Increasingly, conventional imaging is being augmented by digital signal processing with powerful computers that can carry out several billion operations per second. This trend has been supported by advances in transducer technology from single-line arrays to multiline (matrix) arrays and broadband arrays in which the transmitted and received frequencies can be selected and used over a broad spectrum. Combined with digital signal processing and a high sampling rate of the echo signals, these developments make it possible to obtain ultrasound images with high contrast and high resolution, and even study the dynamics of slow blood flow in small vessels.

- ▶ **Contrast harmonic imaging (CHI) and tissue harmonic imaging (THI):** Nonhomogeneous tissues give rise to echo signals that contain harmonic echo frequencies in addition to the fundamental frequency of the transmitted pulse.
  - THI combines special transmitted pulse sequences with a broadband reception technique, using the harmonic frequency components to create ultrasound images that have high contrast, high spatial resolution, and low noise.
  - CHI employs echo-enhancing contrast agents that increase the harmonic frequency component to improve the discrimination between blood-flow echoes and tissue echoes.
- ▶ **Photopic ultrasound imaging:** This technique can be used to optimize image contrast. By the conversion of gray levels to monochromatic color values, very subtle structural differences can be appreciated.
- ▶ **3D sonography:** Large sets of image data can be stored in great numbers by means of high-speed digital signal processing. A position sensor is not required. Local

echo information from contiguous image slices is used to reconstruct 3D data sets with an isotropic voxel size. Data acquisition can be done freehand with standard transducers, or matrix transducers can be used that allow electronic beam steering. The B-mode images and Doppler scans are acquired separately and may be displayed separately or in a combined format.

### Contrast-Enhanced Sonography

- ▶ **Technique and development:** Lesions as small as 4 mm in diameter can be detected with the ultrasound technology currently available. However, because of patient-related factors (obesity, overlying bowel gas, inability to take deep breaths) and the acoustic properties of some tumors, which are isoechoic to surrounding tissue, certain masses can be difficult to detect. In these cases ultrasound contrast agents (echogenic microparticles injected intravenously) can be used to locate and even characterize masses based on the Doppler effect.
- ▶ **Applications:**
  - *Gastroenterology, hepatic ultrasound:* The use of echo-enhancing agents has been investigated in many studies in recent years and may be considered the standard for “high-end ultrasound,” especially in the discrimination of focal hepatic lesions.
  - *Neurological ultrasound:* In the field of neurology as well, contrast-enhanced sonography is widely practiced in specialized ultrasound laboratories, where the use of echo-enhancing agents can significantly improve the diagnostic yield because of the difficulty of scanning through the skull.
  - There are other areas, such as the investigation of myocardial perfusion, where contrast-enhanced sonography has not yet come into broad clinical use.

### Equipment Settings

- **Note:** An accurate sonographic diagnosis relies on the experience and diligence of the examiner but also requires optimum equipment settings. The settings on the ultrasound scanner should be continually adjusted from patient to patient and from organ to organ.
- ▶ **Monitor settings:**
  - *Brightness:* First, adjust the brightness control so that structures are clearly outlined in relation to the background brightness.
  - *Contrast:* Next, adjust the contrast control until the full range of gray levels can be identified on the gray-scale bar.
- ▶ **Basic settings on the ultrasound scanner:**
  - *Power setting:* Set to the lowest possible level.
  - *Overall gain:* Lower the gain if the image appears washed out.
  - *Time gain compensation:* Adjust the TGC to obtain a homogeneous sonodensity and uniform image brightness.
- ▶ **Common errors of adjustment:**
  - Gain set too high or too low
  - Faulty adjustment of the TGC
  - Washed-out appearance of the near field, far field, or both
- **Note:** The goal of optimum monitor and scanner settings is to avoid errors of image interpretation.

## 1.3 Color Duplex Sonography (CDS)

### Method, Diagnostic Information

- ▶ **Synonyms:** CDS, color flow imaging (CFI), color flow mapping (CFM), color velocity imaging (CVI).
- ▶ **Principle:** CDS combines conventional gray-scale imaging with Doppler flow sampling. Doppler sample volumes are positioned within a B-mode image sector or over the entire B-mode image, and Doppler frequency shifts are registered and electronically color-coded. By general convention, flow toward the transducer is encoded in red and flow away from the transducer is encoded in blue.
- ▶ **Goals and capabilities:**
  - *Mapping:* Moving particles in organs are scanned over a broad imaging area.
  - *Motion detection* (e.g., of blood cells) based on frequency changes stemming from the Doppler effect.
  - *Visualization of blood vessels:* The sampling cursor (the sample volume in pulsed Doppler) is positioned in the vessel of interest, and color pixels are electronically displayed within the vessel lumen.
  - *Measurement of maximum flow velocities* (with CW Doppler): Stenoses and/or flow direction can be detected on the basis of spectral waveform analysis, color changes, and mixed (turbulent) color patterns.

### Signal Processing, Equipment Settings

- ▶ **Equipment settings:**
  - The penetration depth and detectable flow velocity depend on the type of transducer used and its operating frequency.
  - The power setting (expressed as a percentage of the maximum power output or in decibels) should be kept as low as possible, both for safety reasons and to prevent color-encoding artifacts such as artificial turbulence and extraluminal color bleed.
  - The overall gain (receiver gain) and TGC should be set at the upper end of the range.
- ▶ **Wall filter:**
  - The wall filter limits signal acquisition to designated frequency ranges (e.g., to detect low flow velocities).
  - It also filters out unwanted frequencies.
- ▶ **Doppler frequency:**
  - The maximum measurable Doppler frequency is adjusted with a dial or toggle switch. The maximum frequency or velocity is displayed above and below the color scale at the edge of the screen.
  - The velocity setting is based on the anticipated frequency spectrum. Parenchymal vessels, for example, would be expected to have lower frequencies and velocities than resistance-type vessels.
  - The maximum detectable frequency depends on the pulse repetition frequency (PRF), which depends in turn on the transducer frequency and penetration depth.
  - The PRF setting should be twice as high as the maximum detectable velocity. If the PRF is set too low, it may cause an apparent flow reversal called **aliasing**.
- ▶ **Shifting the baseline:** The measured frequencies or velocities are displayed on a scale with a central baseline and plus/minus ranges. If the range of detectable frequencies is insufficient at high velocities, the baseline can be shifted up or down to expand the range of interest.

- ▶ **Beam angle:**
  - As in pulsed and CW Doppler, the detectable frequency shift depends on the incidence angle of the ultrasound beam. For a given velocity, the frequency change (Doppler shift) will increase as the beam angle is decreased.
  - The measurement error decreases as the beam angle approaches  $0^\circ$ .
  - A Doppler frequency shift can be accurately converted to velocity only if the incidence angle of the beam is known. For the scanner to make this conversion automatically, the beam angle must be indicated by marking the flow direction in the blood vessel with an angle cursor.

### Color Artifacts

---

- ▣ **Note:** Many color artifacts can adversely affect or distort the interpretation of CDS findings. Some are unavoidable and can actually be used to enhance the accuracy and sensitivity of the diagnosis.
- ▶ **Noise:** Causes may include setting the color gain too high. It is a troublesome artifact, but in some cases it should be provoked as a means of detecting slow flow.
- ▶ **Motion artifacts:** Motion artifacts (**color flash**) are also troublesome. Their possible causes include transmitted cardiac pulsations (e.g., when examining vascularized masses in the left lobe of the liver) and transmitted aortic pulsations.
- ▶ **Aliasing:** This becomes a problem when, for diagnostic reasons, the color scale of the instrument has been set to a certain velocity range (PRF) that does not match the flow velocity in all of the sampled vessels. This results in unwanted zones of color reversal.
- ▶ **Confetti artifact:** Appearing as multiple small color pixels, this is an important sign of an abnormality, such as turbulent flow past a stenosis.
- ▶ **Twinkling artifact:** This has major diagnostic significance. It occurs when confetti pixels or color bands (red and blue pixels) are produced by a very strong acoustic reflector (stone, cholesterol polyp) lying in an acoustic shadow. Twinkling is caused by a vibration of the reflector induced by the impinging sound waves. It may be helpful in the diagnosis of kidney stones and other lesions.

## 1.4 Imaging Artifacts

### Basic Principles

---

- ▶ **Definition:** In ultrasound, artifacts are acoustic images that do not correlate with an anatomical structure. They result from the fact that not all physical phenomena are taken into account in the imaging process.
- ▶ **Significance:** Artifacts can have varying significance in the interpretation of sonographic images. Some, such as **slice-thickness artifact**, can interfere with image interpretation whereas others, such as **acoustic shadowing**, are diagnostically useful.
- ▶ **Overview:** See Tables 2 and 3.

**Table 2 · Overview of imaging artifacts**

Important artifacts	Less important artifacts
Side-lobe artifact (p. 9)	Motion artifact
Noise (p. 10)	Double image artifact
Acoustic shadowing (p. 11)	Transit-time artifact
Acoustic enhancement (p. 11)	
Slice-thickness artifact (p. 12)	
Mirror image artifact (p. 13)	
Reverberations (p. 14)	
Edge shadowing (p. 15)	

**Table 3 · Classification of artifacts by echogenicity**

Hyperechoic	Isoechoic	Anechoic
Side-lobe artifact	Motion artifact	Acoustic shadowing
Noise	Double images	Mirror image artifact
Acoustic enhancement	Transit-time artifact	Edge shadowing
Mirror image artifact	Mirror image artifact	
Beam-width artifact		
Reverberations		

### Side-Lobe Artifact (Figs. 3 and 4)

- ▶ **Definition:** An object is improperly represented in the display as a result of echoes generated by side lobes that accompany the main beam.
- ▶ **Description:** A side-lobe artifact appears as a curved line in an anechoic structure.
- ▶ **Significance:** They may be mistaken for internal echoes in cystic organs (septa, sediment).
- ▶ **Differentiation from a real object:** The artifact is easily eliminated by angling the transducer or changing the scan plane.

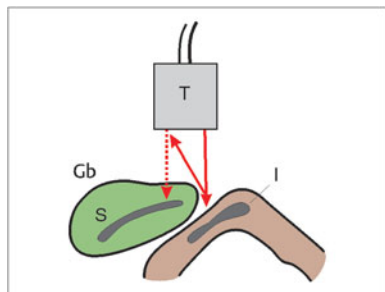


Fig. 3 Side-lobe artifact: Intestinal gas (I) is a strong reflector that is projected into the interior of the gallbladder (Gb). S = side-lobe artifact, T = transducer

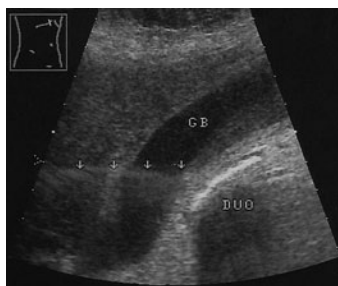

Fig. 4 Side-lobe artifact: The arrows indicate a side-lobe artifact in a stone-free gallbladder (GB). The artifact is caused by gas in the adjacent duodenum (DUO)

### Noise (Figs. 5 and 6)

- ▶ **Definition:** Extremely fine echoes caused by voltage fluctuations in the imaging electronics.
- ▶ **Description:** Noise appears as multiple tiny echoes in the near portion of anechoic structures (“ground glass” appearance in cystic structures).
- ▶ **Significance:** The fine spurious echoes in cystic structures may be mistaken for sludge or gravel. Small cysts may even appear solid.
- ▶ **Differentiation from a real object:** Noise can be eliminated by lowering the gain setting and/or changing the focus.

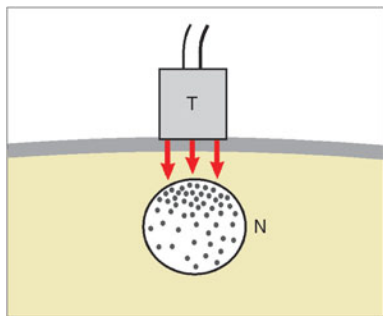


Fig. 5 The amplification of echoes from areas closer to the transducer causes multiple fine echoes to appear within cystic organs. T = transducer, N = noise

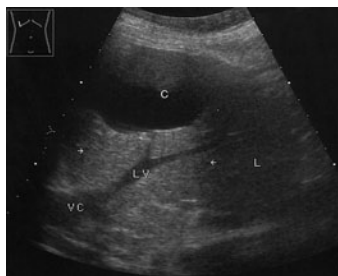


Fig. 6 Noise in a hepatic cyst (C). Multiple fine echoes appear in the anterior part of the cyst

## Acoustic Shadowing (Figs. 7 and 8)

- ▶ **Definition:** An absence of echoes behind structures that are strong reflectors or absorbers of ultrasound.
- ▶ **Description:** The shadow appears as an anechoic band posterior to a high-amplitude echo (from a strong reflector such as calcium, air, or bone).
- ▶ **Significance:**
  - Helpful in the diagnosis of stones and cysts (edge shadowing).
  - Troublesome in abdominal ultrasound (bowel gas and rib shadows).
  - Acoustic shadows are cast not only by strong reflectors but also by connective tissue that is struck tangentially by the beam (ligamentum teres, connective tissue in the porta hepatis).
  - Small stones will cast an acoustic shadow only if they are directly within the focal zone of the transducer.

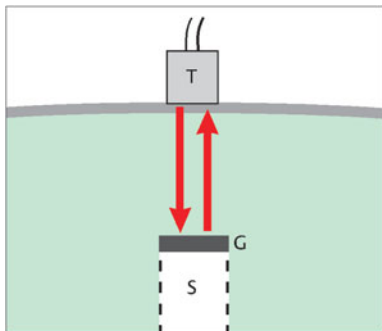


Fig. 7 Acoustic shadowing: A strong acoustic reflector (e.g., a gallstone = G) casts an acoustic shadow (S) due to reflection and absorption. T = transducer

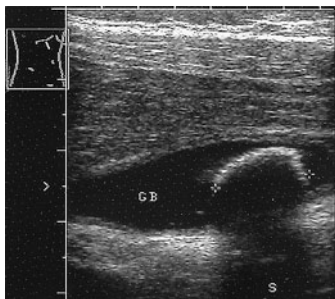


Fig. 8 Typical acoustic shadow (S) associated with a gallstone

## Acoustic Enhancement (Figs. 9 and 10)

- ▶ **Definition:** A relative increase in echogenicity caused by a lack of sound attenuation.
- ▶ **Description:** Structures located behind cysts, abscesses, or necrotic metastases appear more echogenic than adjacent tissues at the same depth.
- ▶ **Significance:**
  - Helpful in the diagnosis of cysts and other anechoic structures.
  - Troublesome in evaluating areas behind cysts and other liquid structures.

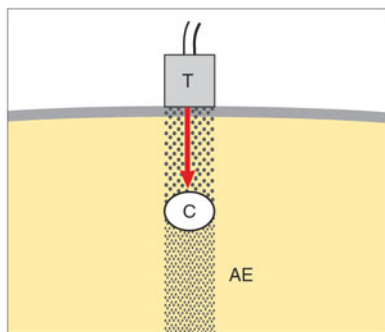


Fig. 9 Acoustic enhancement: Because sound waves are less attenuated in fluid, the echoes behind a fluid-filled structure have greater amplitude. T = transducer, C = cyst, AE = acoustic enhancement

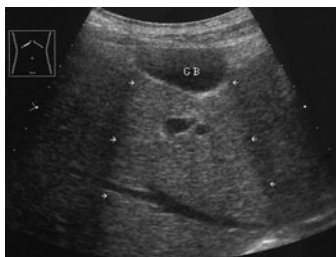

Fig. 10 Posterior acoustic enhancement. An area of increased echogenicity (arrows) appears behind the gallbladder (GB)

### Slice-thickness Artifact (Figs. 11 and 12)

- ▶ **Definition:** Artifact occurring at curved interfaces between anechoic and hyperechoic structures, caused by the beam thickness.
- ▶ **Description:** Appears as fine echoes layered along the inner wall of a fluid-filled structure, causing the wall to appear thickened and indistinct.
- ▶ **Significance:** May be mistaken for debris, sludge, gravel, or clotted blood.

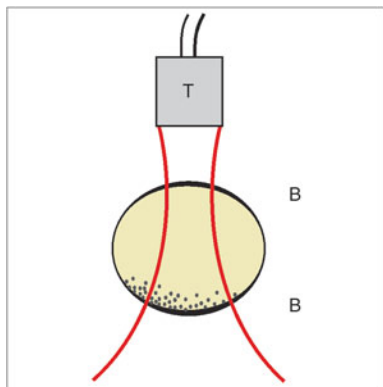
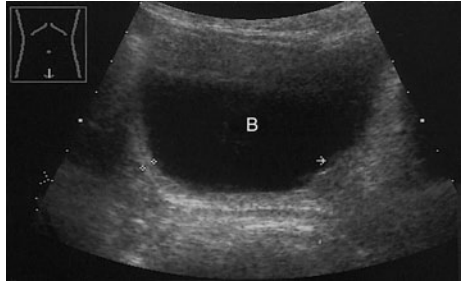


Fig. 11 Slice-thickness artifact: The anterior and posterior cyst walls appear thickened and indistinct. B = beam-width artifact, T = transducer

Fig. 12 Beam-width artifact: Transverse scan through the bladder (B) shows partial thickening and lack of sharpness of the bladder wall, especially on the far side (arrow)



► **Differentiation from a real object:**

- Reposition the patient
- Improve the focus
- Change the scan plane

**Mirror Image Artifact (Figs. 13 and 14)**

- **Definition:** “Ghost images” may appear behind strong reflectors because the reflection alters the path of the beam and doubles its transit time.
- **Description:** Liver tissue located below the strong reflector of the diaphragm is projected to a supradiaphragmatic location in the basal lung zone (“pseudoecho”).
- **Significance:** Minimal, since awareness of the artifact should preclude errors of interpretation.
- **Differentiation from a real object:** The normal parenchyma of the liver and spleen can mimic a pleural effusion, but doubts can be resolved by examining the patient in a sitting position and scanning from the posterior side.

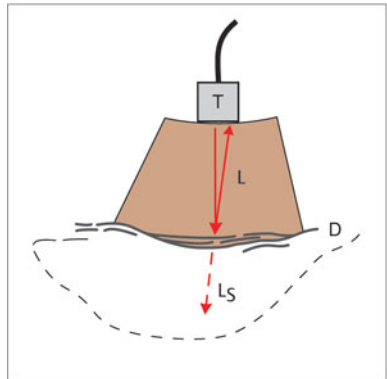


Fig. 13 Mirror image artifact: Schematic representation of sound waves in the liver (L) reflected from the diaphragm (D), giving rise to a “mirror-image” liver. T = transducer, LS = supraphrenic “mirror-image” liver

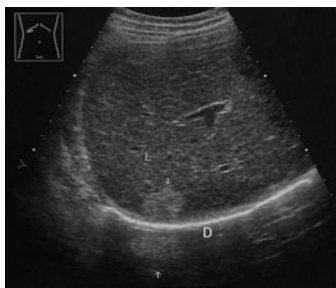

Fig. 14 Mirror image artifact: Right subcostal oblique scan demonstrates the liver (L), the diaphragm (D, or lung entry echo), a subphrenic hepatic hemangioma, and the reflected hemangioma imaged at a supraphrenic location (arrows)

### Reverberations (Figs. 15 and 16)

- ▶ **Definition:** Linear artifacts caused by multiple reflections between two highly reflective interfaces. The computer of the ultrasound system interprets the time delays as increasing distance from the transducer.
- ▶ **Description:** Appear as a series of echogenic lines that are parallel to one another and to the transducer face and whose amplitudes diminish at greater depths
- ▶ **Special forms:**
  - Comet-tail artifact
  - Ring-down artifact

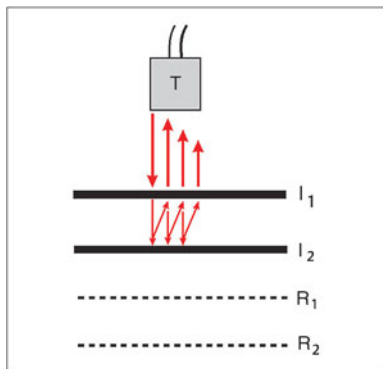


Fig. 15 Schematic representation of typical reverberations (R) occurring between strongly reflective interfaces (I). T = transducer

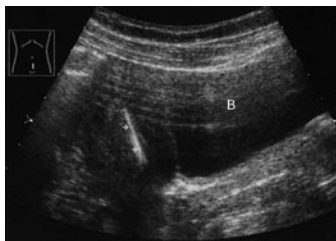


Fig. 16 Reverberations: Longitudinal scan of the uterus and bladder (B) with “superimposed” parallel lines caused by abdominal wall structures. Arrows = IUD

- ▶ **Significance:** Reverberations are consistently present in cystic organs but may also occur in solid structures. They are always troublesome and rarely helpful. They can be eliminated by changing the direction of the beam.

### Edge Shadowing (Figs. 17 and 18)

- ▶ **Definition:** Lateral acoustic shadows caused by a tangential beam angle, scattering, refraction, attenuation, and extinction of the ultrasound beam at cyst walls
- ▶ **Description:** Narrow hypoechoic bands or shadows at the edges of cystic structures, often showing a divergent pattern.
- ▶ **Significance:** Edge shadowing is a useful criterion for diagnosing cysts.
- ▶ **Differentiation from a real object:**
  - Edge shadows can mimic stones, especially in the gallbladder fundus and cystic duct.
  - Double-check the finding in a second scan plane.

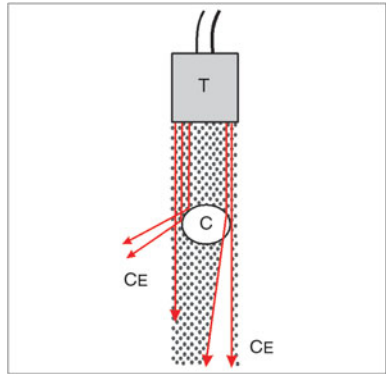


Fig. 17 Edge shadowing: When sound waves encounter cyst walls at a tangential angle, they are scattered or refracted.

T = transducer,

C = cyst,

CE = cystic edge shadows

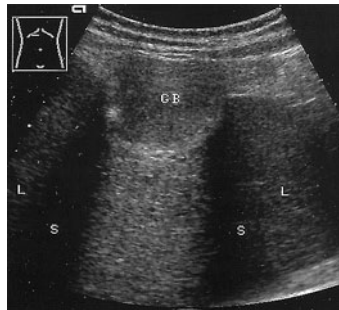


Fig. 18 Edge shadowing. The refraction and attenuation of sound at cyst margins produces a divergent or convergent pattern of acoustic shadowing. Sound attenuation by the echogenic walls of cystic structures is not the only cause of this artifact, which may also result from deviation of the beam due to scattering and refraction. This explains the divergent pattern of edge shadowing that may be seen.

## 2 The Ultrasound Examination

### 2.1 Abdominal Sonography

#### Examination Conditions

- ▶ **Prerequisites:** The patient should be examined in a darkened room with a quiet atmosphere and comfortable ambient temperature. It is essential to select the proper transducer (depending on the organ of interest) and use the correct monitor and scanner settings (p. 6). Other important keys to a successful examination:
  - Address the clinical problem.
  - Premedication with simeticone is rarely needed. When indicated, a high dose should be administered in liquid form.
  - Use sufficient coupling gel between the skin and transducer, eliminating all air bubbles.
  - Use a sterile film on fresh wounds (a cheaper option is a disposable glove without talcum).
  - Reschedule if the examination conditions are poor.
- ▶ **Positioning:** Most organs are scanned with the patient supine. Less common positions are right or left lateral decubitus, sitting, standing, and the semiupright position (see also scanning tips). The examination couch should not be too soft. Bed-side examinations are difficult.

#### Classification of Scan Planes

- ▶ **Introductory notes:**
  - The organs are displayed in “thin slices” as defined by the geometry of the beam (see Fig. 19).
  - Standard ultrasound scan planes basically consist of longitudinal and transverse planes
  - During the examination, the transducer should be oriented in a defined way referring to a special topographic anatomy (Figs. 21, 22, 35, 37, 38). This is important for anatomical orientation in the displayed image.
  - The transducer position can be checked in the moving image to confirm right-left orientation. The image lines should be generated from right to left on the monitor when the transducer is moved to the left, and an acoustic shadow should appear on the left side when the examiner slips a finger beneath the left side of the probe.
- ▶ **Transverse scan:** In a transverse (axial) scan, the right side of the image should correspond to the anatomical left side, and the left side of the image to the anatomical right side. Structures that are closer to the transducer should appear at the top of the image, and structures farther from the transducer should appear at the bottom.
- ▶ **Longitudinal scan:** In a longitudinal scan, the left side of the image should be cranial (superior) and the right side caudal (inferior). Structures closer to the transducer should appear at the top of the image, and structures farther from the transducer should appear at the bottom (as in a transverse scan).
- ▶ **Overview:** See Table 4.

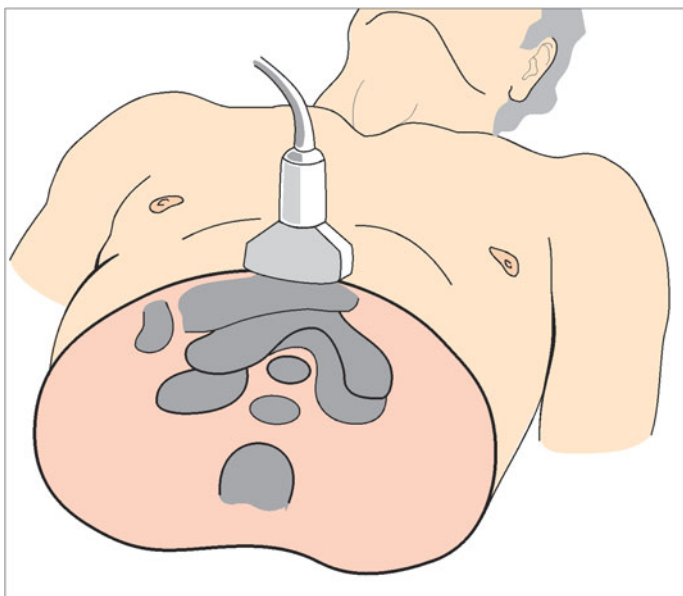


Fig. 19 Schematic representation of a body slice

**Table 4 · Overview of standard ultrasound scan planes**

Standard scan planes	Organs imaged
<i>Transverse scans</i>	
Upper abdominal transverse scan	Liver, stomach, pancreas, vessels (Fig. 23)
Right subcostal oblique scan	Liver, gallbladder (Figs. 24, 30, 33)
Left subcostal oblique scan	Left lobe of liver, stomach, spleen (Fig. 34)
Lower abdominal transverse scan	Bladder, rectum, uterus, fallopian tubes, prostate (Fig. 39)
<i>Longitudinal scans</i>	
Intercostal scan (porta hepatis scan, shoulder–umbilicus scan)	Liver, porta hepatis, gallbladder, bile ducts (Figs. 25–27)
Right flank scan	Liver, kidney (Fig. 29)
Left flank scan	Spleen, kidney (Figs. 31, 32)
Upper abdominal longitudinal scan	Liver, stomach, pancreas, vessels (Figs. 28, 36)
Lower abdominal longitudinal scan	Bladder, rectum, uterus, prostate (Fig. 40)

### Scanning Protocol

---

- ▶ Beginners in particular should follow a systematic protocol in routine ultrasound examinations to ensure complete coverage. The scan planes shown in Fig. 20 can be imaged in the sequence indicated.
- ▶ The examination proceeds in a counterclockwise direction. Longitudinal and transverse scans are carried out continuously along the vessels, working from the upper abdomen to the lower abdomen.
- ▶ **Possible sequence of standard scan planes:**
  - Upper abdominal transverse scan
  - Right subcostal oblique scan
  - Right intercostal scan
  - Extended right intercostal scan
  - Longitudinal paramedian scan
  - Right flank scan
  - Right midabdominal transverse scan
  - High left intercostal scan (high left flank scan)
  - Left flank scan
  - Left midabdominal transverse scan
  - Left subcostal oblique scan
  - Upper abdominal longitudinal scan
  - Lower abdominal longitudinal scan
  - Lower abdominal transverse scan

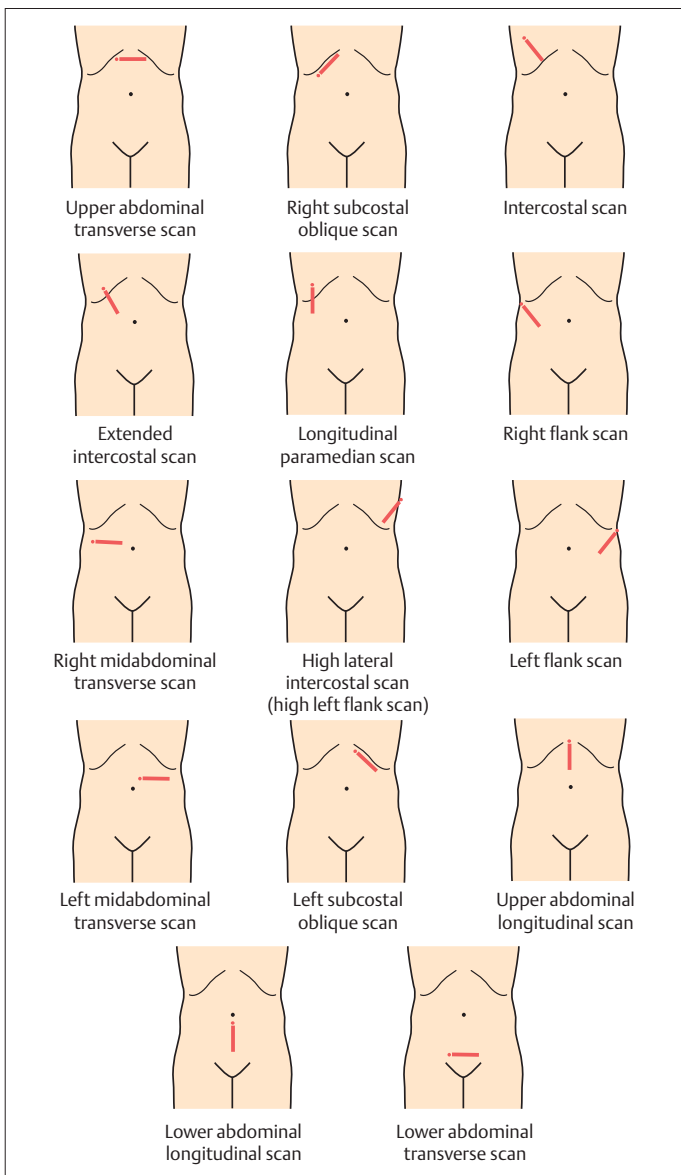


Fig. 20 Standard and supplemental scan planes

Classification of Scan Planes, Sonographic Topography

► Relationship of the gallbladder to adjacent organs:

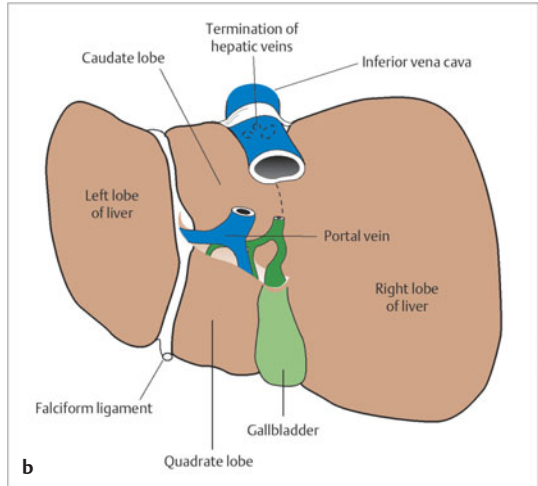
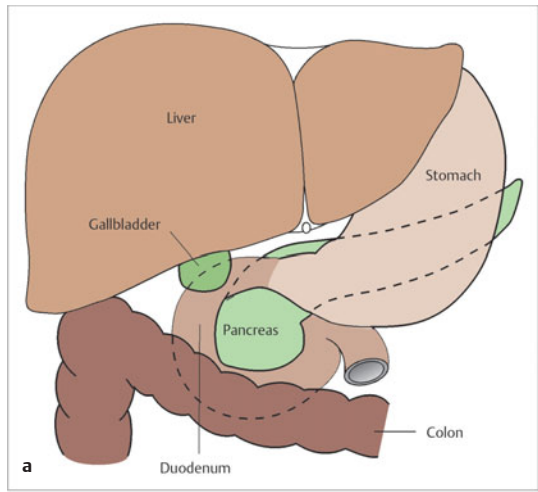


Fig. 21a, b **a** The gallbladder fundus extends past the inferior border of the liver. It lies to the right of the C-shaped duodenal loop and cranial to the right colic flexure. **b** Visceral surface: The caudate lobe is bounded by the superior border of the liver, falciform ligament, gallbladder, and vena cava. The quadrate lobe is bounded by the inferior border of the liver, falciform ligament, gallbladder, and portal vein

► Topographic anatomy of the pancreas and bile ducts:

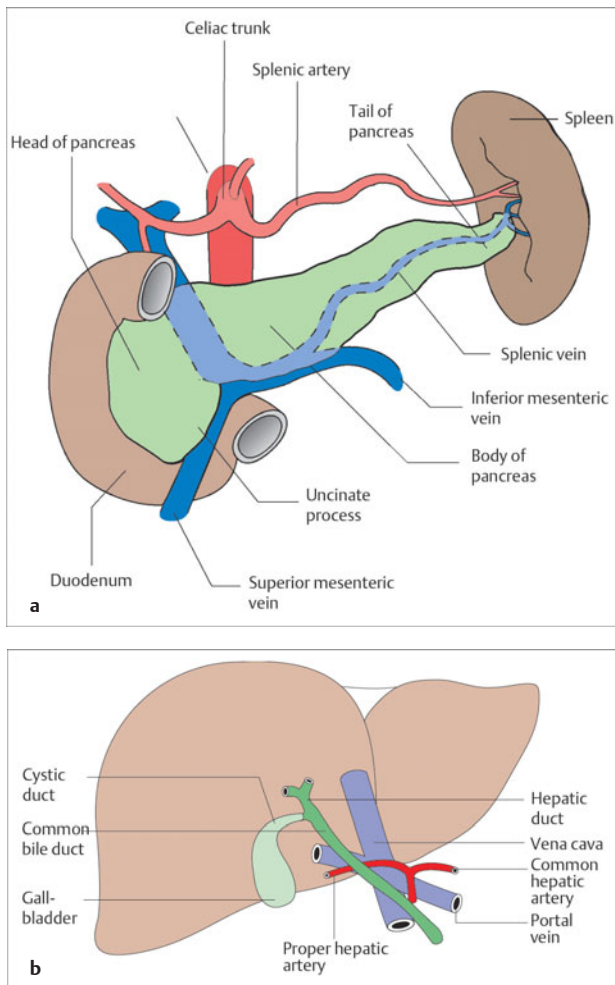


Fig. 22a, b **a** The splenic artery runs posteriorly and superiorly, the splenic vein posteriorly and inferiorly. The tail of the pancreas extends toward the hilum of the spleen, and the head of the pancreas lies within the C-shaped loop of the duodenum. The left lobe of the liver is anterior to the pancreas, and the aorta is posterior.

**b** Topographic anatomy of the bile ducts

► Upper abdominal transverse scan:

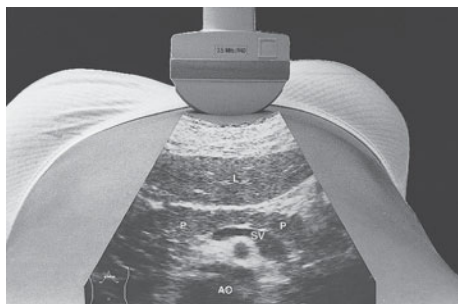


Fig. 23 The upper abdominal transverse scan displays the following structures from anterior to posterior: liver (L), splenic vein (SV), pancreas (P), aorta (AO)

► Anatomical guidelines for scanning the liver:

- The right and left lobes of the liver are separated by the falciform ligament. The ligament appears sonographically as an echogenic band (see Fig. 359), p. 252; scans through the right and left lobes).
- The separation of the two anatomical halves of the liver by the falciform ligament is most clearly appreciated when viewed from the posteroinferior direction.
- Based on the segmental anatomy of the liver, a line drawn from the gallbladder to the vena cava, marked by the interlobar fissure, separates the physiological right and left lobes of the liver.
- The gallbladder lies against the inferior surface of the right lobe of the liver.
- To locate the caudate and quadrate lobes more easily, imagine the letter H drawn on the visceral surface of the liver. One limb of the H is formed by a line connecting the gallbladder and vena cava (which lie in grooves in the liver); the other limb is formed by the falciform ligament. The crossbar is formed by the porta hepatis where the portal vein divides into its right and left main branches. The open areas of the H are occupied superiorly by the caudate lobe and inferiorly by the quadrate lobe (see Fig. 319), p. 231; visceral surface of the liver).

► Right subcostal oblique scan:

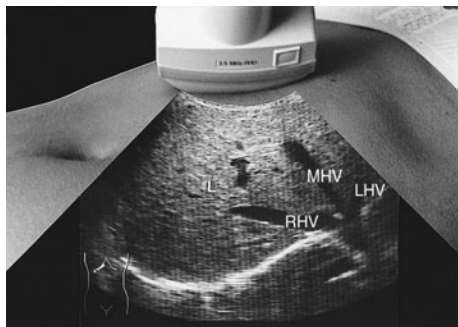


Fig. 24 The probe is placed below the right costal arch and angled laterally upward. The beam is directed postero-laterally and superiorly. The beam passes through the liver (L) and gives a longitudinal view of the hepatic veins, which open posteriorly into the vena cava. RHV = right hepatic vein, MHV = middle hepatic vein, LHV = left hepatic vein

► **Right intercostal scan:**

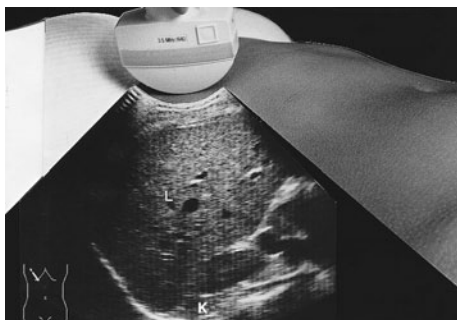


Fig. 25 The intercostal scan is placed on an imaginary line between the right shoulder and the umbilicus. From this point the beam can be swept across the liver (L) in a fan-shaped pattern. The kidney (K) is posterior

► **Extended right intercostal scan:**

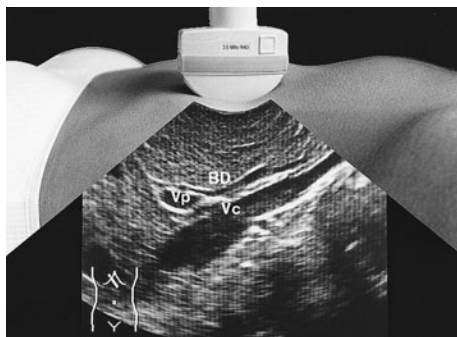


Fig. 26 The extrahepatic bile ducts are defined in the porta hepatis scan by sliding the probe toward the umbilicus. The probe can be slightly angled and rotated to demonstrate the bile duct (BD), vena cava (Vc), and portal vein (Vp) in approximate longitudinal sections. These structures are easier to define in left lateral decubitus at full inspiration

- ▶ Extended right intercostal scan:

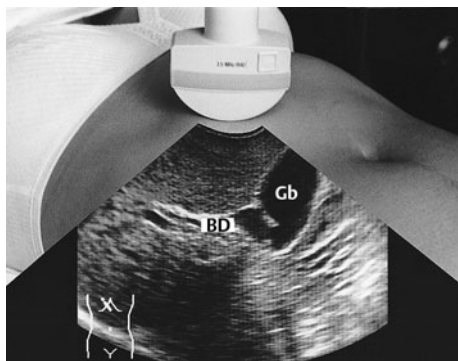


Fig. 27 Scanning in the same direction, the probe can be moved along the costal arch to define the gallbladder (Gb) in longitudinal section. The gallbladder is most easily located by keeping the inferior border of the liver in view while moving the probe. BD = bile duct

- ▶ Right longitudinal paramedian scan:

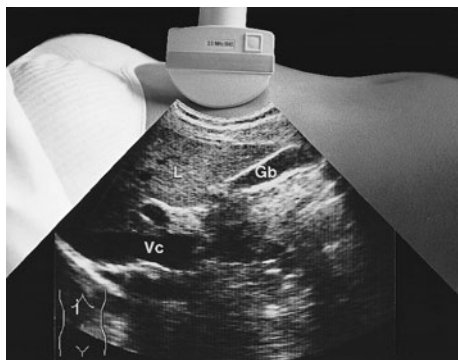

Fig. 28 The probe is oriented longitudinally and is placed lateral to the midline in an intercostal space or below the costal arch. The liver (L) is displayed in longitudinal section, and the shape of the (normally acute) inferior hepatic angle can be evaluated. The fundus of the gallbladder (Gb) projects past the inferior border of the liver. The vena cava (Vc) is displayed in longitudinal section and is posterior to the liver. Vena cava filling can be evaluated in this plane

► **Right flank scan:**

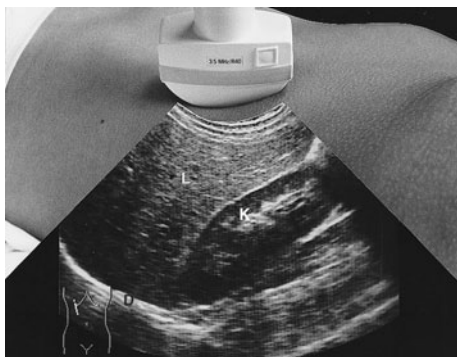

Fig. 29 The flank scan is obtained by moving the probe laterally from the paramedian position. It is used to evaluate the pleural angle distal to the diaphragm (D) and displays a longitudinal section of the kidney (K) posterior to the liver (L)

► **Right midabdominal transverse scan:**

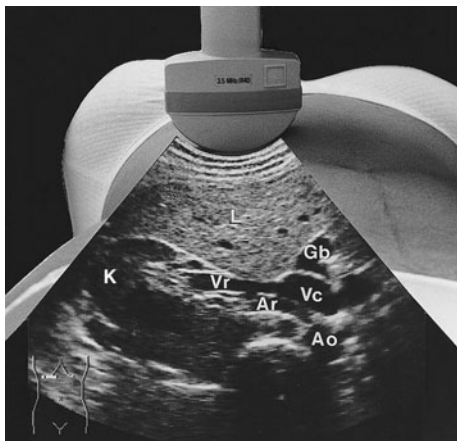


Fig. 30 While viewing the kidney in longitudinal section, the examiner rotates the probe to a midabdominal transverse position and slides it toward the midline. The kidney (K) is displayed in cross-section posterior to the liver (L). The vascular pedicle with the renal vein (Vr) and renal artery (Ar) can be identified from anterior to posterior at the level of the renal hilum, and the ureter may also be seen. In thin patients, one section may display the termination of the renal vein at the vena cava (Vc), the origin of the renal artery from the aorta (Ao), and the gallbladder (Gb) at the inferior border of the liver

- ▶ High lateral intercostal scan (high left flank scan):

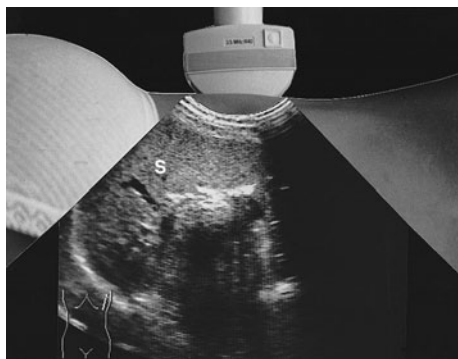

Fig. 31 The probe is placed in an intercostal space cranial to the left flank and is angled cephalad and medially to demonstrate the spleen (S) in longitudinal section. The upper pole of the spleen appears on the left side of the image, the lower pole on the right side. The probe is rotated, slid, and angled until the longest diameter is visualized. The length of the spleen and its thickness at the level of the splenic hilum are measured

- ▶ Left flank scan:

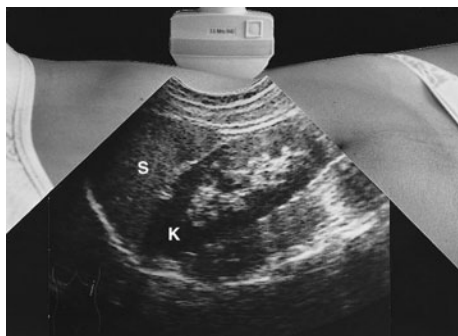


Fig. 32 As the probe is moved caudad from the high flank scan, the kidney (K) appears in longitudinal section posterior to the spleen (S). The orientation of the kidney, its posteriorly placed upper pole, and its anteriorly directed lower pole can be clearly identified

► **Left midabdominal transverse scan:**

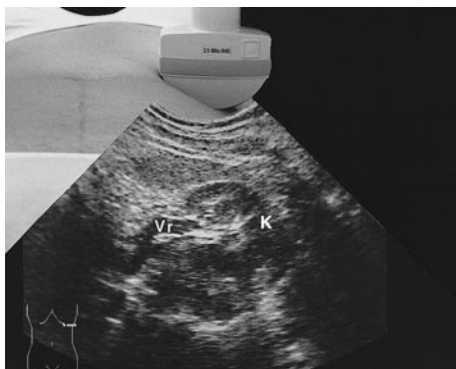

Fig. 33 While still over the kidney, the probe is rotated to a transverse position and is angled, rotated, and slid to a midabdominal transverse scan that displays the renal hilum with its vascular pedicle and may define the proximal ureter. The probe is then moved slowly down the kidney (K) from its upper to lower pole to survey the organ in transverse sections. Vr = renal vein

► **Left subcostal oblique scan:**

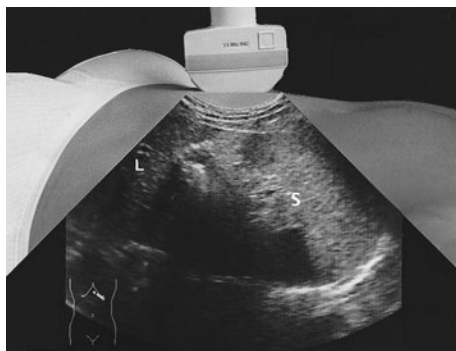


Fig. 34 From the midabdominal transverse scan, the probe is slid to a position below the left costal arch to obtain a left subcostal oblique scan. The liver (L) is visible on the left side of the image. The spleen (S) appears posterolaterally on the right side of the image, displaying its true width and a foreshortened longitudinal diameter

► Diagram of the major abdominal vessels:

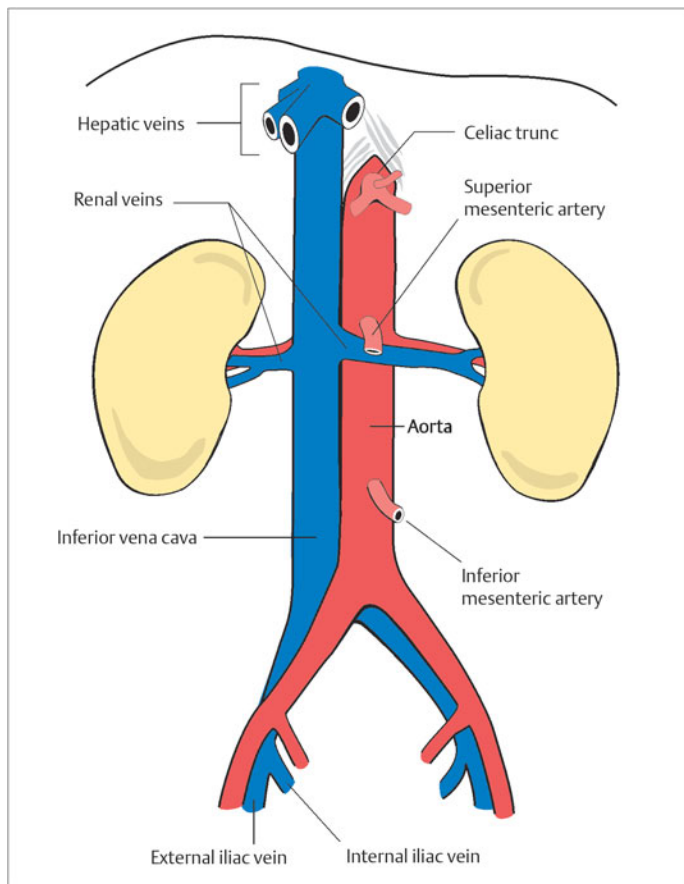
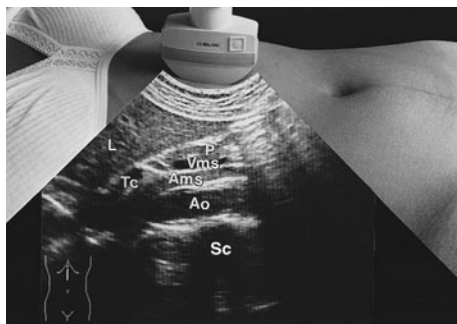


Fig. 35 Diagram of the arterial vessels arising from the aorta and the tributaries of the vena cava. These vessels can be distinguished sonographically and can provide useful landmarks for intra-abdominal scanning

► Upper abdominal longitudinal scan:

Fig. 36 The following structures can be identified from anterior to posterior: liver (L), pancreas (P), superior mesenteric vein (Vms), celiac trunk (Tc), and superior mesenteric artery (Ams), the latter two arising from the aorta (AO). The spinal column (Sc) is visible posteriorly



► Diagram of the female genital organs:

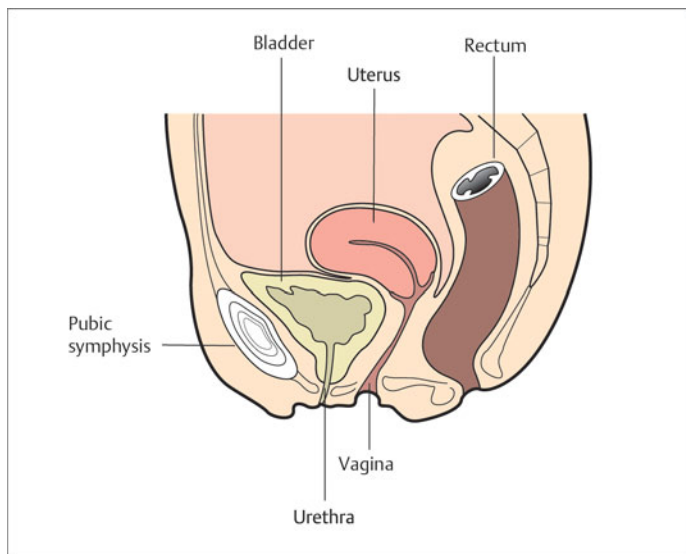


Fig. 37 Relationships of the lower abdominal organs in the female. This diagram aids in understanding how the ultrasound probe should be directed during the examination. The uterus lies posterior and superior to the bladder. The following structures appear in sagittal section from anterior to posterior: pubic symphysis (sound does not penetrate bone, so the probe must be placed above the symphysis), bladder, uterus, and rectum. The probe can be angled downward to demonstrate the vagina

- ▶ Diagram of the male genital organs:

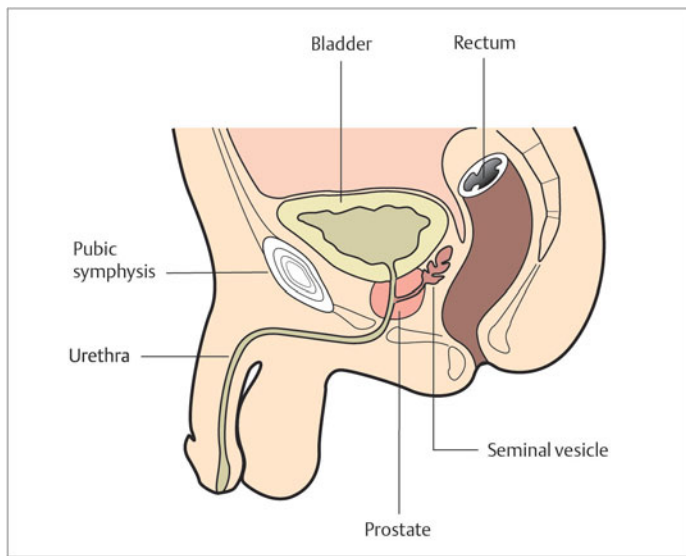


Fig. 38 The male pelvis has a similar structure. It is important to note that the prostate is inferior to the bladder, and the seminal vesicles are posteroinferior

- ▶ Lower abdominal transverse scan:

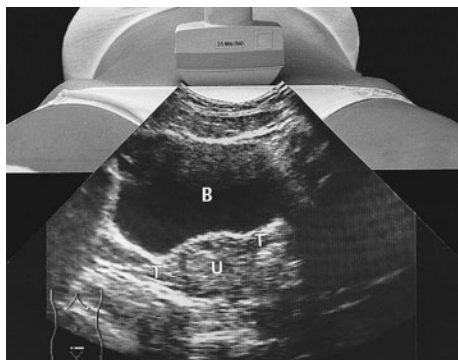


Fig. 39 The following structures are defined from anterior to posterior: abdominal wall, bladder (B), and uterus (U), which is flanked by the fallopian tubes (T)

► Lower abdominal longitudinal scan:

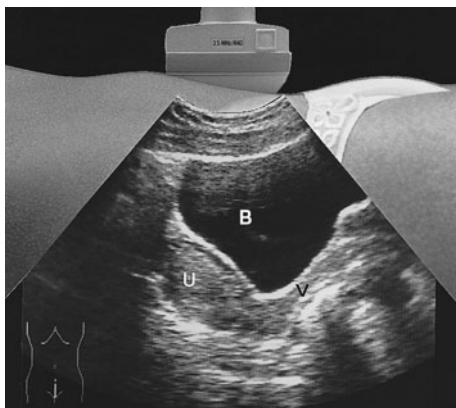


Fig. 40 From anterior to posterior: abdominal wall, bladder (B), and uterus (U), which is bounded by the fundus above and the vagina (V) below

### Examination of Specific Organs: See Blue Part

Arteries and veins, p. 188; cervical vessels, p. 214; liver, p. 231; kidney, p. 262; adrenal glands, p. 292; pancreas, p. 293; spleen, p. 312; bile ducts, p. 322; gallbladder, p. 334; gastrointestinal tract, p. 352; urogenital organs, p. 375; pleura and lung, p. 400; thyroid gland, p. 412; salivary glands, p. 425.

## 2.2 Ultrasound Imaging of Joints (Arthrosonography)

### Basic Principles

- **Clinical importance:** In recent years, ultrasonography of the musculoskeletal system has developed into a recognized and clinically important imaging modality. For investigations in rheumatology, ultrasound imaging is the next step in the diagnostic algorithm following the history and physical examination. The intra- and periarticular soft-tissue changes that are typical of inflammatory joint diseases can be detected much earlier by sonography than by physical examination or radiography. Sonography can make an important contribution to diagnosis (e.g., detecting clinically asymptomatic synovitis) as well as management (e.g., the prompt initiation of basic treatment for early destructive joint changes).
- **Capabilities of arthrosonography:**
- Detection of exudative or proliferative articular synovitis
  - Detection of exudative or proliferative tenosynovitis
  - Detection of synovial cysts
  - Early detection of erosive defects in bone and joint margins
  - Detection of degenerative articular and soft-tissue changes such as marginal osteophytes, bursitis, periarticular ossification, and tendon lesions
- **Limitations of arthrosonography:**
- Limited ability to image superficial joint structures, depending on individual anatomy

- Poor visualization of deeper joint structures, with an inability to evaluate intra-articular or subchondral lesions
- Limited ability to discriminate synovitis (“inflammatory substrates”) in the B-mode image

▶ **Normal findings** (Table 5):

**Table 5 · Normal sonographic findings**

Structure	Sonographic appearance
Synovial membrane	Echogenic, normally difficult to delineate from connective tissue
Cartilage	Anechoic, parallel to bone surface
Bone	Very echogenic with an associated acoustic shadow
Tendons	Echogenic when scanned at a perpendicular angle, but may appear hypoechoic (Fig. 41) when scanned at certain angles (acoustic anisotropy; compare with muscle)
Muscle	Hypoechoic; typical pennate pattern in longitudinal section; mottled echo pattern in transverse section

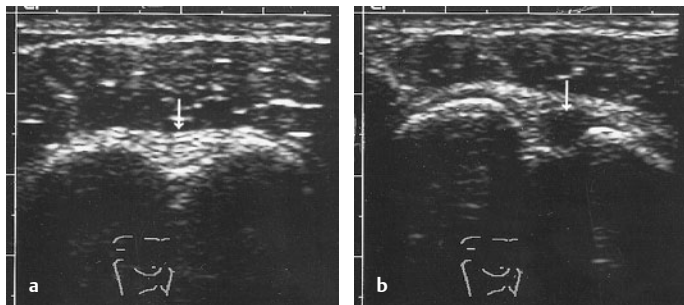


Fig. 41a, b Anterior transverse scan of the shoulder. **a** When the long biceps tendon is perpendicular to the beam, it appears as a bright round echo (→). **b** When the long biceps tendon is scanned at a different angle, the sound waves are not reflected and the tendon groove (→) appears empty.

⚠ **Caution:** Do not interpret this as a tendon rupture

## ► Typical abnormal findings (Table 6):

**Table 6 · Typical abnormal findings**

Structure	Sonographic appearance
Joint effusion	Anechoic or hypoechoic (Fig. 42)
“True” bone erosion	Constant surface discontinuity with echoes from the base of the erosion (Fig. 43)
Pseudoerosion	Apparent defect caused by beam obliquity relative to the bone surface; no base echoes
Pannus	Erosive changes in articular surfaces with infiltration of tendons (Fig. 44)
Synovitis (“inflammatory substrate”)	B-mode image: hypoechoic thickening of the joint capsule (the proliferative and exudative components cannot be positively distinguished in most cases) Color or power Doppler: increased vascularity (Fig. 45)
Tenosynovitis	Anechoic or hypoechoic margin surrounding an echogenic tendon (Fig. 46)

Pannus = inflammatory exudate that can destroy articular cartilage and bone as well as tendons.

Synovitis (“inflammatory substrate”) = synovial proliferation (proliferative component), usually associated with intra-articular effusion (exudative component) → joint swelling.

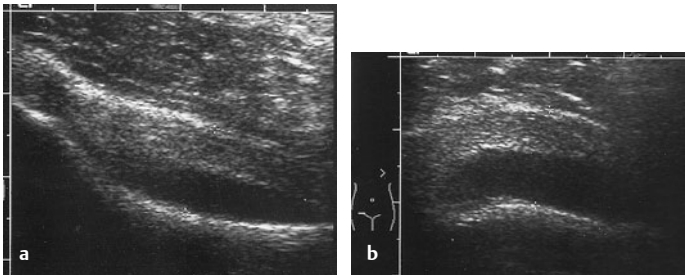


Fig. 42a, b Anechoic effusion in exudative coxitis. Ultrasound demonstrates convex widening of the joint capsule. **a** Longitudinal scan, **b** transverse scan

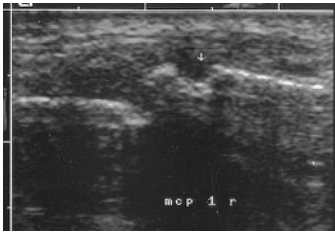


Fig. 43 Echogenic base of an erosion: circumscribed erosive defect at the base of the first proximal phalanx (arrow) in erosive psoriatic arthritis

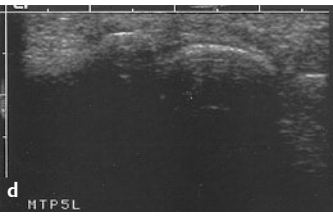
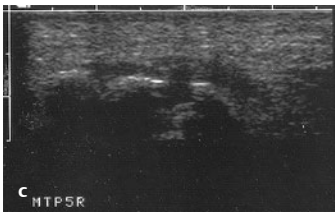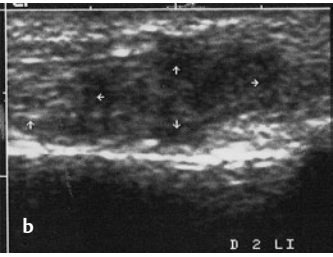
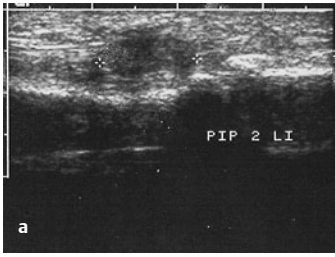


Fig. 44a–d Pannus. **a, b** Hypoechoic infiltration of the tendon by pannus tissue (arrows) due to pannous flexor tenosynovitis in a patient with chronic rheumatoid arthritis. **a** Survey image, **b** zoom image. **c, d** Fifth MTP joint with pannus in the right foot (**c**); compare with the same joint without pannus in the left foot (**d**)

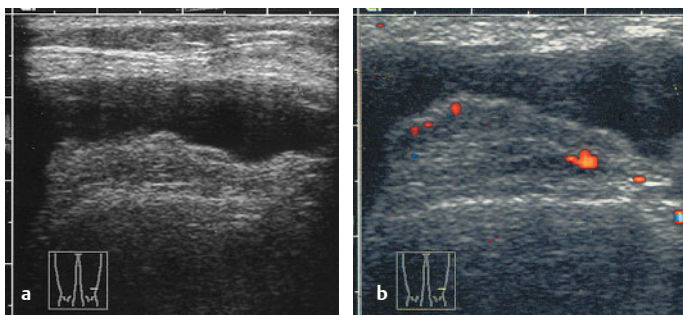


Fig. 45a–c Synovitis in an arthritic knee.

**a** Transverse B-mode image.

**b** CDS demonstrates areas of boggy synovial thickening with increased vascularity.

**c** Doppler spectrum shows a typical increase in diastolic flow

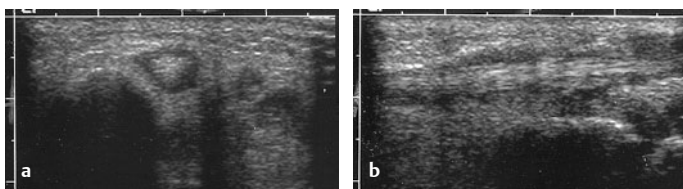


Fig. 46a, b Tendovaginitis appears as a hypoechoic rim around the tendon of the extensor carpi ulnaris. **a** Transverse scan, **b** longitudinal scan over the distal ulna

## General Scanning Guidelines

### ▶ Transducers:

- *High-frequency linear transducer* (7.5–15 MHz): Used for examining superficial structures (e.g., tendons and ligaments) and small joints in the hands or feet.
- *Low-frequency linear transducer* (5 MHz): Used for scanning deeper joints (e.g., the hip and shoulder joints).
- *Convex 3.5 MHz transducer*: Necessary only in rare cases, as in very obese patients.

### ▶ Scanning tips:

- Use standard anatomical landmarks for orientation.
- Locate the static transverse and longitudinal scan planes.
- Use the RES function on the machine to zoom selected regions of interest while maintaining high resolution.
- For dynamic scanning, move the transducer continuously during active or passive motion of the scanned structures. Joint motion is often necessary in order to detect subtle abnormalities (e.g., mild degrees of exudation).
- Always compare the findings with the contralateral joint.

## Sonography of the Shoulder

- ▶ The patient is examined in a sitting position with the arm hanging at the side, the elbow flexed 90°, and the forearm supinated. Dynamic scans are obtained with internal/external rotation and abduction of the shoulder joint.
- ▶ **Scan planes:**
  - *Anterior longitudinal scan:*

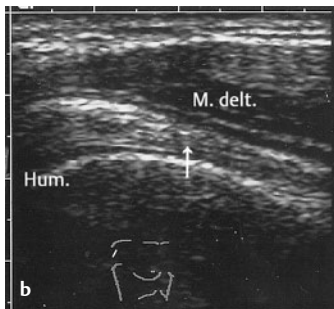
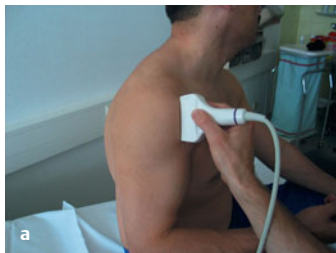

Fig. 47a, b Sonography of the shoulder: anterior longitudinal scan. **a** Scan plane, **b** normal findings. The humerus appears below the long biceps tendon, and above that is the deltoid muscle

- *Anterior transverse scan:*

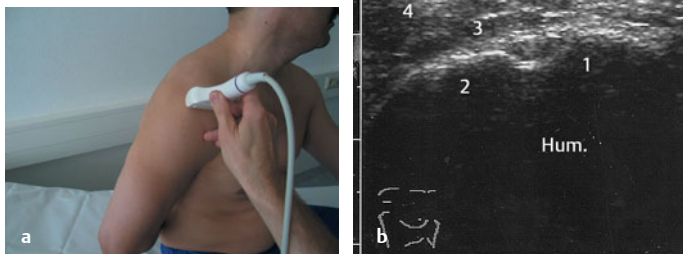


Fig. 48a, b Sonography of the shoulder: anterior transverse scan. **a** Scan plane, **b** normal findings. The greater tuberosity is on the left side of the image (2), adjacent to the biceps tendon groove. The lesser tuberosity is on the right (1); 3 = supraspinatus muscle, 4 = infraspinatus muscle

- *Posterior longitudinal scan:*

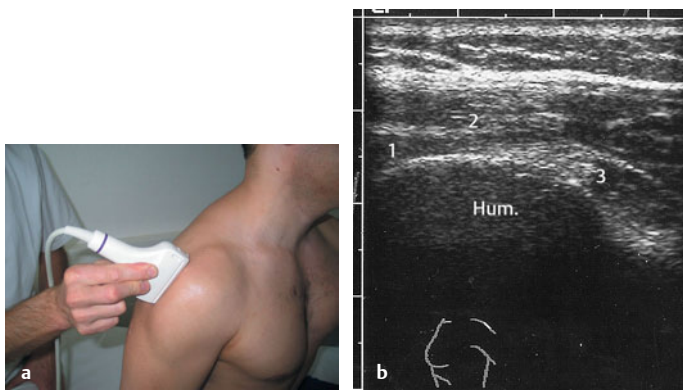


Fig. 49a, b Sonography of the shoulder: posterior longitudinal scan. **a** Scan plane, **b** normal findings. 1 = Supraspinatus muscle, 2 = infraspinatus muscle, 3 = teres major

- *Posterior transverse scan:*

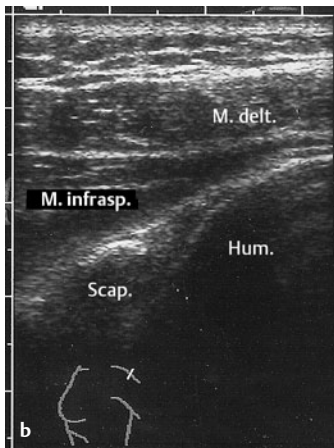
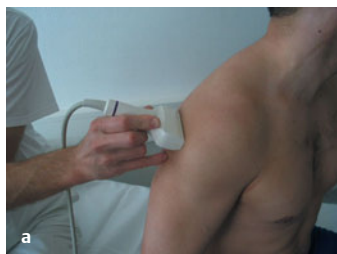

Fig. 50a, b Sonography of the shoulder: posterior transverse scan. **a** Scan plane, **b** normal findings. The humerus appears on the right side of the image. To the left of it is the scapular border, and above that is the infraspinatus. The deltoid muscle is visible above the humerus

- *Lateral longitudinal scan:*

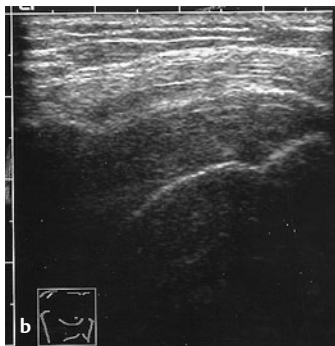
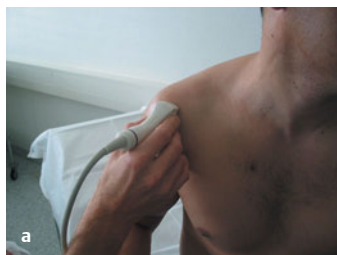


Fig. 51a, b Lateral longitudinal scan of the rotator cuff. **a** Scan plane, **b** normal findings. The image in this place resembles a bird's head and beak. The acromion is on the left, the humerus is at lower right. Between them is the supraspinatus muscle, and above that is the deltoid

- *Lateral transverse scan:*

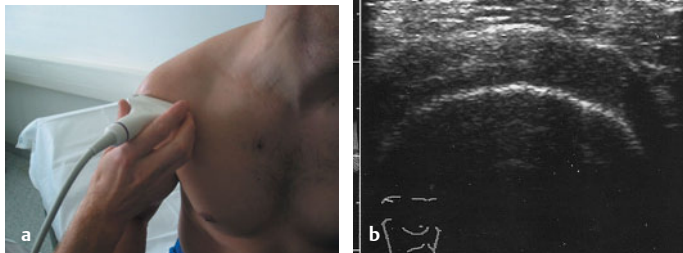


Fig. 52a, b Lateral transverse scan of the rotator cuff. **a** Scan plane, **b** normal findings. The image in this plane resembles a tire on a wheel. The humerus appears at the bottom of the image, with the rotator cuff above it. Above the rotator cuff are the deltoid muscle and subcutaneous tissue

- *Axillary longitudinal scan (Fig. 53):* Can detect small effusions.

**⚠ Caution:** Do not press too hard with the transducer, as this could mask small effusion volumes.

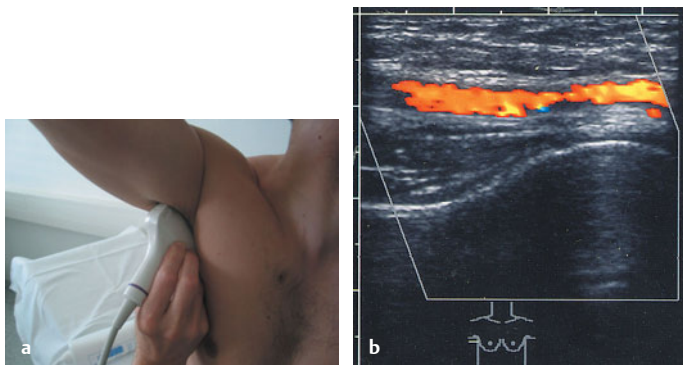


Fig. 53a, b Axillary longitudinal scan. **a** demonstrates the axillary recess of the joint capsule, which is concave and parallel to the neck of the humerus. **b** Major vascular structures (axillary artery) appear hypoechoic on CDS

### Sonography of the Elbow

- ▶ The patient is examined in a standing position.
- ▶ **Scan planes:** Posterior scans with the elbow flexed, anterior scans with the elbow extended.
  - *Anterior humeroradial scan:*

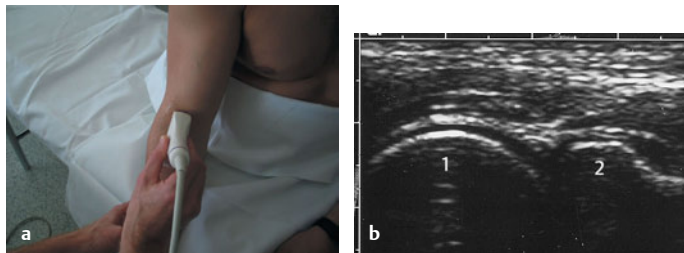


Fig. 54a, b Sonography of the elbow: anterior humeroradial longitudinal scan. **a** Scan plane, **b** normal findings. 1 = Capitellum of the humerus, 2 = head of the radius

- *Anterior humeroulnar scan:*

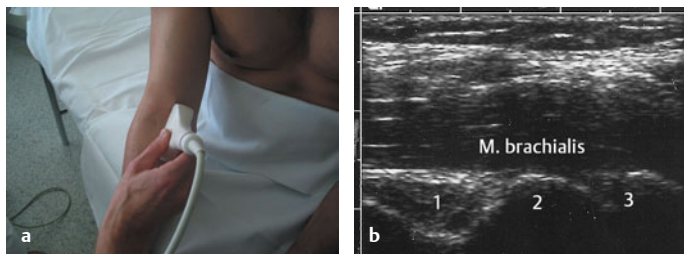


Fig. 55a, b Sonography of the elbow: anterior humeroulnar longitudinal scan. **a** Scan plane, **b** normal findings. 1 = Coronoid fossa, 2 = humeral trochlea, 3 = coronoid process of the ulna, with the brachialis muscle above

- *Posterior longitudinal scan:*

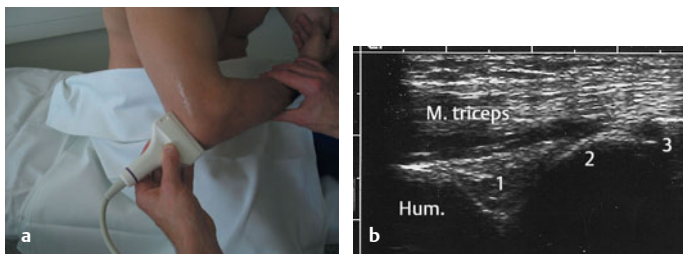


Fig. 56a, b Sonography of the elbow: posterior longitudinal scan. **a** Scan plane, **b** normal findings. 1 = Olecranon fossa, 2 = humeral trochlea, 3 = olecranon, with the triceps muscle above

### Sonography of the Carpal Joints, Fingers, and Toes

- ▶ The small joints in particular are easily accessible to ultrasound examination.
- ▶ **Scan planes:** Posterior and anterior transverse and longitudinal scans.

### Sonography of the Hip

- ▶ 5–7.5 MHz transducer.
- ▶ The patient is examined in the supine or lateral position.
- ▶ **Scan planes:**
  - Anterior scan along the neck of the femur (Fig. 57); 90° transverse scan in the neutral (0°) joint position; may also obtain dynamic scans with the hip joint in slight flexion (10–20°) and rotation.

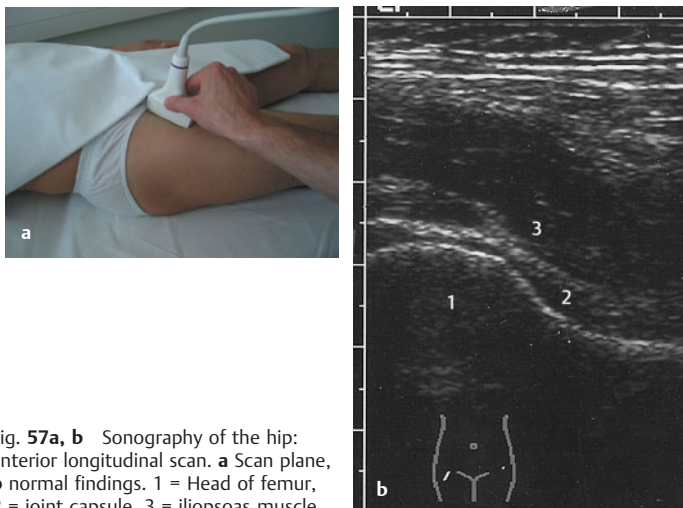


Fig. 57a, b Sonography of the hip: anterior longitudinal scan. **a** Scan plane, **b** normal findings. 1 = Head of femur, 2 = joint capsule, 3 = iliopsoas muscle

- Posterior scan along the neck of the femur; 90° transverse scan with the hip joint in 90° flexion (Fig. 58).

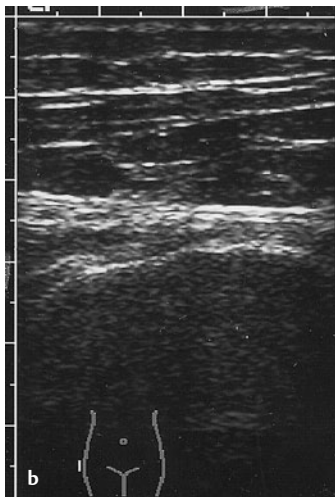
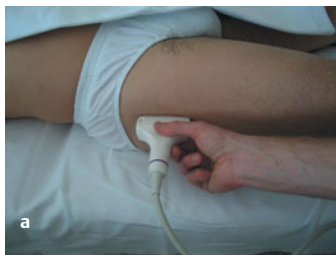

Fig. 58a, b Sonography of the hip: lateral longitudinal scan over the greater trochanter.  
**a** Scan plane, **b** normal findings. Above the greater trochanter are the insertions of the gluteal muscles, and above that are layers of subcutaneous connective tissue and fat

- Lateral longitudinal scan over the greater trochanter (to check for trochanteric bursitis).

### Sonography of the Knee

- ▶ The patient is examined in the supine position. The prone position is used for scanning the popliteal fossa.
- ▶ Flexion of the knee makes more areas of the joint accessible to scanning.
- ▶ **Scan planes:**
  - Anterior longitudinal and transverse scans for evaluating the supra-, para- and infrapatellar recesses (Figs. 59 and 60).
  - Posterior longitudinal and transverse scans for evaluating the popliteal recess or a popliteal cyst (Baker cyst) and blood vessels (Fig. 61).
  - Supplementary medial and lateral longitudinal scans.

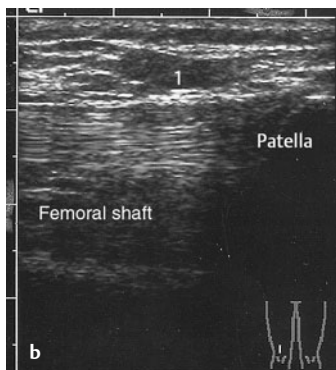
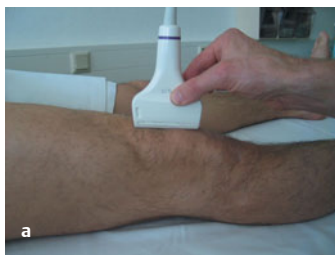

Fig. 59a, b Sonography of the knee: suprapatellar longitudinal scan.

**a** Scan plane. **b** Normal sonographic appearance of the patella, femoral shaft, and quadriceps tendon

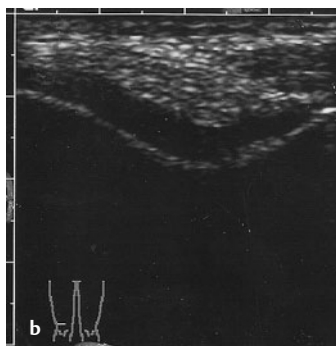
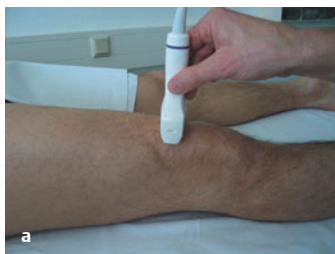

Fig. 60a, b Sonography of the knee: suprapatellar transverse scan with the knee in flexion. **a** Scan plane, **b** normal findings. Concavity = hyaline cartilage.

The medial condyle is on the left, the lateral condyle on the right. Above that is the quadriceps tendon, imaged in cross-section

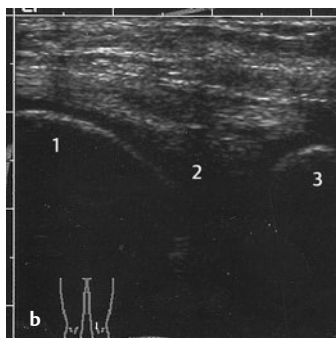
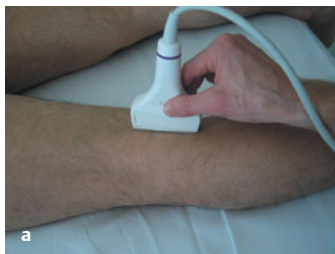

Fig. 61a, b Sonography of the knee: posterior (medial) longitudinal scan of the right knee. **a** Scan plane, **b** normal findings. 1 = Medial femoral condyle, 2 = joint space, 3 = tibia

### Sonography of the Malleolar Region

- ▶ The patient is examined in the supine position. The prone position is used for posterior scanning. The ankle joint should be unconstrained, to allow passive movement.
- ▶ **Ankle joint:**
  - Anterior and posterior longitudinal and transverse scans (Fig. 62).

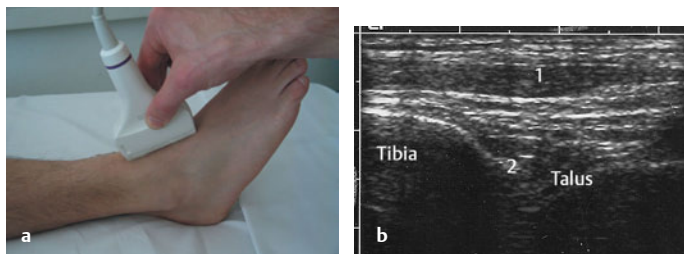


Fig. 62a, b Sonography of the ankle joint: anterior longitudinal scan. **a** Scan plane, **b** normal findings. 1 = Extensor digitorum longus, 2 = ankle joint space

- Medial and lateral longitudinal scans.
- *Dynamic examination:* Flexion and extension of the talocrural joint.
- ▶ **Achilles tendon:** Longitudinal scan over the Achilles tendon (Fig. 63).

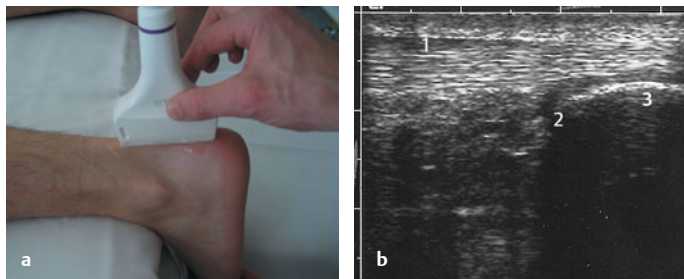


Fig. 63a, b Sonography of the Achilles tendon. **a** Scan plane, **b** normal findings. 1 = Achilles tendon, 2 = connective tissue or Karger's triangle, 3 = calcaneus

**Normal and Abnormal Distance Values in Arthrosonography****Table 7 · Normal and abnormal distance values in arthrosonography**

Joint	Scan plane	Measurement	Mean value (mm)	Abnormal (mm)
Shoulder	Axillary recess, longitudinal	Distance from bone to joint capsule	2.2	> 3.5
Rotator cuff (supraspinatus muscle)	Lateral transverse, 60° internal rotation	Sagittal diameter	4.6	< 3.0
Elbow	Anterior longitudinal	Distance from bone to joint capsule	1.8	> 3.0
Wrist	Posterior (dorsal) longitudinal	Distance from bone to joint capsule	1.5	> 3.0
Metacarpophalangeal joint	Volar longitudinal	Distance from bone to joint capsule	0.9	> 2.0
Hip	Anterior longitudinal	Distance from bone to joint capsule	5.2	> 8.0
Knee	Anterior longitudinal midline	Maximum clearance in suprapatellar pouch	2.4	> 5.0
Ankle joint	Anterior longitudinal	Distance from bone to joint capsule	1.7	> 3.0
Achilles tendon	Posterior longitudinal	Sagittal diameter 2 cm proximal to calcaneus	4.3	> 6.0
Metatarsophalangeal joint	Anterior longitudinal	Distance from bone to joint capsule	1.6	> 3.0

Note: The numerical data are intended as reference values and may vary as a function of various parameters. Besides noting the absolute value, the examiner should directly compare the findings with the opposite side in order to make an accurate interpretation. A difference between the sides > 1 mm is suggestive of capsular thickening, and a difference > 2 mm is a definite sign of capsular thickening (e.g., due to effusion or synovial proliferation).

## 3 Documentation and Reporting

- ▶ The written ultrasound report should be concise and should cover all relevant findings (normal and abnormal).
- ▶ The report may be freely dictated, or the findings may be entered on standard preprinted forms.
- ▶ Computer-based systems are increasingly used in ultrasound reporting as they are faster, more precise, and more objective than traditional methods. Computer records also make it easier to compare sonographic findings, and provide an efficient database for quality control.
- ▶ Written reports should always be supplemented by image documentation and archiving.

### 3.1 Requirements for Documentation

- ▶ **Written documentation:**
  - Patient identification
  - Place and date of the examination
  - Clinical problem that prompted the examination; presumptive diagnosis
  - Description of the sonographic findings
  - Final sonographic diagnosis and its relevance to the clinical problem
  - Signature of the examining physician
- ▶ **Image documentation:**
  - Patient identification
  - Place and date of the examination
  - Documentation of the scan direction (pictogram)
  - Acceptable image quality
  - Abnormal findings documented in two planes

### 3.2 Guideline-Oriented Documentation

- ▶ Documentation should follow guidelines such as those of the German Society for Ultrasound in Medicine.
- ▶ The image documentation for each organ should include as many scans as needed to display essential organ structures and should include information on significant environmental factors.
- ▶ The documentation should include representative images for the following regions:
  - *Pancreas*: 3 scans (head of pancreas with uncinate process, body of pancreas with pancreatic duct, tail of pancreas)
  - *Liver*: 4 scans (termination of hepatic veins, portal vein, right and left hepatic lobes)
  - *Gallbladder and bile ducts*: 3 scans (gallbladder longitudinal and transverse, bile duct longitudinal)
  - *Spleen*: 1 scan
  - *Kidneys*: 2 scans each (longitudinal and transverse)
  - *Retroperitoneum*: 4 scans (aorta, may include major branches; vena cava, may include tributaries; iliac vessels on both sides)
  - *Thyroid gland*: 4 scans (both lobes longitudinal and transverse)

- *Intra-abdominal lymph nodes*: 5 scans (celiac, superior and inferior mesenteric groups, parietal retroperitoneal, and portal)
- *Gastrointestinal tract*: Document according to findings. A complete workup should be documented by 9 scans:
  - *Stomach*: Fornix, body, antrum
  - *Colon*: Ileocecal; ascending, transverse and descending colon; sigmoid colon; rectum
- *Genital organs*: 2 scans each (uterus + adnexa or prostate + seminal vesicle; testicular scans may be added if required)
- *Urinary tract*: 6 scans (renal pelvis and ureteropelvic junction on both sides, site where the ureter crosses over the iliac vessels on both sides, bladder transverse with prevesical ureter, bladder longitudinal)
- *Adrenal glands*: 2 scans.

### 3.3 Sonographic Nomenclature

■ **Note**: When reporting sonographic findings, use proper nomenclature and try to avoid using terms drawn from radiology.

▶ The report consists of an accurate description of findings and the diagnosis. Structures not adequately visualized are described as such in the report.

▶ **Criteria for evaluating findings**: It is important to evaluate the location, size, shape, margins, relations, internal echo pattern, consistency, and dynamics (of moving structures). Tenderness to pressure, compressibility, and movement with respiratory excursions should also be assessed.

▶ **Examples of terms used in ultrasound reporting (listed alphabetically)**:

- Acoustic enhancement
- Acoustic shadow (Fig. 64b)
- Coarse (coarse granularity)
- Defect
- Density
- Distribution
- *Echogenicity* (Fig. 64):  
Hypochoic, anechoic, echogenic, isoechoic, hyperechoic; internal echoes
- Heterogeneous
- Homogeneous
- Intensity
- Internal echo pattern
- Irregular
- Lesion
- Loose (rarefied) echo texture
- Margins
- Nonhomogeneous
- Nonuniform
- Normal-appearing
- Regular
- Sharp
- Spacing
- Structure (structural defect)
- Uniform

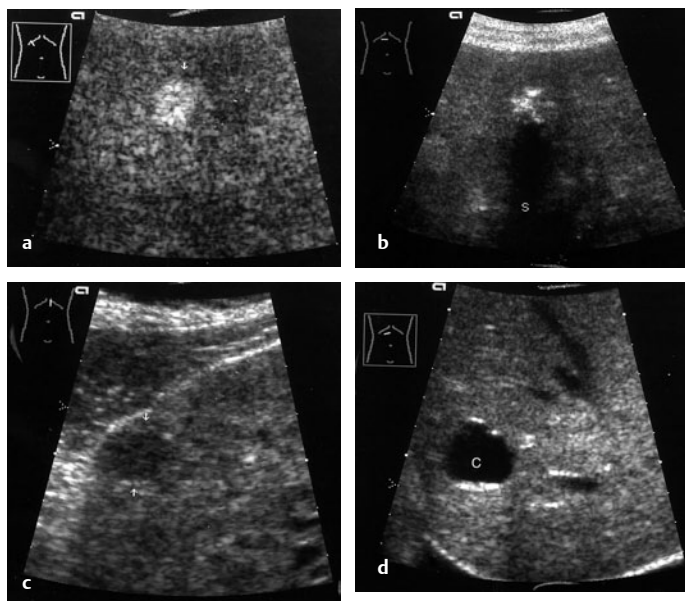


Fig. 64a–d Examples of various internal echo patterns. **a** Echogenic pattern (arrow). **b** Hyperechoic (very echogenic) pattern with an acoustic shadow (S). **c** Hypoechoic pattern (arrows). **d** Anechoic pattern (C)

► Individual echo characteristics and echo patterns

**Table 8** · Individual echoes and echo patterns

Individual echoes	Echo pattern
<i>Intensity</i>	
Intense (high-level echoes in a dense arrangement)	Echogenic, hyperechoic (Fig. 64a)
Scant (low-level echoes spaced far apart)	Hypoechoic (Fig. 64c)
None (devoid of echoes)	Anechoic (Fig. 64b)
<i>Distribution</i>	
Uniform	Homogeneous
Nonuniform	Nonhomogeneous

## 4 Function Studies

### 4.1 Basic Principles

- ▶ As well as static examinations that yield morphologic findings, functional ultrasound studies can also be done. Since they involve the assessment of dynamic phenomena, these tests significantly expand our diagnostic capabilities by supplying information on organ functions.
- ▶ The following tests have proved useful in routine situations:
  - Measurement of gallbladder contractions
  - Measurement of gastric emptying (p. 50)
  - Residual urine determination (p. 51)
  - Diuresis urography (p. 52).

### 4.2 Sonographic Measurements

#### Gallbladder Contractions

##### ▶ Indications:

- Suspected cystic duct obstruction
- Prior to litholysis
- Prior to lithotripsy

##### ▶ Measurement:

- *With a planimetry unit:* Measure the maximum longitudinal area by scanning points around the gallbladder circumference (Figs. 65 and 66).

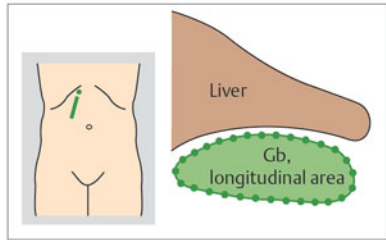


Fig. 65 Gallbladder planimetry for determining maximum longitudinal area

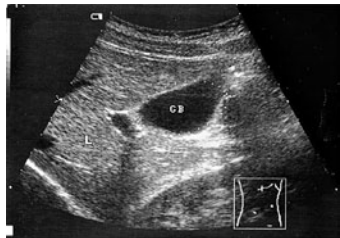


Fig. 66 Sonographic gallbladder planimetry for determining maximum longitudinal area.

L = liver, GB = gallbladder

## 4.2 Sonographic Measurements

- **Without a planimetry unit:** Measure the three greatest diameters in two planes and multiply them (length  $\times$  depth  $\times$  width) to calculate the gallbladder volume using the formula for an ellipsoid (sonographic residual urine determination; see Fig. 69).
- ▶ **Test meal:** A large, fatty, nonstandardized breakfast or a standardized beverage (e.g., 350 mL of cocoa).
- ▶ **Procedure:**
  - The gallbladder is measured in the fasted patient (see above).
  - The patient consumes a fatty breakfast (e.g., rolls with butter and cheese, 1 egg, and 1 cup of hot chocolate).
  - The measurements are repeated at intervals of approximately 10 min.
- ▶ **Findings:**
  - More than a 50% decrease in gallbladder volume indicates a significant contraction. Gallbladder contractions are maximal at 30–45 min.
  - Contractions are absent or deficient in patients with cholecystitis, cystic duct obstruction, hepatic cirrhosis, diabetes mellitus, pregnancy, or celiac disease.

## Gastric Emptying

- ▶ **Indications:** Detection of impaired gastric motility, which may occur in diabetic neuropathy, nondiabetic neuropathy, and systemic diseases.
- ▶ **Measurement:** Cross-sectional area of the antrum in the aortomesenteric plane (Figs. 67 and 68).

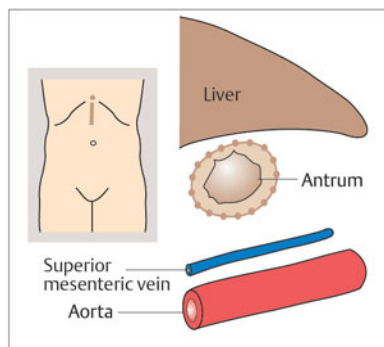


Fig. 67 Antral planimetry in the aortomesenteric plane

- ▶ **Test meal:** Tea
- ▶ **Procedure:**
  - The fasted patient is examined in the morning in the sitting or standing position.
  - Antral planimetry is carried out in the aortomesenteric plane.
  - The patient drinks 300 mL of unsweetened tea with a straw.
  - Antral planimetry is repeated at 5 min intervals.
- ▶ **Findings:** Determine the time required for the maximum antral area measured after ingestion of tea to return to the initial area measured before ingestion of tea:
  - **Normal value:** 25 min.
  - A value of 40 min or more signifies impaired gastric emptying.

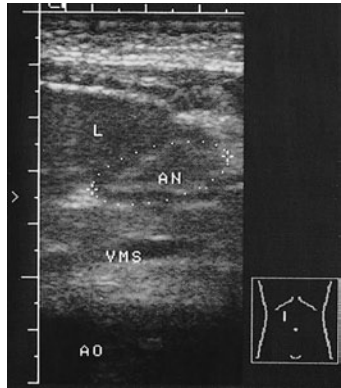


Fig. 68 Sonographic antral planimetry. VMS = superior mesenteric vein, L = liver, AO = aorta, AN = antrum

### Residual Urine Determination

- ▶ **Indications:** Determination of residual urine.
- ▶ **Measurement:** Calculate bladder volume using the formula for an ellipsoid (see below).
- ▶ **Procedure:**
  - Have the patient empty the bladder completely.
  - Measure the residual urine volume sonographically using the formula (Fig. 69):  
 $\text{volume (mL)} = \text{width (cm)} \times \text{depth (cm)} \times \text{length (cm)} \times 0.5$ .

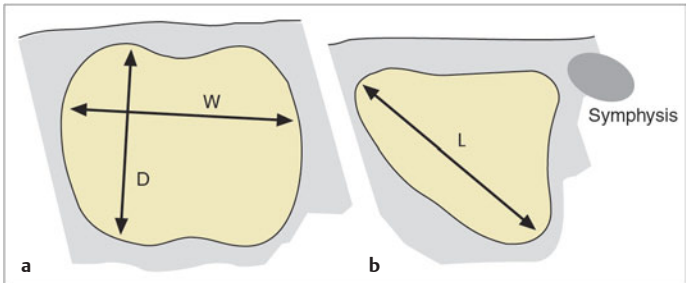


Fig. 69a, b **a** Measurement in transverse section. W = width, D = depth.  
**b** Measurement in sagittal section. L = length

- ▶ **Findings:**
  - A residual urine volume < 50 mL is still within the normal range.
  - Bear in mind that the residual urine values calculated for small volumes are too large, and that those calculated for large volumes are too small.

### Diuresis Urography

- ▶ **Indications:** Detection of subpelvic stenosis.
- ▶ **Measurement:** Transverse diameter of the anechoic separation of the renal sinus echo complex (Fig. 70).
- ▶ **Test substance:** Furosemide
- ▶ **Procedure:**
  - Measure the transverse diameter of the central echo complex at the widest point (Fig. 71).
  - Administer 20 mg of furosemide by i.v. bolus.
  - Repeat the measurement at 5 min and 15 min.
- ▶ **Findings:**
  - In a normal examination, the separation of the central echo complex measured at 15 min is less than the separation measured at 5 min.
  - If the separation increases or shows no change, an obstructive subpelvic stenosis should be suspected.

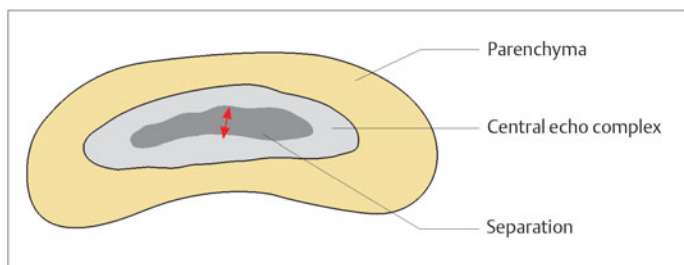


Fig. 70 Measurement of the separation of the renal sinus echo complex

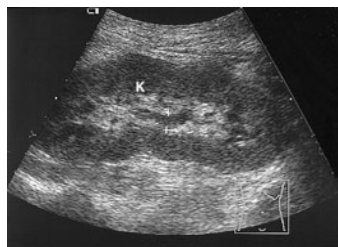

Fig. 71 Sonographic measurement.  
++ = separation of central echo complex,  
K = kidney

## 5 Interventional Ultrasound


### 5.1 Fine-Needle Aspiration Biopsy (FNAB)

#### Preparations and Technique

- ▶ **Setup** (Fig. 72): The supplies include sterile drapes and gloves.
- ▶ **Prerequisites:**
  - *Adequate coagulation:* Quick PT > 70%, platelets > 100 000/mm<sup>3</sup>. Factor analysis (e.g., factor XIII) may be indicated in patients with a hematologic systemic disease.
  - Secure informed consent.
  - Confirm a safe puncture route.

Fig. 72 Materials for fine-needle aspiration biopsy:

- 1 Syringe, needle, razor, local anesthesia.
- 2 Syringe with citrate.
- 3 Angiomed core needles. Otto needles 0.8 mm, 0.95 mm, 1.2 mm, or
- 4 glass slides with a formalin-filled Eppendorf tube



- ▶ **Technique with a FNAB transducer** (Fig. 73):
  - To maintain asepsis, the transducer must be sterilized (e.g., by placing it in disinfectant solution), and it may be necessary to line the guide channel of the biopsy transducer with sterile film. An antiseptic spray can be used as the ultrasound coupling medium.
  - Visualize the target lesion (Figs. 74a, 75a).
  - Mark the puncture route (Figs. 74b, 75b).
  - Measure the depth of needle insertion (Figs. 74b, 75b).
  - Anesthetize the puncture site.
  - Swiftly advance the biopsy needle along the designated path under sonographic guidance.
  - Remove the inner stylet, and visually check the position of the needle tip echo at the target site (Figs. 74b, 75c).
  - Apply gentle suction and rotate the core needle to sample material for cytohistologic analysis.

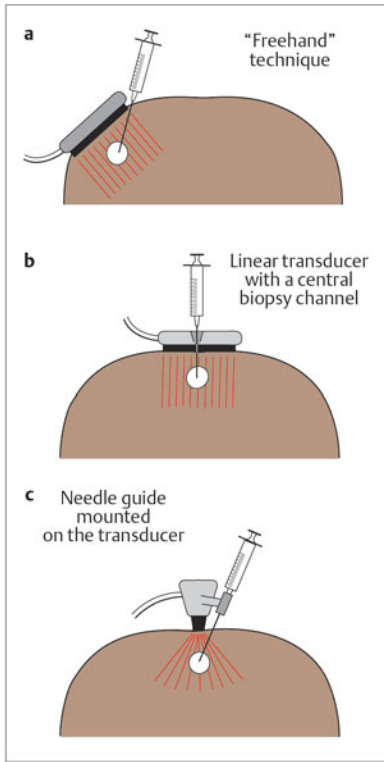


Fig. 73a–c Ultrasound-guided percutaneous FNAB

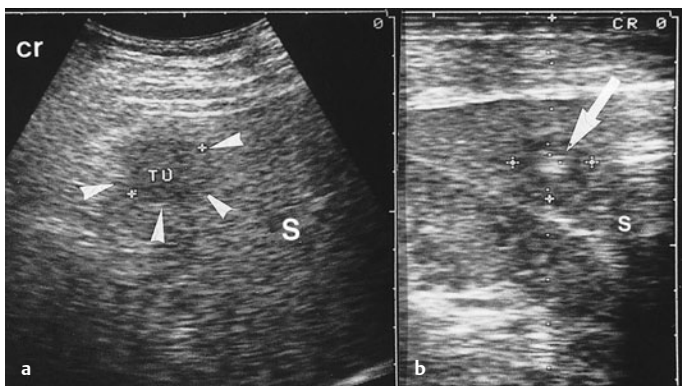


Fig. 74a, b Fine-needle aspiration biopsy. **a** Rounded, hypoechoic intrasplenic mass (TU). **b** The lesion is visualized, here using a linear transducer with a central biopsy channel. The needle path is marked on the screen. The insertion depth is measured (arrow), and the position of the tip echo at the target site (arrow) is checked. S = spleen

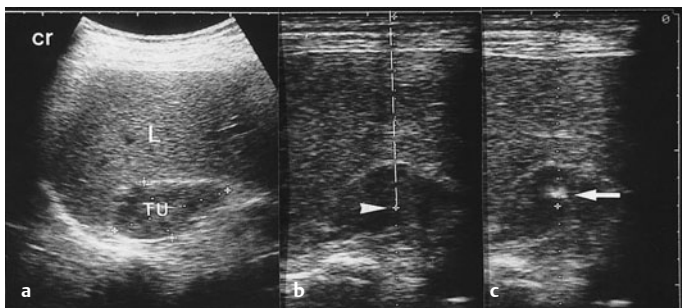


Fig. 75a–c FNAB. **a** Elliptical, hypoechoic mass (TU) in the region of the right adrenal gland. L = liver. **b** The mass is visualized, the needle path is marked, and the depth is measured (arrowhead). **c** The position of the tip echo at the target site (arrow) is checked

► **Preparation of the sample:**

- Expel the material (mixed with citrate) onto a glass slide.
- Transfer larger tissue particles into a formalin-filled Eppendorf tube.
- Spread out and air-dry the cytologic sample.
- Liquid samples should undergo cytologic and bacteriologic analysis (Fig. 76).

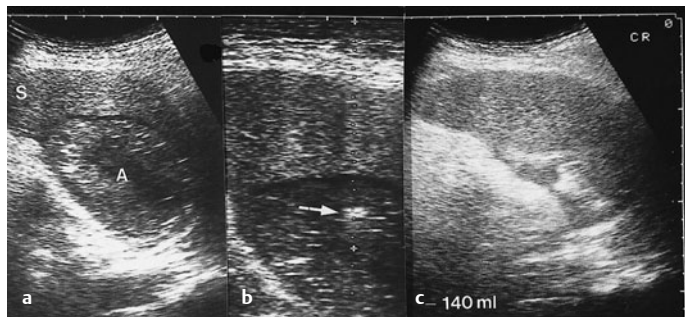


Fig. 76a–c Therapeutic fine-needle aspiration and drainage. **a** Rounded, sharply circumscribed intrasplenic mass with a nonhomogeneous internal echo pattern. **b** Diagnostic fine-needle aspiration yielded abscess material. Arrow: needle tip echo. **c** The abscess material (140 mL) was therapeutically evacuated at the same sitting. S = spleen, A = abscess

### Indications and Guidelines for Specific Organs

► **Liver:**

- *Indications:* Investigation of diffuse and focal abnormalities.
- **Note:** With superficial lesions, make sure the lesion is biopsied through normal liver tissue.

► **Spleen:**

- *Indications:* Abscess, primary focal lesions (Figs. 74, 76).
- **Note:** The spleen is a very vascular organ, and strict criteria should be applied in patient selection.

► **Pancreas:**

- *Indication:* Carcinoma
- **Note:** It is unnecessary to establish a preoperative histologic diagnosis for indeterminate pancreatic masses that are localized and operable.
- FNAB of a pancreatic mass is unnecessary if diagnostic imaging indicates a malignant tumor and operative treatment is planned.

► **Adrenal gland:**

- *Indication:* Indeterminate mass lesion (Fig. 75).
- **Caution:** Before puncturing an adrenal mass, first exclude pheochromocytoma clinically and by laboratory tests.

► **Lymph nodes:**

- *Indications:* Malignant lymphoma, metastasis, reactive lymphadenopathy.
- *Limitations:* FNAB is inadequate in most cases for the evaluation of a suspected malignant lymphoma; surgical lymphadenectomy is usually required.

▶ **Kidney:**

- *Indications:* Suspected tumor, parenchymal disease.

🚩 **Caution:** If hypernephroma is suspected, a preoperative needle biopsy is not advised because of the risk of bleeding and inoculation metastasis.

▶ **Thyroid gland:**

- *Indications:* Cold nodule, cyst

📌 **Note:** Often there is no need for local anesthesia.

▶ **Accumulations of fluid:**

- *Indications:* Pleural effusion, pericardial effusion, ascites, cyst, pseudocyst, hematoma, abscess.

📌 **Note:** Percutaneous aspiration may be diagnostic or therapeutic.

- In the therapeutic aspiration of a pleural effusion, no more than 1.5 L should be evacuated in one sitting. If the effusion is under negative pressure, aspirating even a small volume may cause a significant shift of the mediastinum (common with malignant effusions), and the procedure should therefore be terminated if the patient manifests chest pressure or a dry cough.

▶ **Other indications:** Lesions of the retroperitoneum, chest wall, subpleural lung, mediastinum, bone, gastrointestinal tract, soft tissues, etc.

### Contraindications

---

▶ Refusal of informed consent or lack of patient cooperation

▶ Severe coagulation disorder

▶ Noninvasive diagnostic alternatives

▶ Lack of therapeutic implications

🚩 **Caution:** Be careful when dealing with very vascular superficial lesions.

### Interpretation

---

▶ **General:**

- *Focal lesions* (> 2 cm in diameter) in parenchymal organs (e.g., liver, pancreas, retroperitoneum, adrenal gland) are diagnosed with approximately 90% sensitivity and 100% specificity.

- *Complications* (excessive pain, peritoneal irritation, bleeding, infection, inoculation metastasis, bile leak, pneumothorax, death) are extremely rare when the puncture route is carefully selected and contraindications are noted.

▶ **Specific risks:**

- *Liver:* With superficial lesions, a hemangioma should be excluded with very high confidence because of the risk of bleeding.
- *Pancreas:* Confirm a safe puncture route because of the risk of bowel injury.
- *Kidney:* Apply rigorous patient selection criteria.
- *Pleura:* When draining an effusion, discontinue at once if the patient complains of chest pressure or tightness or develops a dry cough, because of the risk of mediastinal displacement.

## 5.2 Therapeutic Aspiration and Drainage

### Preparations and Technique

- ▶ **Prerequisites:** Quick PT > 70%, platelets > 100 000/mm<sup>3</sup>. Factor analysis (e.g., factor XIII) may be indicated in patients with a hematologic systemic disease. Obtain informed consent.
- ▶ **Setup (Fig. 77):**
  - Skin prep, sterile drapes, local anesthesia, razor, scalpel blade
  - **Drainage materials:** Small-gauge catheters (F 8) are often adequate for cyst aspiration. Abscess drainage requires a larger (double-lumen) suction-irrigation catheter (F 14).
  - Suture material (plus scissors and needle holder)
  - Dressing materials

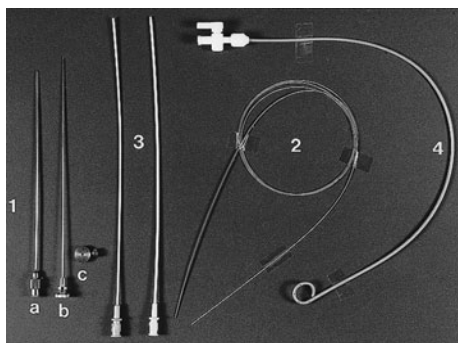


Fig. 77 Materials for Seldinger drainage. **1a–c** Puncture needle (a), stylet (b), and depth-setting lock screw (c). **2** Guidewire, **3** dilators, **4** pigtail catheter, F 8 (e.g., for cyst drainage)

- ▶ **Procedure for percutaneous drainage (Seldinger technique):**
  - Define the target lesion and puncture route, and measure as for a diagnostic aspiration (Figs 78, 79a). Make a stab incision with a scalpel blade.
  - Insert the needle, remove the stylet, and check the position of the needle tip echo (may be necessary to aspirate and instill saline solution). Introduce the guidewire and remove the puncture needle. Dilate the tract with graded dilators.

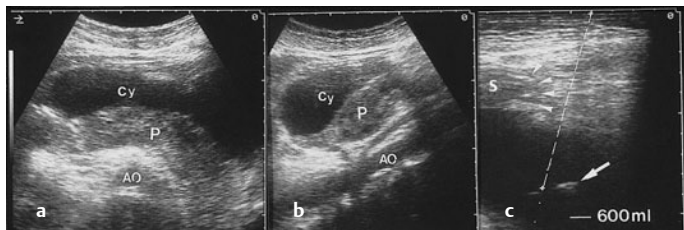


Fig. 78a–c Diagnostic and therapeutic aspiration. **a** B-mode image shows an anechoic pancreatic pseudocyst anterior to the pancreas (P). AO = aorta. **b** Longitudinal scan of the pseudocyst (Cy). **c** The angle of the puncture is carefully planned to bypass the stomach (arrow heads). Large arrow: needle tip echo

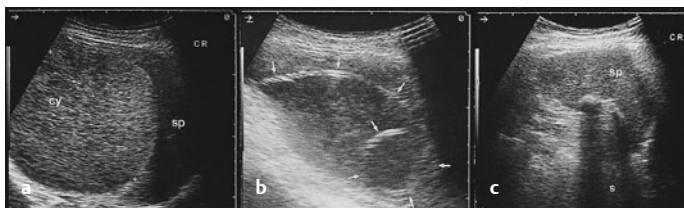

Fig. 79a–c Therapeutic catheter drainage. **a** Large, rounded, sharply circumscribed, intrasplenic cystic mass with fluctuating internal echoes on real-time examination. **b** The liquid mass was drained externally using Seldinger technique. The arrows indicate the catheter in place. **c** Follow-up scan several months after catheter drainage shows complete resolution of the cystic lesion, leaving a calcified scar. SP = spleen, CY = cystic lesion, S = acoustic shadow

tors, and introduce the drainage catheter (Fig. 79b). Remove the guidewire and check catheter position (may be done radiographically). Secure the catheter with sutures and apply a dressing.

### Indications and Guidelines for Specific Lesions

#### ► Pseudocysts (e.g., of the pancreas):

- *Therapeutic procedure:* See Fig. 80).
- *Technique:* See Figs. 78 and 81.

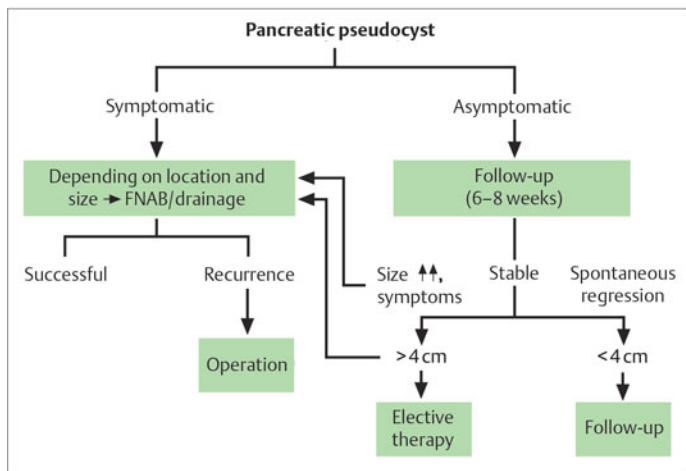


Fig. 80a–c Algorithm for the management of pancreatic pseudocysts (after Schwerk)

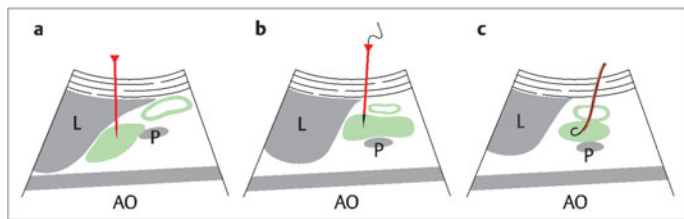


Fig. 81a–c Ultrasound-guided percutaneous external drainage of pancreatic pseudocysts (after Schwerk). **a** Transhepatic (or transgastric) fine-needle aspiration. AO = aorta, L = liver, P = pancreas. **b** External catheter drainage using Seldinger technique. The guidewire is advanced into the pseudocyst under sonographic guidance, avoiding the perforation of internal organs. **c** Transgastric external catheter drainage

- ▶ **Abscesses** (of the liver or spleen, intra- or retroperitoneal, subphrenic):
  - The treatment of choice is repeated percutaneous drainage (Fig. 76) or therapeutic catheter drainage (Fig. 79).
  - ▶ **Note:** Irrigate the abscess cavity with saline solution. Drains should be flushed once or twice daily to prevent clogging.
- ▶ **Primary symptomatic cysts:**
  - By definition, these lesions are lined with potentially secretory epithelium.
  - If the contents reaccumulate after percutaneous drainage, the cyst should be surgically extirpated or evacuated by catheter drainage followed by the injection of pure alcohol (99.5%). Catheter placement should be checked radiographically.
  - Percutaneous drainage may be combined with sclerotherapy for cysts of the liver, spleen, kidney, etc.
- ▶ **Empyema:** Intrathoracic, gallbladder, ascites, pleural effusion, pericardial effusion.

### Contraindications

- ▶ Refusal of informed consent or lack of patient cooperation
- ▶ Coagulation disorder
- ▶ Unsafe drainage route

### Specific Types of Therapeutic Drainage

- ▶ **Alcohol instillation:**
  - *Indications:* Malignant tumors (e.g., malignant primary or secondary hepatic tumors), thyroid adenoma.
  - *Prerequisites:* Good visualization, solitary lesion, tumor < 5 cm.
- ▶ **Suprapubic bladder catheter:**
  - *Indication:* Incontinence that necessitates long-term urinary diversion. Possible causes include outflow obstruction due to inoperable prostatic carcinoma.
  - In principle, suprapubic aspiration of a full bladder can be carried out after clinical palpation and percussion. Ultrasound-guided aspiration is recommended only when the bladder volume is small.
- ▶ **Percutaneous nephrostomy:**
  - *Indication:* Ultrasound-guided puncture aided by fluoroscopy is appropriate for renal pelvic dilatation that is clearly demonstrated by sonography.

- **Technique:** Using the Seldinger technique, a needle is passed into the dilated calyx under continuous sonographic guidance from a posterolateral approach, avoiding the vascularized renal medulla. The tract is dilated, and a pigtail catheter (F 5–8) is introduced.

### Interpretation

---

#### ▶ **Pancreatic pseudocysts:**

- **Success rate:** 60–90% depending on the location, size, and consistency of the pseudocyst (see Figs 78 and 81).
- **Complications:** Bleeding, septicemia, organ injuries in 5–10% of cases. The complication rate can be lowered by finding a safe drainage route that avoids parenchymatous organs, gastrointestinal structures (Fig. 78c), and the costophrenic angle.

#### ▶ **Abscesses:**

- **Success rate:** 80–95%
- **Complications:** With a safe access route and proper instrumentation, the complication rate is approximately 10% (sepsis, bleeding, pleural empyema, fistula formation).

#### ▶ **Primary symptomatic cysts:**

- **Success rate:** > 95%
- **Complication rate:** < 5% (infection, bleeding)

#### ▶ **Empyema:**

- **Success rate:** 72–88% with early diagnosis of pleural empyema
- **Complication rate:** Low (bleeding from intercostal vessels)

#### ▶ **Nephrostomy:**

- **Success rate:** 95%
- **Complication rate:** 5% (bleeding, infection)

## 6 Principal Signs and Symptoms

### 6.1 Upper Abdominal Pain

#### Basic Principles

- ▶ **Principal signs and symptoms:** Pain, fever, vomiting, circulatory depression, hematologic changes, muscular guarding (rigidity), occasional retention of stool
- ▶ The **differential diagnosis** is reviewed in Table 9, where the possible diagnoses are listed in order of their frequency in the general hospital setting.

**Table 9 · Differential diagnosis of upper abdominal pain**

Diagnosis	Sonographic signs
<i>Common</i>	
Acute cholecystitis (p. 63)	Thickened, three-layered wall; possible gallbladder hydrops
Biliary colic (p. 64)	Stone echo, acoustic shadow, obstructed duct
<i>Less common</i>	
Acute pancreatitis (p. 65)	Pancreatic enlargement; hypoechoic, hazy internal echo pattern, circumscribed hypoechoic lesions
Impaired gastric emptying (p. 70)	Greatly distended, fluid-filled stomach with internal echoes
Myocardial infarction	Echocardiography: circumscribed abnormality of wall motion
Pulmonary embolism (p. 67)	Peripheral embolism: wedge-shaped hypoechoic area (thoracic sonography)
Renal colic (p. 65)	Obstructed, anechoic pyelocalyceal system; stone echo with twinkling artifact
Hernia (p. 77)	Hernia sac, gap in peritoneum, possible thickening of bowel wall
<i>Rare</i>	
Perforated gastric or duodenal ulcer (p. 68)	Detectable free air, possible wall thickening at the ulcer site
Perforated gallbladder (p. 69)	Wedge-shaped parenchymal lesion, absence of flow by CDS
Splenic infarction (p. 74)	Usually wedge-shaped, hypoechoic parenchymal lesion
Renal vein thrombosis (p. 74)	Kidneys initially enlarged, then small; dilated veins
Subphrenic abscess (p. 71)	Nonhomogeneous mass with ill-defined margins located between the diaphragm and the liver or spleen

**Table 9 · Differential diagnosis of upper abdominal pain – continued**

Diagnosis	Sonographic signs
Cholangitis (p. 304, 331)	Hypoechoic wall thickness, hypoechoic intraductal mass
Intraorgan bleeding (p. 72)	Hypoechoic mass, usually with associated organ enlargement

**Conditions that cannot be diagnosed with ultrasound**

*Common:* Gastroenteritis, pleurisy

*Less common:* Diabetic coma with pseudoperitonitis, uremia, thyrotoxicosis, Meckel diverticulum, Boerhave syndrome

*Rare:* Hemolytic crisis, hepatic porphyria (e.g., acute intermittent porphyria), Addisonian crisis, intoxication (lead, arsenic, mushroom, thallium), type I hypertriglyceridemia

**Acute Cholecystitis (Figs. 82 and 83)**

- ▶ See also Gallbladder, p. 334.
- ▶ **Clinical manifestations:** Right upper abdominal pain radiating to the right shoulder, fever, possible jaundice (if the edematous inflammatory changes involve the biliary tract). Anorexia; nausea; enlarged, tense, painful gallbladder that may be palpable (Murphy's sign). Localized rigidity, meteorism, or diminished bowel sounds due to paralytic ileus may be noted.
- ▶ **Diagnosis:**
  - History and physical examination
  - *Laboratory findings:* Leukocytosis,  $\gamma$ -glutamate transferase (GGT) and alkaline phosphatase (AP)  $\uparrow$ , possible elevation of direct serum bilirubin, C-reactive protein (CRP)  $\uparrow$
  - Sonography
  - *Radiography:* Plain abdominal radiograph for suspected emphysematous cholecystitis
  - Biliary scintigraphy if the gallbladder cannot be visualized.
- ▶ **Sonographic findings:**
  - Tenderness to probe pressure over the gallbladder
  - Gallbladder wall is thickened, and three distinct layers are visible as a result of edema
  - Borders may be poorly demarcated from surroundings as a result of pericholecystitis
  - Gallbladder hydrops may occur with a painful, enlarged, incompressible gallbladder

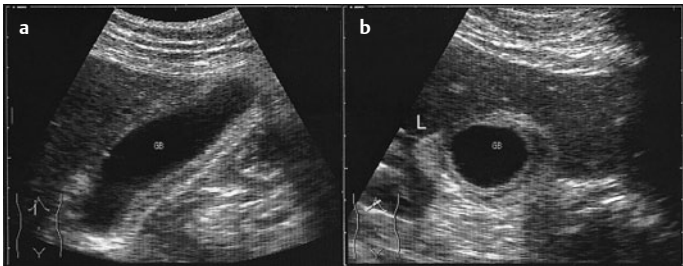


Fig. 82a, b Acute cholecystitis. The edematous wall of the gallbladder (GB) appears thickened and shows a distinct layered structure. L = liver

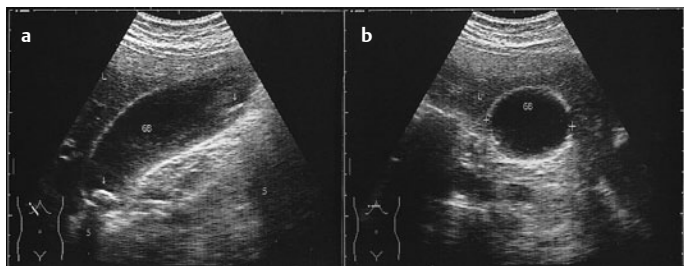


Fig. 83a, b Gallbladder hydrops in acute cholecystitis. The gallbladder (GB) is enlarged, tender to pressure, and is incompressible with the ultrasound probe. Arrows: shadowing stones (S). L = liver

- Calculi can be detected in up to 95% of cases.
- ▶ **Accuracy of sonographic diagnosis:** Very high, especially when combined with the clinical presentation and history, laboratory findings, and sonographic follow-ups. There is no need for additional imaging studies.

### Biliary Colic (Fig. 84)

- ▶ **Clinical manifestations:** Episodes of severe, colicky pain due to gallbladder contractions. The cause is a stone obstructing the bile ducts and raising the pressure within the gallbladder. The pain often occurs after meals and lasts for 1–4 hours (residual complaints may persist for 24 hours). Vomiting is common, and jaundice may occur with duct occlusion. Fever signifies a complication.
- ▶ **Diagnosis:**
  - *History:* Many patients have a prior history of gallstones.
  - Laboratory tests may show signs of cholestasis with elevated bilirubin, GGT, and AP.
  - Sonography.
- ▶ **Sonographic findings:**
  - *Stone:* Hyperechoic with an associated acoustic shadow.
  - Often difficult to define a stone within the bile duct.
  - Acoustic shadow may indicate the presence of a stone.
  - With an obstructed duct, look for a stone:
    - Common duct stone leads to ductal dilatation
    - Infundibular or cystic duct stone leads to gallbladder hydrops (marked gallbladder enlargement and tenderness).
    - Prepapillary stones may obstruct the pancreatic duct and incite pancreatitis.

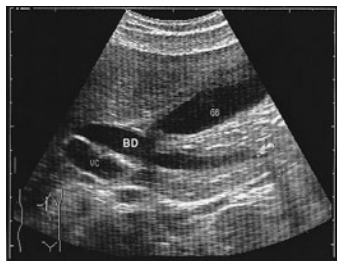

Fig. 84 Duct stone. The bile duct (BD) is obstructed. An acoustic shadow (S) indicates the presence of the intraductal stone (cursors). GB = gallbladder, VC = vena cava

- ▶ **Accuracy of sonographic diagnosis:** The cause of biliary colic can be diagnosed sonographically with > 90% accuracy. With atypical findings (small gallbladder), the diagnostic accuracy falls to 65%. Additional imaging modalities are necessary only in exceptional cases (e.g., radiographs for distinguishing a porcelain gallbladder from gallstones).

### Renal Colic (Figs. 85 and 86)

- ▶ **Clinical manifestations:** Unilateral pain that comes in characteristic waves, often radiating to the groin. Nausea and vomiting. Reflex ileus may occur. Hematuria
- ▶ **Diagnosis:** Sonography and urinalysis; may be supplemented by urography
- ▶ **Sonographic findings:**
  - Obstructed, anechoic pyelocalyceal system.
  - The proximal ureter may be dilated, depending on the site of the outflow obstruction (stone, tumor, lymphadenopathy).
  - The twinkling artifact (see p. 283, 382) is helpful in detecting intraluminal stones and differentiating them from bowel gas.
- ▶ **Accuracy of sonographic diagnosis:** The obstruction can be detected sonographically in up to 100% of cases, and the obstructing lesion can be identified in approximately 85% of cases. Additional imaging studies may be ordered as adjuncts.

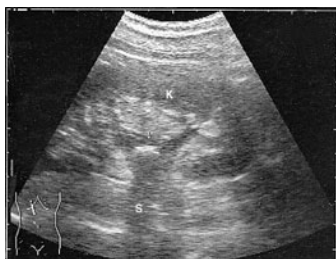

Fig. 85 Renal pelvic stone. The renal pelvis is hypoechoic and dilated. A stone with a high-amplitude echo (arrow) and posterior acoustic shadow (S) is visible at the ureteropelvic junction. K = kidney

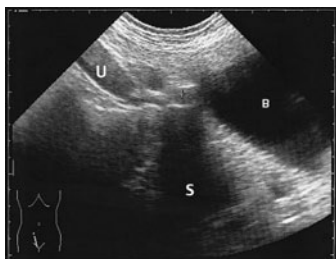


Fig. 86 Ureteral stone. The ureter (U) is occluded by a prevesical stone (arrow). An acoustic shadow (S) indicates the presence of the stone. B = bladder

### Acute Pancreatitis (Figs. 87–89)

- ▶ See also Pancreas, p. 295.
- ▶ **Clinical manifestations:** Pain of variable intensity, most severe in the epigastrium and usually radiating to the back in a girdling pattern. The pain is exacerbated by lying down. Nausea, vomiting, meteorism, hypotension, tachycardia, fever.
- ▶ **Diagnosis:**
  - *History* (women often have a prior history of gallstones, men usually have a history of alcoholism); pain characteristics.
  - *Clinical examination:* Tenderness that is maximal in the epigastrium. Basal lung findings are common (rales, atelectasis, pleural effusion) and usually involve the left side.

- **Laboratory findings:** Leukocytosis, elevated amylase and lipase (serum levels do not correlate with disease severity), LDH ↑, hyperglycemia, hypocalcemia, hyperbilirubinemia (usually without jaundice), hypertriglyceridemia, hypoxemia, albumin deficiency.
- Abdominal sonography, pleural sonography
- **Radiography:** Plain abdominal radiograph, standing or in left lateral decubitus (to detect or exclude ileus and/or perforation).
- **Endoscopic retrograde cholangiopancreatography (ERCP):** For diagnosing ductal obstruction and relieving the obstruction by stone extraction (not indicated in alcohol-related pancreatitis).
- Contrast-enhanced sonography or pre- and postcontrast CT may also help to differentiate viable from nonviable tissue.

▶ **Sonographic findings:**

- The pancreas is frequently obscured by overlying gas, which may be due in part to gastric dilatation.
- The pancreas shows no sonographic changes during the first few hours. Later it becomes acutely hypoechoic and shows marked swelling or enlargement.

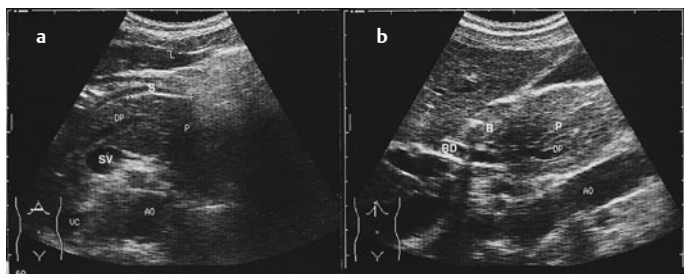


Fig. 87a, b Acute pancreatitis. The pancreas (P) is thickened and hypoechoic, and the pancreatic duct (DP) is dilated. **a** Upper abdominal transverse scan. The stomach (S) lies between the liver (L) and pancreas. Arrows: peripancreatic fat necrosis. **b** Upper abdominal longitudinal scan shows dilatation of the pancreatic duct (DP) in the head of the pancreas (P) and of the bile duct (BD). SV = splenic vein, AO = aorta, VC = vena cava, B = Bowel

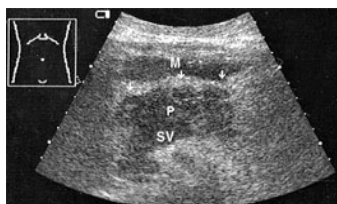


Fig. 88 Acute necrotizing pancreatitis. Between the posterior wall of the stomach and the nonhomogeneous pancreas (P) are a hypoechoic mass (M) and an echoic mass (arrows) signifying free fluid and necrosis. SV = splenic vein

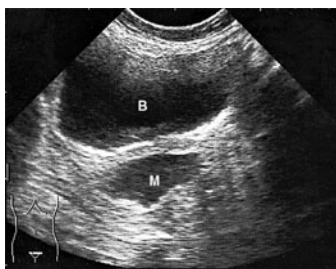


Fig. 89 Necrosis extending to the cul-de-sac in pancreatitis: hypoechoic to anechoic mass (M) located behind the bladder (B)

- The pancreatic duct cannot be visualized in edematous pancreatitis, or it may be accentuated or dilated by an obstructing stone.
  - Areas of necrosis often appear hypoechoic or anechoic with ill-defined margins.
  - Free fluid in the abdomen often appears as an anechoic rim surrounding the pancreas, liver, and particularly the splenic hilum.
  - Pseudocysts
  - Pleural effusion
  - *Etiologic signs:*
    - Gallstones in biliary pancreatitis
    - Fatty liver in alcoholic pancreatitis
- ▶ **Accuracy of sonographic diagnosis:** Presumably low in the early stage of the disease. Reportedly, CT scanning has an accuracy rate of 60–85%. Sonography is a particularly important modality for follow-up.

### Pulmonary Embolism (Fig. 90)

- ▶ See also Thorax, Pulmonary infarction, p. 410, 411.
- ▶ **Clinical manifestations:** Dyspnea, tachycardia, persistent mild cough, hemoptysis, chest pain, anxiety, feeling of oppression, shock
- ▶ **Cause:** Only one-fourth of all venous thromboses are symptomatic before a pulmonary embolism. Only one-third of pulmonary embolisms are diagnosed before death.
- ▶ **Diagnosis:**
- Blood gas analysis, D-dimers, echocardiography, ECG, spiral CT
  - Lower extremity venous sonography; thoracic sonography with color Doppler, may be supplemented with ultrasound contrast agents; abdominal sonography (other possible embolus sources include the prostatic plexus and uterovaginal plexus)
  - Chest radiographs
  - *Pulmonary scintigraphy:* May be combined with ventilation scintigraphy, pulmonary angiography, and local thrombolysis as needed.
- ▶ **Sonographic findings:**
- Ballooning of the right ventricle and right atrium due to right-heart overload. The left ventricle tends to be small, empty, and hyperactive.
  - Embolus is occasionally detectable in the pulmonary artery in patients with central embolism.
  - *Lower extremity venous sonography:* May demonstrate lower-extremity venous thrombosis with a dilated, somewhat echogenic (thrombus) and incompressible vein as the most frequent cause (see also p. 210).

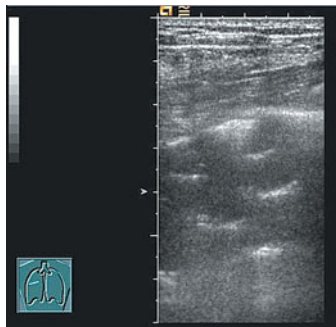


Fig. 90 Pulmonary embolism: extensive hypoechoic mass in the anterior apex of the right lung with postinfarction pneumonia and air inclusions

- **Thoracic sonography:** Peripheral, hypoechoic, wedge-shaped area in the lung with ventilatory impairment (if the infarct is at a site accessible to ultrasound).
- ▶ **Accuracy of sonographic diagnosis:** Sonographic findings support the diagnosis of pulmonary embolism. The diagnosis is established by spiral CT, scintigraphy, or pulmonary angiography.

### Perforated Ulcer (Figs. 91 and 92)

- ▶ **Clinical manifestations:** Acute-onset pain with muscular guarding, hematemesis, and a tarry stool.
- ▶ **Diagnosis:**
  - **History:** Known ulcer disease
  - **Sonography:** Free air; excludes other causes of pain
  - **Endoscopy:** Demonstrates the ulcer
  - **Radiography:**
    - **Abdominal radiograph:** Free air
    - **Chest radiograph:** Air crescent below the diaphragm leaflets
- ▶ **Sonographic findings:**
  - **Free air in the abdomen:**
    - Small amounts of air collect below the abdominal wall in the supine patient (appearing sonographically as a continuous echogenic band with an incomplete acoustic shadow).
    - When the upper body is slightly elevated, larger amounts of air collect below the diaphragm leaflets.

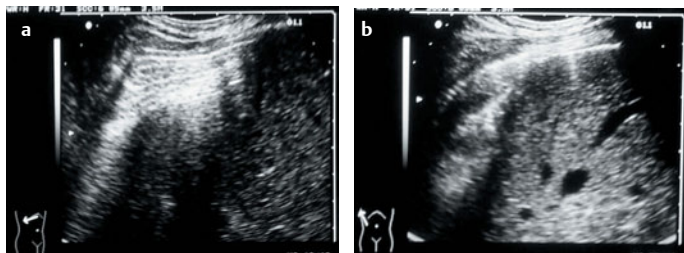


Fig. 91a, b Free air in the abdomen following a perforation. a Echogenic band over the liver. b Free air in left lateral decubitus

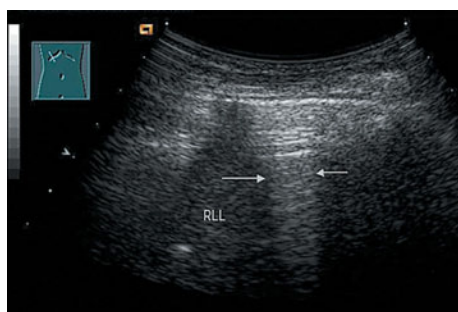


Fig. 92 Free air following a perforation: echogenic band over the liver, associated with an incomplete acoustic shadow. The air over the liver is seen even more clearly when the patient is scanned in left lateral decubitus. Arrows: Reverberations. RLL = right liver lobe

– In left lateral decubitus, air echoes appear superimposed over the echo pattern of the liver.

- Wall thickening can sometimes be detected at the ulcer site.

▶ **Accuracy of sonographic diagnosis:** As little as 1 mL of free air can be detected, and 10 mL cannot be missed. Sonography shows definite evidence for the presence of a perforation. The site of the perforation is demonstrated by endoscopy.

### Perforated Gallbladder (Figs. 93–95)

▶ **Clinical manifestations:** Severe pain followed abruptly by a more or less pain-free interval, followed in turn by a recurrence of pain and rigidity. The patient becomes seriously ill when peritonitis supervenes.

▶ **Diagnosis:**

- **History:** Lithiasis, inflammation, course of illness
- Sonography
- **Radiography:** Plain abdominal radiograph

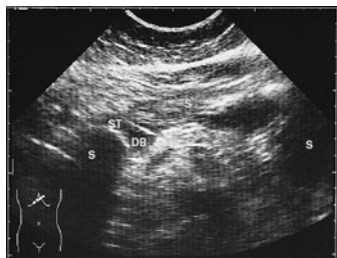

Fig. 93 Gallstone perforation. A gallstone (ST) with a bright surface echo and acoustic shadow (S) has perforated into the duodenal bulb (DB). S = stomach

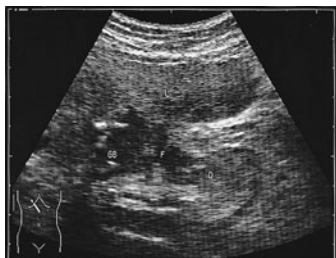

Fig. 94 Perforated gallbladder (same patient as in Fig. 93). The gallbladder (GB) has ill-defined margins with a non-homogeneous internal echo pattern and a fistulous tract (F) leading into the duodenum (D). L = liver

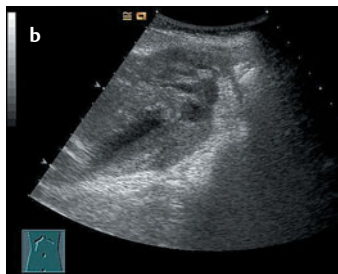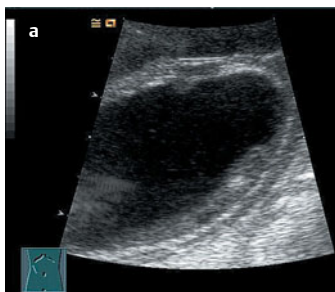


Fig. 95a, b Perforated gallbladder. **a** The gallbladder has a thickened wall and is still fluid-filled because the perforation is confined. The wall discontinuity is caused by detached mucosa. **b** Perforated gallbladder (same woman, 65 years of age). Scan shows a hypoechoic mass with ill-defined margins around the gallbladder due to suppurative pericholecystitis

- ▶ **Sonographic findings:**
  - *With cholecystitis:*
    - Gallbladder poorly demarcated from its surroundings
    - Irregular, anechoic rim
  - Discontinuity in the gallbladder wall
  - Thickening of the gallbladder wall
  - Small amounts of free fluid in the abdomen, particularly around the liver
- ▶ **Accuracy of sonographic diagnosis:** A perforated gallbladder may be indistinguishable from pericholecystitis by ultrasound. A discontinuity in the gallbladder wall suggests the correct diagnosis, which is confirmed by demonstrating a direct communication of the gallbladder lumen with the peritoneal cavity.

### Impaired Gastric Emptying (Fig. 96)

- ▶ **Clinical manifestations:** Vomiting, epigastric pressure, weight loss, impaired gastric emptying
- ▶ **Cause:** Narrowing of the gastric outlet due to recurrent ulcers, extrinsic compression (pancreatic tumor, cysts, etc.), a previous vagotomy, or diabetic autonomic neuropathy (gastroparesis)
- ▶ **Diagnosis:** History; sonography; gastric intubation; endoscopy to identify the cause. May be supplemented by an upper GI series if necessary.
- ▶ **Sonographic findings:**
  - Stomach maximally distended by fluid
  - Possible absence of peristalsis
  - Internal echo pattern may be anechoic to hyperechoic, depending on the consistency of the contents, causing the stomach to become more isoechoic to its surroundings; may be mistaken for an upper abdominal mass.
- ▶ **Accuracy of sonographic diagnosis:** Sonography shows a distended stomach prior to gastric intubation. Impaired gastric emptying can be positively established as the cause of an acute abdomen. When the stomach has been decompressed with an oro- or nasogastric tube, it appears empty on ultrasound.

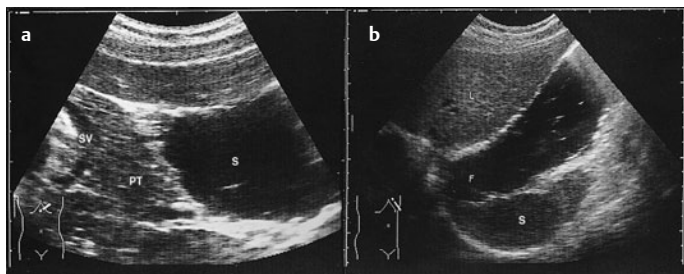


Fig. 96a, b Gastric atony. **a** Extended left intercostal scan shows the gastric fornix (S) distended by fluid (no internal echoes). SV = splenic vein, PT = pancreatic tail. **b** Subcostal oblique scan in left lateral decubitus shows the distended stomach (S) and fundus (F). The wall layers are no longer visible

## Dissecting Aortic Aneurysm (Fig. 97)

- ▶ **Clinical manifestations:** Severe pain of sudden onset, similar to that of renal colic (migrates as the dissection advances along the aorta). Dyspnea and syncope are also present. Neurologic deficits may occur, depending on the site of the dissection. Multiple episodes are common. Initially the dissection is confined to the intima, and the dissecting blood creates a false lumen. Later the aneurysm may rupture, causing death. Hemorrhagic shock may occur, depending on the extent of the dissection.
- ▶ **Occurrence:** Most common in elderly patients with significant atherosclerosis. Many patients have a prior history of hypertension.
- ▶ **Diagnosis:** It is essential not to overlook the diagnosis of a dissecting aortic aneurysm.
  - *History:* Laboratory tests with Hb monitoring
  - Sonography, particularly color duplex; transesophageal sonography is recommended for thoracic scanning
  - CT, MRI
- ▶ **Sonographic findings:**
  - Aortic dilatation > 25 mm; massive aortic enlargement not always present.
  - Echogenic plaques are usually seen as an expression of atheromatosis; they may be hard (with acoustic shadowing) or soft (no shadowing).
  - Echogenic band floating in the aortic lumen (intimal flap).
  - Double aortic lumen; the second lumen may be echogenic, indicating thrombotic occlusion.
  - *CDS:* Can differentiate the false lumen from the true lumen (by detecting different flow velocities).
- ▶ **Accuracy of sonographic diagnosis:** With adequate visualization, sonography can confirm the diagnosis in 98% of cases. A CT scan is often done preoperatively.

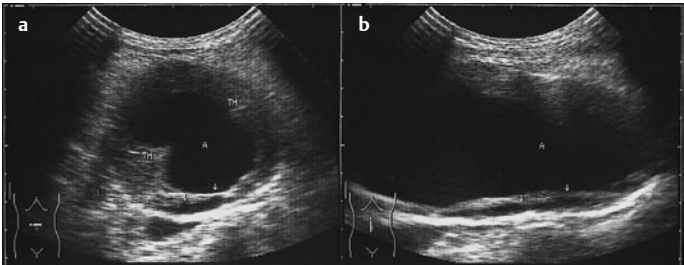


Fig. 97a, b Dissecting aneurysm of the abdominal aorta. The aorta (A) is markedly expanded, and partial thrombosis (TH) is seen at the periphery of its lumen. Arrows: echogenic intimal flap with anechoic false lumen

## Subphrenic Abscess (Fig. 98)

- ▶ **Clinical manifestations:** Unexplained fever, pain. The depth of respirations may be restricted, causing dyspnea.
- ▶ **Diagnosis:**
  - *Abdominal and chest radiographs:* Usually show elevation of the diaphragm; may demonstrate basal lung consolidation and pleural effusion in some cases.

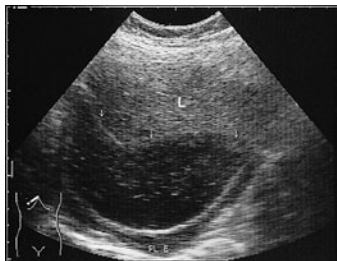


Fig. 98 Subphrenic abscess. Behind the liver (L) and below the diaphragm is a hypoechoic mass (arrows) with high-level internal echoes. Pleural effusion (PLE) is also present

- Sonography
- CT, MRI
- Leukocyte scanning
- Percutaneous aspiration

► **Sonographic findings:**

- Nonhomogeneous hypoechoic or echogenic mass with ill-defined margins between the diaphragm and the liver or spleen.
- The sonographic appearance of the mass changes as it undergoes liquefaction.

► **Accuracy of sonographic diagnosis:** Sonography suggests the correct diagnosis, which is confirmed by ultrasound-guided needle aspiration.

### **Intraorgan Bleeding (Fig. 99)**

► **Clinical manifestations:** Acute pain, usually localized, with pain-induced shock symptoms; peritoneal irritation; occasional hemorrhagic shock, depending on the severity of the bleeding

► **Diagnosis:**

- History, physical examination
- *Laboratory tests:* Simple blood count, coagulation status
- *Sonography:* Preliminary examination followed by scans at the site of greatest pain

► **Sonographic findings:**

- Hypoechoic mass within an organ (fresh blood is anechoic to hyperechoic; an older hematoma is echogenic or complex)
- The affected organ is usually enlarged.

► **Accuracy of sonographic diagnosis:** A confident diagnosis can be made when sonographic findings are interpreted in the context of clinical findings. The sonographic picture is typical. Additional imaging studies such as CT can support the

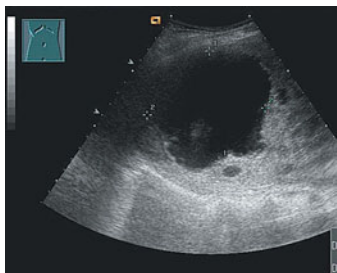


Fig. 99 Bleeding from hepatic metastases appears as a sharply circumscribed, hypoechoic mass (cursors) in the liver following an episode of acute pain with shock symptoms

diagnosis, which is established by percutaneous aspiration and drainage (unless contraindicated).

### Renal Infarction (Fig. 100)

- ▶ **Clinical manifestations:** Flank pain, hematuria, and proteinuria; fever, leukocytosis; nausea, vomiting. Oliguric renal failure may occur. Hypertension develops several days afterward.
- ▶ **Diagnosis:** Determine the cause of the embolism and thrombosis; should be considered in patients with cardiac arrhythmias
  - **Laboratory findings:** Elevated GOT (= AST), LDH (very high), and AP. LDH and AP may also be elevated in the urine.
  - Sonography with follow-up scans; ultrasound contrast agents may be used if needed
  - CT with contrast medium
  - Angiography is rarely necessary
- ▶ **Sonographic findings:**
  - The kidney may appear sonographically normal in the acute stage of a renal artery embolism, or it may contain a wedge-shaped hypoechoic area whose apex points toward the renal pelvis.
  - Later an echogenic triangular scar develops, causing an indentation of the renal surface with narrowing of the parenchymal border.
  - With a hemorrhagic infarction due to renal artery thrombosis, parenchymal bleeding leads to an irregular, patchy echogenic area in the renal parenchyma.
  - CDS shows an absence of flow in the renal artery and may show a wedge-shaped perfusion defect in the parenchyma.
  - Later scans show a decrease in renal size.
- ▶ **Accuracy of sonographic diagnosis:** A fresh infarction cannot be confidently diagnosed without CDS, which has an accuracy rate up to 85%. The diagnosis can be established by using ultrasound contrast agents or CT angiography.

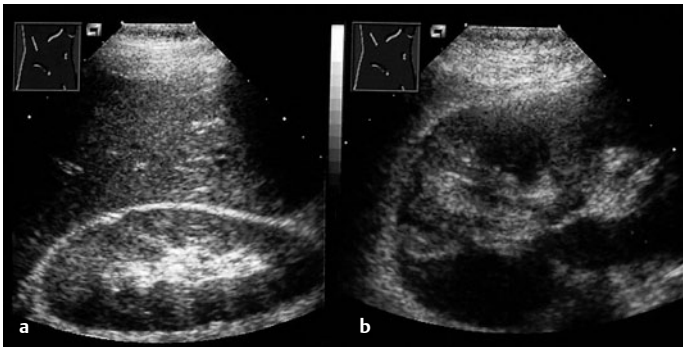


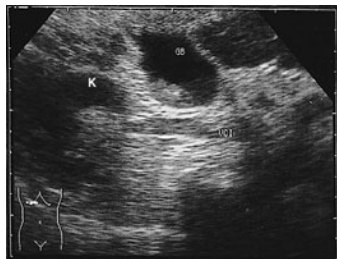Fig. 100a, b Renal infarction. **a** Wedge-shaped, sharply circumscribed hyperechoic area. **b** Magnification: The triangular avascular area confirms the infarction. The patient presented clinically with flank pain. For CDS see also Figs. 420b, 403c

## Splenic Infarction

- ▶ See also Spleen, p. 317.
- ▶ **Clinical manifestations:** Sudden onset of left upper quadrant pain
- ▶ **Diagnosis:**
  - *History:* Underlying disease that may cause thrombosis (e.g., hemoglobinopathy, myeloproliferative disease) or embolism (e.g., cardiac arrhythmia, atherosclerosis, heart disease, or endocarditis)
  - Auscultation of a perisplenic friction sound
  - *Sonography:* Clinical manifestations antedate changes on B-mode images. The infarction can be quickly detected by the use of ultrasound contrast agents
  - Splenic scintigraphy
  - CT angiography shows a change in the acute stage.
- ▶ **Sonographic findings:** Same causes and same appearance as a renal infarction
  - *Fresh:* Hypoechoic, superficial parenchymal change, usually wedge-shaped
  - *Old:* Echogenic change with associated surface retraction
  - Splenic infarctions may also develop into cystic lesions.
- ▶ **Accuracy of sonographic diagnosis:** The morphologic changes are easily identified, but it is difficult to make an etiologic diagnosis. Only CDS is rewarding in the acute stage. The level of diagnostic confidence can be significantly increased by adding ultrasound contrast agents.

## Renal Vein Thrombosis (Fig. 101)

- ▶ See also Kidney, p. 268.
- ▶ **Clinical manifestations:** Acute flank pain, initially like that with renal colic; possible fever and chills. Laboratory tests show hematuria, proteinuria, and leukocytosis. Acute renal failure may occur in bilateral cases.
- ▶ **Occurrence:** Most common in association with a tumor, nephrotic syndrome, dehydration, pregnancy, oral contraceptive use, or trauma
- ▶ **Diagnosis:**
  - History, preexisting diseases
  - Laboratory tests (urinalysis)
  - CDS
- ▶ **Sonographic findings:**
  - The kidney is initially enlarged with a nonhomogeneous, predominantly hypoechoic rim of parenchyma. Later the kidney is diminished in size.
  - Well-defined dilated veins, usually echogenic
  - *CDS:* No detectable flow
  - With left renal vein thrombosis, testicular congestion may be noted on the left side in male patients.



**Fig. 101** Renal vein thrombosis. The renal parenchyma (K) is thickened and hypoechoic. The renal vein is dilated with high-level internal echoes extending to the inferior vena cava (VCI). GB = gallbladder with sludge

- **Accuracy of sonographic diagnosis:** With adequate visualization, there is no need for additional imaging modalities. Duplex sonography (e.g., in power mode) can distinguish a true thrombosis from venous occlusion by an infiltrating tumor and can detect vascularity in the tumor nodule. Angiography, venography, or CT may rarely be necessary in doubtful cases.

## 6.2 Lower Abdominal Pain

### Basic Principles

- **Principal signs and symptoms:** See p. 62  
 ► **Differential diagnosis:** See Table 10

**Table 10 · Differential diagnosis of lower abdominal pain**

Diagnosis	Sonographic signs
<i>Common</i>	
Appendicitis	Abnormal target pattern, typical layered wall structure
Diverticulitis (p. 76)	Thickened, hypoechoic bowel wall; partial acoustic shadow from trapped air
<i>Less common</i>	
Hernia (p. 77)	Hernia sac with wall-thickened bowel loops
Renal colic (p. 65, 382)	Obstructed, anechoic pyelocalyceal system, twinkling artifact
<i>Rare</i>	
Epiploic appendagitis (p. 77)	Fat necrosis of an epiploic appendix
Urinary retention (p. 78)	Strongly distended bladder; obstructed, anechoic renal pelvis
Adnexitis (p. 78)	Mixed cystic and solid mass, wall thickening
Torsion of an ovarian cyst (p. 80)	Unilateral ovarian enlargement with a cystic mass
Tubal rupture (p. 79)	Enlarged uterus, parauterine free fluid
Testicular torsion (p. 80)	Enlarged, isoechoic testis, hydrocele

For conditions that cannot be diagnosed with ultrasound, see Table 9, p. 62.

### Appendicitis (Fig. 102)

- See also Large Intestine, p. 369.
- **Clinical manifestations:**
- Upper abdominal pain may be present initially; right lower quadrant pain, rebound pain
  - Nausea, anorexia, vomiting; rarely constipation or diarrhea
  - Fever with a gradient between axillary and rectal temperatures
  - *After a perforation:* Initial relief of pain, followed by the picture of an acute abdomen ranging to septic-toxic shock

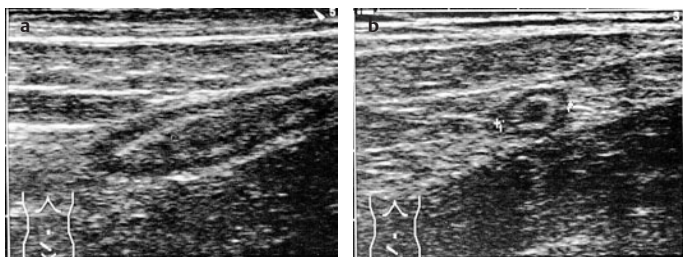


Fig. 102a, b Appendicitis. Oblique scan through the right lower abdomen shows hypoechoic swelling of the appendix wall anterior to the psoas in the area of the cecal pole. **b** Transverse scan shows an abnormal target pattern (cursor) with hypoechoic–hyperechoic–hypoechoic wall layers

► **Diagnosis:**

- *History:* typical sequence of complaints. Pain is difficult to localize initially, usually affecting the periumbilical and epigastric regions. Pain subsequently increases and becomes constant, exacerbated by coughing and movement.
- *Laboratory findings:* leukocytosis, elevated ESR; obtain urinalysis to exclude a urinary tract infection.

► **Sonographic findings** (intestinal sonography with a 5 MHz transducer; identify the cecal pole at the ileocecal junction):

- Small, abnormal target pattern in the right lower quadrant with a thickened, hypoechoic bowel wall due to edema. The wall layers show a hypoechoic–hyperechoic–hypoechoic pattern.
- Maximal pain on compression.

► **Accuracy of sonographic diagnosis:** Finding a thickened (>6 mm) painful appendix confirms the diagnosis. An absence of ultrasound abnormalities makes the diagnosis unlikely, but does not exclude appendicitis. With an adequate examination time and an experienced examiner, the diagnostic accuracy is 100%.

### Diverticulitis (Fig. 103)

► See also Large Intestine, p. 370.

► **Clinical manifestations:** Usually the pain is maximal in the left lower quadrant (“left-sided appendicitis”). Gastrointestinal bleeding may occur, and blood is often present in the stool. Fever, palpable mass in the lower abdomen.

► **Diagnosis:** history, laboratory tests, sonography, colonoscopy or sigmoidoscopy (may cause a perforation in the acute phase).

► **Sonographic findings:**

- Thickened, hypoechoic bowel walls.
- It is common to find a small air collection (trapped in the diverticulum) that does not move with peristalsis and casts a constant, incomplete acoustic shadow.

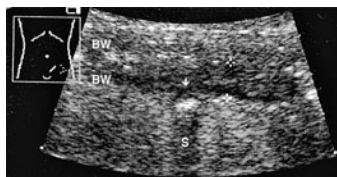


Fig. 103 Diverticulitis: swelling of the bowel wall (BW), air in the diverticulum (arrow) with an associated acoustic shadow (S)

- ▶ **Accuracy of sonographic diagnosis:** Selective intestinal scanning with a high-resolution probe can demonstrate typical bowel wall changes in up to 90% of patients. These changes, combined with the clinical presentation, can establish the diagnosis.

### Epiploic Appendagitis (Fig. 104)

- ▶ **Fat necrosis of an epiploic appendix:**
  - Biconvex, incompressible mass of high echogenicity
  - Surrounding rim of low echogenicity

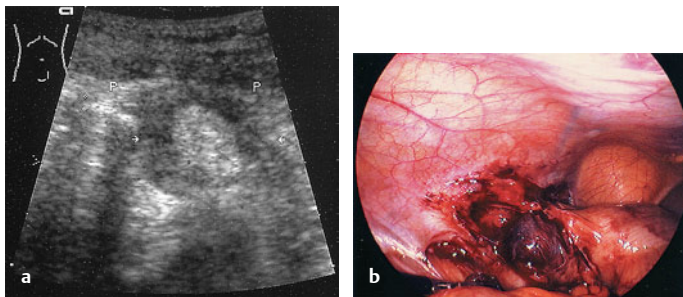


Fig. 104a, b Epiploic appendagitis. **a** Inflammatory matting and necrosis of the epiploic appendix (arrows) on the peritoneum (P). **b** Endoscopic appearance

### Hernia (Fig. 105)

- ▶ See also Palpable Masses, p. 105.
- ▶ **Clinical manifestations:** Pain is localized to the hernia site and is constant if the hernia has become incarcerated. Most patients present with a palpable mass, and many have a palpable hernial ring. The mass enlarges on coughing or straining.
- ▶ **Diagnosis:**
  - History
  - Clinical examination with inspection, auscultation, and selective palpation
  - Sonography

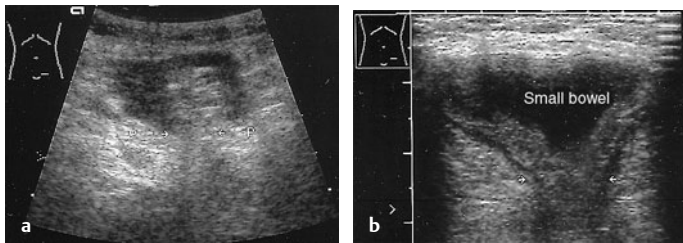


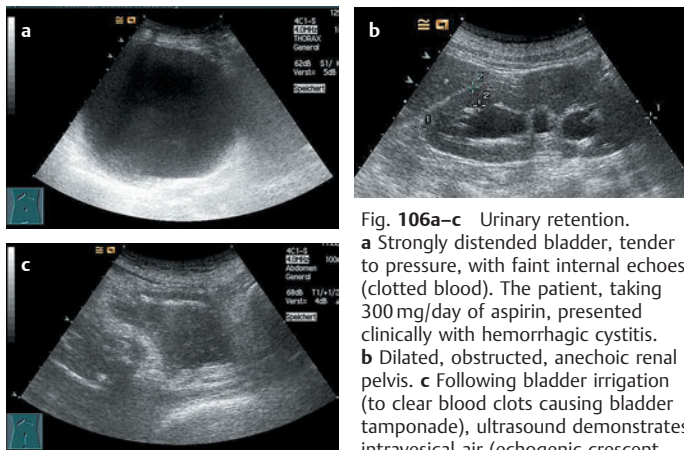
Fig. 105 a, b Inguinal hernias. **a** Echogenic omentum in the hernial sac. **b** Herniated small bowel. With an incarcerated hernia, the sac always contains fluid

► **Sonographic findings:**

- Signs of mechanical bowel obstruction (see p. 82).
- Gap in the peritoneal line (detectable with a 5 MHz or 7 MHz transducer).
- Bowel loops with thickened walls or omentum can be detected in the hernial sac. The contents are easier to identify if peristalsis is still present.
- Indirect hernia = hernial sac that is lateral to the epigastric vessels and passes obliquely through the abdominal wall.
- Direct hernia = medial hernial sac that passes directly through the abdominal wall.

### Urinary Retention (Fig. 106)

- **Clinical manifestations:** retention of urine, increasing pain in the lower abdomen
- **Diagnosis:** history (onset of pain, location of pain, last voiding); urinalysis; sonography; urethral catheter
- **Sonographic findings:**
  - Markedly distended bladder
  - The renal pelvis is often dilated and anechoic as a result of bladder tamponade and reflux
  - High-level internal echoes (blood clots) may be seen.

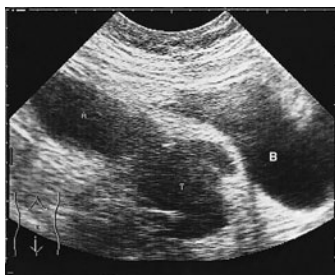

**Fig. 106a–c** Urinary retention. **a** Strongly distended bladder, tender to pressure, with faint internal echoes (clotted blood). The patient, taking 300 mg/day of aspirin, presented clinically with hemorrhagic cystitis. **b** Dilated, obstructed, anechoic renal pelvis. **c** Following bladder irrigation (to clear blood clots causing bladder tamponade), ultrasound demonstrates intravesical air (echogenic crescent along the bladder roof). Bright swirling echoes (blood) can be seen during irrigation

### Adnexitis (Fig. 107)

- **Clinical manifestations:** acute or slowly progressive lower abdominal pain, often bilateral; frequently begins after menses; fever; palpable tender mass.
- **Diagnosis:**
  - History, physical examination
  - *Laboratory findings:* leukocytosis, elevated ESR
  - Sonography
  - Transvaginal sonography may be used if needed; diagnostic laparotomy is rarely indicated.

Fig. 107 Adnexitis. Behind the bladder (B) is a mass with irregular echogenic margins and a hypoechoic center (T). Hypoechoic free fluid is visible above the mass. May be mistaken for an ovarian tumor in patients with elevated tumor markers (diagnosis established by histologic examination)



► **Sonographic findings:**

- Mixed cystic/solid mass (hypoechoic, echogenic) caused by wall thickening and the accumulation of pus
- Tenderness to probe pressure

► **Accuracy of sonographic diagnosis:** The sonographic findings are diagnostic in approximately 80% of all cases. This accuracy rate can be increased somewhat by transvaginal scanning. More pronounced forms may be indistinguishable from a tumor.

### Tubal Rupture (Fig. 108)

► **Clinical manifestations:** lower abdominal pain; signs and symptoms may mimic hemorrhagic shock

► **Diagnosis:**

- *History:* menstrual history, including information on the intensity of menstrual bleeding. (Most tubal ruptures are caused by an unrecognized ectopic pregnancy in adolescents and young women.)
- Sonography
- Laboratory findings, pregnancy index
- Laparoscopy, followed if necessary by laparotomy

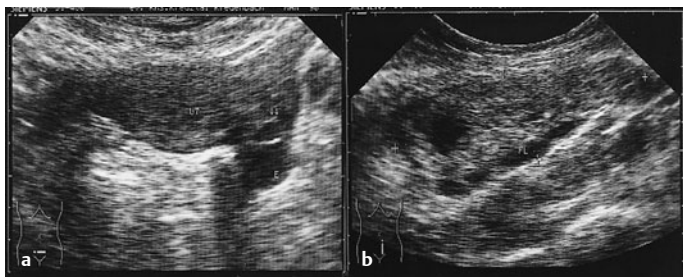


Fig. 108a, b Tubal rupture in a patient with ectopic pregnancy and periadnexitis. **a** Uterus (UT) with proliferative endometrium, left adnexa enlarged with a marginal discontinuity (arrows) and retrouterine effusion (E). **b** Enlarged adnexa (cursors) with an irregular internal echo pattern and a conspicuous hypoechoic mass (possible an old gestational sac). A fluid rim (FL) surrounds the adnexa. With a presumptive diagnosis of abscess, laparoscopy was performed to exclude ovarian cancer, followed by laparotomy. Histologic diagnosis: periadnexitis following an old tubal abortion

- ▶ **Sonographic findings:** uterine changes like those seen in pregnancy (enlarged uterus, proliferative endometrial changes with or without a pseudogestational sac). Free fluid around the uterus. A conceptus can often be detected.
- ▶ **Accuracy of sonographic diagnosis:** An acute tubal rupture can be diagnosed sonographically in conjunction with the clinical findings and  $\beta$ -HCG. Small, older ruptures are difficult to evaluate with ultrasound. The detection of an ectopic sac establishes an extrauterine pregnancy. In the absence of this finding, ectopic pregnancy can be sonographically confirmed in 80% of cases.

### Torsion of an Ovarian Cyst (Fig. 109)

- ▶ **Clinical manifestations:** colicky pain of sudden onset, increasing in intensity, sometimes beginning after an abrupt twisting of the body
- ▶ **Diagnosis:**
  - ▶ **Note:** It is essential not to overlook this diagnosis.
    - *Rectal or vaginal examination:* very tender mass
    - Sonography, transvaginal sonography
    - Laparoscopy with preparations for laparotomy
- ▶ **Sonographic findings:**
  - Unilateral ovarian enlargement with an associated cystic mass.
  - In many cases the twisted pedicle can be visualized as an echogenic band.
- ▶ **Accuracy of sonographic diagnosis:** The cyst can be detected with high confidence, but it may be difficult to classify. The diagnosis can be made sonographically in conjunction with clinical findings and the exclusion of pregnancy.

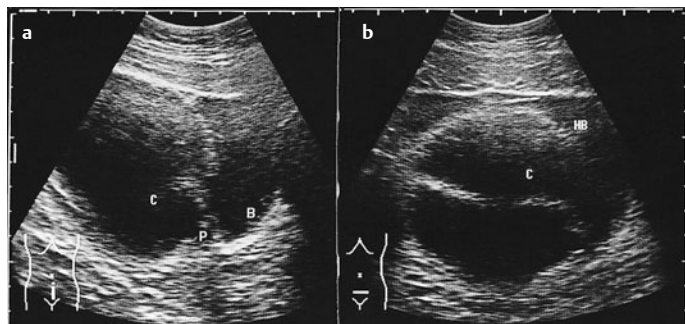


Fig. 109a, b Torsion of an ovarian cyst: anechoic cyst (C) adjacent to the bladder (B). The pedicle (P) appears as an echogenic band

### Testicular Torsion

- ▶ **Clinical manifestations:** excruciating pain of sudden onset; swelling and redness of the scrotum; nausea, vomiting
- ▶ **Diagnosis:**
  - *History:* age
  - Laboratory tests to differentiate from orchitis and epididymitis
  - Sonography
- Sonographic findings:**
  - Enlarged testis
  - Testis decreases in size over a period of days, may become atrophic

- Affected testis is isoechoic to unaffected testis
  - Hypoechoic to anechoic areas increase over a period of days, signifying necrosis
  - Enlarged epididymis
  - Hydrocele
  - Absence of vascularity by CDS
- ▶ **Accuracy of sonographic diagnosis:** Testicular torsion may be mistaken for a tumor or inflammation. CDS can confirm the diagnosis in 100% of cases by showing an absence of blood flow.
- ▣ **Caution:** This diagnosis is an indication for immediate surgery.

## 6.3 Diffuse Abdominal Pain

### Basic Principles

- ▶ **Principal signs and symptoms:** see p. 62.
- ▶ **Differential diagnosis:** see Table 11.

**Table 11 · Differential diagnosis of diffuse abdominal pain**

Diagnosis	Sonographic signs
<i>Common</i>	
Gastroenteritis (p. 361)	Accentuated bowel walls, increased intraintestinal fluid, possible small hypoechoic mesenteric lymph nodes
Coprostasis	Distended colon loops with tense, air-filled haustra
Mechanical ileus (p. 82)	Bidirectional peristalsis, dilated bowel loops containing increased amounts of fluid
Paralytic ileus (p. 83)	Absence of peristalsis, dilated bowel loops
Peritonitis (p. 83)	Thickened peritoneum, dilated bowel without wall swelling, free fluid
<i>Less common</i>	
Mesenteric vascular occlusion (p. 84)	Long segmental thickening of bowel walls, acute luminal narrowing, decreased peristalsis
Dissecting aortic aneurysm (p. 71, 205)	Aortic dilatation, floating anechoic band in aortic lumen, double lumen
<i>Rare</i>	
Intra-abdominal bleeding (p. 86)	Essentially anechoic fluid surrounding the organs; capsular discontinuity is seen with an organ rupture

For conditions that cannot be diagnosed with ultrasound, see Table 9, p. 62.

### Mechanical Bowel Obstruction (Figs. 110–113)

- ▶ See also Small Intestine, p. 361.
- ▶ **Clinical manifestations:**
  - *Intermittent colicky pain:* The pain from a strangulated bowel does not have this colicky aspect. An obstruction of the small bowel is more painful than an obstruction of the large bowel.
  - *Vomiting with retention of stool and flatus:* The higher the site of the obstruction, the greater the frequency and severity of vomiting.
  - *Distended abdomen*
- ▶ **Diagnosis:** History, auscultation, palpation; ultrasound, plain abdominal radiograph, endoscopy
- ▶ **Sonographic findings:**
  - Circumscribed bidirectional peristalsis
  - Dilated bowel loops containing an increased amount of fluid and stool
  - *Detectable causes:*
    - *Gallstone* (rapidly enlarges after entering the duodenum or colon following a confined gallbladder perforation): Typical echogenic crescent, generally casting a complete acoustic shadow
    - *Adhesive band:* Echogenic constricting band associated with thickening of the bowel wall due to venous stasis
    - *Tumor:* Circumscribed swelling of the bowel wall with an abnormal target pattern
    - *Intussusception:* Target pattern with a hypoechoic inner and outer ring (bowel wall) separated by an hyperechoic middle ring (bowel lumen between the telescoped wall segments)
    - *Bezoar:* Foreign body obstructing the bowel lumen (hyper- or hypoechoic structure, often with an irregular surface). Frequently casts an acoustic shadow. May cause intermittent signs of bowel obstruction, and may migrate initially. Marked symptoms usually appear when the foreign body becomes lodged at the ileocecal valve.
- ▶ **Accuracy of ultrasound diagnosis:** Very high, up to 100%. More sensitive than radiographs in early cases.

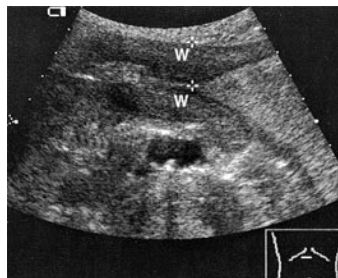


Fig. 110 Mechanical obstruction by a circumferential antral tumor causing high-grade stenosis of the bowel lumen. Ultrasound shows that the wall thickness (W) is increased to 17 mm (cursors). The patient presented clinically with intractable vomiting

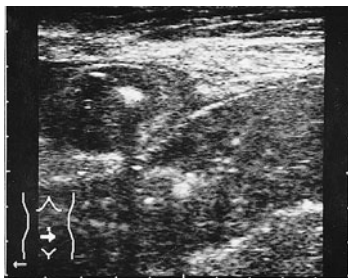


Fig. 111 Adhesive bowel obstruction. Midabdominal transverse scan shows an abnormal target pattern with a markedly thickened bowel wall that is tapered inferiorly (adhesive band). The acoustic shadow is from intraluminal air

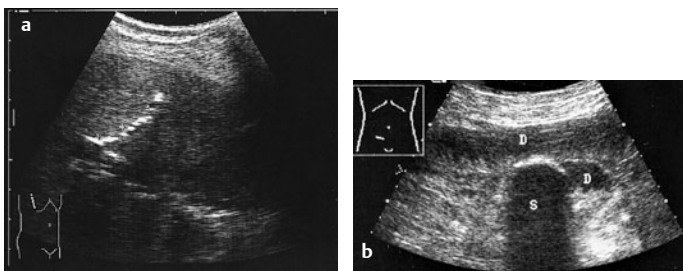


Fig. 112a, b Gallstone ileus of the small bowel. **a** Gas in an intrahepatic bile duct (arrows) following the perforation of a calculus into the duodenum. **b** Gallstone obstructing the bowel lumen. The stone can be identified by its echogenic crescent and complete acoustic shadow (S). D = dilated bowel loop

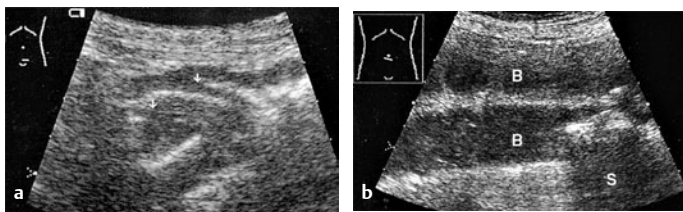


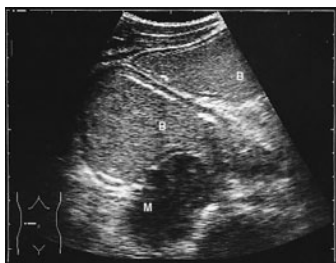Fig. 113a, b Intussusception and bezoar obstruction of the small bowel. **a** Intussusception (bowel wall in bowel). Arrows: hypoechoic bowel walls. **b** Bezoar obstruction: fluid-filled bowel (B), nonhomogeneous foreign body with an acoustic shadow (S)

### Paralytic Ileus (Fig. 114)

- ▶ See also Small Bowel, p. 362.
- ▶ **Clinical manifestations:** see Mechanical Bowel Obstruction, p. 82, 361.
- ▶ **Diagnosis:** History, including possible precipitating causes. Absent bowel sounds. See also Mechanical Bowel Obstruction, p. 82, 361.
- ▶ **Sonographic findings:**
  - Absence of peristalsis, usually affecting the entire bowel.
  - Dilated bowel loops.
  - *Toxic megacolon:* Gas-distended bowel loops with thinning of the anterior wall
  - The posterior bowel walls cannot be evaluated because of extensive intraluminal gas and associated shadowing.
- ▶ **Accuracy of ultrasound diagnosis:** Same as in mechanical bowel obstruction.

### Peritonitis (Fig. 114)

- ▶ **Clinical manifestations:** Severe clinical picture that may include shock, heart failure, or impaired renal function; tense abdomen, diffuse or localized pain; retention of stool, nausea, vomiting, fever.



**Fig. 114** Inflammatory peritonitis with paralytic ileus in Crohn disease. Bowel loops (B) are crowded together, dilated, and filled with stool. No evidence of wall thickening or bowel motility. The large psoas muscle (M) is visible posteriorly

▶ **Diagnosis:**

- *History and clinical course:* Appendicitis; perforated diverticulitis, ulcer disease or gallbladder; previous cholecystectomy or common duct surgery; gangrenous bowel obstruction due to adhesions (prior surgery) or an incarcerated hernia.
- *Laboratory findings:* Inflammatory signs, marked leukocytosis
- Ultrasound
- Rarely, diagnostic lavage to identify the causative organism
- Peritoneal biopsy

▶ **Sonographic findings:**

- Thickened peritoneum
- Inflammatory peritonitis may cause the matting of bowel loops by adhesions. The bowel loops cannot be separated from one another by digital palpation.
- Dilatation of the bowel (due to deficient absorption) with no wall swelling and decreased or absent peristalsis. Paralytic ileus may result.
- Peritonitis is usually marked by a very cellular exudate, and free fluid in the abdomen often contains high-level internal echoes.

- ▶ **Accuracy of ultrasound diagnosis:** Ultrasound can rarely demonstrate the peritonitis itself, but can detect the associated changes. The detection of infected ascites (by percutaneous aspiration) confirms the diagnosis.

### Mesenteric Vascular Occlusion (Figs. 115–117)

- ▶ **Clinical manifestations:** Colicky pain of very sudden onset, circumscribed and later diffuse. The pain subsides as the condition worsens. Intestinal gangrene develops with peritonitis and abdominal rigidity, sepsis, and shock. Vomiting, nausea, diarrhea, and constipation may occur.

- ▶ **Cause** is often cardiogenic: Absolute arrhythmia with atrial fibrillation, dilatative cardiomyopathy, or a ventricular aneurysm after myocardial infarction.

- ▶ **Course:** Embolism develops more rapidly than thrombosis.

▶ **Diagnosis:**

- *Laboratory findings:* Include acidosis, elevated serum lactate, and leukocytosis
- Ultrasound imaging and Doppler sonography of the mesenteric vessels (superior and inferior mesenteric arteries)
- *Radiography:* Contrast enema with a water-soluble contrast medium to check for edematous thickening (“thumbprinting”) of the bowel wall
- Celiacography and mesentericography
- Look for the source of the embolus and/or signs of atherosclerosis.

▶ **Sonographic findings:**

- Significant, hypoechoic wall thickening affecting a long bowel segment, becoming less pronounced over time

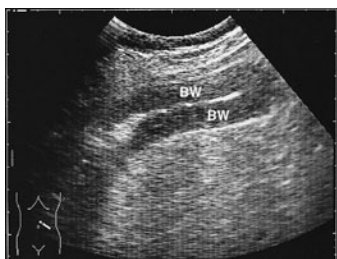

Fig. 115 Mesenteric infarction: Segmental thickening of hypoechoic bowel wall (BW) with absence of peristalsis. The bowel lumen appears as an echogenic band

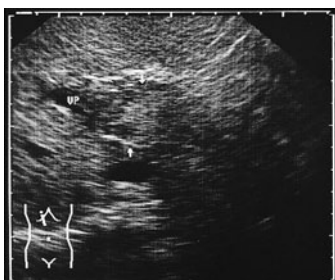

Fig. 116 Acute portal vein thrombosis. Mass in the portal vein (VP) is isoechoic to liver tissue (arrows). Doppler scanning shows no evidence of flow

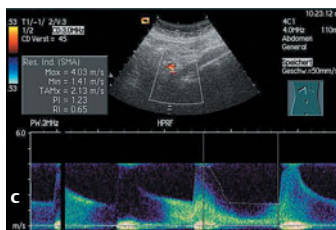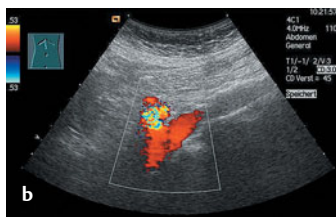
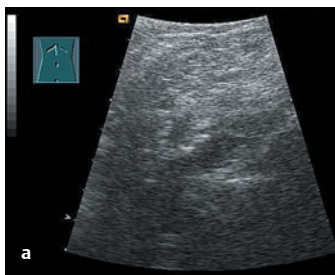


Fig. 117a–c **a** Stenosis of the superior mesenteric artery: Echogenic plaques at the origin of the superior mesenteric artery, initially difficult to identify. **b** CDS shows bright color pixels (aliasing) indicating turbulence and high flow velocities. **c** Spectral curve in a pulsed Doppler scan shows flow acceleration to 4 m/s

- Acute luminal narrowing, progressing to dilatation due to ischemic malabsorption
  - Decreased peristalsis progressing to aperistalsis
  - *Doppler sonography*: atherosclerosis of the mesenteric vessels, occasionally with demonstrable stenosis of the celiac trunk or superior mesenteric artery (Fig. 117)
- **Accuracy of ultrasound diagnosis**: Typical ultrasound findings narrow the differential diagnosis, but mesenteric vascular occlusion cannot be diagnosed by exclusion. The definitive diagnosis is made at operation, since an arterial stenotic occlusion and a thrombotic venous occlusion are often indistinguishable by ultrasound.

### Intra-Abdominal Bleeding (Fig. 118)

- ▶ **Clinical manifestations:** Acute pain, which may be local or diffuse. Significant bleeding can lead to shock, abdominal distention and rigidity.
- ▶ **Diagnosis:**
  - *History:* Previous painful traumatic episode (vehicular accident, kick, fall, etc.) or neoplasia (bleeding metastasis)
  - *Ultrasound:* Ultrasound follow-ups are advised because of the possibility of a delayed organ rupture.
  - *Laboratory findings:* Hematocrit and hemoglobin tests are mandatory.
  - *Paracentesis:* This is warranted in doubtful cases or in patients with copious intra-abdominal fluid.
  - Exploratory laparotomy (diagnostic)
- ▶ **Sonographic findings:**
  - Essentially anechoic fluid surrounding the organs
  - Older organized hematomas are usually nonhomogeneous and more echogenic.
  - Blood may be localized or distributed throughout the abdominal cavity.
  - Capsular discontinuity is seen with an organ rupture (kidney, spleen, liver, etc.).
- ▶ **Accuracy of ultrasound diagnosis:** Ultrasound can detect an intra-abdominal fluid volume as small as 10–15 mL. The nature of the fluid can be determined by guided needle aspiration. Rarely, tumors and metastases may rupture and bleed profusely.

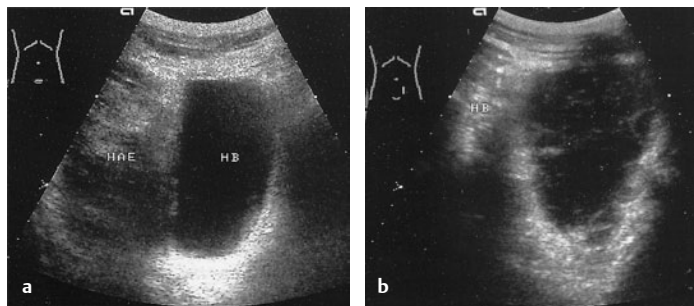


Fig. 118a, b Intra-abdominal bleeding. **a** Echogenic clots (HAE; 2 days) in the right lower abdomen. **b** Arterial hemorrhage in progress, almost anechoic. Skiing injury

## 6.4 Diarrhea and Constipation

### Basic Principles

- ▶ **Classification:** acute or chronic; infectious; secondary to organic disease
- ▶ **Principal signs and symptoms:**
  - *Diarrhea:*
    - more than four bowel movements per day
    - stool weight > 250 g/day
    - soft or liquid consistency
  - *Constipation:*
    - two or fewer bowel movements per week
    - stool volume significantly below the normal range of approximately 80–150 g/day
    - hard consistency
  - The passage of stool may or may not cause discomfort. Stool may be mucus-covered, bloody, watery, or granular and may contain grossly visible food residues.
- ▶ **Diagnosis:**
  - The history is of key importance, as bowel habits are interpreted differently by different examiners. A stool examination may be helpful.
  - All patients with diarrhea should be evaluated for the presence of an infection and for organic disease. Blood work should be done and may include tests for infectious organisms (blood culture, complement binding reaction). The stool may also be examined for bacteriologic testing and antibody detection (e.g., clostridium antibody).
  - All true cases of chronic constipation are presumed to be caused by a stenosing lesion.
  - Only a few causes of diarrhea and constipation can be diagnosed with ultrasound. Most cases should be investigated by endoscopy with tissue sampling and histologic evaluation.
- ▶ The differential diagnosis is reviewed in Table 12, where the possible diagnoses are listed in order of their frequency in the general hospital setting.

### Crohn Disease

- ▶ See also Small Intestine, p. 363, and Large Intestine, p. 366.
- ▶ **Clinical manifestations:** diarrhea, occasionally bloody; abdominal pain over the site of maximum inflammation; fever and malaise, malabsorption syndrome.
- ▶ **Diagnosis:**
  - *Physical examination:* palpable mass (matted bowel loops due to transmural inflammation in Crohn disease); a fistula is often detectable
  - Sonography
  - High colonoscopy with ileoscopy and tissue sampling from all bowel segments (Crohn disease does not always produce grossly visible changes if it affects only the deep wall layers, and so generous biopsies should be taken in all suspected cases)
  - Gastroduodenoscopy may also be done, taking biopsies from the distal duodenum (Watson capsule biopsy may be obtained to evaluate for sprue).
  - *Radiography:* Double-contrast enema is necessary only if endoscopy cannot be done or the patient is believed to have diverticula.

**Table 12 · Differential diagnosis of diarrhea and constipation**

Diagnosis	Sonographic signs
<i>Common</i>	
Crohn disease (p. 87)	Homogeneous, hypoechoic wall thickening, often > 10 mm; discontinuous pattern of involvement; decreased peristalsis
Ulcerative colitis (p. 89)	Continuous pattern of involvement with intraluminal wall irregularities (pseudopolyps); wall thickening is less common
Abdominal tumor (p. 89)	Target pattern, circumscribed wall thickening to 8 mm
Obstructive lesion (p. 89)	Bidirectional peristalsis; fluid-distended bowel loops
Chronic pancreatitis, pancreatic insufficiency (p. 89)	Nonhomogeneous parenchyma with coarse, high-level internal echoes (fibrosis, calcification)
Diverticulitis (p. 90)	Thickened, hypoechoic bowel wall; incomplete acoustic shadow from intraluminal air
<i>Less common</i>	
Hernia (p. 91)	Hernial sac with wall-thickened bowel loops, gap in the peritoneum
<i>Rare</i>	
Pseudo-obstruction (p. 91)	Dilated bowel loops, decreased peristalsis, no obstruction of intestinal transit

**Conditions that cannot be diagnosed with ultrasound**

*Common:* Viral, bacterial and parasitic bowel disease; Whipple disease; panarteritis nodosa of the mesenteric vessels; drugs, poisoning, irritable bowel

*Less common:* Lactase deficiency, reflex response to pain, fluid deficiency, electrolyte disorders

*Rare:* Abdominal toxoplasmic lymphangitis, malabsorption syndrome (diagnosis, see Fig. 436, p. 300), intestinal polyps, carcinoid syndrome, hormone-producing tumor, hyper- or hypothyroidism, food allergy, antibody deficiency syndrome, cystic fibrosis, mesenteric lymph node tuberculosis

**► Sonographic findings:**

- Homogeneous, hypoechoic wall thickening, often > 10 mm, affecting a long segment of the bowel wall; a three-layered wall structure is occasionally seen
- Decreased peristalsis
- Luminal narrowing with prestenotic dilatation
- Discontinuous pattern of involvement
- Involvement of the cecum and terminal ileum
- Frequent lymphadenopathy around affected bowel segments
- Complications can be clearly identified:
  - Abscess (hypoechoic to anechoic mass, stationary, with irregular margins)
  - Conglomerate mass
  - Fistula
  - Ascites

- ▶ **Accuracy of sonographic diagnosis:** The bowel-wall changes detectable with ultrasound are not specific for chronic inflammatory bowel disease. However, the sum of the changes and their distribution pattern, combined with the patient's history, provide a very high index of suspicion. The detectable complications will also suggest the correct diagnosis.

### Ulcerative Colitis

---

- ▶ See also Large Intestine, p. 367.
- ▶ **Clinical manifestations:** chronic diarrhea, frequently bloody; anemia, rarely pain
- ▶ **Diagnosis:**
  - Sonography
  - High colonoscopy with ileoscopy and tissue sampling from all bowel segments, also to exclude carcinoma in long-standing cases; rectal biopsy is particularly advised (for positive differentiation from Crohn disease)
  - Gastroduodenoscopy may also be done if necessary.
  - **Radiography:** double-contrast enema is necessary only if endoscopy cannot be done.
- ▶ **Sonographic findings:**
  - Continuous pattern of intestinal involvement, usually confined to the rectum, sigmoid colon, and descending colon
  - Less commonly, there may be detectable wall thickening to a maximum of 8 mm (not as pronounced as in Crohn disease); wall thickness apparently correlates with the activity of the disease.
  - Irregular hypoechoic or echogenic intraluminal wall indicating pseudopolyp formation
  - Scans in long-standing cases show a rigid tube devoid of haustrations.
  - **Complication:** toxic megacolon
- ▶ **Accuracy of sonographic diagnosis:** The sonographic signs may also appear in infectious bowel diseases, so it is important to proceed with endoscopic examination and biopsy.

### Abdominal Tumor, Obstructive Lesion

---

- ▶ See also Diffuse Abdominal Pain, Mechanical Bowel Obstruction, p. 81, 82, 371; Large Intestine, Diffusely infiltrating carcinoma, p. 370; Colorectal carcinoma, p. 371.
- **Note:** An abdominal tumor may remain asymptomatic for some time, and its initial symptoms may result from mass effects, luminal narrowing, or other secondary effects (e.g., thrombosis).

### Chronic Pancreatitis, Pancreatic Insufficiency

---

- ▶ See also Pancreas, Chronic Pancreatitis, p. 297; Pancreatitis of the body or tail of the pancreas, p. 306; Focal pancreatitis, p. 304.
- ▶ **Clinical manifestations:** recurrent upper abdominal pain (pain ceases with burned-out pancreatitis); pasty, fatty stools; weight loss, diabetes
- ▶ **Diagnosis:**
  - **History:** With a history of recurrent bouts of pancreatitis, try to elicit the precipitating cause. Many patients have a history of alcoholism, gallstones, drugs, cystic fibrosis, malnutrition, or enzyme deficiency.
  - **Stool examination:** collect stool for 3 days, weigh the samples. An average daily weight >150 g suggests pancreatic insufficiency (sprue should be excluded; see Fig. 436), p. 300).

- **Laboratory findings:** glucose intolerance ranging to frank diabetes mellitus. Elevated cholesterol levels are common. Tests may include stool fat determination (more than 7 g of fat/day is abnormal). Less common tests are chymotrypsin determination and/or pancreatic lactase in the stool. Vitamin deficiencies are common.
- Secretin-pancreozymin test is rarely necessary.
- Sonography
- Spot radiographs to check the pancreas for coarse calcifications
- ERCP

► **Sonographic findings:**

- The pancreas may be normal in size, small, or even enlarged.
- Generally the parenchyma is somewhat nonhomogeneous with coarse, high-level internal echoes (fibrosis, calcification).
- There may be irregular hypoechoic to anechoic areas indicating pseudocyst formation.
- The surface of the organ may appear wavy and indistinct.
- There may be irregularity and slight dilatation of the pancreatic duct, with or without calcification.
- Bowel wall thickening may be noted in the duodenal C loop.
- Incompressibility and “en bloc” movement of the fibrotic organ with aortic pulsations.

► **Accuracy of sonographic diagnosis:**

- The detection of ductal dilatation, calcification, and pseudocysts confirms the diagnosis, and this can be done sonographically in almost 85% of cases. If the findings are equivocal, there is evidence that CT scans can provide a somewhat higher diagnostic accuracy.
- FNAB can help in distinguishing a segmental pancreatitis or pancreatic cysts from a pancreatic tumor, although the cytologic and histologic findings are not always conclusive.
- With a sonographically confirmed tumor or indeterminate lesion that will or may be treated operatively, percutaneous biopsy is contraindicated because of the risk of seeding malignant cells along the needle track. A needle biopsy may be done if guided by endosonography, however, because the needle tract can subsequently be included in the resection.

### Diverticulitis (Fig. 119)

► See also Large Intestine, p. 370, and Lower Abdominal Pain, p. 76.

■ **Note:** “Right-sided diverticulitis” of the sigmoid colon may be mistaken for appendicitis.

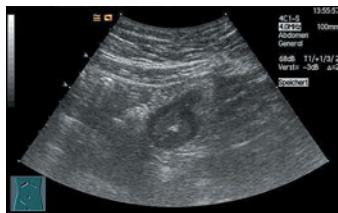

Fig. 119 Abnormal target pattern in the right lower quadrant: sigmoid diverticulitis with peridiverticulitis. Differentiation is mainly required from appendicitis with an incipient perityphlitic abscess

## Hernia

- ▶ See Lower Abdominal Pain, p. 77, and Palpable Masses, p. 105.

## Pseudo-Obstruction (Fig. 120)

### ▶ Classification:

- Chronic, intermittent, secondary (diabetes mellitus, myxedema, amyloidosis, scleroderma, dermatomyositis, muscular dystrophy, endocrine disorders)
- Idiopathic
- Acute (Ogilvie syndrome) after a severe illness or surgical operation

- ▶ **Clinical manifestations:** intermittent pain, abdominal distention, nausea, vomiting (suggests mechanical bowel obstruction); constipation, possible intermittent diarrhea with steatorrhea (in blind pouch syndrome due to intestinal bacterial overgrowth); malnutrition ranging to anorexia

### ▶ Diagnosis:

- *History, clinical examination:* Digital rectal examination is important (rectal ampulla is filled with stool in pseudo-obstruction, empty with a true obstruction)
- Laboratory tests, including tests for endocrine disorders
- Sonography
- Endoscopic examination and biopsy (amyloidosis, muscular dystrophy); air aspiration may also be therapeutic

### ▶ Sonographic findings:

- Distended bowel loops with increased fluid content
- Small and large intestine may be affected
- Decreased peristalsis
- No obstruction of intestinal transit
- Bowel wall appears thinned
- The posterior walls of anterior bowel loops may not be visualized because of dehiscence and intraluminal air.

- ▶ **Accuracy of sonographic diagnosis:** The sonographic findings are unequivocal, but the diagnosis remains uncertain because the cause cannot be determined. A stenosing lesion may be missed at ultrasound examination. Doubts are resolved by endoscopy and histologic evaluation of biopsy samples.

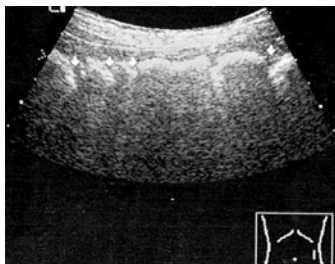


Fig. 120 Pseudo-obstruction: overdistended loops of colon with anterior intraluminal air (echogenic crescent). The plicae (arrows) and haustrations in this patient can still be identified

## 6.5 Unexplained Fever

### Basic Principles

- ▶ **Principal signs and symptoms:** malaise; undulating subfebrile temperatures are most common, but fever may occur. Hematologic changes, anemia, elevated ESR. Weight loss, night sweats; constipation or diarrhea, or an alternation of both.
- ▶ **Diagnosis:**
  - Basically, all infectious diseases should be excluded.
  - An occult abscess is frequently responsible for the disease and fever. A systematic search should be conducted and may include CT scans if required.
  - Virtually any tumor may cause unexplained fever.
  - If enlarged lymph nodes are found, the anatomy of the lymphatic drainage pathways can help direct the search for a primary tumor (Table 13 and Fig. 131, p. 99). As a general rule, superficial lymphatic vessels course with the cutaneous veins while deep lymphatics follow the arteries.

**Table 13 · Visceral lymph node metastases and their relationship to primary tumor sites**

Sites of nodal metastases	Primary tumor sites
Inferior mesenteric lymph nodes	Left side of the colon, sigmoid colon
Superior mesenteric lymph nodes	Right side of the colon, small intestine, pancreas
Celiac lymph nodes	Lower esophagus, stomach
Lymph nodes at the porta hepatis	Lower esophagus, stomach, colon, liver, gallbladder, pancreas, urogenital system

- ▶ **Differential diagnosis:** Reviewed in Table 14, where the possible diagnoses are listed in order of their frequency in the general hospital setting. The list includes lesions that cause relatively nonspecific complaints, making them more difficult to find. The examiner must remember to look for them.

**Table 14 · Differential diagnosis of unexplained fever**

Diagnosis	Sonographic signs
<i>Common</i>	
Gastrointestinal tumors	Hypoechoic round lesions, intestinal target patterns, signs of partial bowel obstruction
Pancreatic tumor (p. 94)	Hypoechoic mass, dilatation of pancreatic and bile duct
Abscess (p. 94)	Hypoechoic, sharply circumscribed mass that may show high-level internal echoes
Pulmonary embolism (p. 95)	

**Table 14 · Differential diagnosis of unexplained fever – continued**

Diagnosis	Sonographic signs
<i>Less common</i>	
Hypernephroma (p. 95)	Nonhomogeneous mass, variable echogenicity, pseudocapsule
Adrenal tumor (p. 96)	Hypochoic mass between the vena cava or aorta and the superior renal pole
Malignant lymphoma (p. 97)	Diffuse organ infiltration or multiple, hypochoic extra- and intra-abdominal round lesions distributed along vascular pathways
Breast carcinoma (p. 97)	Variable echogenicity, ill-defined margins with tumor extensions, usually a nonhomogeneous internal echo pattern
Endocarditis (p. 98)	Thickened valves, echogenic deposits, valvular regurgitation (TTE or TEE)
<i>Rare</i>	
Sarcoma (p. 97)	
Atrial myxoma (p. 98)	Intracavitary echogenic mass, usually very mobile

**Conditions that cannot be diagnosed with ultrasound**

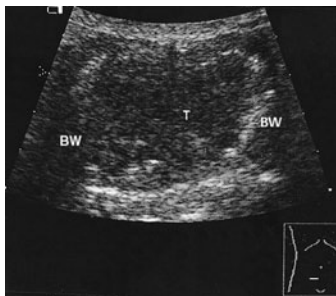
*Common:* Central bronchial carcinoma (chest wall tumors can be detected sonographically and sampled by ultrasound-guided percutaneous biopsy)

*Less common:* Leukemia

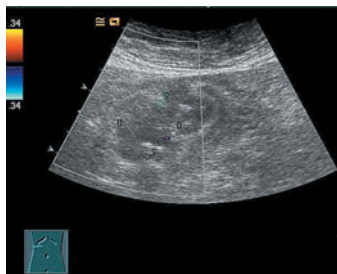*Rare:* Melanoma

**Gastrointestinal Tumors (Figs. 121 and 122)**

- ▶ See also Diffuse Abdominal Pain, Mechanical Bowel Obstruction, p. 81, 82, and Paralytic Ileus, p. 83.
- ▶ **Clinical manifestations:** variable constipation, blood in the stool, weight loss.
- ▶ **Diagnosis:** history that elicits specific information on gastrointestinal complaints; clinical evaluation including a rectal examination; laboratory tests; endoscopy; abdominal CT.



**Fig. 121** Intestinal tumor: abnormal mass (T) with a thickened bowel wall (BW)



**Fig. 122** Tumor of the right colic flexure: nonhomogeneous, hypochoic colonic mass with associated wall thickening. The patient had a clinically palpable mass

- ▶ **Sonographic findings:**
  - Hypoechoic round lesions distributed along the mesentery or along vessels
  - Intestinal target patterns
  - Signs of partial bowel obstruction, sometimes intermittent
- ▶ **Accuracy of sonographic diagnosis:** An experienced examiner can detect intestinal lesions with high confidence, and the sonographic findings can direct the search for a primary tumor. Ultrasound should be supplemented by additional studies that supply more specific information.

### Pancreatic Tumor (Fig. 123)

- ▶ See also Pancreas, Pancreatic carcinoma, p. 304.
- ▶ **Clinical manifestations:** The tumor may remain asymptomatic for some time, depending on its location (tail of pancreas). In most cases the tumor is no longer curable by the time symptoms appear, particularly if there are detectable local or distant metastases and/or vascular invasion. Symptoms may include jaundice, inferior vena cava syndrome, and upper abdominal pain.
- ▶ **Diagnosis:** Imaging studies consist of sonography, ERCP, and CT if necessary. Percutaneous FNAB is done only to confirm the diagnosis in inoperable cases. A histologic diagnosis is made at operation.
- ▶ **Sonographic findings:**
  - Hypoechoic mass
  - Dilated pancreatic duct
  - Obstructed bile duct
- ▶ **Accuracy of sonographic diagnosis:** The changes associated with a pancreatic tumor are clearly detectable with ultrasound, although pancreatitis cannot always be distinguished from a tumor. If there is any doubt, a prompt exploratory laparotomy is advised.

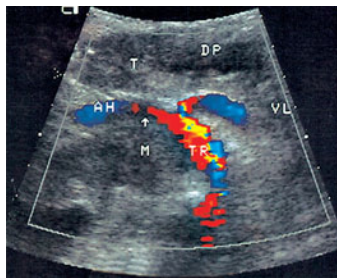


Fig. 123 Metastasis from a pancreatic tumor. The metastasis (M) is compressing the hepatic artery (arrow), and the primary tumor (T) is compressing the pancreatic duct (DP), which is markedly expanded. VL = splenic vein, TR = celiac trunk

### Abscess (Figs. 124 and 125)

- ▶ See also Arteries and Veins, Periprosthetic Infection, p. 206; Upper Abdominal Pain, Subphrenic Abscess, p. 71; Postoperative Complications, p. 434.
- ▶ **Note:** Abscesses may form in any organ as a result of bacterial dissemination. Occasionally they are preceded by an interventional procedure. The history may narrow the differential diagnosis in these cases.
- ▶ **Clinical manifestations:** unexplained fever, significant malaise; occasional dull pain at the abscess site. A palpable mass may be noted, depending on the location of the abscess.

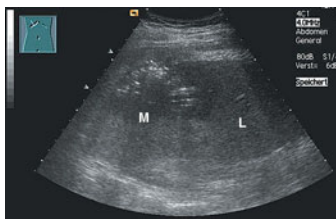


Fig. 124 Hepatic abscess caused by gas-forming organisms: hypoechoic mass (M) with high-level internal echoes (air). L = liver

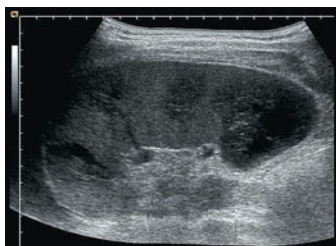


Fig. 125 Splenic abscess: hypoechoic splenic mass with ill-defined margins

- ▶ **Diagnosis:** history; blood count, blood culture; sonography (scans may be directed by clinical complaints)
- ▶ **Sonographic findings:**
  - Hypoechoic mass, usually with smooth but irregular margins
  - High-level internal echoes with gas-forming organisms
- ▶ **Accuracy of sonographic diagnosis:** The diagnosis can be made sonographically with high confidence. CDS and harmonic imaging are helpful. If doubt exists, ultrasound contrast agents can be used to confirm that the mass is avascular (unnecessary in most cases). The diagnosis is established by percutaneous aspiration and examination of the aspirate to identify the infecting organism and determine its antibiotic sensitivity. The abscess is evacuated in the same sitting, and if necessary it may be drained under sonographic guidance.

### Pulmonary Embolism

- ▶ See Upper Abdominal Pain, p. 67.

### Hypernephroma (Fig. 126)

- ▶ **Clinical manifestations:** Most of these tumors are asymptomatic, and the only manifestation may be intermittent fever in the absence of infection. Microhematuria is usually present; gross hematuria is rare. An expansile tumor will cause flank pain and a palpable intra-abdominal mass. Metastases are seeded to the lung, CNS, bone, and thyroid gland. Late features include fatigue, weight loss, and cachexia.
- **Note:** Tumors detected early by ultrasound are surgically curable.
- ▶ **Diagnosis:**
  - **Urinalysis:** All patients with hematuria should be evaluated for serious underlying disease. Possible causes are renal, bladder and urinary tract tumors; glomerulonephritis (casts in urinary sediment); and pyelonephritis.
  - Sonography
  - Intravenous pyelography; abdominal CT if required
- ▶ **Sonographic findings:**
  - Nonhomogeneous renal mass; may be associated with regressive changes, intratumoral hemorrhage, or both
  - Lesion transcends the renal capsule
  - Variable echogenicity relative to the renal parenchyma
  - Lesion is well delineated by a pseudocapsule

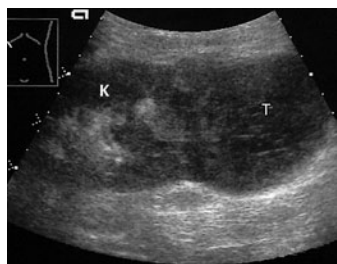


Fig. 126 Large, hypoechoic tumor (T). Partial hypoechoic transformation of sinus echo due to tumor vein thrombosis. K = kidney

- ▶ **Accuracy of sonographic diagnosis:** Even small, asymptomatic renal cell carcinomas can be detected at an early stage by routine sonography. Tumors as small as 5 mm can be visualized under favorable conditions. In a selective tumor search, renal changes can be reliably detected and referred for further evaluation. The tumor may be mistaken for a cystic lesion on ultrasound, and percutaneous aspiration should be carried out. A cyst contains clear yellowish fluid, whereas a carcinoma yields a turbid, sometimes bloody aspirate that may be cytologically negative.

### Adrenal Tumor (Fig. 127)

- ▶ **Clinical manifestations:** lethargy, electrolyte disorders, hormonal disorders; upper abdominal pain due to mass effect; edema due to vena cava compression syndrome
- ▶ **Diagnosis:**
  - History, clinical findings
  - *Laboratory tests* (20% of adrenal tumors are nonfunctioning): electrolytes, 24-hour cortisol levels if required; androgens, andosterone, suppression test
  - Sonography with ultrasound-guided percutaneous aspiration
  - CT examination if required

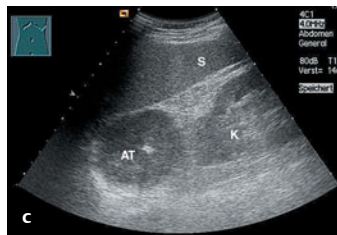
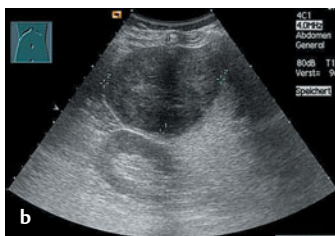
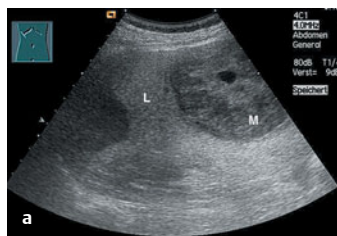Fig. 127a–c Adrenal tumor. **a** Non-homogeneous, hypoechoic mass (P) “in” the liver (L), suspicious for a hepatic tumor. **b** Hypoechoic mass (P) by the right superior renal pole in the same patient. **c** Flank scan demonstrates a large, hypoechoic adrenal tumor (AT) medial to the anterior part of the left superior renal pole (K). Diagnosis: pheochromocytoma. S = spleen

► **Sonographic findings:**

- Hypochoic mass, appearing on the right side between the vena cava and superior renal pole (where it may easily cause a vena cava compression syndrome) or on the left side between the aorta and superior renal pole

- **Accuracy of sonographic diagnosis:** Adrenal carcinomas are rarely < 3 cm, and adenomas are usually < 6 cm. An adrenal tumor as small as 2–3 cm is very likely to be detected sonographically when a specific search is undertaken. Benign–malignant differentiation relies on ultrasound-guided percutaneous biopsy.

### Malignant Lymphoma

- See Hepatosplenomegaly, High-Grade Lymphoma, p. 150, 316; Palpable Masses, High-Grade Lymphoma, p. 101; Enlarged Lymph Nodes, Malignant Lymphoma, p. 113.

### Breast Carcinoma (Fig. 128)

- **Clinical manifestations:** nonspecific; ESR may be elevated; palpable breast mass

► **Diagnosis:**

- *Inspection:* cutaneous erythema, nipple retraction, possible abnormal nipple discharge, orange-peel appearance of skin
- *Palpation:* firm, relatively fixed breast mass
- Sonography
- *Mammography:* Local excision is indicated in doubtful cases.

► **Sonographic findings:**

- Exclusion of breast cyst
- Usually, indistinct margins with spiculations
- Echo pattern is usually nonhomogeneous
- Extremely variable echogenicity

- **Accuracy of sonographic diagnosis:** Breast nodules can be clearly visualized with ultrasound. Benign–malignant differentiation is uncertain, however, and additional studies are needed. Ultrasound-guided percutaneous biopsy can establish the diagnosis.

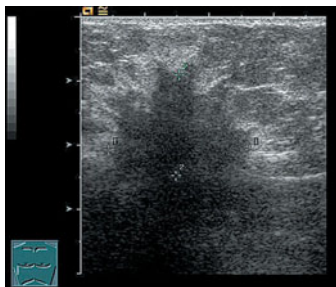


Fig. 128 Hypochoic breast mass with ill-defined margins (69-year-old woman). The patient presented clinically with a firm, immobile, painless nodule in the right breast

### Sarcoma

- See Fig. 167a, b), (p. 122).

- **Note:** Sarcoma becomes symptomatic because of its complications, usually consisting of mass effects (gastric sarcomas frequently ulcerate and bleed). Sarcomas are clearly demonstrated by ultrasound. Histologic confirmation is mandatory.

## Atrial Myxoma

- ▶ **Clinical manifestations:** nonspecific signs and symptoms, fever, weight loss, possible cardiac murmur
- ▶ **Diagnosis:** First it is essential to consider this entity in the differential diagnosis. An elevated ESR, anemia, and lethargy are suggestive signs. The diagnosis is advanced by transthoracic and transesophageal echocardiography.
- ▶ **Sonographic findings:**
  - Intracavitary echogenic mass, usually very mobile.
  - Rapid tumor enlargement may occur.
- ▶ **Accuracy of sonographic diagnosis:** The diagnosis remains uncertain, and differentiation from an intracavitary thrombus is difficult. A thrombus should shrink in response to thrombolytic therapy.

## Endocarditis (Figs. 129 and 130)

- ▶ **Clinical manifestations:** significant general malaise
- ▶ **Diagnosis:**
  - Known history of valvular heart disease. Do not overlook this diagnosis, especially in patients with artificial valves.
  - Repeated blood cultures; echocardiography; TEE
- ▶ **Sonographic findings:**
  - *Transthoracic echocardiography* (TTE): valvular incompetence; thickened, echogenic valves, possibly with mobile vegetations (difficult to detect by TTE because they are on the side away from the transducer)
  - *Transesophageal echocardiography* (TEE): thickened valves, echogenic mobile vegetations on the valves. Aortic valve vegetations are usually on the aortic side, mitral valve vegetations are usually on the atrial side. It is rare to find vegetations on the tricuspid valve (most common after catheterization and in drug addicts) or pulmonary valve.
- ▶ **Accuracy of sonographic diagnosis:** Valvular vegetations in endocarditis are clearly visualized by TEE but are easily mistaken for fibrotic or thrombotic depos-

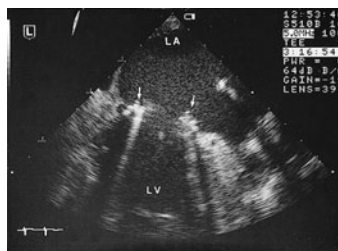

Fig. 129 Mitral valve endocarditis following a mitral valve replacement. The valve displays echogenic margins and club-like expansion (arrow). Note the homogeneous, slightly echogenic internal echo pattern (spontaneous echoes) in the left atrium (LA) due to mitral insufficiency. Fluttering motions of the endocarditic vegetation can be seen with real-time ultrasound. LV = left ventricle

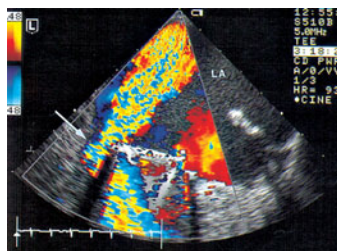


Fig. 130 Mitral valve endocarditis (same patient as in Fig. 129). CDS demonstrates a paravalvular leak (arrow) causing regurgitation into the left atrium (LA)

its. A definitive diagnosis relies on multiple positive blood cultures. Follow-ups showing a regression of the changes in response to antibiotic therapy confirm the diagnosis.

## 6.6 Palpable Masses

### Basic Principles

- **Principal signs and symptoms:** palpable, enlarged lymph nodes, painful or painless (see also p. 107); palpable masses of indeterminate nature. Enlarged lymph nodes may reflect a distant disease process (tumor, infection). The lymphatic pathways shown in Fig. 131 are helpful in locating the source of an infection.

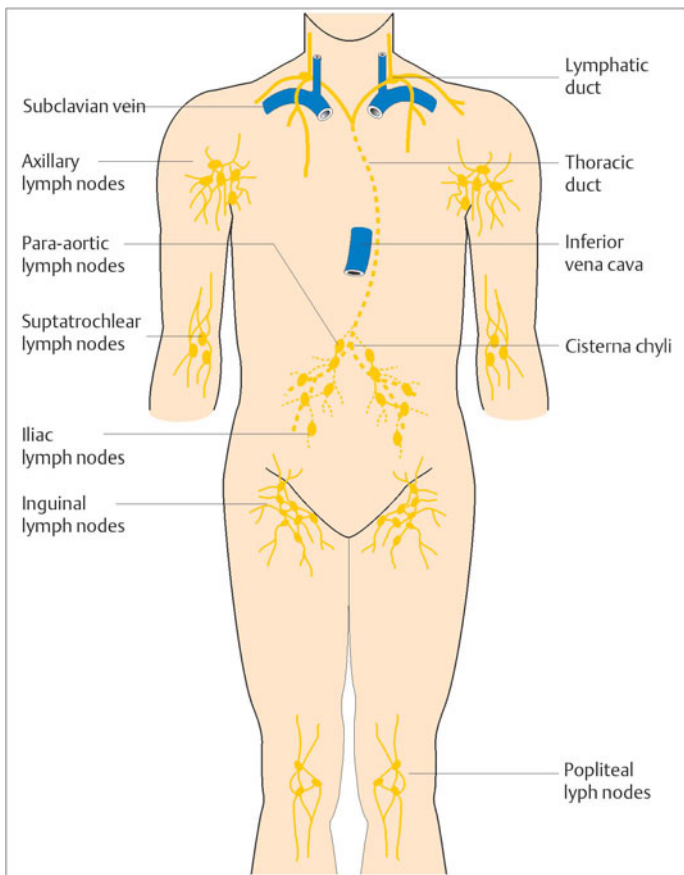


Fig. 131 Lymphatic pathways

- The **differential diagnosis** is reviewed in Table 15, where the possible diagnoses are listed in order of their frequency in the general hospital setting.

**Table 15 · Differential diagnosis of palpable masses**

Diagnosis	Sonographic signs
<b>Generalized</b>	
<i>Common</i>	
High-grade non-Hodgkin lymphoma (p. 101), lymphogranulomatous Hodgkin disease (p. 113)	Multiple hypoechoic masses (p. 113, 114), enlarged lymph nodes, sandwich signs, multifocal involvement
<i>Conditions that cannot be diagnosed with ultrasound</i>	
<i>Common:</i> Leukosis (CLL)	
<i>Rare:</i> Infections (acute infectious lymphocytosis, toxoplasmosis, infectious mononucleosis, AIDS, rubella, histoplasmosis, tropical diseases), systemic diseases (lupus erythematosus, juvenile rheumatoid arthritis, Waldenström macroglobulinemia, lymphosarcomatosis, Felty syndrome, generalized exfoliative dermatitis, reticuloendotheliosis), hereditary diseases	
<b>Regional</b>	
<i>Common</i>	
High-grade lymphoma (p. 101)	
<i>Conditions that cannot be diagnosed with ultrasound</i>	
<i>Common:</i> Erysipelas	
<i>Less common:</i> Lymphangitis	
<i>Rare:</i> Infections (cat-scratch disease, tropical diseases, syphilis, primary focus, anthrax)	
<b>Local</b>	
<i>Common</i>	
Goitrous nodule (p. 102)	
Inguinal, femoral or abdominal hernia (p. 105)	Variable echogenicity, possible peristaltic motion
Inflamed lymph nodes (p. 110)	Enlarged, hypoechoic lymph nodes, elliptical

**Table 15 · Differential diagnosis of palpable masses – continued**

Diagnosis	Sonographic signs
<i>Less common</i>	
Breast tumor (p. 97)	Nonhomogeneous, hypoechoic
Suppurative thyroiditis (p. 103)	Nonhomogeneous, hypoechoic/echogenic
Salivary gland swelling (p. 103)	Usually hypoechoic, elliptical foci
Metastases (p. 105)	Round lesions of varying echogenicity, depending on the primary tumor and stage
Nodular varix (p. 106)	Compressible, anechoic nodule, shows blood flow by CDS
<i>Rare</i>	
Neck cyst (p. 104)	Anechoic mass
Malignant lymphoma (p. 97), lymphogranulomatous Hodgkin disease	Enlarged lymph nodes, sandwich sign
Lipoma, fibroma (p. 107)	Round or elliptical, well-circumscribed mass; fibroma is hypoechoic, lipoma is echogenic

*Conditions that cannot be diagnosed with ultrasound*

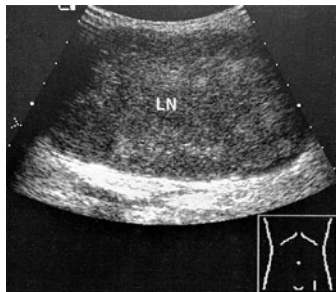
*Less common:* Infections (erysipelas, infectious mononucleosis, tonsillitis), systemic diseases (lymphatic leukemia)

*Rare:* Infections (lymphangitis, vaccination reaction, otitis media, Plaut–Vincent tonsillitis, pseudocroup, pediatric diseases, ulcerative stomatitis, actinomycosis, venereal diseases, tropical diseases), systemic diseases (Waldenström macroglobulinemia, Pancoast tumor, lymphangioma, malignant reticulosis)

### High-Grade Lymphoma, Lymphogranulomatous Hodgkin Disease (Figs. 132 and 133)

► See Enlarged Lymph Nodes, p. 107; Hepatosplenomegaly, p. 148.

■ **Note:** Malignant lymphoma is typically characterized by multifocal involvement and the “sandwich sign” of enlarged lymph nodes.



**Fig. 132** High-grade lymphoma: hypoechoic, sharply circumscribed rounded mass with an echogenic center (LN). The patient presented clinically with palpable inguinal lymph nodes

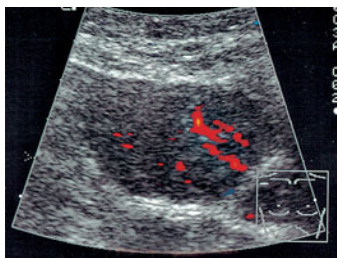

Fig. 133 High-grade lymphoma (same patient as in Fig. 132). CDS shows irregular central blood vessels. The patient presented clinically with a palpable axillary lymph node

### Goitrous Nodule (Figs. 134–137)

- ▶ See also Thyroid Gland, p. 412, and Goiter, Hyper- and Hypothyroidism, p. 179.
- ▶ **Note:** A patient with a goiter may be in such poor general health that the signs and symptoms suggest neoplasia. New swelling may signify a fast-growing thyroid carcinoma, intrathyroid hemorrhage, or the rapid growth of a thyroid nodule. Rapid progression of dyspnea may indicate bleeding into a thyroid carcinoma.
- ▶ **Clinical manifestations:** palpable, nontender swelling in the neck, often visible. There may be dyspnea with stridor serious enough to require intubation. If dyspnea is of long standing, the patient may be in a debilitated condition.
- ▶ **Diagnosis:** History, sonography. If intubation is required, it should be followed by tracheoscopy.
- ▶ **Sonographic findings:**
  - Enlarged thyroid gland, with or without a discrete nodule
  - The trachea may be narrowed or obstructed.

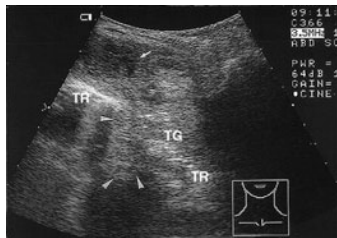


Fig. 134 Goiter with internal bleeding: enlarged, nonhomogeneous thyroid gland (TG) with an irregular anechoic area (arrow, identified as a fresh hemorrhage by CDS). The trachea (TR) is narrowed by the goitrous nodule (arrows). Presumptive diagnosis: thyroid carcinoma. Clinically, there was rapid progression of dyspnea requiring emergency intubation

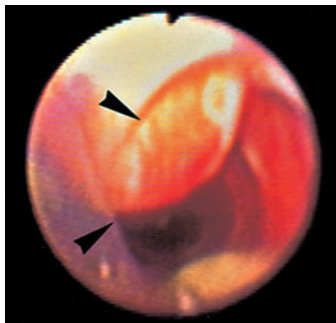


Fig. 135 Endoscopy demonstrates tracheal narrowing by the tumor (same patient as in Fig. 134). A nodule has narrowed the trachea at the end of the endotracheal tube (arrows), preventing successful extubation. Histology → simple goiter with internal bleeding (possibly iatrogenic following catheter placement in the internal jugular vein)

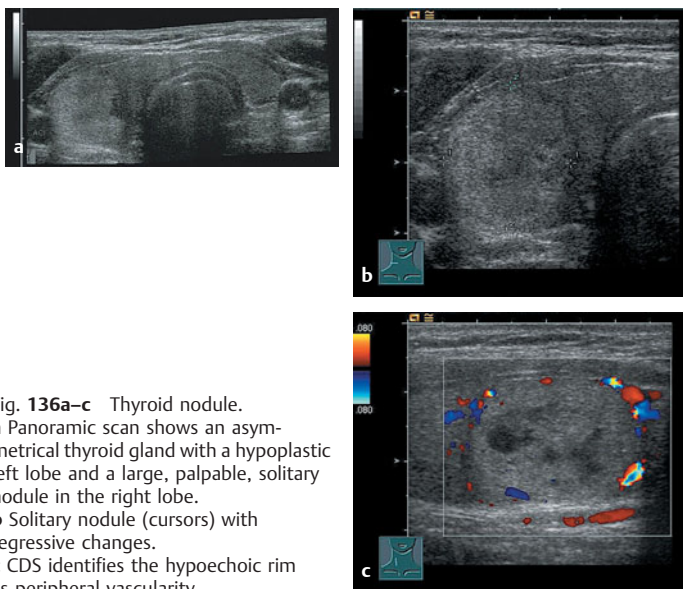
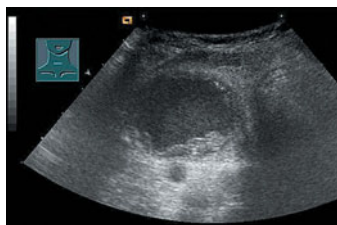


Fig. 136a–c Thyroid nodule.  
**a** Panoramic scan shows an asymmetrical thyroid gland with a hypoplastic left lobe and a large, palpable, solitary nodule in the right lobe.  
**b** Solitary nodule (cursors) with regressive changes.  
**c** CDS identifies the hypochoic rim as peripheral vascularity

Fig. 137 Thyroid nodule with cystic degeneration and internal bleeding. The patient presented clinically with a new, firm, palpable swelling in the neck



- ▶ **Accuracy of sonographic diagnosis:** The sonographic findings are diagnostic in many cases. Additional laboratory parameters are often needed but are not yet available in an emergency setting, making the diagnosis uncertain.

### Suppurative Thyroiditis

- ▶ See Goiter, Hyper- and Hypothyroidism, p. 179.; Thyroid Gland, Abscess, p. 419.

### Salivary Gland Swelling

- ▶ See also Chapter 19, Major Salivary Glands.
- ▶ **Classification:**
  - *Parotitis:*
    - Acute bacterial, viral, or allergic
    - Chronic in systemic diseases, radiation-induced

- **Tumor:**
  - *Benign:* e.g., adenoma, cystadenolymphoma
  - *Malignant:* e.g., acinar cell tumor, mucoepidermoid tumor, carcinoma, malignant lymphoma, metastases (locoregional bronchial carcinoma, melanoma)
- Duct stone
- Trauma
- Cysts
- ▶ **Clinical manifestations:** swelling, fever, hematologic changes. Signs suspicious for a malignant tumor are rapid growth, pain, facial nerve paralysis, cervical lymph node metastases, firm infiltration, skin ulceration, and very limited mobility.
- ▶ **Diagnosis:**
  - History
  - *Palpation:* consistency, mobility
  - Sonography, FNAB
- ▶ **Sonographic findings:**
  - *Anechoic:* cyst
  - *Echogenic:* duct stone
  - *Elliptical foci, usually hypoechoic:*
    - *Malignant:* ill-defined, infiltrating margins; lesions are often multiple
    - *Benign:* well-defined margins
- ▶ **Accuracy of sonographic diagnosis:** The sonographic signs are easily recognized, but an accurate benign–malignant differentiation requires histologic examination. Thus, any salivary gland swelling that is not definitely referable to a known viral infection should be investigated by FNAB, and the aspirate should be sent for both cytologic and histologic evaluation.

### Neck Cyst (Fig. 138)

- ▶ **Clinical manifestations:** Neck cysts become symptomatic only when infected, producing a painful neck swelling associated with palpable lymph nodes, fever, and dysphagia.

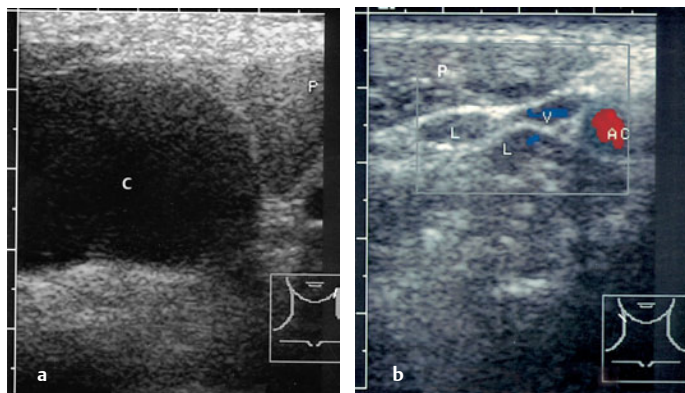


Fig. 138a, b Infected neck cyst (C) and enlarged cervical lymph nodes (L). **a** B-mode image before percutaneous aspiration. **b** CDS shows color pixels in the carotid artery (AC) and jugular vein (V). The cyst was aspirated.

- ▶ **Diagnosis:**
  - History, palpation
  - Sonography
  - **FNAB:** The aspirate is examined cytologically and bacteriologically to identify the infecting organism and determine its antibiotic sensitivity.
- ▶ **Sonographic findings:**
  - Anechoic mass at the border of the sternocleidomastoid muscle
  - **Cyst:** rubbery, compressible; with abscess formation, the contents become more echogenic
- ▶ **Accuracy of sonographic diagnosis:** The cyst is easily detected by sonography, and CDS can positively distinguish it from blood vessels. Neck cysts are rare, and when infected by bacteria they are virtually indistinguishable from a parotid abscess. In these cases the diagnosis can be advanced by aspiration cytology.

### Inguinal, Femoral or Abdominal Hernia (Fig. 139)

- ▶ See also Lower Abdominal Pain, Hernia, p. 75.
- ▶ **Clinical manifestations:** soft, painless bulge of variable size. An incarcerated hernia is painful.
- ▶ **Diagnosis:**
  - History
  - **Palpation:** soft consistency, can usually be pressed down to skin level
  - **Auscultation:** bowel sounds
- ▶ **Sonographic findings:**
  - Structure close to the transducer
  - Variable echogenicity, depending on the contents
  - May have detectable peristalsis
  - With an abdominal hernia, a gap can be seen in the peritoneum.
- ▶ **Accuracy of sonographic diagnosis:** When accessible to ultrasound scanning, the hernia itself can be clearly visualized. In the absence of peristalsis, hernias may be mistaken for lymph nodes or tumors, but the clinical findings will suggest the correct diagnosis.

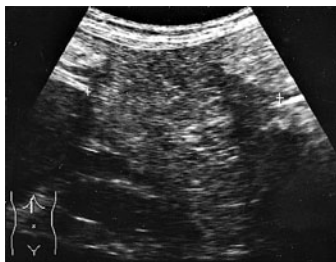
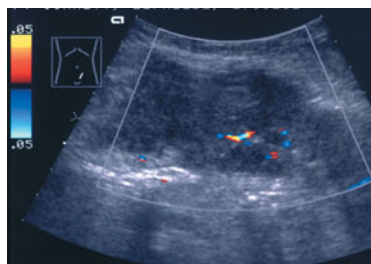
Fig. 139 Abdominal hernia: hypoechoic, palpable rounded mass (cursors, marking the gap in the peritoneum)

### Metastases (Fig. 140)

- ▶ **Clinical manifestations:** complaints relating to the primary tumor. Symptoms may be caused by mass effects such as superior and inferior vena cava syndrome (see p. 122).
- ▶ **Diagnosis:** sonography; FNAB: cytology aids in locating the primary tumor. Other modalities that can aid the search for an occult primary tumor are chest radiography and fluoroscopy, thoracic and/or abdominal CT, pelvic CT, and endoscopy.

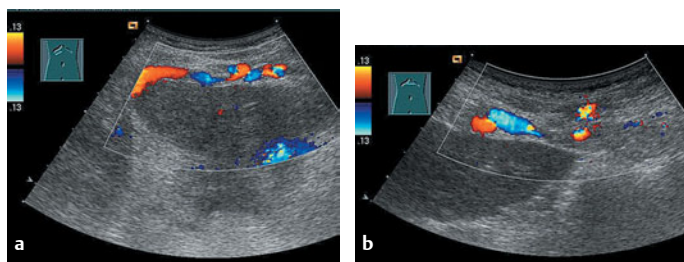


**Fig. 140** Lymph node metastasis: large tumor mass in the left inguinal region; metastasis from an ovarian carcinoma. May be confused with a hernia. The punctate vascularization in the CDS suggests the tumor genesis

- ▶ **Sonographic findings:** Round lesions of varying echogenicity, depending on the primary tumor; in the CDS tumor vascularisation
- ▶ **Accuracy of sonographic diagnosis:** Sonography alone cannot positively distinguish a benign lymph node from a metastasis. Suggestive criteria are illustrated in Figs. 144 and 145 (p. 109) and Table 16 (p. 108).

### Nodular Varix (Fig. 141)

- ▶ **Clinical manifestations:**
  - Livid, localized nodular swelling
  - An infected varix is hard, extremely tender, and surrounded by erythematous skin.
- ▶ **Diagnosis:** compression sonography of the veins of the lower extremity; conventional venography is rarely necessary (see p. 212).
- ▶ **Sonographic findings:**
  - Easily compressible, anechoic nodule
  - CDS demonstrates blood flow. A normal flow velocity excludes thrombosis and an arteriovenous fistula (following left-heart catheterization or dilatation therapy).
- ▶ **Accuracy of sonographic diagnosis:** A varix located close to the transducer can be positively identified.



**Fig. 141a, b** Recanalized umbilical vein, CDS. **a** The vessel is easily traced to the abdominal wall. **b** The palpable, nodular mass beneath the abdominal wall is identified as a varix by CDS. The patient presented clinically with alcoholic cirrhosis of the liver

## Lipoma, Fibroma (Fig. 142)

- ▶ **Clinical manifestations:** swelling, no systemic manifestations
- ▶ **Diagnosis:**
  - History
  - *Palpation:* doughy, mobile, nontender
  - Gradual enlargement may occur; doubts are resolved by FNAB.
- ▶ **Sonographic findings:**
  - Round or elliptical mass
  - Smooth, well-defined margins
  - Hypoechoic rim may form as a result of tumor expansion
  - Mobile
  - Fibroma tends to be hypoechoic.
  - Lipoma tends to be echogenic.
- ▶ **Accuracy of sonographic diagnosis:** Sonography can clearly demonstrate the individual features of these tumors, but it is prudent to evaluate the lesion by FNAB. If the findings are equivocal, a local excision is indicated.

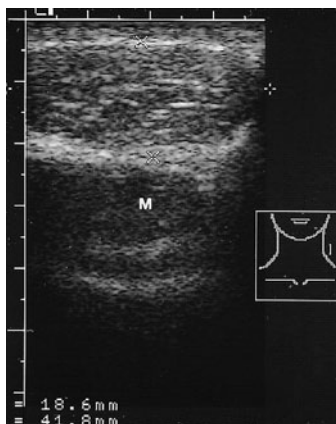


Fig. 142 Lipoma (cursors): rubbery, mobile mass that is hyperechoic to the neck muscles (M)

## 6.7 Enlarged Lymph Nodes

### Basic Principles

- **Note:** The evaluation of enlarged lymph nodes relies on the history, physical examination, and serologic findings. A definitive diagnosis requires histologic examination.
- ▶ **Criteria for evaluating findings:** See Table 16

**Table 16 · Sonographic criteria for the differentiation of lymph nodes**

Location (Fig. 143)	Superficial or deep, visceral or parietal
Size, shape, cortical widening, hilar sign (Fig. 144)	Length/width ratio < 2, length/width ratio $\geq$ 2
Echogenicity (Fig. 145)	Echogenic hilum, hypoechoic cortex
Vascularity	Absent, branching, aberrant vessels

► **Differential diagnosis of benign-malignant lymph nodes:** See Table 17.

**Table 17 · Differential diagnosis of enlarged lymph nodes**

Diagnosis	Sonographic signs
Inflamed lymph nodes (p. 110)	Variable size, L/W ratio $\geq$ 2, prominent echogenic hilum
Lymph node metastases (p. 112)	Variable size, L/W ratio < 2, absent hilar sign, aberrant vessels
Malignant lymphoma (p. 113)	Variable size, L/W ratio often < 2, absent hilar sign, variable pattern of involvement, variable echogenicity, increased vascularity on CDS

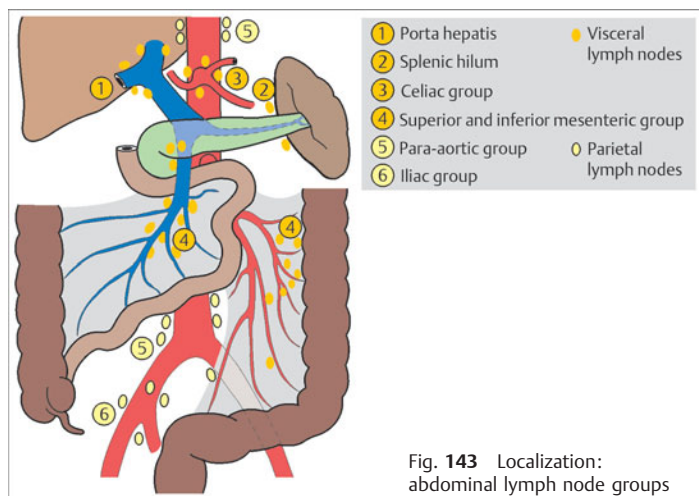


Fig. 143 Localization: abdominal lymph node groups

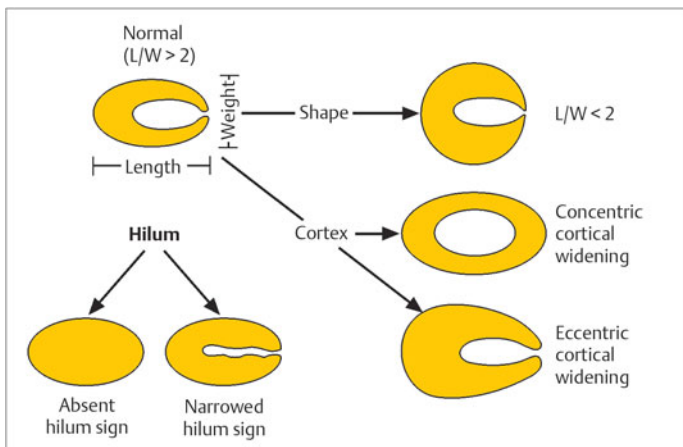


Fig. 144 Sonographic morphology of peripheral lymph nodes (after Vasallo et al.)

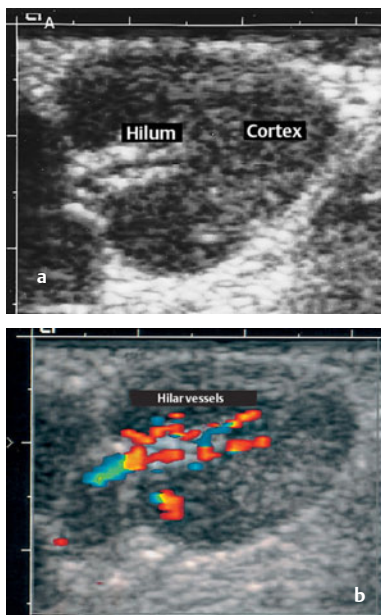


Fig. 145a, b Echogenicity. **a** Enlarged lymph node with an echogenic hilum and hypoechoic cortical parenchyma. **b** The hilar vessels course within the echogenic hilum

- ▶ **Causes:** Table 18 reviews the most frequent causes of enlarged lymph nodes. Ultrasound examination contributes significantly to benign–malignant differentiation.

**Table 18 · Most frequent causes of enlarged lymph nodes**

Inflamed lymph nodes	Metastatic lymph nodes	Malignant lymphoma
Tonsillitis	ENT carcinoma	Low-grade NHL
Pharyngitis	Bronchial carcinoma	High-grade NHL
Mononucleosis	Thyroid carcinoma	Hodgkin disease
Toxoplasmosis	Breast carcinoma	
Rubella	Esophageal carcinoma	
Tuberculosis	Gastric carcinoma	
Mesenteric lymphadenitis	Gallbladder carcinoma	
Ileitis	Colon carcinoma	
Appendicitis	Malignant melanoma	
Diverticulitis	Sarcoma, etc.	
Hepatitis		
Cholecystitis, etc.		

### Inflamed Lymph Nodes

- ▶ **Most frequent causes:** see Table 18.
- ▶ **Clinical manifestations:** The clinical findings often suggest the correct diagnosis (local infection with regional lymphadenopathy) and may include inflammatory signs, tenderness to palpation, and positive serology.
- ▶ **Sonographic diagnosis:** The sonographic criteria for benign–malignant differentiation are helpful in the evaluation of peripheral lymphadenopathy (Figs. 144 and 145).
  - Variable size, L/W ratio  $\geq 2$
  - Prominent echogenic hilum; occasional concentric or eccentric cortical widening
  - Frequent visualization of hilar vessels or a branched vascular pattern

► **Sonographic findings:** See Figs. 146–149.

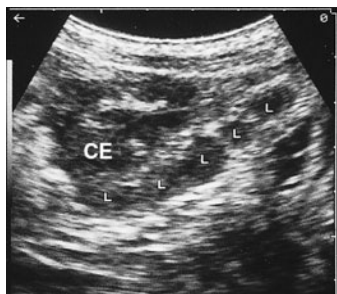

Fig. 146 Multiple paracolic lymph nodes (L) in a patient with ileocecal tuberculosis. CE = cecum

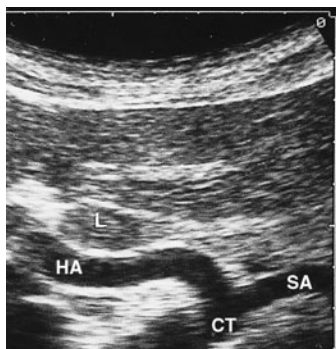


Fig. 147 Solitary hypoechoic lymph node (L) at the porta hepatis in infectious hepatitis. HA = hepatic artery, SA = splenic artery, CT = celiac trunk

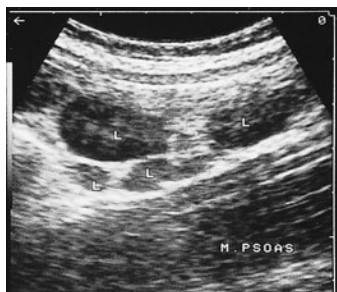

Fig. 148 Multiple large lymph nodes (L) along the right psoas muscle in a patient with mesenteric lymphadenitis

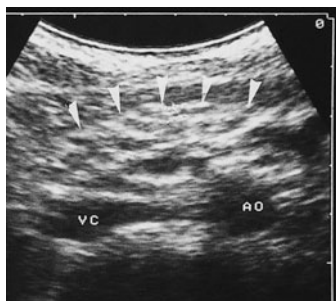


Fig. 149 Small lymph nodes (arrows) produce a speckled echo texture in the mesentery of a patient with gastroenteritis. VC = vena cava, AO = aorta

► **Further studies:**

- In cases with a typical clinical presentation, it is sufficient to provide sonographic follow-up and treatment as needed.
- Asymptomatic cases that do not regress and show rapid growth → lymphadenectomy. There are no definite ultrasound criteria for benign–malignant differentiation.

## Lymph Node Metastases

- ▶ **Most frequent causes:** see Table 18, p. 110.
- ▶ **Clinical manifestations:** frequently suggest the correct diagnosis. Lymph node enlargement has major prognostic implications for tumor staging (TNM), especially in terms of operability (Fig. 150).

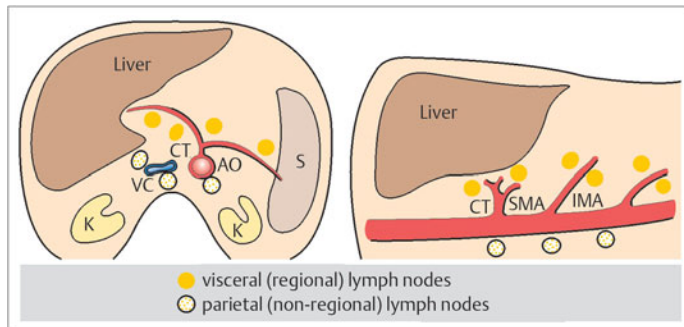


Fig. 150 Schematic representation of regional and “super”-regional lymph node groups that are significant in tumors of the gastrointestinal tract. K = kidney, VC = vena cava, CT = celiac trunk, AO = aorta, S = spleen, SMA = superior mesenteric artery, IMA = inferior mesenteric artery

### ▶ Sonographic diagnosis:

- Ultrasound cannot positively differentiate metastatic lymph nodes from benign lymphadenopathy.
- Variable size (Figs. 151 and 152). The L/W ratio is often  $< 2$ .

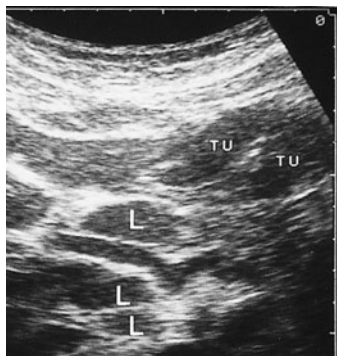


Fig. 151 Multiple enlarged lymph nodes (L) clustered around the celiac trunk in a patient with gastric carcinoma (TU)

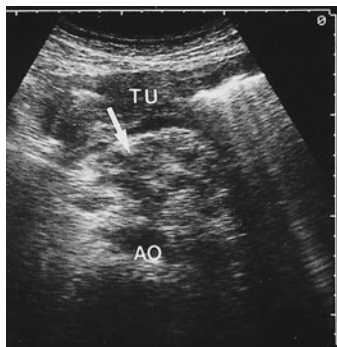


Fig. 152 Speckled pattern of micronodular infiltration (arrows) about the celiac trunk due to regional lymph node metastasis and gastric carcinoma (TU). AO = aorta

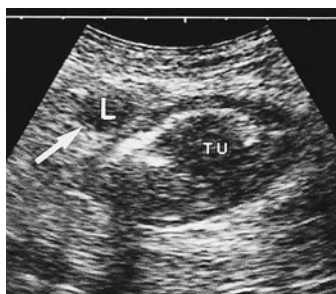


Fig. 153 Small regional lymph node (arrow) bordering the sigmoid colon and intraluminal tumor growth (TU) in a patient with colon carcinoma

- Echogenic hilum is frequently absent (“absent hilum” sign, often found in the lymphatic region draining the primary tumor, Fig. 153)
- CDS frequently shows aberrant vessels in peripheral lymph nodes.

► **Further studies:**

- With a primary malignancy of confirmed histology, it is likely that a nodal diameter > 2 cm signifies metastasis. Doubtful cases require histologic confirmation (if there are therapeutic implications), and a pathology specimen is usually necessary for accurate staging.
- CT is often superior to sonography in the detection of mediastinal, hilar, para-aortic, and iliac nodal metastases. Endosonography is the method of choice for staging gastrointestinal tumors outside the colon and small intestine.

## Malignant Lymphoma

- **Most frequent causes:** see Table 18, p. 110.

**Table 19** · Modified Ann Arbor system for staging malignant lymphoma with primary nodal involvement

Stage	Involvement
I	Involvement of a single lymph node region (I) or a single extralymphatic organ or site (IE)
II1	Involvement of two adjacent lymph node regions above or below the diaphragm (II1) or of a single lymph node region with localized involvement of an extralymphatic organ or site (II1E)
II2	Involvement of two nonadjacent lymph node regions or more than two adjacent lymph node regions above or below the diaphragm (II2) accompanied by localized involvement of extralymphatic organ or site (II2E)
III	Involvement of lymph nodes above or below the diaphragm (III) accompanied by localized involvement of an extralymphatic organ or site (III E) or by involvement of the spleen (IIIS) or both (IIISE)
IV	Lymph node involvement with diffuse or disseminated involvement of one or more extralymphatic organs or tissues

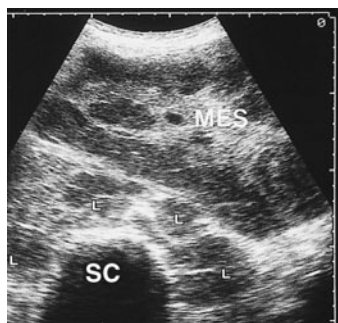

Fig. 154 Marked involvement of the para-aortic lymph nodes (L) and mesentery (MES) by non-Hodgkin lymphoma. SC = spinal column

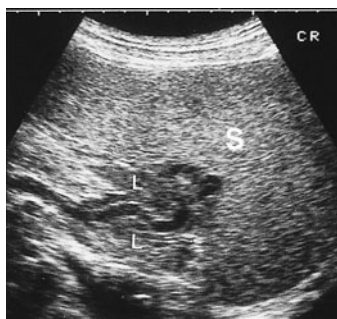

Fig. 155 Confluent hilar lymphomas (L) distributed around the splenic artery in a patient with non-Hodgkin lymphoma. S = spleen

- ▶ **Clinical manifestations:** frequently suggest the correct diagnosis (fever, night sweats, weight loss, generalized lymphadenopathy, blood count, elevated LDH). Staging has major prognostic importance and therapeutic implications (Table 19, Figs. 154 and 155).
- ▶ **Sonographic diagnosis:**
  - Benign and metastatic lymph nodes cannot be positively distinguished on the basis of their sonographic features alone
  - Variable size (Figs. 156 and 157); L/W ratio often  $< 2$

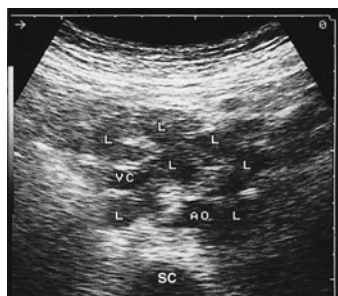

Fig. 156 Multiple small para-aortic and mesenteric lymph nodes (L) in Hodgkin disease. VC = vena cava, AO = aorta, SC = spinal column

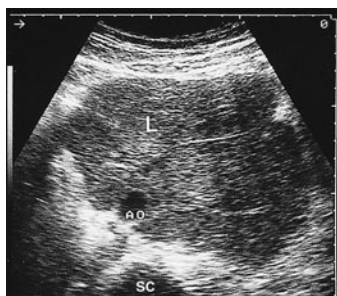

Fig. 157 Large solitary para-aortic lymphoma (L) in a patient with malignant non-Hodgkin lymphoma. AO = aorta, SC = spinal column

- Echogenic hilum is usually absent; variable patterns of involvement with occasional extreme size, often confluent (Fig. 158); multiple foci of variable echogenicity, varying infiltration patterns (see Fig. 159)
- CDS frequently shows increased vascularity.

Fig. 158 Confluent, matted lymphomas (L) encasing the aorta (AO) in a patient with malignant non-Hodgkin lymphoma. SC = spinal column

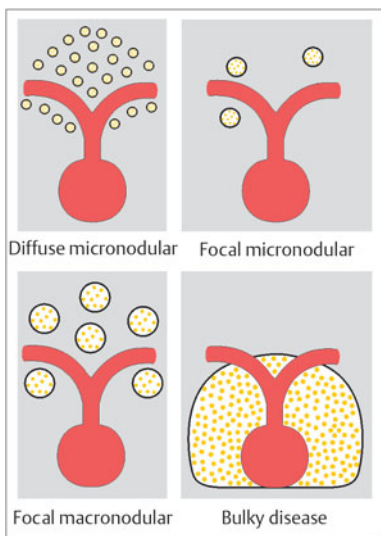
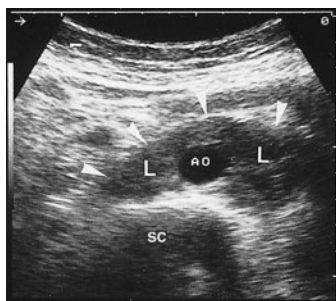


Fig. 159 Sonographic infiltration patterns of abdominal lymph nodes, illustrated in an upper abdominal transverse scan through the origin of the celiac trunk

- **Further studies:** With a confirmed malignant lymphoma, a nodal diameter  $> 2$  cm probably signifies metastasis. Abdominal CT is necessary only if the lesions cannot be evaluated sonographically. A staging laparotomy (Hodgkin disease) is indicated only if it would have therapeutic implications. Response to treatment should be evaluated in sonographic follow-ups.

### Possible Errors of Interpretation

- These errors are numerous and location-dependent:
  - *Neck* → cysts, abscesses
  - *Abdomen* → bowel structures (usually recognized by peristaltic motion, Fig. 160), cysts, abscesses, hematomas (typical clinical presentation)
  - *Groin* → hematomas, hernias, aneurysms

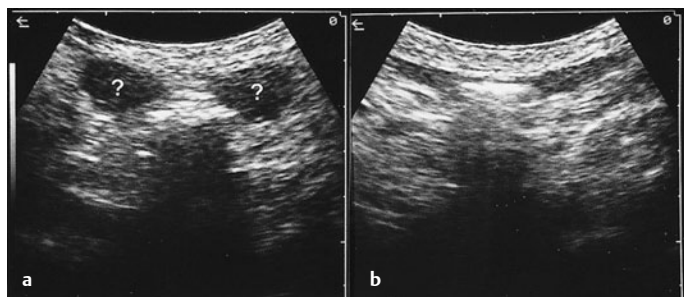


Fig. 160a, b Hypoechoic mesenteric masses suspicious for lymphoma, identified as bowel loops by their peristaltic size changes

► **Further studies in patients with equivocal findings:**

- Doubtful cases should be investigated by FNAB, especially in patients with a suspected abscess or pancreatogenic pseudocysts.
- Aneurysms can be identified by their features on CDS.

## 6.8 Edema

### Basic Principles

- **Principal signs and symptoms:** swollen extremities, dyspnea with pulmonary edema, possible pleural effusion, ascites, and anasarca.
- **Differential diagnosis:** Table 20 lists the possible diagnoses in order of their frequency in the general hospital setting.

**Table 20** · Differential diagnosis of edema

Diagnosis	Sonographic signs
<b>Generalized</b>	
<i>Common</i>	
Right heart failure (p. 117)	Anechoic congested veins, echocardiography: dilatative areas of the right heart
<i>Less common</i>	
Hepatic diseases (pp. 118, 231)	
Edema of pregnancy (p. 118)	Diagnosed by exclusion; normal-appearing venous system, no ascites or pleural effusion

**Table 20 · Differential diagnosis of edema – continued**

Diagnosis	Sonographic signs
<i>Rare</i>	
Myxedema (p. 118)	Atrophic thyroid gland
Acute glomerulonephritis (p. 119)	Enlarged kidneys, echogenic parenchyma, prominent hypoechoic medullary pyramids, indistinct boundary between the renal pelvis and parenchyma

*Conditions that cannot be diagnosed with ultrasound**Common:* Idiopathic edema, premenstrual symptoms*Less common:* Nephrotic syndrome, medications*Rare:* Quincke edema, exudative enteropathy, intestinal lymphangiectasia, Whipple disease, Menetrier syndrome, Cushing syndrome, malabsorption syndrome, beriberi, nutritional edema, mehlährschaden, neonatal hemolytic disease**Localized***Common*

Lower-extremity or pelvic venous thrombosis (p. 120)	Veins are markedly dilated and may contain high-level echoes; incompressible
Deep lower extremity varicose veins (p. 121)	Dilated, compressible veins with abnormal flow patterns
Left heart failure (p. 119)	Pleural effusion; echocardiography: enlarged left ventricle with diminished output

*Rare*

Phlegmasia cerulea dolens (p. 123)	Maximally dilated veins, thrombotic material, absence of flow, incompressible veins
Superior or inferior vena cava syndrome (p. 122)	Dilated vena cava; causative tumor may be visualized

**Conditions that cannot be diagnosed with ultrasound***Common:* Post-thrombotic syndrome*Less common:* Lymphatic forms of edema (elephantiasis nostras [recurrent erysipelas with obliterative lymphangitis]), thermal, mechanical, chemical or bacterial capillary damage*Rare:* Obliterative lymphangiopathy, lymphedema praecox (Meige disease), congenital lymphedema (Milroy disease), osteomyelitis, scleronychia syndrome**Right Heart Failure**

- ▶ See also Ascites, p. 155; Renal Failure, Shock Kidney, p. 124, 136.
- ▶ **Scanning tip:** During scanning of the upper abdomen, the probe can be angled cephalad in the mid-upper abdominal transverse plane to display the enlarged right atrium and the terminal part of the congested inferior vena cava. Generally the enlarged right ventricle can also be visualized.

## Hepatic Diseases

- ▶ See also Renal Failure, Hepatorenal Syndrome, p. 135; Ascites, Hepatic Cirrhosis, p. 156, 239; Liver, Hepatic Cirrhosis, pp. 236.
- ▶ **Scanning tip:** A CDS or power Doppler examination is important for detecting vascular abnormalities such as venous occlusions, portal vein thrombosis, and flow reversal due to portal hypertension.

## Edema of Pregnancy

- ▶ **Clinical manifestations:** generalized edema and excessive weight gain during pregnancy
- ▶ **Diagnosis:** Exclude other causes such as congestive heart failure, drug effects, deep lower extremity venous thrombosis, and renal disease. It is particularly important to recognize impending preeclampsia (proteinuria, blood pressure elevation).
- ▶ **Sonographic findings:**
  - Normal-appearing venous system with good compressibility
  - No fluid collection in anatomical cavities (pleura, intraperitoneal)
  - Normal-appearing kidneys
  - Normal echocardiogram
- ▶ **Accuracy of sonographic diagnosis:** Simple edema of pregnancy is not accessible to sonography. Other causes of edema during pregnancy should be excluded, however, and therefore the role of ultrasound is to facilitate a diagnosis by exclusion.

## Myxedema (Fig. 161)

- ▶ **Clinical manifestations:** edema, deepening of the voice, bradycardia, hypothyroidism
- ▶ **Diagnosis:** elevated TSH, T<sub>3</sub> and T<sub>4</sub> values, TPO antibodies
- ▶ **Sonographic findings:**
  - Small, hypoechoic thyroid gland
  - Possible scars and calcification

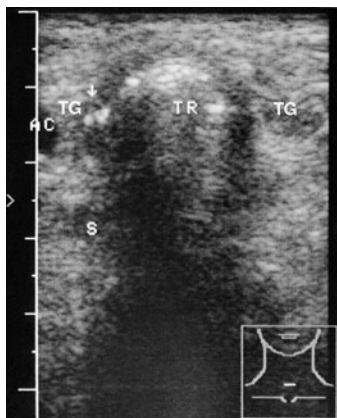


Fig. 161 Myxedema due to complete atrophy of the thyroid gland (TG) with microcalcifications and an acoustic shadow (S)

## Acute Glomerulonephritis

- ▶ See also Kidney, p. 269.
- ▶ **Clinical manifestations:** generalized edema, starting in the periorbital region; possible ascites and pleural effusion; hematuria, proteinuria (ask about foamy urine); hypertension
- ▶ **Diagnosis:**
  - *Urinalysis:* proteinuria, hematuria, possible erythrocyte and leukocyte casts; 24 hour urine: proteinuria may exceed 3 g/day, blood chemistry, hypalbuminemia (< 2.5 g/dL)
  - Abdominal sonography
  - *Chest radiograph:* Pulmonary congestion without cardiomegaly, no dyspnea
  - *Renal biopsy:* Not mandatory, but helpful in establishing the cause
- ▶ **Sonographic findings:**
  - Bilateral renal enlargement
  - Thickened echogenic parenchyma; may appear less echogenic in other acute forms of nephritis, depending on the extent of inflammatory edema
  - Prominent hypoechoic medullary pyramids
  - Narrowing of the central echo complex
  - Possible local tenderness to probe pressure
  - Indistinct boundary between the renal pelvis and parenchyma
  - Possible posterior acoustic shadow, depending on edema
  - Possible perirenal fluid
- ▶ **Accuracy of sonographic diagnosis:** The sonographic changes in acute nephritis are clearly defined. Ultrasound cannot establish the cause of an episode of acute nephritis, however.

## Left Heart Failure (Figs. 162 and 163)

- ▶ See also Pleura, Transudative Effusion, p. 405.
- ▶ **Clinical manifestations:** dyspnea, poor exercise tolerance, possible angina pectoris. Other clinical signs depend on the cause: hypertension, valvular disease, etc.
- ▶ **Diagnosis:**
  - *History, physical examination:* Acute event? Pulmonary edema, dullness? Blood pressure
  - *Laboratory tests:* simple blood count, CK, CKMB, GOT, AP, electrolytes, creatinine, ESR
  - ECG; chest radiograph
  - Abdominal sonography; echocardiography

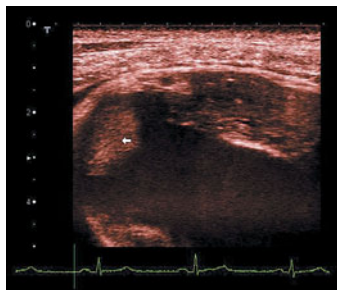


Fig. 162 Left heart failure, CDS: apical left ventricular aneurysm following a myocardial infarction with a mural thrombus (arrow)

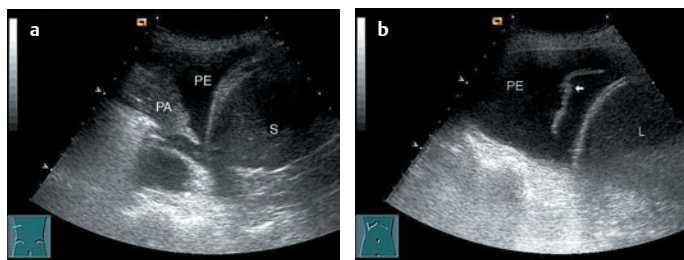


Fig. 163 a, b Pleural effusion. a Pleural effusion (PE) on the left side with pulmonary atelectasis (PA) due to compression. S = spleen. b Pleural effusion (PE) on the right side with a fibrin strand (arrow). L = liver

► **Sonographic findings:**

- *Pleural sonography:* anechoic mass above the diaphragm, often more on the right side than on the left, as a sign of pleural effusion
  - Occasional floating echogenic bands (fibrin strands) in long-standing effusions
  - Echogenic, less mobile, denser-appearing structures (lung tissue) may signify areas of pulmonary atelectasis
- Signs of right heart failure in patients who already have long-standing left heart failure
- *Echocardiography:* enlarged left ventricle with impaired pumping action; a valvular defect may be detectable as the cause; possible signs of hypertensive heart disease (impaired diastolic pumping action, left ventricular hypertrophy)

- **Accuracy of sonographic diagnosis:** Left heart failure can be diagnosed sonographically with 100% accuracy on the basis of pleural sonography and echocardiography. Further studies are needed to establish the cause.

### Venous Thrombosis of the Pelvis and Lower Extremity (Figs. 164 and 165)

- See also Vena Cava and Peripheral Veins, p. 210.
- **Clinical manifestations:** lower extremity swelling, usually confined to one leg; more common on the left side than on the right (the left iliac vein passes below the iliac artery and is compressed); usually painful; minimally pitting edema
- **Diagnosis:**
- *History:* mobility, underlying diseases; ask about symptoms of possible sequelae (e.g., persistent mild cough due to pulmonary embolism, chest pain on respiration)
  - *Laboratory tests:* simple blood count with HCT, coagulation parameters and D-dimers; serum and EDTA blood may be frozen for later coagulation studies
  - *Lower extremity venous sonography:* more details with CDS; the veins of the lower leg are examined in the sitting position
  - Abdominal sonography
  - Conventional venography of the lower extremity may be necessary in equivocal cases.
- ⚠ **Caution:** It is also important to look for an unknown tumor that may have caused the thrombosis.

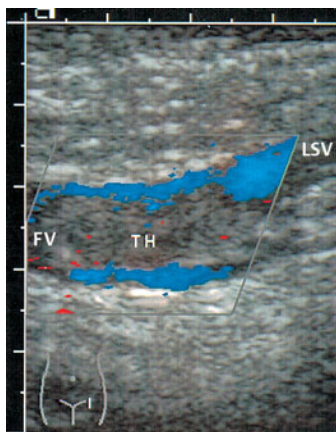


Fig. 164 Thrombosis of the common femoral vein, CDS: partially occlusive thrombus (TH) in the dilated femoral vein (FV) located at the termination of the long saphenous vein (LSV)

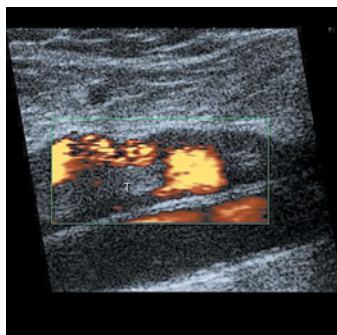


Fig. 165 Partially occlusive thrombus (T) in the popliteal vein. The popliteal artery is posterior to the popliteal vein

#### ► Sonographic findings:

- Markedly dilated veins; the venous caliber is twice that of the accompanying artery (with a fresh thrombosis)
- High-level internal echoes (thrombus) may be noted:
  - Floating or adherent to the vessel wall
  - Appears as an intraluminal flow void or distributed along the wall
  - Affected veins show little or no compressibility.

#### ► Accuracy of sonographic diagnosis:

- Venous sonography is easy to learn, and the upper leg veins can be accurately evaluated by an experienced examiner. Thrombosis in this region can be detected or excluded with a high degree of confidence. Thrombosis in the abdomen, lesser pelvis, and lower leg can be clearly visualized, but it is difficult to distinguish between acute and chronic thrombosis below the knee.
- If there is a high index of clinical suspicion for thrombosis but ultrasound findings are equivocal, conventional venography is indicated (see p. 213). This study may also be inconclusive, however, especially at the pelvic level because of insufficient opacification of the veins.

### Deep Varicose Veins of the Leg (Fig. 166)

- **Clinical manifestations:** increased superficial venous markings; feeling of tension or aching tightness rather than actual pain; swelling of the legs, aggravated by prolonged standing and worse at night
- **Diagnosis:**
  - History, clinical examination
  - Venous sonography; Doppler sonography of the veins (to detect saphenofemoral incompetence)

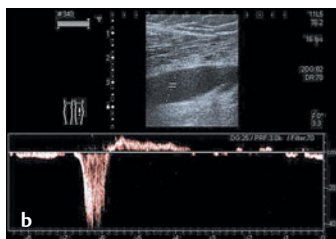
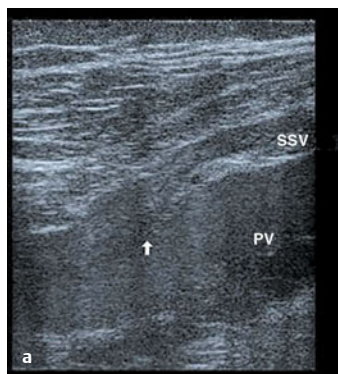


Fig. 166a, b Varicose veins. **a** Dilated popliteal vein (PV) and short saphenous vein (SSV) with high-level internal echoes; termination of the short saphenous vein at the popliteal vein (arrow). **b** Testing of valvular competence and measurement of reflux time

► **Sonographic findings:**

- Dilated veins
- Good compressibility
- Abnormal flow characteristics

► **Accuracy of sonographic diagnosis:** same as in the diagnosis of deep venous thrombosis of the lower extremity

**Superior or Inferior Vena Cava Syndrome (Figs. 167 and 168)**

► See also Liver, Chronic Portal Vein Thrombosis, p. 246; Search for Occult Tumors, displacement, fixation, infiltration, p. 449.

► **Clinical manifestations:** signs of global heart failure due to decreased venous return to the heart: dyspnea, tachycardia, hypotension; edema distal to the caval obstruction

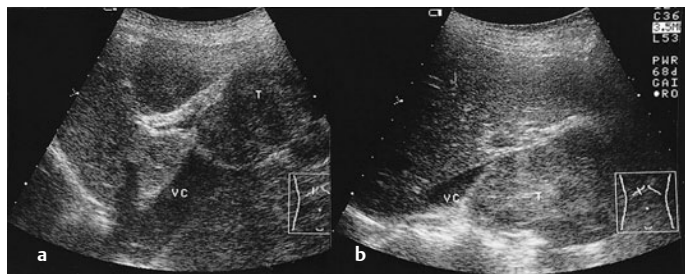


Fig. 167a, b Inferior vena cava syndrome: retroperitoneal sarcoma (T) compressing the vena cava (VC)

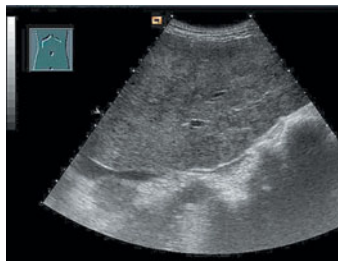


Fig. 168 Compression of the inferior vena cava by hepatic metastases

► **Diagnosis:**

■ **Note:** It is essential to consider the possibility of this diagnosis.

- Abdominal sonography
- Search for an occult tumor

► **Sonographic findings:**

- Dilated vena cava
- A tumor can usually be detected as the cause of the obstruction:
  - Metastasis or primary tumor causing extrinsic compression
  - Intraluminal tumor extension

► **Accuracy of sonographic diagnosis:** Generally this syndrome is easy to diagnose with ultrasound. CT and FNAB should also be carried out to evaluate treatment options (chemotherapy, radiotherapy, etc.).

### *Phlegmasia cerulea dolens*

► **Clinical manifestations:** fulminating form of deep venous thrombosis marked by extremely painful swelling of the extremity (all veins obstructed). The limb is cold and livid as a result of arterial compression.

► **Diagnosis:**

- Clinical examination
- Venous sonography to define the outflow tract and locate the cause of the obstruction

► **Sonographic findings:**

- Maximally dilated veins
- CDS: absence of detectable flow
- Incompressible veins

► **Accuracy of sonographic diagnosis:** The diagnosis is based on the combination of sonographic and clinical findings.

## 6.9 Renal Insufficiency and Acute Renal Failure

### Basic Principles

- ▶ **Principal signs and symptoms:** decrease or absence of urinary excretion, increased solute retention in the blood, possible edema
- ▶ **Classification:** Renal failure is classified as prerenal, due to diminished renal blood flow; intrinsic (renal), caused by renal parenchymal damage; and postrenal, due to blockage of urine flow.
  - Prerenal: fluid deficit
  - *Renal:* glomerulonephritis (Tables 21 and 22) or interstitial nephritis (Table 23)
  - *Postrenal:* Can be positively confirmed or excluded by sonography
  - Acquired
  - Congenital

**Table 21 · Classification of glomerulonephritis**

Acute glomerulonephritis
Rapidly progressive glomerulonephritis
Chronic glomerulonephritis (membranous, membranoproliferative, mesangioproliferative)
Thrombotic microangiopathy
Minimal-change nephritis

**Table 22 · Occurrence of glomerulonephritis**

In systemic diseases	In metabolic diseases
Wegener granulomatosis	Diabetes mellitus (Kimmelstiel–Wilson glomerulosclerosis)
Panarteritis	Amyloidosis
Lupus erythematosus	
Antiglomerular basement membrane disease	

**Table 23 · Classification of interstitial nephritis**

Form of nephritis	Causes
<i>Bacterial nephritis</i>	Bacterial infection
<i>Abacterial nephritis</i>	Drug-induced
	Metabolic
	Obstruction
	Autoimmune
	Other causes: polycystic kidneys, multiple myeloma, sickle cell anemia, Balkan nephritis, radiation nephritis

- **Differential diagnoses:** Listed in Table 24 according to their frequency in the general hospital setting.

**Table 24 · Differential diagnosis of renal insufficiency**

Diagnosis	Sonographic signs
<i>Common</i>	
Fluid deficit (p. 126)	Collapsed vena cava, empty bladder, normal-appearing kidneys
Kimmelstiel–Wilson glomerulosclerosis (p. 128)	Kidneys initially enlarged; signs of chronic glomerulonephritis appear as the disease progresses (see below), followed by signs of chronic pyelonephritis (see below)
Heart failure (p. 127)	Hypoechoic kidney with a thickened parenchymal rim, congested renal vein
<i>Less common</i>	
Chronic pyelonephritis (p. 130)	Small kidney with contour irregularities due to scarring; thin, echogenic parenchyma; calyces are cystic or ectatic
Chronic glomerulonephritis (p. 128)	Diffusely increased echogenicity, loss of corticomedullary differentiation, prominent hypoechoic medullary pyramids
Hydronephrosis (p. 131)	Full bladder, obstructed ureter, dilated pyelocalyceal system, displaced renal sinus, loss of renal parenchyma
Ureteral obstruction (p. 131)	Dilated ureter, possible dilatation of the pyelocalyceal system
Pyonephrosis (p. 132)	Dilated renal collecting system, occasional high-level internal echoes
Analgesic nephropathy (p. 133)	Poor delineation, irregular increase in parenchymal sonodensity, papillary tip calcification
Atrophic kidney (p. 134)	Disproportionately small kidney, parenchymal thinning, increased parenchymal echogenicity
<i>Rare</i>	
Bladder tamponade (p. 134)	Full bladder, often with high-level internal echoes (blood, debris, stone)
Acute glomerulonephritis (p. 135)	Thickened renal cortex, hyperechoic to the prominent medullary pyramids
Hepatorenal syndrome (p. 135)	Normal-appearing kidneys, ascites, signs of hepatic cirrhosis or injury
Shock kidney (p. 136)	Enlarged kidneys, markedly hypoechoic parenchyma, swollen medullary pyramids, narrow renal sinus
Renal lithiasis (p. 137)	Features vary depending on the location of the stone and duration of the disease: <ul style="list-style-type: none"> <li>– echogenic renal pelvis with an acoustic shadow</li> <li>– obstructed renal pelvis, shadowing ureteral stone</li> </ul>
Antiglomerular basement membrane disease (p. 129)	Enlarged, rounded kidney; ill-defined medullary pyramids; nonhomogeneous echogenic parenchyma

**Table 24 · Differential diagnosis of renal insufficiency – continued**

Diagnosis	Sonographic signs
Renal artery embolism (p. 129)	Wedge-shaped echogenic area in the renal parenchyma due to loss of perfusion
Urethral obstruction (p. 131)	Full bladder; extrinsic compression is usually seen
Polycystic kidney (p. 137)	Multiple anechoic masses displacing the renal parenchyma
Renal amyloidosis (p. 137)	Both kidneys enlarged with decreased parenchymal echogenicity
Medullary nephrocalcinosis (p. 138)	Markedly echogenic medullary pyramids, possible acoustic shadowing
Gouty nephropathy (p. 136)	Small, bulging surface with parenchymal thinning, calculi

**Conditions that cannot be diagnosed with ultrasound**

*Rare:* Calcium oxalate nephritis, Fanconi syndrome (congenital defect of tubular transport), amino acid diabetes, renal hypochloremic acidosis, renal hypercalcemia (Fanconi syndrome), potassium loss syndrome (of Albright–Hadorn), salt-losing nephritis (Thorn syndrome), and many others

**Fluid Deficit**

- ▶ **Classification:** prerenal renal failure, due either to a decrease in total fluid volume or to decreased fluid delivery to the kidneys (perfusion deficit)
- ▶ **Clinical manifestations:** decrease or absence of urinary excretion, possible somnolence, possible fever; signs of low-output syndrome due to heart failure
- ▶ **Diagnosis:**
  - *History:* Pay particular attention to the cause of the fluid deficit (decreased intake, increased losses)
  - *Laboratory tests:* simple blood count with hematocrit
  - Sonography
  - Echocardiography to investigate a cardiac etiology
  - A central venous catheter may be used to measure CVP for assessing the fluid deficit. The CVP measurement should be interpreted within the context of the echocardiography findings. Usually there is no need for right heart catheterization to measure the left ventricular filling pressure.
- ▶ **Sonographic findings:**
  - ▣ **Note:** Scanning conditions are usually poor because of tissue dryness.
    - Collapsed vena cava with decreased filling of other veins
    - Empty urinary bladder
    - Renal morphology appears normal on ultrasound.
    - *Echocardiography:* empty, hyperactive cardiac ventricle due to volume deficit. Pumping action may be impaired even with a dilated ventricle (forward failure; in this case the veins are generally congested and the renal parenchyma is swollen).
- ▶ **Accuracy of sonographic diagnosis:** The sonographic signs of the fluid deficit are unmistakable. The resumption of diuresis after fluid loading is confirmatory.

**Heart Failure with Low-Output Syndrome (Figs. 169–171)**

- ▶ See also Shock Kidney, p. 136; Ascites, Right Heart Failure, p. 160; Edema, Left Heart Failure, p. 119; Hepatosplenomegaly, Cardiac Inflow Stasis, p. 149.
- **Note:** The effects of cardiac failure are twofold: a decreased arterial supply to the organs (with a potential for anuria) and reflux leading to the venous engorgement of organs (resulting in pleural effusion and eventual ascites). The organic changes can be detected sonographically.

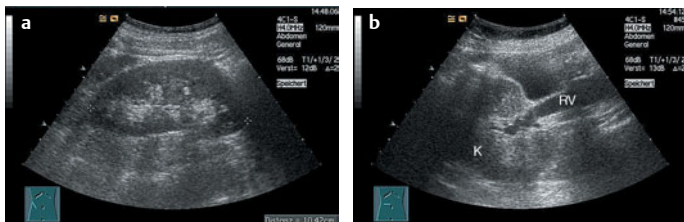


Fig. 169a, b Sonographic renal changes in low-output syndrome. **a** Hypoechoic right kidney with a thickened parenchymal rim. The patient presented clinically with acute anuria, an empty bladder, and mildly elevated creatinine. **b** The renal vein (RV) is congested. Renal vein thrombosis was excluded by duplex sonography

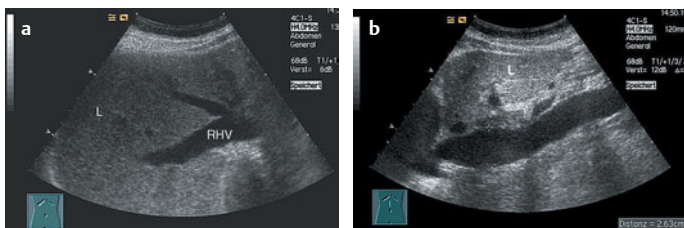


Fig. 170a, b Sonographic liver changes in low-output syndrome. **a** Diffusely hypoechoic liver with obstructed hepatic veins. The patient presented clinically with extremely high transaminase levels. L = right lobe of liver, RHV = right hepatic vein. **b** Posterior to the liver (L) is the strongly congested vena cava (cursors), which is dilated to 2.6 cm

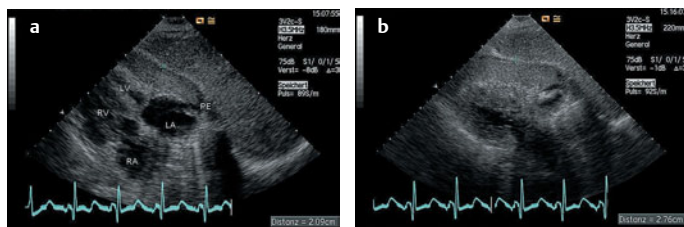


Fig. 171a, b Pericardial effusion (PE) impairs ventricular filling, causing a global reduction of cardiac output. **a** Echogenic bolus-like mass in the pericardial sac (cursors) is consistent with hemopericardium. The heart shows very little ventricular filling with prominent atria and tricuspid valve regurgitation. LA = left atrium, RA = right atrium, LV = left ventricle, RV = right ventricle. **b** Echogenic pericardial effusion (cursors: 2.76 cm). The patient presented clinically with impending ventricular tamponade in a setting of myocardial infarction with pericarditis

### Kimmelstiel–Wilson Glomerulosclerosis

- ▶ See also Kidney, Diabetic Nephropathy, p. 269, 270.
- ▶ **Clinical manifestations:** long-standing diabetes mellitus, hypertension. The disease eventually progresses to terminal renal failure requiring dialysis.
- ▶ **Diagnosis:**
  - *Laboratory tests:* 24 hour urine, measurement of total protein excretion; increased solute retention (creatinine, urea)
  - Sonography
  - *Percutaneous biopsy:* rarely necessary (histology: diffuse, exudative and nodular changes; in end-stage glomerulosclerosis, the underlying disease can no longer be determined histologically)
- ▶ **Sonographic findings:** bilateral changes:
  - Initially, hyperfiltration with enlarged kidneys
  - With progression, signs of chronic glomerulonephritis:
    - Echogenic parenchyma
    - Prominent hypoechoic medullary pyramids
    - Loss of parenchyma
  - Possible signs of chronic pyelonephritis:
    - Scars (echogenic parenchymal retraction)
    - Abscesses
    - Papillary necrosis
    - Papillary calcifications
- ▶ **Accuracy of sonographic diagnosis:** Under favorable scanning conditions, the sonographic signs are conclusive. When the underlying diabetes is known, the diagnosis can be established by ultrasound and no further tests are needed. Generally there is no need for renal biopsy.

### Chronic Glomerulonephritis

- ▶ See also Kidney, p. 270.
- ▶ **Clinical manifestations:** insidious onset with peripheral edema, followed later by hypertension and impaired renal function

- ▶ **Diagnosis:**
  - *Urinalysis.* 24 hour urine collection: nonselective proteinuria, microhematuria, possible erythrocyturia, possible red-cell and white-cell casts (which confirm glomerular disease), also hyaline and granular cysts
  - *Laboratory findings:* dysproteinuria, hyperlipidemia
  - Sonography with follow-up
  - *Renal biopsy:* histologic detection and differentiation (histology shows leukocytic infiltration, hyaline deposition, sclerosis, fibrosis, and tubular atrophy). Renal biopsy is unnecessary when overall findings suggest a minimal lesion (good general health, normal filtration rate, acellular urinary sediment, normal blood pressure).
- ▶ **Sonographic findings:** The sonographic findings are uniform, regardless of the cause of the glomerulonephritis. The end stage cannot be differentiated even by histologic examination. Sonographic findings may remain essentially normal for some time (at least with regard to renal size), and sonographic abnormalities are found only with the onset of renal failure and significantly elevated creatinine levels (look for subtle changes).
  - Diffuse increase in echogenicity
  - Loss of corticomedullary differentiation
  - Prominent hypoechoic medullary pyramids
  - Bilateral small kidneys with a homogeneous echo pattern
- ▶ **Accuracy of sonographic diagnosis:** The sonographic findings in later stages are unequivocal, but the cause cannot be determined.

### Antiglomerular Basement Membrane Disease

---

- ▶ **Clinical manifestations:** hemoptysis in cases with pulmonary involvement and consolidation; microcytic anemia; progressive renal failure
- ▶ **Diagnosis:**
  - History and physical examination, including inspection of the pharynx
  - *Urinalysis:* erythrocyturia and proteinuria
  - *Chest radiograph:* specific changes
  - *Antibody detection:* detection of antiglomerular basement membrane antibodies in the blood (even in emergency cases); renal biopsy for detection of antiglomerular basement membrane antibodies by fluorescent microscopy. (In Wegener granulomatosis, by contrast, antineutrophilic cytoplasmic antibodies [C-ANCA] are positive in only 88% of patients with active disease, and in up to 44% of patients during the remission phase.)
- ▶ **Sonographic findings:**
  - Enlarged, rounded kidney
  - Ill-defined medullary pyramids
  - Nonhomogeneous, echogenic parenchymal pattern
- ▶ **Accuracy of sonographic diagnosis:** The signs of acute renal failure are easily recognized with ultrasound, but their cause cannot be determined. An etiologic diagnosis requires additional tests (so that the patient can be referred as soon as possible for antibody elimination therapy such as plasmapheresis).

### Renal Artery Embolism (Figs. 172–174)

---

- ▶ See also Upper Abdominal Pain, Renal Infarction, p. 73; Kidney, Renal atrophy due to vascular occlusive disease, p. 270; Vascular Scars, p. 280.

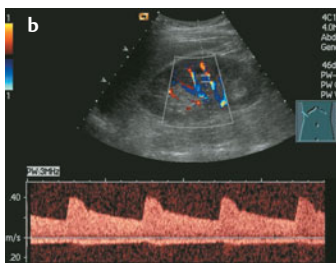
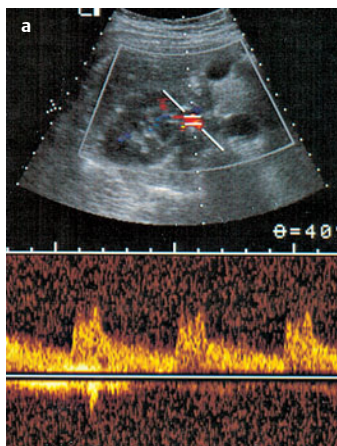


Fig. 172a, b Exclusion of renal artery embolism. **a** Transverse scan of the renal artery. Doppler demonstrates normal flow in the renal artery as it enters the renal hilum. **b** Longitudinal scan of the kidney. Doppler signals from the segmental arteries also show no evidence of renal artery embolism

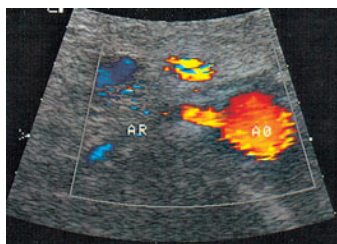

Fig. 173 Normal flow pattern in the proximal right renal artery

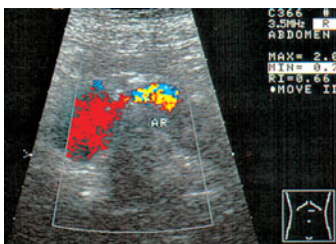


Fig. 174 Proximal stenosis of the left renal artery (RA)

- ▶ **Occurrence:** Renal artery embolism is probably not an extremely rare condition. Etiologically, renal artery embolism due to cholesterol crystals should be considered in addition to cardiac arrhythmias (e.g., absolute arrhythmia in atrial fibrillation).
- ▶ **Sonographic diagnosis:** CDS can advance the diagnosis. Ultrasound contrast agents are helpful in defining the renal arteries and delineating the perfusion defect in the renal tissue.

### Chronic Pyelonephritis

- ▶ See also Kidney, p. 271.
- ▶ **Clinical manifestations:** nycturia and other nonspecific micturition problems; progressive renal insufficiency with lethargy, decreased exercise tolerance, fatigue, anemia, and visual deterioration; hypertension. An acute exacerbation of pyelonephritis is marked by local tenderness to pressure.
- ▶ **Diagnosis:**
  - **History:** recurrent episodes of pyelonephritis, history of early childhood diseases, known voiding problems (e.g., previous bedwetting, ureterocele)

- *Urinalysis*: bacteriuria; the causative organism should be identified and tested for antibiotic sensitivity; leukocyturia with white-cell casts, proteinuria; creatinine clearance in 24 hour urine
  - *Laboratory tests*: CRP, simple blood count, electrolytes, creatinine, uric acid, urea, glucose
  - Sonography
  - High-quality scans obviate the need for further tests such as CT, plain radiographs, or intravenous pyelography (IVP).
- ▶ **Sonographic findings:**
- Small kidney
  - Changes usually limited to one side
  - Circumscribed thinning and increased echogenicity of the parenchymal rim
  - Irregular renal surface with areas of scar retraction (differential diagnosis: previous renal infarction, resection and nephrostomy, tuberculosis)
  - Calyceal cysts or ectasia
  - Frequent calcifications
  - *End stage*: Shrunken, atrophic kidney
- ▶ **Accuracy of sonographic diagnosis:** Typical sonographic signs with circumscribed parenchymal changes provide a reasonably high degree of confidence. Calyceal cysts confirm the diagnosis.

### Hydronephrosis

- ▶ See also Urogenital Organs, Obstructive pyelocalyceal ectasia, p. 380, 382.
- ▶ **Clinical manifestations:** possible flank tenderness, slowly progressive decline in renal function.
- ▶ **Diagnosis:**
- *History*: Ask about underlying diseases that may be associated with outflow obstruction, bladder dysfunction, or bladder atony.
  - Sonography
- ▶ **Sonographic findings:**
- Full urinary bladder in patients with bladder dysfunction
  - Obstructed ureter
  - Outflow obstruction may be detectable in the ureter, due to an intraluminal stone or extrinsic compression by a tumor/metastasis or lymph node.
  - Dilated pyelocalyceal system
  - Displaced renal sinus
  - Loss of renal parenchyma
- ▶ **Accuracy of sonographic diagnosis:** An obstruction can be detected sonographically with up to 98% confidence, but the precise cause cannot always be determined.

### Ureteral Obstruction (Fig. 175)

- ▶ See also Upper Abdominal Pain, Renal Colic, p. 65.
- ▶ **Clinical manifestations:** colicky flank pain, oligo- or anuria. With an intermittent obstruction, intermittent polyuria may occur. With a long-standing obstruction and reflux, the loss of renal parenchyma leads to renal insufficiency with increased solute retention.
- ▶ **Diagnosis:**
- *Laboratory tests*: complete blood count, creatinine, electrolytes, urea and uric acid

- **Urinalysis:** bacteriuria, leukocyturia (with infection), hematuria (with stone or tumor), crystals
  - Sonography
  - The diagnostic workup may include IVP and CT
- Caution:** IVP should be used with caution in renal insufficiency.

► **Sonographic findings:**

- Ureteral dilatation or obstruction
- Possible dilatation of the pyelocalyceal system
- Degree of obstruction can be graded based on the extent of the changes (see p. 382)
- Intraluminal obstruction by a stone, pus, clot, or tumor
- Extrinsic compression by a tumor, metastasis, retroperitoneal fibrosis (Ormond disease), or malignant lymphoma
- An empty bladder is seen only with bilateral obstruction (rare).

- **Accuracy of sonographic diagnosis:** The sonographic diagnosis is very accurate (almost 100%) in cases where the renal collecting system has also become dilated (necessary for renal insufficiency to occur). Frequently the cause of the obstruction cannot be identified. Because the ureter is retroperitoneal, it is often difficult to visualize and its course can be traced only when it is dilated. If a high ureteral obstruction is suspected but the cause is not seen on ultrasound, the condition may be confused with fibrolipomatosis or small peripelvic cysts.

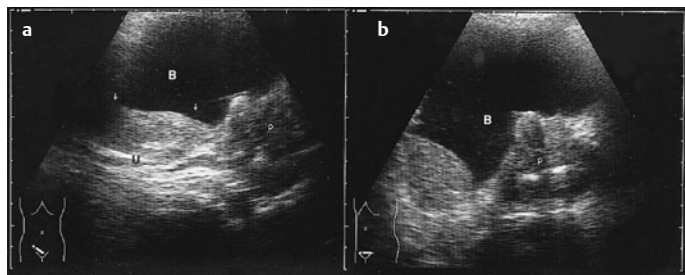


Fig. 175a, b Prostatic carcinoma in two planes. The prostate (P) has an irregular shape and a nonhomogeneous internal echo pattern. It has indented the bladder (B), leading to outflow obstruction and the collection of sludge (arrows). The ureter (U) is compressed and obstructed

### Pyonephrosis (Fig. 176)

- See also Kidney, Chronic pyelonephritis, p. 271; Infected obstruction, p. 286.
- **Clinical manifestations:** long history of lethargy, urinary tract infection, and fever. The systemic manifestations are usually severe, ranging to sepsis.
- **Diagnosis:**
  - **Laboratory tests:** blood chemistry, ESR; bacteriologic testing of urinary sediment; identify the causal organism and determine its antibiotic sensitivity
  - Sonography
  - Ultrasound-guided aspiration and drainage of the pus; necessary when outflow obstruction is present

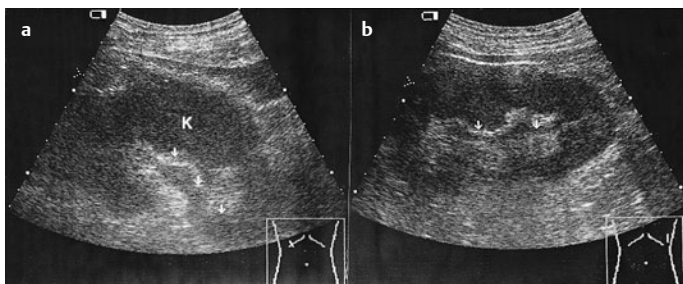


Fig. 176a, b Pyonephrosis: relatively hypoechoic renal parenchyma (K). The renal pelvis is played open, and the renal collecting system (arrows in right image) is dilated into the proximal ureter (arrows in left image) and filled with high-level echoes (pus). **a** Transverse scan, **b** longitudinal scan. Clinical presentation: young male with diabetes mellitus

► **Sonographic findings:**

- Dilated renal collecting system
- Occasional high-level internal echoes representing pus or debris

► **Accuracy of sonographic diagnosis:** Ultrasound suggests the correct diagnosis, which can be established by percutaneous aspiration biopsy. The therapeutic response and sonographic follow-ups also confirm the diagnosis.

### Analgesic Nephropathy

► See also Kidney, p. 271.

► **Clinical manifestations:** diffuse pattern of complaints with pain, mental abnormalities, possible colicky abdominal pain (due to the passage of necrotic papillary tips), and dysuria. Slowly progressive renal insufficiency usually establishes the diagnosis. Pathogenic mechanism: analgesics compromise the blood supply to the kidneys.

► **Diagnosis:**

- **History:** Most patients do not give a history of heavy analgesic use, partly because they do not appreciate its significance. Careful questioning is essential
- **Urinalysis:** mild proteinuria, microhematuria, sterile leukocyturia. Salt loss > 30 mmol/day on a salt-free diet, renal tubular acidosis. Metabolites of phenacetin (paracetamol, *N*-acetyl-*p*-aminophenol) are detectable in the urine.
- **Blood chemistry:** elevated creatinine level, anemia (due also to gastrointestinal blood loss)
- **Sonography:** May also be used to direct percutaneous biopsy
- Exclude diabetic nephropathy, sickle cell anemia, renal tuberculosis, and acute pyelonephritis.

► **Sonographic findings:**

- Poor delineation
- Irregular increase in parenchymal echogenicity
- Ringlike calcifications at the tips of the papillae
- Secondary cysts

► **Note:** The changes begin at the papillary tips and spread toward the cortex. Papillary tip necrosis may also occur in chronic pyelonephritis, diabetes mellitus, sickle cell anemia, and obstructive uropathy.

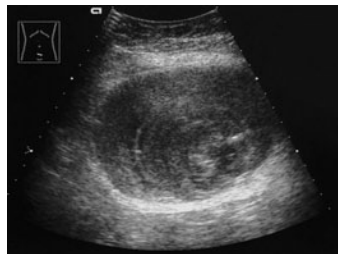
- ▶ **Accuracy of sonographic diagnosis:** The sonographic detection of papillary tip necrosis makes a diagnosis of analgesic nephropathy very likely. A known history of analgesic abuse is considered to establish the diagnosis.

### Atrophic Kidney

- ▶ See also Renal Artery Embolism, p. 129; Kidney, Renal atrophy due to vascular occlusive disease, p. 270.
- ▶ **Classification:**
  - *Unilateral:* chronic pyelonephritis, renal artery stenosis, long-standing renal vein thrombosis. The differential diagnosis includes hypoplastic kidney.
  - *Bilateral:* chronic glomerulonephritis, diabetic nephropathy, nephrosclerosis, other systemic diseases; less commonly, bilateral chronic pyelonephritis
- ▶ **Clinical manifestations:** end stage of chronic nephritis with renal insufficiency; often rapid fatigability, poor exercise tolerance, dyspnea with pleural effusion and edema, anemia. Dialysis is necessary in bilateral cases.
- ▶ **Diagnosis:**
  - History
  - *Laboratory tests:* simple blood count; urine culture and urinary sediment, 24 hour urine, creatinine: and creatinine clearance
  - Sonography
- ▶ **Sonographic findings:**
  - Disproportionately small kidneys. (When only one kidney is affected, there is generally compensatory enlargement of the contralateral kidney.)
  - Parenchymal thinning
  - Increased parenchymal echogenicity
  - Poor organ delineation. Occasionally the kidney can be identified only by the presence of cortical cysts (cystic degeneration of medullary pyramids or secondary retention cysts).
- ▶ **Accuracy of sonographic diagnosis:** The diagnosis is considered to be established if the kidney can be visualized and is disproportionately small. There is no need for percutaneous biopsy because histologic confirmation is unnecessary in end-stage disease.

### Bladder Tamponade (Fig. 177)

- ▶ **Clinical manifestations:** anuria, possible lower abdominal pain and tenderness. Colicky flank pain occurs in long-standing cases with stasis.
- ▶ **Diagnosis:**
  - *History and examination:* palpable lower abdominal mass (distended bladder). Ask about a precipitating event (renal biopsy, bladder aspiration, etc.).



**Fig. 177** Bladder tamponade. A layered, hypoechoic mass (clotted blood) is visible within the bladder lumen following the insertion of a suprapubic catheter

- *Sonography*: May also be used to direct percutaneous aspiration
- Cystoscopy
- ▶ **Sonographic findings:**
  - Full urinary bladder
  - Frequent high-level internal echoes from clotted blood (e.g., after bladder aspiration, catheterism), debris, stone, or tumor
- ▶ **Accuracy of sonographic diagnosis:** Bladder tamponade can be confidently diagnosed with ultrasound. Other tests are necessary only to investigate the cause.

### Acute Glomerulonephritis

- ▶ See Edema, p. 119; and Kidney, p. 269.

### Hepatorenal Syndrome (Fig. 178)

- ▶ **Clinical manifestations:** known hepatic cirrhosis, usually decompensated with ascites and gastrointestinal bleeding; hypertension; progressive renal insufficiency ranging to anuria. May be precipitated by forced diuresis, percutaneous aspiration of ascites, bleeding, sepsis, or potentially nephrotoxic drugs.
- ▶ **Diagnosis:**
  - *History and clinical findings:* basic neurological staging examination (flapping tremor, writing test, connect-the-numbers test)
  - Laboratory tests
  - Sonography
  - *Esophagogastroduodenoscopy:* esophageal varices, fundal varices
  - Reasons for impaired renal function are not found: urinalysis normal, IVP normal (and therefore rarely necessary), negative renal biopsy (rarely done)
- ▶ **Sonographic findings:**
  - Free fluid in the abdominal cavity (ascites)
  - Signs of hepatic cirrhosis (see Ascites, p. 155) or other causes of liver cell destruction
  - Both kidneys show normal sonographic features.
- ▶ **Note:** It is important to look for other renal diseases that are independent of the liver disease.
- ▶ **Accuracy of sonographic diagnosis:** The sonographic signs are clear-cut, and the diagnosis is supported by the overall clinical presentation and course. The cause of the syndrome is not precisely known but presumably relates to diminished blood flow.

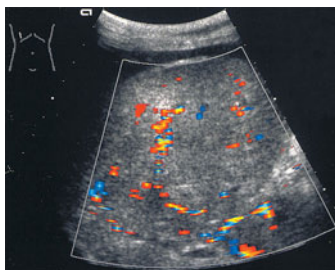


Fig. 178 Acute renal failure in hepatorenal syndrome: hepatic cirrhosis with echogenic areas of liver necrosis and ascites. CDS shows predominantly large-caliber arteries; hepatic veins are not visualized

**Shock Kidney (Fig. 179a)**

- ▶ See also Kidney, Acute Renal Failure, p. 267.
- ▶ **Classification:** Shock kidney is characterized by the development of renal failure due to prerenal causes – traumatic, postoperative, or septic.
- ▶ **Clinical manifestations:** oliguria, anemia, peripheral edema, hypertension, pulmonary edema
- ▶ **Diagnosis:**
  - *History:* may suggest the precipitating cause – volume deficit, cardiogenic shock, sepsis, medications
  - Blood tests and urinalysis
  - Sonography
- ▶ **Sonographic findings:**
  - Enlarged kidneys
  - Markedly hypoechoic parenchyma; distal acoustic shadowing enhancement may occur (depending on the extent of edema)
  - Swollen medullary pyramids
  - Typically, the boundary between the renal pelvis and renal sinus is indistinct.
  - Renal sinus is compressed and narrowed as a result of parenchymal swelling.
- ▶ **Accuracy of sonographic diagnosis:** The findings resemble the features of right heart failure and renal congestion. Sonography can establish the diagnosis in conjunction with clinical findings.

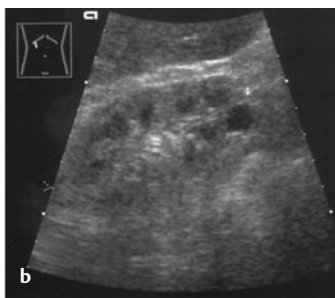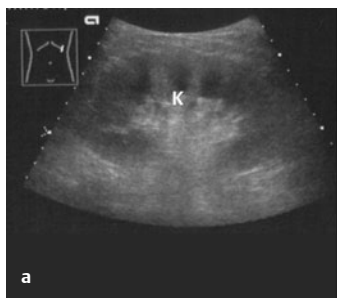


Fig. 179a,b **a** Acute prerenal renal failure in a patient with severe vomiting and alcohol disease. The kidney (K) is markedly enlarged to a longitudinal diameter of 15 cm. The parenchyma is thickened and hypoechoic, with swollen medullary pyramids. **b** Gouty nephropathy; small kidney with elevated echogenicity, swollen pyramids and a secondary cyst (arrow)

**Gouty Nephropathy (Fig. 179b)**

- ▶ **Occurrence, course:**
  - Chronic hyperuricemia
  - Deposition of sodium urate in the pyelocalyceal system
  - Crystalization in the renal tubule and collecting duct
  - Inflammatory processes
  - Development of medullary fibrosis, with fibrosis of the papillary tips
- ▶ **Clinical manifestations:** progressive signs of renal insufficiency, frequent hypertension, frequent pyelonephritis

- ▶ **Diagnosis:**
  - *Laboratory findings:* frequent hyperlipidemia and bacteriuria
  - Sonography
- ▶ **Sonographic findings:**
  - Small kidneys
  - Increased echogenicity
  - Bulging renal surface
  - Parenchymal thinning
  - Calculi
- ▶ **Accuracy of sonographic diagnosis:** Ultrasound is very accurate when laboratory tests show elevated uric acid and other clinical manifestations of gout are present.

### Renal Lithiasis

---

- ▶ See Upper Abdominal Pain, Renal Colic, p. 65; Kidney, Renal calyceal or pelvic stone, p. 288; Urogenital Organs, Urinary stone colic, p. 380.
- **Note:** Renal insufficiency may develop in long-standing cases of lithiasis with recurrent episodes of colic.

### Polycystic Kidney

---

- ▶ See also Kidney, p. 273.
- ▶ **Clinical manifestations:** upper and midabdominal pain, hematuria, hypertension. Recurrent renal colic due to intracystic hemorrhage and clotting, with possible discharge of clots into the collecting system. Recurrent urinary tract infections; progressive renal failure until dialysis is required
- ▶ **Diagnosis:**
  - *Examination, history:* enlarged, palpable kidneys. Familial occurrence; family members should be screened whenever possible
  - Urinalysis
  - Sonography
- ▶ **Sonographic findings:**
  - Multiple anechoic masses (cysts)
  - Cysts are flattened and spaced close together. The renal parenchyma may be greatly thinned.
  - Bilateral involvement
- ▶ **Accuracy of sonographic diagnosis:** The sonographic findings are unequivocal, provided the kidneys can still be identified. If so, there is no need for further testing.

### Renal Amyloidosis

---

- ▶ See also Kidney, p. 269.
- ▶ **Clinical manifestations:** nonspecific proteinuria; symptoms of the underlying disease leading to amyloidosis are predominant.
- ▶ **Diagnosis:**
  - Laboratory examination of the blood and urine
  - Abdominal sonography
  - Ultrasound-guided percutaneous renal biopsy with histologic evaluation
- ▶ **Sonographic findings:**
  - Bilateral renal enlargement
  - Thickened, hypoechoic renal parenchyma
  - Frequent enlargement of other parenchymal organs (e.g., spleen)

- ▶ **Accuracy of sonographic diagnosis:** The sonographic findings are nonspecific. Percutaneous biopsy may confirm the presumptive diagnosis.

### Medullary Nephrocalcinosis

- ▶ See also Kidney, p. 282.
- ▶ **Definition:** variable degree of calcification of the renal medulla (= renal pyramids).
- ▶ **Occurrence:**
  - Analgesic abuse (phenacetin, acetaminophen [paracetamol], aspirin, etc.)
  - Renal tubular acidosis
  - Primary hyperoxaluria
  - Treatment for cystinuria
- ▶ **Clinical manifestations:** progressive renal insufficiency.
- ▶ **Sonographic findings:** markedly echogenic medullary pyramids, which may cast acoustic shadows.

### Urethral Obstruction (Fig. 180)

- ▶ **Clinical manifestations:** urinary retention with a full bladder; lower abdominal pain usually present; flank pain due to reflux
- ▶ **Diagnosis:**
  - *History:* previous surgery, radiotherapy, etc.
  - Sonography
  - Endoscopy or CT if required.
- ▶ **Sonographic findings:**
  - Full urinary bladder
  - In most cases the urethra is obstructed by extrinsic compression from an enlarged prostate or tumor.
- ▶ **Accuracy of sonographic diagnosis:** The urethra itself can rarely be visualized with ultrasound, but abnormalities about the urethra can be demonstrated, particularly with a full bladder.

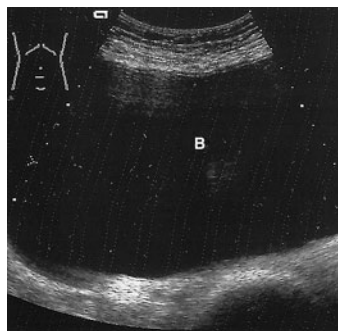


Fig. 180 Massive enlargement of the bladder (B) secondary to ureteral stenosis. The bladder volume is 1482 mL

## 6.10 Jaundice

### Basic Principles

#### ► Principal signs and symptoms:

- Cholestasis with elevated liver values (AP,  $\gamma$ -glutamate transferase [GGT], bilirubin, etc.)
- Yellowish discoloration of the skin (jaundice when bilirubin > 3 mg/dL), pruritus, pale stool, dark urine, fatigue

■ **Note:** Painless jaundice has a malignant etiology in more than 95% of cases.

#### ► Sonographic findings. Particular attention is given to the following aspects:

##### • Size and configuration of the liver:

- Smooth or nodular surface
- Nodular parenchymal changes
- Truncation or displacement of portal vessels
- Increased hepatic echogenicity, visual texture
- Impression of left hepatic lobe by cardiac pulsations

##### • Increased hepatic arterial perfusion (on CDS) indicating cirrhosis

- **Dilated bile ducts:** dilatation due to biliary outflow obstruction caused by increased intraductal pressure (segmental intrahepatic or affecting one half of the lobe → no jaundice). With loss of parenchymal elasticity (as in cirrhosis), very little dilatation of the intrahepatic bile ducts can occur.

#### ► Accuracy of sonographic diagnosis: A parenchymal cause of biliary outflow obstruction can almost always be identified. Ultrasound can also define the level of the obstruction and disclose a lithogenic or malignant cause. Jaundice due to acute hepatitis or hemolysis is not associated with sonographic abnormalities.

#### ► Differential diagnosis: The possible diagnoses are listed in Table 25 in order of their frequency in the general hospital setting.

**Table 25 · Differential diagnosis of jaundice**

Diagnosis	Sonographic signs
<i>Common</i>	
Hepatic or toxic cirrhosis of the liver (p. 236, 238)	
Cholelithiasis (p. 332)	Shadowing stone, possible duct occlusion with prestenotic ductal dilatation
Biliary obstruction or tumor (p. 330)	Dilated bile ducts with possible obstruction of the pancreatic duct; other findings depend on the cause
<i>Less common</i>	
Hepatic tumor (p. 249, 250)	Intrahepatic mass, with or without biliary obstruction; anechoic fluid in the abdominal cavity
Cholangitis (p. 331)	Signs of PSC and inflammation, wall thickening, lymph nodes; causative lesion may be definable (purulent cholangitis, stone, tumor, abscess)

**Table 25 · Differential diagnosis of jaundice – continued**

Diagnosis	Sonographic signs
Fatty liver hepatitis (toxic liver disease, NASH, p. 146)	Enlarged liver, homogeneously increased echogenicity, rounded border, acoustic shadowing
Cholecystitis (p. 147)	
<i>Rare</i>	
Budd-Chiari syndrome (p. 147)	
Secondary biliary cirrhosis (p. 147)	Signs of hepatic cirrhosis, detectable cause of the biliary obstruction
Helminthiasis (ascariasis, p. 331)	Luminal obstruction by ascarids
Papillomatosis (p. 328)	Hypoechoic, immobile intraluminal flow void with ill-defined margins
Caroli syndrome (p. 141)	Cystic dilatation of intrahepatic bile ducts, possible signs of cholangitis, gallstones
Bile duct compression or infiltration (p. 143)	
Biliary atresia (p. 147)	

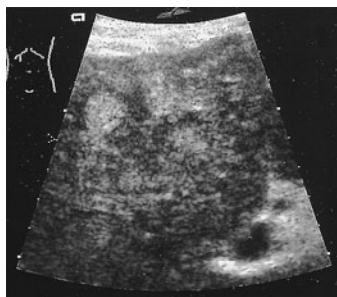**Conditions that cannot be diagnosed with ultrasound**

*Less common:* Epidemic hepatitis, primary biliary hepatic cirrhosis, cholestatic liver disease, juvenile jaundice (Meulengracht disease)

*Rare:* Galactosemia, Dubin–Johnson syndrome, Rotor disease, spherocytic anemia, thalassemia, paroxysmal hemoglobinuria, hemoglobin anomaly, erythrocyte enzyme disorder, autoimmune forms of hemolysis, toxic isoimmune hemolysis, neonatal jaundice, hemolytic disease of the newborn, neonatal infection, congenital hemolysis, reactive hepatitis due to infections, toxic liver damage, Crigler–Najjar disease

**Hepatic or Toxic Hepatic Cirrhosis (Fig. 181)**

- ▶ See also Ascites, Hepatic Cirrhosis, p. 156; Liver, Hepatic Cirrhosis, p. 236; Severe chronic hepatitis with structural change or cirrhosis p. 238.



**Fig. 181** Hepatic cirrhosis: echogenicic necrotic foci. Multiple needle biopsies showed no evidence of tumor

## Cholelithiasis (Figs. 182 and 183)

- See also Upper Abdominal Pain, Biliary Colic, p. 64; Bile Ducts, Gallstones, p. 332; Biliary Cysts, p. 326.

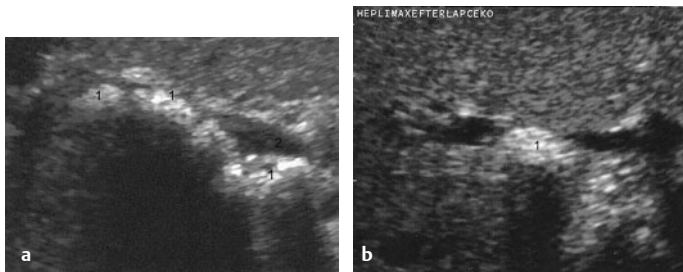


Fig. 182a, b Intrahepatic cholelithiasis. **a** Caroli syndrome: pronounced cholelithiasis (1) with a dilated intrahepatic bile duct (2). **b** Hepatolithiasis

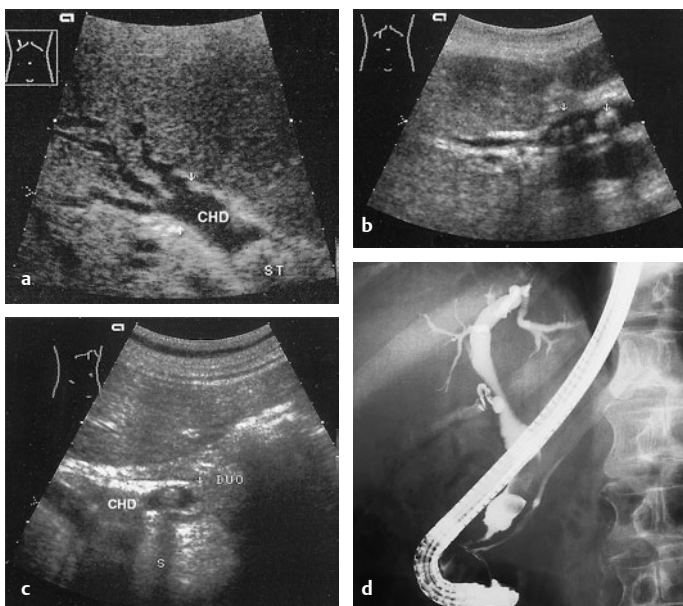


Fig. 183a–d Common duct stone disease (choledocholithiasis). **a** Large occlusive stone (ST) in the common hepatic duct (CHD) with prestenotic ductal dilatation extending into the intrahepatic divisions of the ducts (arrows). **b** Four gallstones (arrows), nonocclusive (normal caliber of intrahepatic duct). **c** Two prepapillary stones with distal shadowing (S). Arrow: papillary region on the posterior wall of the duodenum (DUO). **d** ERCP of the case in **c** demonstrates the two prepapillary stones noted on ultrasound

► **Occurrence:**

- *Intrahepatic* (Fig. 182): Caroli syndrome (cystic dilatation of intrahepatic bile ducts) leads to recurrent episodes of cholangitis with abscess formation and predisposes to lithiasis and other diseases. It must be differentiated from hepatolithiasis.
- *Extrahepatic* (Fig. 183): common hepatic duct, common bile duct, prepapillary

### Biliary Obstruction or Tumor (Fig. 184)

- See also Bile Ducts, Biliary papillomatosis, p. 328; intrahepatic biliary carcinoma, p. 329; Ductal dilatation due to compression or invasion by metastases, p. 143, 145, 329; Anechoic ductal dilatation due to obstructive cholestasis, p. 330.
- **Clinical manifestations:**
  - Painless jaundice, or jaundice with colicky pain
- **Diagnosis:**
  - History
  - *Laboratory findings:* elevated conjugated direct bilirubin
  - Sonography
  - ERCP
  - Percutaneous biopsy is done only if the diagnosis is uncertain, not to confirm a tumor.
- **Sonographic findings:** dilated bile ducts, depending on the site of the obstruction; possible obstruction of the pancreatic duct
  - *Stone* (Fig. 184): relatively echogenic mass that moves with position changes, usually with a partial acoustic shadow (Stones that form intraductally are mostly pigment stones containing little calcium.)
  - *Biliary papillomatosis* (multiple mucus-producing epithelial tumors): hypoechoic, immobile intraluminal voids with ill-defined margins; see also p. 328
  - *Ascariasis:* luminal obstruction by ascarids; see also p. 331
  - *Klatskin tumor:* dilated intrahepatic bile duct near the bifurcation of the hepatic duct and distal, hypoechoic bile duct obstruction with ill-defined margins; see also p. 329
- **Accuracy of sonographic diagnosis:** The dilated bile ducts can be clearly visualized. Occasionally the cause cannot be determined even with further tests and is not definitely established until operative exposure and histologic examination.

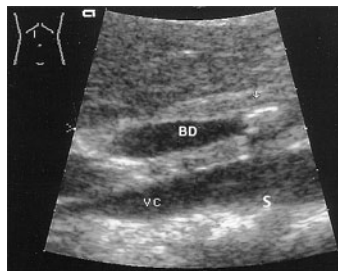


Fig. 184 Large gallstone (arrow; incomplete shadow, S) partially obstructing the bile duct (BD)

### Bile Duct Compression or Infiltration (Figs. 185–190)

- ▶ **Note:** Rarely, jaundice is caused by the compression of bile ducts by lymph nodes, a pseudocyst, duodenal diverticulum, Mirizzi stone, or in Caroli syndrome. The infiltration of bile ducts by an invasive tumor is somewhat more common.
- ▶ **Mirizzi syndrome** (Fig. 185): Morphological variant of the cystic duct, which has a low termination and runs parallel to the hepatic duct. An impacted stone in the cystic duct or gallbladder neck may lead to compression of the hepatic duct. Mirizzi syndrome is marked by chronic biliary tract stenoses due to recurrent episodes of cholangitis. Four grades of severity are distinguished based on the circumference of the common hepatic duct and common bile duct.
- ▶ **Caroli syndrome** (Fig. 182a, p. 141): cystic dilatation of the intrahepatic bile duct, diffuse or localized. Children are predominantly affected and often present with upper abdominal pain and jaundice. Cholangitis, lithiasis, and renal and pancreatic cysts are common. Frequently coexists with congenital periportal hepatic fibrosis. Inspissated bile in the dilated ducts may be mistaken for a tumor.

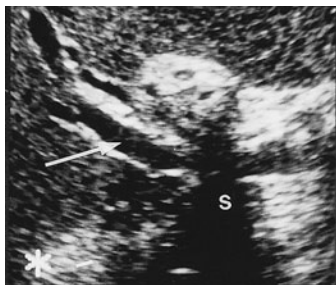

Fig. 185 Mirizzi stone (arrow) with an acoustic shadow (S) causing minimal ductal dilatation; no common duct stone

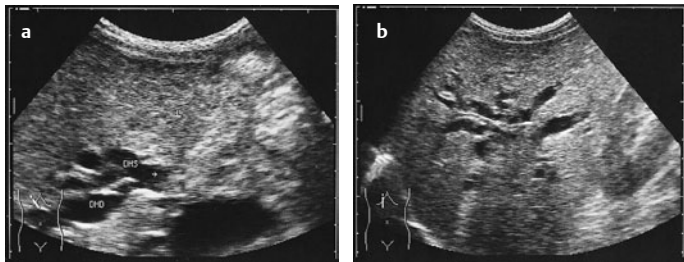


Fig. 186a, b Small lymph node metastases (arrow) compressing the common hepatic duct; dilatation of the right and left duct (DHD, DHS). The hilar ductal caliber is increased, and conspicuous tubular structures are visible in the perihilar parenchyma (b)

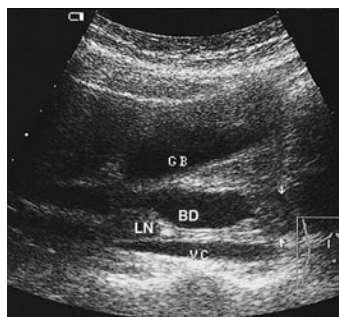


Fig. 187 Compression of the bile duct (BD) by inflamed lymph nodes (LN, arrows). GB = gallbladder, VC = vena cava. Clinical findings raised suspicion of malignant papillary stenosis, prompting operative treatment. Histology showed no malignancy, only inflammation and fibrosis of the papilla with enlarged lymph nodes

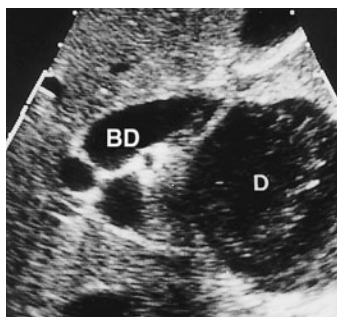


Fig. 188 Compression of the bile duct (BD) by a duodenal diverticulum (D), which could be mistaken for a cyst

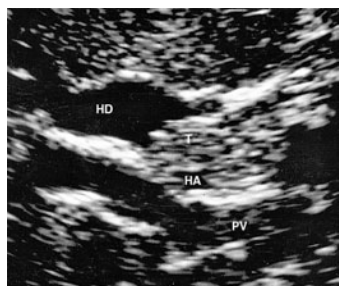


Fig. 189 Truncated duct pattern typical of a malignant tumor. The tumor (T) has infiltrated only the hepatic duct (HD) in the absence of hydrops and has encased the hepatic artery (HA), which is in a typical location. PV = portal vein

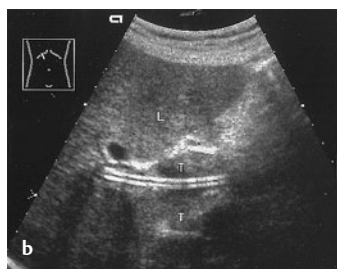
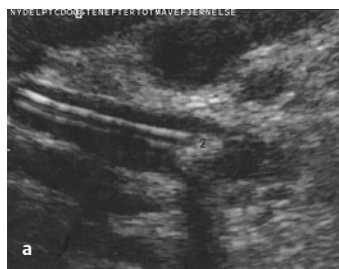
Fig. 190a, b Treatment with a stent. a Stent and stone in the obstructed bile duct. b Stent in the bile duct, which is completely occupied by papillomatous carcinoma

### Hepatic Tumor (Fig. 191)

- ▶ See also Liver, Primary hepatic carcinoma, p. 249; Metastases, p. 250.
- ▶ **Clinical manifestations:** painless jaundice; possible known tumor disease; possible abdominal distension with ascites
  - ▶ **Note:** Painless jaundice is often the initial sign and sole indicator of a primary hepatic tumor.
- ▶ **Diagnosis:** history; laboratory tests; sonography; CT angiography (if required); FNAB
- ▶ **Sonographic findings:**
  - Anechoic fluid in the abdominal cavity
  - Mass of highly variable echogenicity and shape (see also Chap. 21, Search for Occult Tumors):
    - Discrete outflow obstruction with associated biliary stasis
    - Diffuse lesion with functional loss of liver parenchyma and jaundice, even in the absence of biliary obstruction
- ▶ **Accuracy of sonographic diagnosis:** A careful examination can detect round lesions as small as 1–2 cm in 80% of cases.

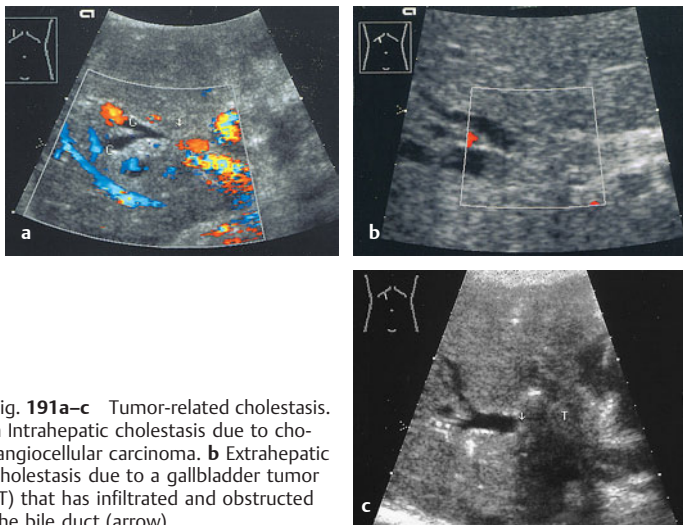


Fig. 191a–c Tumor-related cholestasis. **a** Intrahepatic cholestasis due to cholangiocellular carcinoma. **b** Extrahepatic cholestasis due to a gallbladder tumor (T) that has infiltrated and obstructed the bile duct (arrow)

### Cholangitis (Fig. 192)

- ▶ See also Bile Ducts, Biliary sludge and pus, p. 331; Sclerosing cholangitis, p. 327.
- ▶ **Classification:**
  - Acute suppurative cholangitis
  - *Primary sclerosing cholangitis (PSC)*: associated with chronic inflammatory bowel diseases; leads to biliary hepatic cirrhosis
  - *Chronic, nonsuppurative destructive cholangitis* (precursor of primary biliary cirrhosis [PBC]): cannot be diagnosed with ultrasound, which is used only to

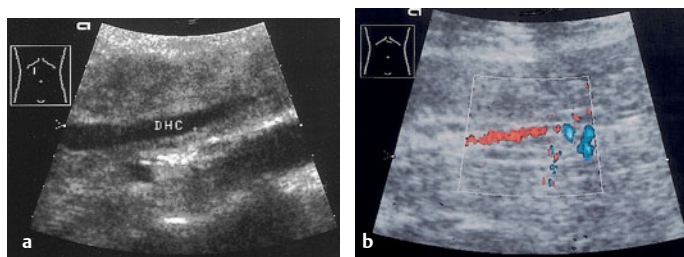


Fig. 192a, b **a** Cholangitis due to chronic obstruction by an impacted stone. The bile duct is expanded and shows marked wall thickening to 4 mm. **b** Chronic sclerosing cholangitis with the development of hepatic cirrhosis. Magnified view of the left hepatic lobe: “three-lane highway” pattern; the central red-encoded vessel is a dilated artery

exclude other causes of jaundice. Typically, mitochondrial antibodies are positive in 96% of cases.

- Vascular cholangitis
- ▶ **Clinical manifestations of acute suppurative cholangitis:** severe illness ranging to septic shock, fever, jaundice, right upper quadrant pain
- ▶ **Diagnosis:** history, associated disease; laboratory tests; sonography; ERCP:
  - *In* **PSC:** irregular luminal width of the bile ducts; biopsy, histology
  - *In* **PBC:** markedly fine intra- and extrahepatic bile ducts
- ▶ **Sonographic findings:**
  - *Signs of sclerosis in PSC* (see also Fig. 479, p. 327):
    - Bile duct walls are thickened and echogenic
    - Luminal irregularities of the intra- or extrahepatic bile ducts with circumscribed dilatations
    - Prominence of the portal tract arteries and intrahepatic bile ducts (“three-lane highway”)
    - *Development of cirrhosis:* initial vascular changes followed by changes in the liver contours
  - *Inflammatory signs in suppurative cholangitis:*
    - Thickening and layering of the duct wall
    - Echogenic material in the duct lumen
  - *Causes of inflammation:* stone, abscess, obstructing tumor
- ▶ **Accuracy of sonographic diagnosis:** Ultrasound can suggest the correct diagnosis, which is confirmed by endoscopic retrograde cholangiography (ERC), biopsy, and the clinical findings.

### Fatty Liver Hepatitis, Chronic Toxic Liver Disease, Nonalcoholic steatohepatitis (NASH)

- ▶ See also Liver, toxic fatty liver, toxic chronic liver disease, p. 234, 238.
- ▶ **Clinical manifestations:** right upper quadrant abdominal pain, anorexia, nausea, weight loss, hepatomegaly, splenomegaly, jaundice, fever.
- ▶ **Diagnosis:** history; clinical findings; laboratory findings: elevated transaminases, glutamate dehydrogenase (GLDH); sonography; liver biopsy and histology

- ▶ **Sonographic findings:**
  - Enlarged liver
  - Diffuse, homogeneous increase in echogenicity (“white liver”)
  - The liver is markedly hyperechoic to the normal kidney or psoas muscle
  - The portal vessels appear hypoechoic (reversal of contrast)
- ▶ **Accuracy of sonographic diagnosis:** Ultrasound can establish the presence of a fatty liver in more than 90% of cases, but it cannot determine the cause of the excessive fat deposition.

### Cholecystitis

---

- ▶ See Upper Abdominal Pain, Acute Cholecystitis, p. 63; Gallbladder, Acute cholecystitis, p. 339; Mural abscess, p. 341; Chronic cholecystitis, p. 344.

### Budd–Chiari Syndrome

---

- ▶ See Ascites, p. 162; Hepatosplenomegaly, p. 148; Search for Occult Tumors, Deformation and infiltration of vessels, p. 447.

### Secondary Biliary Cirrhosis

---

- ▶ **Clinical manifestations:** lethargy, decreased exercise tolerance, feeling of upper abdominal pressure or fullness; nausea, vomiting; jaundice; pruritus with scratch marks, spider nevi, telangiectasis, palmar erythema, glossitis, hormonal disorders
- ▶ **Diagnosis:**
  - History
  - *Clinical findings:* liver feels hard and initially enlarged; later it is decreased in size.
  - *Laboratory findings:* low cholinesterase, Quick PT, albumin; elevated AP, LAP, GGT, and conjugated bilirubin
  - Sonography (comparable to CT)
  - *Biopsy:* Histology establishes the diagnosis
- ▶ **Sonographic findings:**
  - Typical signs of hepatic cirrhosis (see p. 236, 330)
  - *Demonstrable cause of biliary obstruction:*
    - Signs of chronic pancreatitis
    - Common duct obstruction, gallstone
    - Choledochal cyst
- ▶ **Accuracy of sonographic diagnosis:** Diagnostic accuracy is only about 85%. Sonographic findings are least rewarding in the early phase of the disease.

### Biliary Atresia

---

- ▶ See Ascites, p. 155.

## 6.11 Hepatosplenomegaly

### Basic Principles

- ▶ **Principal signs and symptoms:** abdominal tenderness in the right and left upper quadrants, palpable organ enlargement

**Table 26 · Differential diagnosis of hepatosplenomegaly**

Diagnosis	Sonographic signs
<i>Common</i>	
Hepatic cirrhosis (p. 149)	
Cardiac inflow stasis (p. 149)	
Fatty liver (p. 149)	Enlarged, echogenic, homogeneous liver with rarefied hepatic veins
Hepatic tumor or metastasis (p. 150)	Hypoechoic or echogenic masses, enlarged liver and spleen, biliary stasis
<i>Less common</i>	
High-grade lymphoma, lympho-granulomatous infiltrates in Hodgkin disease (p. 150)	Enlarged liver and spleen, enlarged lymph nodes
Cystic liver (p. 151)	Numerous anechoic nodules (may be echogenic due to intralesional hemorrhage)
<i>Rare</i>	
Portal vein thrombosis (p. 151)	Enlarged spleen, venous collaterals (recanalized umbilical vein, convoluted veins)
Splenic vein thrombosis (p. 151)	Dilated splenic vein with no detectable flow
Budd–Chiari syndrome (p. 152)	Occlusion of the large hepatic veins; the veins usually show increased echogenicity with no detectable flow
Constrictive pericarditis (p. 152)	Hypoechoic enlargement of the liver, obstruction of the vena cava
Echinococcal cyst of the liver (p. 153)	Anechoic round lesion with echogenic wall, calcifications
Hepatic fibrosis (p. 153)	Coarse parenchymal pattern, periportal fibrosis, signs of portal hypertension

#### *Conditions that cannot be diagnosed with ultrasound*

*Common:* Sepsis due to various pathogens, infectious mononucleosis, epidemic hepatitis, toxic liver damage

*Less common:* Familial hyperlipidemia, hemochromatosis, subacute infectious endocarditis, sarcoidosis, blood diseases (hemolytic anemia, chronic myeloid leukemia, thrombocytosis, osteomyelofibrosis), malaria

*Rare:* Amyloidosis, hematologic diseases (polycythemia vera, Waldenström macroglobulinemia, acute erythromyelosis, erythropoietic porphyria), tropical diseases, other infectious diseases (Weil disease, Bang disease, relapsing fever, etc.), salmonellosis, paratyphoid fever, miliary tuberculosis, cytomegalovirus infection, metabolic diseases (storage diseases such as

**148** Gaucher disease, Wilson disease, fructose intolerance), rubella

- ▶ **Differential diagnosis:** The possible diagnoses are listed in Table 26 in order of their frequency in the general hospital setting.

### Hepatic Cirrhosis (Fig. 193)

- ▶ See also Ascites, p. 156; and Liver, pp. 236 and 238.

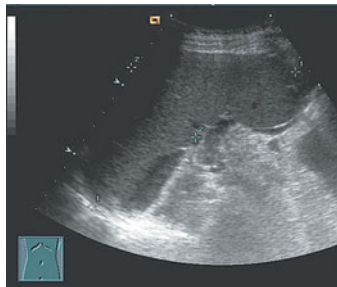


Fig. 193 Marked splenic enlargement in hepatic cirrhosis due to portal hypertension

### Cardiac Inflow Stasis

- ▶ See Renal Insufficiency, Heart Failure, p. 127; Shock Kidney, p. 136; Liver, Congestive Cirrhosis, p. 236; Vena Cava and Peripheral Veins, Congestion, p. 208.

### Fatty Liver (Fig. 194)

- ▶ See also Liver, Alimentary or diabetic fatty liver, p. 127; Toxic fatty liver, p. 238.
- ▶ **Clinical manifestations:** enlarged, palpable liver that may be tender to pressure; also signs and symptoms of the precipitating illness
- ▶ **Diagnosis:** history; laboratory tests: liver values, lipids, blood sugar, HbA1c
- ▶ **Sonographic findings:**
  - Enlarged, bulbous, echogenic, homogeneous liver (markedly hyperechoic to the healthy kidney)
  - Rarefied hepatic veins
  - Posterior (distal) acoustic shadowing
- ▶ **Accuracy of sonographic diagnosis:** Ultrasound can show only that fatty infiltration has probably occurred, producing a circumscribed area having the appearance of a fatty liver. The diagnosis can be confirmed by percutaneous biopsy, but this is rarely indicated. It is important to exclude other causes of echogenic

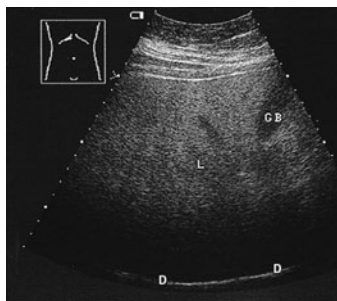


Fig. 194 Fatty liver: enlarged liver (L) with a dense, homogeneous echo pattern. The hepatic veins are only faintly visible, and there is dense posterior acoustic shadowing. GB = gallbladder, D = diaphragm

liver enlargement (see p. 234, 235). Therapeutic implications relate to the prevention or treatment of the precipitating cause (diabetes mellitus, glycogen storage disease, lipid metabolism disorder, alcohol-related disorders, etc.). Often no specific cause can be identified.

### Hepatic Tumor or Metastasis (Fig. 195)

- ▶ See also Jaundice, p. 145; Liver, Primary hepatic carcinoma, p. 249; Metastases, p. 250.
- ▶ **Clinical manifestations:** Early metastases may be clinically silent. As the intrahepatic pressure rises and bile ducts are compressed, jaundice may develop. Enlargement of the liver may lead to significant complaints (e.g., inferior vena cava obstruction and tenderness).
- ▶ **Sonographic findings:**
  - Hypoechoic or echogenic masses (usually rounded) with more or less well-defined margins
  - Enlarged liver
  - Biliary stasis
- ▶ **Accuracy of sonographic diagnosis:** The masses are clearly visualized in most cases. Ultrasound contrast agents can be helpful in locating and differentiating hepatic masses. Ultrasound-guided percutaneous biopsy establishes the diagnosis.

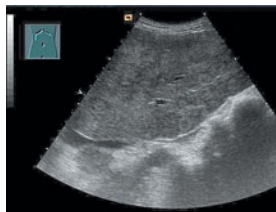


Fig. 195 Considerably enlarged liver with multiple round lesions, some showing a bull's-eye pattern → "metastatic liver", compressing and obstructing the inferior vena cava (vena cava compression syndrome)

### High-Grade Lymphoma, Lymphogranulomatous Infiltrates in Hodgkin Disease (Fig. 196)

- ▶ See also Palpable Masses, p. 101; Enlarged Lymph Nodes, Malignant Lymphoma, p. 113; Spleen, Splenic lymphoma, p. 316; Liver, Hematologic malignant systemic diseases, p. 239.
- ▶ **Clinical manifestations:** enlarged, palpable lymph nodes; lethargy, fever, night sweats, weight loss
- ▶ **Diagnosis:**
  - *Laboratory tests:* differential blood count, ESR; LDH; tuberculin test (e.g., Tine test)
  - Sonography with staging
  - Search for superficial lymph nodes
  - Lymphadectomy or percutaneous biopsy
- ▶ **Sonographic findings:**
  - Enlarged liver
  - Enlarged spleen
  - Other enlarged lymph nodes in the abdominal cavity and in peripheral soft tissues

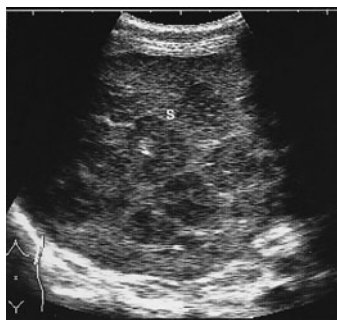

Fig. 196 High-grade non-Hodgkin lymphoma of the spleen (S)

- ▶ **Accuracy of sonographic diagnosis:** Multiple organ manifestations and multiple enlarged lymph nodes suggest a diagnosis of lymphoma. Splenic involvement is particularly suggestive, as other primary tumors rarely metastasize to the spleen. The diagnosis is confirmed by histologic examination (preferably of an excised lymph node).

### Cystic Liver

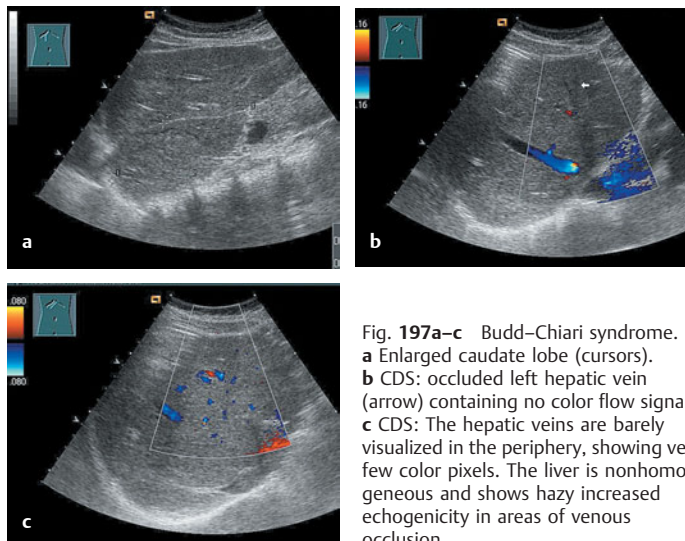
- ▶ See also Liver, p. 242.
- ▶ **Clinical manifestations:** frequently asymptomatic; possible nonspecific feeling of abdominal pressure and fullness
- ▶ **Diagnosis:**
  - History, especially the family history
  - *Physical examination:* palpably enlarged liver with a tense, nodular consistency
  - *Laboratory findings:* unrewarding, as there is no change in liver function. Laboratory values are altered only when complications arise.
  - *Sonography:* liver and kidney. Screening of family members may also be advised. Follow-ups
  - Percutaneous biopsy of an enlarged liver after the exclusion of hydatid disease (echinococcosis)
- ▶ **Sonographic findings:**
  - Numerous anechoic round lesions
  - Cyst contents may become echogenic as a result of intralesional hemorrhage.
  - Cysts may be flattened because of their close proximity to one another.
- ▶ **Accuracy of sonographic diagnosis:** The ultrasound findings are clear-cut. The presence of cysts in other organs and a positive family history establish the diagnosis, and no additional studies are needed.

### Portal Vein Thrombosis and Splenic Vein Thrombosis

- ▶ **Portal vein thrombosis:** see Ascites, Portal Hypertension, p. 158; Diffuse Abdominal Pain, Mesenteric Vascular Occlusion, p. 84; Portal Veins, Luminal Widening (Portal Hypertension), p. 257; Chronic portal vein thrombosis, p. 260.
- ▶ **Splenic vein thrombosis:** see Ascites, Portal Hypertension, p. 158.

**Budd–Chiari Syndrome (Fig. 197)**

- ▶ See also Ascites, p. 162; Search for Occult Tumors, Deformation and infiltration of vessels, p. 447.
- ▶ **Example (Fig. 197):** hepatic vein occlusion associated with oral contraceptive use. The patient had an elevated GGT. Hepatic ultrasound and ERCP were initially normal. Four weeks later she showed hypertrophy of the caudate lobe and partial occlusion of the hepatic veins.



**Fig. 197a–c** Budd–Chiari syndrome. **a** Enlarged caudate lobe (cursors). **b** CDS: occluded left hepatic vein (arrow) containing no color flow signals. **c** CDS: The hepatic veins are barely visualized in the periphery, showing very few color pixels. The liver is nonhomogeneous and shows hazy increased echogenicity in areas of venous occlusion

**Constrictive Pericarditis**

- ▶ **Clinical manifestations:** weakness, fatigue, weight loss, anorexia; inflow stasis with dilated neck veins, exertional dyspnea, frequent orthopnea. Signs of stasis include hepatomegaly, ascites (more pronounced than peripheral edema), and splenomegaly. Exudative enteropathy is seen with obstructed lymphatic drainage from the small bowel.
- ▶ **Diagnosis:**
  - *Laboratory tests:* simple blood count, HCT, hypalbuminemia, proteinuria, liver function values (abnormal: Quick PT, CHE)
  - *ECG:* low voltage
  - Chest radiograph or fluoroscopy shows pulmonary congestion with a normal-sized or slightly enlarged heart. Calcifications are visible in 50% of cases.
  - Sonography and echocardiography
  - Thoracic CT
- ▶ **Sonographic findings:**
  - Free fluid in the abdominal cavity (ascites)

- **Hepatic changes:**
    - Hypoechoic enlargement due to congestion, with good through-transmission of sound
    - *Later:* hepatic cirrhosis
  - Splenic enlargement due to congestion (differential diagnosis: infectious endocarditis, tricuspid valve disease)
  - Obstruction of the vena cava, etc.
  - Possible renal enlargement due to congestion
  - **Echocardiography:** pericardial thickening (hyperechoic band behind the left ventricle). The ventricular volumes are approximately normal.
- ▶ **Accuracy of sonographic diagnosis:** The ultrasound findings are typical and easily recognized but are not conclusive. Other causes can be excluded by sonography and laboratory testing. The clinical examination is important: finding decompensated hepatic cirrhosis in a patient with congested neck veins is very suspicious for constrictive pericarditis. Congestion of the neck veins is unresponsive to forced diuresis.

### **Echinococcal (Hydatid) Cyst of the Liver (*Echinococcus granulosus*)**

- ▶ See also Liver, cystic lesions, p. 244.
- ▶ **Organ involvement:** liver, lung, bone, CNS, heart
- ▶ **Clinical manifestations:** The patient may be asymptomatic for some time, depending on the pattern of involvement. Pain eventually occurs as the cysts enlarge and exert pressure on the organ capsule. A palpable mass is noted in the right upper quadrant. Intermittent bile duct compression can mimic recurrent cholelithiasis. Jaundice may occur. Discharge of hydatid fluid leads to fever, pruritus, urticaria, eosinophilia, and anaphylaxis. Pulmonary involvement is marked by cough, chest pain, and hemoptysis.
- ▶ **Diagnosis:**
  - **Laboratory tests:** differential blood count, antibodies (may be false-negative)
  - Sonography
  - **Chest radiograph:** irregular round lesions
  - CT if required.
- ▶ **Sonographic findings:**
  - Round, more or less anechoic lesion meeting all the criteria for a cyst (*E. granulosus*, type CE 1 of the WHO classification of cystic echinococcosis cysts), or
  - Multiple cysts arranged in a rosette-like pattern (type CE 2)
  - Sharply circumscribed
  - Echogenic wall
  - Complex structure, calcification (types CE 3, 4)
  - **Alveolar echinococcus disease** (*E. multilocularis*): blurred, limited, complex-structured mass
- ▶ **Accuracy of sonographic diagnosis:** Calcified walls can be clearly visualized and suggest the correct diagnosis. Finding daughter cysts within a larger cyst confirms the diagnosis. The diagnosis could be proved by aspirating the cyst contents and identifying scolices, but this is not advised because of the risk of spreading the infection. The definitive diagnosis is made during therapeutic drainage of the cysts followed by alcohol instillation or after possible surgical intervention.

### **Hepatic Fibrosis (Figs. 198–200)**

- ▶ See also Liver, p. 235.

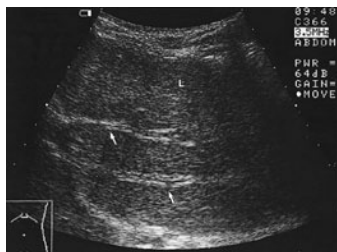

Fig. 198 Congenital hepatic fibrosis. The liver (L) appears normal sized with a somewhat coarse internal echo pattern. Fibrotic encasement of the portal vessels (arrows) is clearly visualized

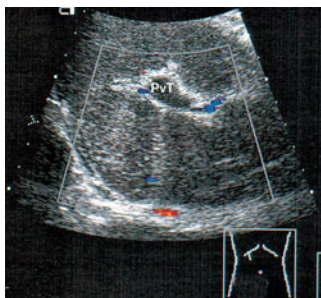

Fig. 199 Congenital hepatic fibrosis. The portal venous trunk (PVT), cut approximately in cross-section by the scan plane, shows even clearer evidence of fibrotic encasement (same patient as in Figs. 198 and 200)

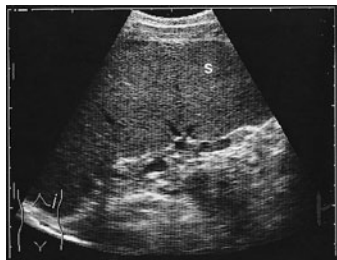

Fig. 200 Splenomegaly in congenital hepatic fibrosis. The spleen (S) is markedly enlarged in this slender patient, measuring 16 cm long by 6 cm deep

- ▶ **Classification:** congenital form, or secondary fibrotic transformation due, for example, to collagen deposition resulting from an infectious disease (e.g., schistosomiasis).
- ▶ **Clinical manifestations:** The patient feels well. Later, a pattern of complaints may emerge that resembles portal hypertension (see Ascites, Portal Hypertension, p. 158).
- ▶ **Diagnosis:**
  - Laboratory tests are unrewarding (normal liver values); liver cells are undamaged.
  - *Physical examination, palpation:* small, hard, nodular liver
  - Sonography; biopsy is rarely necessary
- ▶ **Sonographic findings:**
  - Liver exhibits a somewhat coarse internal echo pattern.
  - Periportal fibrosis, echogenic encasement (fibrotic transformation of the portal branches, echogenic bands)
  - No regenerative nodules as in cirrhosis
  - Signs of portal hypertension (see Ascites, p. 158)
  - Splenomegaly is less common than with hepatic cirrhosis.
  - Congenital form may be associated with polycystic kidneys or liver.
- ▶ **Accuracy of sonographic diagnosis:** The sonographic features are so characteristic that biopsy is generally unnecessary.

## 6.12 Ascites

### Basic Principles

- ▶ **Principal signs and symptoms:** possible abdominal distention with prominent flanks, slender extremities, free fluid in the abdominal cavity (as little as 30 mL can be detected sonographically); feeling of tension and fullness, possible dyspnea and tachycardia
- ▶ **Differential diagnoses:** These are listed in Table 27 according to their frequency in the general hospital setting.

**Table 27 · Differential diagnosis of ascites**

Diagnosis	Sonographic signs
<i>Common</i>	
Hepatic cirrhosis (p. 156)	Enlargement of the caudate lobe, wavy surface contours with apparent breaks in the capsule, peripheral pruning of the portal vessels
Peritoneal carcinomatosis (p. 157)	Anechoic deposits in the abdominal cavity, thickened echogenic peritoneum, possible tumor mass
Peritonitis (p. 158)	Echogenic thickening of the peritoneum, loculated fluid, local or diffuse intestinal paralysis
Portal hypertension (p. 158)	Enlarged spleen, venous collaterals (recanalized umbilical vein, convoluted veins)
Abdominal tumor (p. 159)	Variable appearance, usually hypoechoic or hyperechoic to surroundings, sharply circumscribed or with ill-defined infiltrating margins
<i>Less common</i>	
Pancreatitis (p. 159)	Appearance varies with the stage of the disease: normal, echogenic, hypoechoic, possible cysts or calcifications
Right heart failure (p. 160)	Enlarged, congested liver; dilated hepatic veins; expanded vena cava
<i>Rare</i>	
Pericardial effusion (p. 161)	Anechoic masses in the pericardial sac; ventricles usually empty and hyperactive
Bowel obstruction, paralytic ileus (p. 161)	Dilated bowel loops, circumscribed or diffuse absence of peristalsis, frequent hypoechoic thickening of bowel wall; contents may be increased or decreased
Meigs syndrome (p. 162)	Free fluid in the abdominal cavity, pleural effusion, hypoechoic enlargement of the ovary (usually unilateral)
Mesenteric vascular thrombosis (p. 162)	Doppler shows absence of flow in the artery (embolism) or in the dilated hypoechoic veins (thrombosis)
Budd–Chiari syndrome (p. 162)	Liver greatly enlarged and tender with hypertrophic caudate lobe; large hepatic veins are not visualized and show no flow by CDS

**Table 27 · Differential diagnosis of ascites – continued**

Diagnosis	Sonographic signs
Hepatic tumor or metastases (p. 249, 250)	Hepatitis mass of variable echogenicity (depending on its origin)
Biliary atresia (p. 163)	Bile ducts cannot be visualized

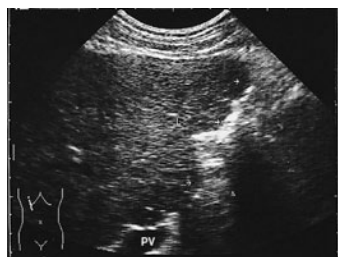**Conditions that cannot be diagnosed with ultrasound**

*Less common:* Hypoproteinemia (nephrotic syndrome, malabsorption), primary biliary hepatic cirrhosis

*Rare:* Mesenteric tuberculosis, hemorrhagic diathesis, fulminating hepatitis, acute liver dystrophy, intestinal lymphangiectasia, Wilson disease, galactosemia

**Hepatic Cirrhosis (Figs. 201 and 202)**

- ▶ See also Liver, Severe chronic hepatitis with fibrosis or cirrhosis, p. 236, 239.
- ▶ **Classification:**
  - Hepatic (same features as in siderocirrhosis and autoimmune cirrhosis)
  - Toxic
  - Secondary biliary
  - Primary sclerosing cholangitis
- ▶ **Clinical manifestations:** lethargy, decreased exercise tolerance, weight loss (rarely, weight gain due to copious ascites), feeling of upper abdominal pressure or fullness, nausea, vomiting; abdominal distention, jaundice, pruritus with scratch marks, spider nevi, telangiectasis, palmar erythema, glossitis; hormonal disorders, edema, hepatic insufficiency with gastrointestinal bleeding, coma
- ▶ **Diagnosis:**
  - *History:* alcohol consumption, viral hepatitis, medications
  - *Examination:* liver is hard and initially enlarged, later diminished in size
  - *Laboratory findings:* decreased CHE, Quick PT, albumin; elevated AP, LAP, GGT, and bilirubin (conjugated = direct). Hepatitis serology, coagulation status, etc.
  - Sonography is of equivalent diagnostic value as CT
  - Biopsy (e.g., with Menghini needle), histology
- ▶ **Sonographic findings:**
  - **Note:** Initial structural and contour changes in a cirrhotic liver are followed by vascular changes (in hepatic and toxic forms). First the liver is enlarged, and later it becomes small and atrophic. The right lobe of the liver tends to shrink, while the left lobe tends to enlarge and may come in contact with the spleen (“kissing liver and spleen” sign).
  - Enlargement of the caudate lobe
  - Rounded hepatic border, wavy surface, apparent breaks in the capsule



**Fig. 201** Hepatic cirrhosis. The liver presents a coarse, mottled internal echo pattern. The inferior border shows coarse nodularity (arrows) with apparent “breaks” in the liver capsule. PV = portal vein

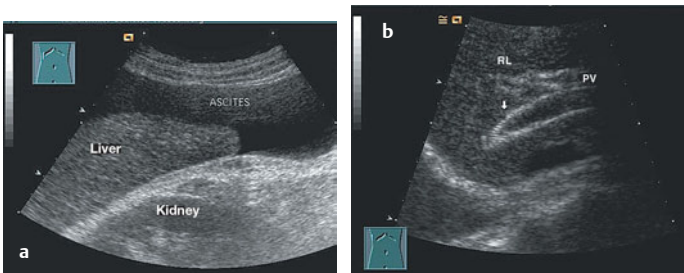


Fig. 202a, b Decompensated hepatic cirrhosis with refractory ascites in chronic hepatitis C, before and after insertion of a transjugular intrahepatic portosystemic shunt (TIPS; arrow). **a** Enlarged, hypoechoic liver with a coarse parenchymal echo texture, surrounded by anechoic fluid. **b** Following TIPS insertion, ascites is no longer detected. RL = right lobe of liver, PV = portal vein

- Rapid tapering of the portal system, with apparent “pruning” of portal branches toward the periphery
- *Signs of portal hypertension:*
  - Flow reversal
  - Collateral formation
  - Recanalization of the umbilical vein
  - Splenomegaly
  - Ascites
- *Possible detectable cause of biliary obstruction:*
  - Signs of chronic pancreatitis
  - Common duct obstruction
  - Choledochal cyst
  - Biliary sclerosis (see Fig. 479), p. 327).
- ▶ **Accuracy of sonographic diagnosis:** Hepatic cirrhosis cannot be positively detected with ultrasound in its initial stage. All diagnostic criteria should be considered. It is difficult to distinguish between severe fibrosis and cirrhosis. Advanced stages of hepatic cirrhosis can be diagnosed with 100% accuracy.

### Peritoneal Carcinomatosis

- ▶ See also Search for Occult Tumors, Abnormal accumulations of fluid, p. 439.
- ▶ **Clinical manifestations:** severe constitutional symptoms, diffuse abdominal pain, tense abdominal distention due to ascites
- ▶ **Diagnosis:**
  - History (known neoplastic disease)
  - Sonography
  - Aspiration of ascites with bacteriologic and cytologic examination and laboratory analysis (WBC, protein, pancreatic and liver enzymes, LDH, cholesterol, glucose)
  - FNAB of the peritoneum for cytologic analysis
  - Laparoscopy
- ▶ **Sonographic findings:**
  - Largely anechoic fluid in the abdominal cavity (ascites) with floating, solid echogenic components
    - *With small amounts of ascites:* anechoic rim around organs
    - *With copious ascites:* floating bowel loops that are adherent to one another

- Thickened peritoneum and mesentery
- Possible adherent tumor masses

▶ **Accuracy of sonographic diagnosis:** The diagnosis is based on the laboratory detection of malignant ascites and laparoscopy. Ultrasound findings are equivocal.

### Peritonitis

▶ See also Diffuse Abdominal Pain, p. 83.

▶ **Classification:**

- *Bacterial* (ultrasound does not show pathogen-specific changes): secondary to perforation, appendicitis, etc.; seepage, hematogenous dissemination (in tuberculosis)
- *Chemical:* due to pancreatic juice, gastric acid, bile
- Sterile

▶ **Clinical manifestations:** constitutional symptoms, severe malaise, marked abdominal tenderness, local or (usually) diffuse rigidity

▶ **Sonographic findings:**

- Echogenic thickening of the peritoneum
- Local or diffuse tenderness to pressure
- Small amounts of loculated peritoneal fluid
- Local or diffuse paralytic ileus with a local increase in bowel fluid

▶ **Accuracy of sonographic diagnosis:** Further tests are essential to establish the diagnosis.

### Portal Hypertension (Fig. 203)

▶ See also Diffuse Abdominal Pain, Mesenteric Vascular Occlusion, p. 84; Liver, Luminal Widening (Portal Hypertension), p. 257; Chronic portal vein thrombosis, p. 260.

▶ **Classification:**

- *Presinusoidal:*
  - *Extrahepatic:* e.g., splenic vein thrombosis, portal vein thrombosis
  - *Intrahepatic:* e.g., schistosomiasis
- *Sinusoidal:* e.g., hepatic cirrhosis, chronic active hepatitis (see p. 238)
- *Postsinusoidal:*
  - *Extrahepatic:* e.g., Budd–Chiari syndrome
  - *Intrahepatic:* e.g., venous occlusive disease

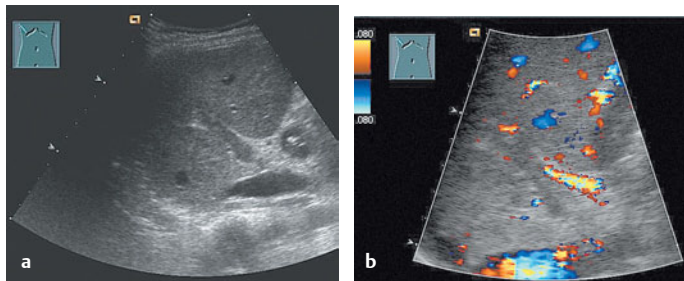


Fig. 203a, b Portal vein thrombosis. **a** Hypoechoic band in the porta hepatis of a 24-year-old woman who underwent splenectomy. **b** CDS: The hypoechoic band in the portal vein has no detectable flow, even at a low PRF setting. Color flow signs are visible in the adjacent hepatic artery. Extended intercostal scan

- ▶ **Clinical manifestations:** ascites (abdominal distention), hypersplenism, splenomegaly (may lead to thrombocytopenia and pancytopenia), gastrointestinal bleeding, hepatic encephalopathy (all types of neurologic deficit may occur, especially cognitive impairment and varying state of consciousness)
- ▶ **Diagnosis:**
  - History and clinical findings
  - Sonography, CDS
  - Esophagoscopy, fundoscopy
- ▶ **Sonographic findings:**
  - Enlarged spleen
  - *Venous collaterals:* recanalized umbilical vein, convoluted veins in the abdominal wall (without duplex scanning, these may be mistaken for matted lymph nodes)
  - Ascites
  - *Depending on the cause:*
    - Signs of hepatic cirrhosis
    - Enlarged splenic veins or portal vein with absence of flow
    - Empty hepatic veins
    - Decreased flow velocity in the portal vein, or retrograde flow
- ▶ **Accuracy of sonographic diagnosis:** The signs of portal hypertension can be clearly identified when they are specifically looked for.

### Abdominal Tumor (Fig. 204)

- ▶ See also Jaundice, Biliary Obstruction or Tumor, p. 142; Hepatic Tumor, p. 145; Liver, Primary hepatic carcinoma, p. 249; Metastases, p. 250.

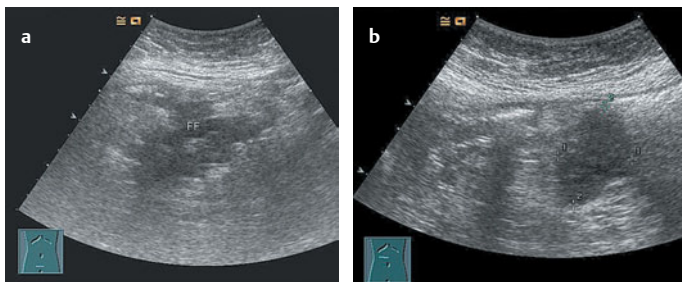


Fig. 204a, b Ascites associated with a colonic tumor. **a** Hypoechoic free fluid (FF) in the lower abdomen due to a colonic tumor. **b** Hypoechoic wall thickening associated with a tumor of the right colic flexure (cursors)

### Pancreatitis (Fig. 205)

- ▶ See also Upper Abdominal Pain, Acute Pancreatitis, p. 65; Pancreas, Pancreatitis of the head and tail of the pancreas (severe), p. 303; Acute pancreatitis, p. 295.

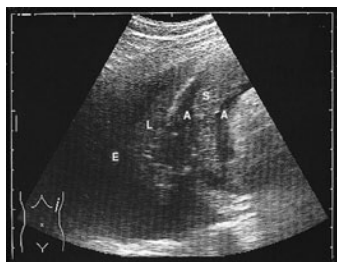

Fig. 205 Pancreatitis: pleural effusion (E), free fluid around the lung (L), free fluid (ascites, A) around the spleen (S)

### Right Heart Failure (Fig. 206)

- ▶ See also Renal Insufficiency, Heart failure, p. 127; Shock Kidney, p. 136; Liver, Congestive cirrhosis, p. 236; Vena Cava and Peripheral Veins, Congestion, p. 208.
- ▶ **Clinical manifestations:** visible venous congestion, weight gain due to water retention, generalized edema, dyspnea due to pleural effusion (chiefly on the right side); enlarged, painful, congested liver; feeling of fullness due to congestive gastritis; tachycardia, nycturia
- ▶ **Diagnosis:**
  - History (known pulmonary disease as the cause of portal hypertension and consequent right heart failure)
  - *Sonography:* abdominal sonography, lower extremity venous sonography, echocardiography
  - Chest radiographs
  - Aspiration of ascites to exclude other causes
- ▶ **Sonographic findings:**
  - Hepatic venous dilatation extending far into the periphery
  - Enlarged, congested liver
  - Vena cava congested and dilated, shows no caliber change during inspiration
  - Possible renal venous congestion with swelling and thickening of the renal parenchyma
  - *Lower extremity venous sonography:* congested lower extremity veins, compressible, with detectable flow; no evidence of thrombosis
  - *Echocardiography:* dilated right atrium, enlarged right ventricle; with right-sided failure, the left heart appears normal
- ▶ **Accuracy of sonographic diagnosis:** The signs of right heart failure can be clearly identified.

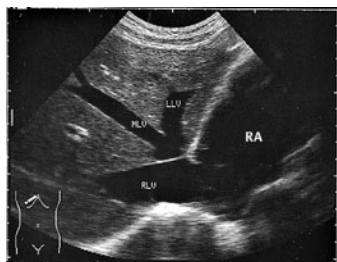


Fig. 206 Right heart failure: dilated hepatic veins, prominent star-shaped termination of the hepatic veins with dilatation of the right (RV), middle (MLV) and left (LLV) hepatic veins. There is concomitant dilatation of the right atrium (RA)

## Pericardial Effusion (Figs. 207 and 208)

- ▶ See also Renal Insufficiency, Heart Failure, p. 127 (Fig. 171a, b).
- ▶ **Clinical manifestations:** chest pain at the onset of the disease, signs of global heart failure with dyspnea, signs of superior and inferior vena caval obstruction (tense jugular veins, lower extremity edema)
- ▶ **Diagnosis:**
  - *History:* possible causes of pericarditis (e.g., infarction, tumor, infection, prior Tb)
  - Sonography; echocardiography
  - ECG; chest radiograph
- ▶ **Sonographic findings:**
  - Possible signs of hepatic venous congestion, ascites, and hepatic cirrhosis
  - An anechoic mass, highly variable in size and thickness, is usually found in the pericardial sac. M-mode scans during cardiac contractions can differentiate the effusion from pericardial fat.
  - Scant, impaired ventricular filling; ventricles appear hyperactive
- ▶ **Accuracy of sonographic diagnosis:** Small pericardial effusions may be mistaken for pericardial fat. Moderate and large pericardial effusions are easily recognized. Other sonographic signs relating to inflow stasis can also be identified.

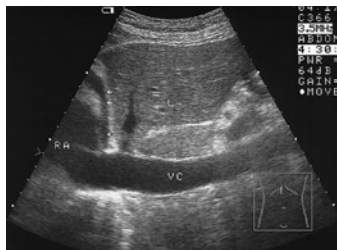


Fig. 207 Pericardial effusion (arrows): enlarged right atrium (RA) and congested vena cava (VC). The patient presented clinically with bronchial carcinoma that had invaded the pericardium. Upper abdominal longitudinal scan. L = liver

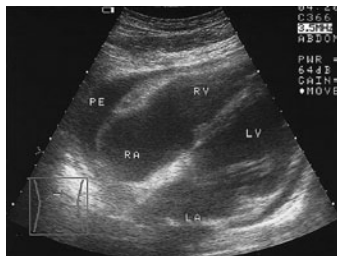
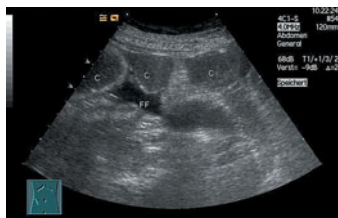

Fig. 208 Pericardial effusion (same patient as in Fig. 207): enlarged heart with right ventricle (RV), left ventricle (LV), right atrium (RA), and left atrium (LA). The pericardial effusion (PE) is 2 cm wide and fully encompasses the heart. Upper abdominal transverse scan (subxiphoid)

## Bowel Obstruction, Paralytic Ileus (Fig. 209)

- ▶ See also Diffuse Abdominal Pain, p. 82; Small Intestine, Partial or complete paralytic ileus, p. 83.
- ▶ **Note:** Ascites may develop, depending on the cause of the bowel obstruction, and may consist of transudate or inflammatory exudate.

Fig. 209 Free fluid (FF) in paralytic ileus. The patient presented clinically with an acute exacerbation of ulcerative colitis and toxic megacolon. C = dilated loops of colon



### Meigs Syndrome (Benign Ovarian Fibroma, Fig. 210)

- ▶ **Clinical manifestations:** increased abdominal circumference, possible dyspnea, palpable lower abdominal mass.
- ▶ **Diagnosis:**
  - History
  - Sonography
  - Gynecologic examination
  - Percutaneous tumor biopsy for histologic evaluation; aspiration of ascites, thoracentesis
- ▶ **Sonographic findings:**
  - Free fluid in the abdominal cavity
  - Pleural effusion
  - Hypochoic neoplastic enlargement, usually confined to one ovary

### Mesenteric Vascular Thrombosis

- ▶ See Diffuse Abdominal Pain, Mesenteric Vascular Occlusion, p. 84.

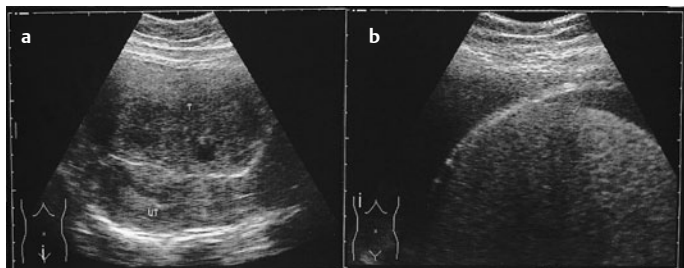


Fig. 210a, b Meigs syndrome with pleural effusion and ascites. **a** Large ovarian tumor (T), slightly nonhomogeneous with small cystic areas, lying anterior to the uterus (UT). **b** Pleural effusion appears as a hypoechoic crescent above the diaphragm, ascites as a hypoechoic crescent between the liver and diaphragm

### Budd–Chiari Syndrome (Hepatic Venous Occlusion)

- ▶ See also Search for Occult Tumors, Deformation and infiltration of vessels, p. 447.
- ▶ **Occurrence:** septum formation at the termination of the hepatic veins, thrombocytopenia, hormonal contraceptive use, paroxysmal nocturnal hemoglobinuria, abscess, polycythemia vera, tumor, treatment with chemotherapeutic agents
- ▶ **Clinical manifestations:** significant upper abdominal pain, venous markings on the chest, signs of portal hypertension (see Portal Hypertension, p. 258).
- ▶ **Diagnosis:** sonography; laboratory findings: elevated transaminases; angiography
- ▶ **Sonographic findings:**
  - Pronounced ascites
  - Nonvisualization of the hepatic veins upstream from their termination at the vena cava
  - Liver greatly enlarged and tender
  - Nonhomogeneous, mottled (“leopard-skin”) hepatic echo pattern

- Hypertrophy of the caudate lobe in chronic cases (separate drainage into the vena cava), may cause vena cava compression
  - CDS: no detectable flow
  - Direct tumor extension or intravascular thrombus may be detected.
  - Compression from a tumor, lymph node, or abscess may be detected.
- ▶ **Accuracy of sonographic diagnosis:** The hepatic venous occlusion is seen in 98% of cases, and the cause (e.g., a tumor) can be identified in 85%.

### Biliary Atresia

- ▶ **Clinical manifestations:** Life-threatening obstructive jaundice develops during the first month of life. The later course is marked by the development of chronic cholangitis and hepatic fibrosis (see p. 235).
- ▶ **Diagnosis:** sonography; cholangiography; laparotomy
- ▶ **Sonographic findings:** nonvisualization of the biliary tract
- ▶ **Accuracy of sonographic diagnosis:** still very uncertain. The diagnosis is established by cholangiography. Despite operative treatment, consistent sequelae are chronic cholangitis and the development of hepatic fibrosis with portal hypertension, which can be diagnosed sonographically.

## 6.13 Joint Pain and Swelling

### Basic Principles

- ▶ **Incidence:** Pain in or around the joints and swelling of the joints are common reasons for seeking medical attention. In many cases a presumptive diagnosis can be made based on the history and physical examination alone.
- ▶ **Principal signs and symptoms:**
- Pain at rest, joint tenderness, or pain during joint movement
  - Active and/or passive limitation of motion
  - Favoring the affected joint
  - Swelling and local warmth
- ▶ **Causes:**
- *Inflammatory:* e.g., articular synovitis, tenosynovitis, bursitis
  - *Degenerative:* e.g., osteoarthritis, degenerative rotator cuff lesions, chondrocalcinosis

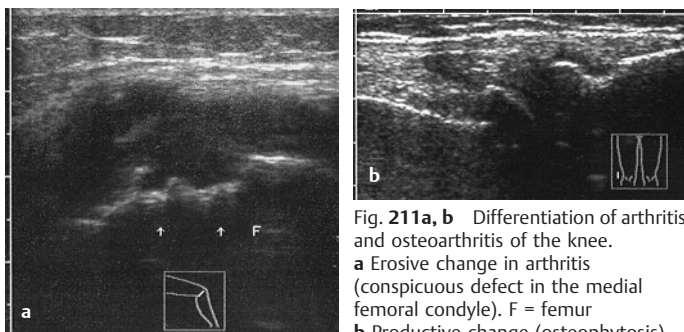


Fig. 211a, b Differentiation of arthritis and osteoarthritis of the knee.  
**a** Erosive change in arthritis (conspicuous defect in the medial femoral condyle). F = femur  
**b** Productive change (osteophytosis) in primary osteoarthritis of the knee

**Table 28 · Differential diagnosis of joint pain (accessible to sonographic diagnosis)**

Diagnosis	Sonographic findings
Articular synovitis	Hypoechoic thickening of the joint capsule Anechoic exudate Variable size and shape during active or passive joint movements Erosive surface defects in cartilage and bone (erosive arthritic changes, see Fig. 211a)
Examples	Arthritis of the shoulder (see p. 169), acromioclavicular and sternoclavicular arthritis (see p. 170), cubital arthritis (see p. 171), articular synovitis of the finger and toe joints (see p. 172), arthritis of the hip (see p. 173), arthritis of the knee (see p. 174), arthritis of the ankle joint (see p. 176)
Tenosynovitis	Hypoechoic rim surrounding the central echogenic tendon Confluent borders due to involvement of adjacent tendon sheaths Superficial tendon erosion, or complete rupture due to pannous tenosynovitis
Examples	Tenosynovitis of the long biceps tendon (see p. 167), tenosynovitis of the malleolar region (see p. 177)
Osteoarthritis	Thinning of the articular cartilage and narrowing of the joint space Marginal osteophytes forming spurs or ledges (productive osteoarthritic changes, see Fig. 211b) Deformation of articular surfaces Concomitant intra-articular exudates or periarticular bursopathy
Examples	Osteoarthritis of the shoulder (see p. 170), osteoarthritis of the knee (see p. 175)
Degenerative rotator cuff lesions	See p. 165
Subdeltoid bursitis	See p. 166
Rheumatoid nodule	See p. 172
Gouty tophi	See p. 176
Baker cyst	See p. 175
Periarthritis	See p. 177

- **Muscular (static):** Due to unphysiologic or excessive loading, e.g., rotator cuff tear

- ▶ **Diagnostic approach:** history, physical examination, laboratory tests, arthrosonography (see p. 31). Other modalities such as conventional radiographs, scintigraphy, CT, MRI, and arthroscopy may also be needed
- ▶ **Differential diagnosis:** see Table 28.

## Degenerative Lesions of the Rotator Cuff

- **Note:** Rotator cuff lesions are a frequent cause of shoulder pain
- ▶ **Sonographic anatomy:** The rotator cuff is a cap-shaped musculotendinous structure that encompasses the humeral head. It is formed by the insertions of the supraspinatus, infraspinatus, teres minor, and subscapularis muscles.
- ▶ **Diagnosis:** see Diagnostic approach, p. 164.
- ▶ **Sonographic findings:**
  - Circumscribed echogenic or echopenic areas within the rotator cuff.
  - **Caution:** image in two planes to exclude artifacts due to anisotropy.
  - Calcifications with posterior acoustic shadowing (Fig. 212)
  - Circumscribed, concave thinning of the rotator cuff with a partial rupture; complete disruption of the rotator cuff echo band with a complete rupture (Figs. 213 and 214). A complete rupture leads to nonvisualization or rudimentary visualization of the rotator cuff and allows direct contact between the deltoid muscle and humeral head (“bare” humeral head).
  - Anechoic rim is a sign of concomitant subdeltoid bursitis (see below).

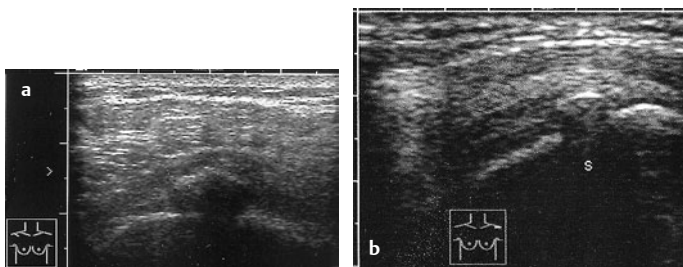


Fig. 212a, b Calcaneal tendinitis: domelike echogenicity with a posterior acoustic shadow. The shadow (S) obscures the underlying outline of the humeral head (lateral transverse scan)

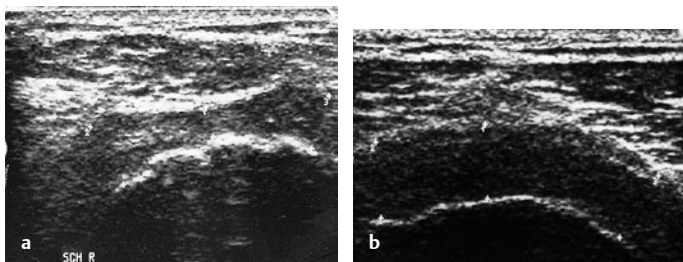


Fig. 213a, b a Partial rupture of the right rotator cuff with a concave indentation in the “bursal line”. b Compare with the intact rotator cuff (cursors) on the contralateral side

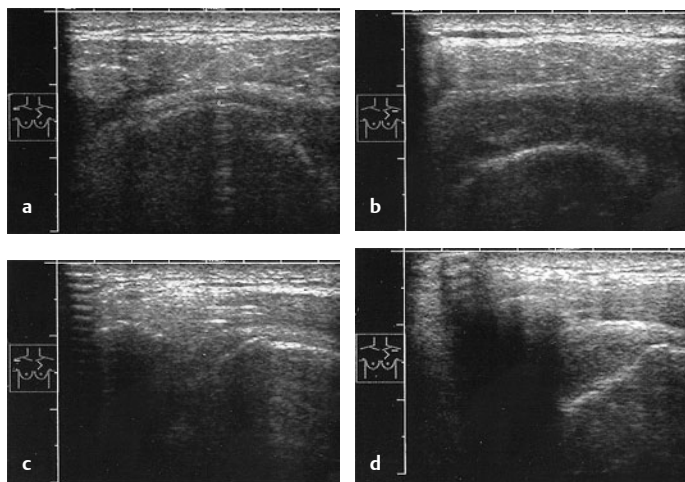


Fig. 214a–d Chronic degenerative rotator cuff tear in a professional musician (bowed string instrument). **a** Transverse scan: fusiform thinning of the rotator cuff with a bare humeral head (“wheel without a tire” pattern). **b** Opposite side for comparison. **c** Longitudinal scan: “bird’s head with no beak,” high-riding humeral head. **d** Opposite side for comparison. For normal findings, see also Fig. 49, p. 37

### Subdeltoid Bursitis

- ▶ **Sonographic anatomy:** The subdeltoid or subacromial bursa is the largest bursa in the human body. When imaged in a lateral longitudinal scan, it lies between the sonographically well-defined deltoid muscle and the muscles of the rotator cuff.
- ▶ **Sonographic findings** (Fig. 215): an anechoic region of variable extent occupying the space between the rotator group and deltoid muscle. An effusion of approximately 10 mL or more is detectable by ultrasound
- ▶ **Scanning tips:**
  - With a larger collection, even an anterior transverse scan may demonstrate an anechoic band anterior to the long biceps tendon.
  - An extensive, chronic bursitis may be difficult to recognize because of its echogenic contents (e.g., fibrin, debris, cholesterol crystals; Fig. 216).
  - On dynamic examination (passive shoulder abduction), the painful impingement can be reproduced in the real-time image.
- ✔ **Caution:** Avoid excessive transducer pressure, as this could mask small amounts of effusion.

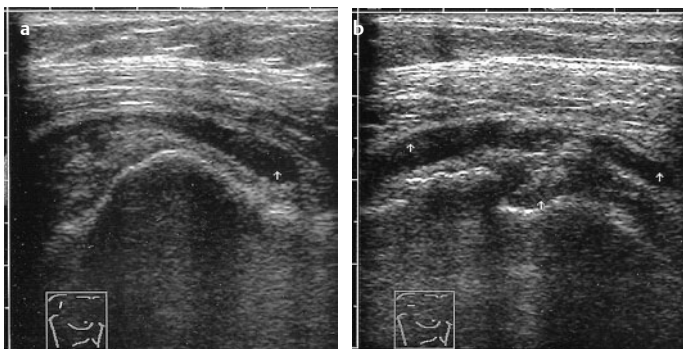


Fig. 215a, b Subdeltoid bursitis in acute polyarthritis: effusion (arrows) with separation of the deltoid muscle and rotator cuff, also bicipital tenosynovitis. **a** Lateral longitudinal scan, **b** anterior transverse scan

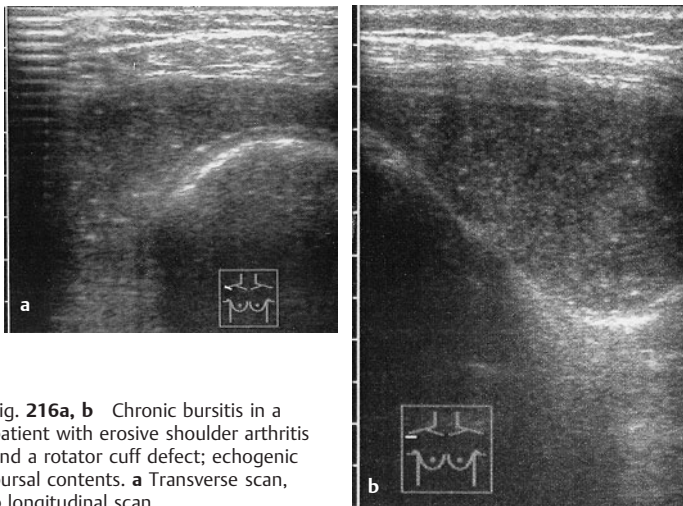


Fig. 216a, b Chronic bursitis in a patient with erosive shoulder arthritis and a rotator cuff defect; echogenic bursal contents. **a** Transverse scan, **b** longitudinal scan

### Tenosynovitis of the Long Biceps Tendon (Bicipital Tenosynovitis)

- ▶ **Occurrence:** a frequent accompaniment of degenerative or inflammatory joint disease
- ▶ **Sonographic findings:**
  - Typical circumferential, hypochoic widening of the tendon sheath with a halo or “fried egg” pattern in the anterior transverse scan (Fig. 217). A “white stripe on black asphalt” pattern is seen in the anterior longitudinal scan.
  - CDS shows increased vascularity in a primary inflammatory process (Fig. 218).

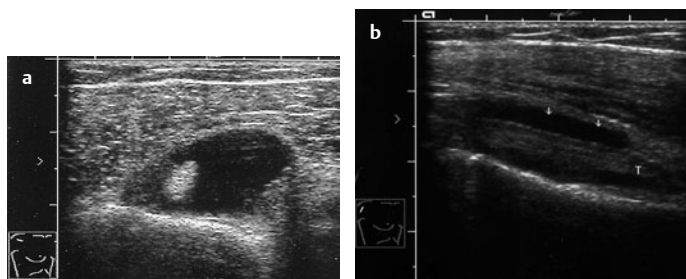


Fig. 217a, b Bicipital tenosynovitis in polyarthritis (anterior transverse and longitudinal scans over the bicipital groove). **a** Transverse scan: halo pattern. **b** Longitudinal scan: hypoechoic to anechoic widening of the tendon sheath (arrows), central echogenic tendon (T)

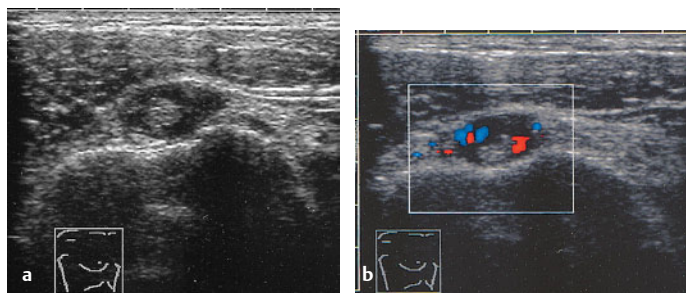


Fig. 218a, b Bicipital tenosynovitis in polyarthritis. Anterior transverse scan shows an anechoic rim surrounding the echogenic biceps tendon, also numerous color flow signals including small arterial signals

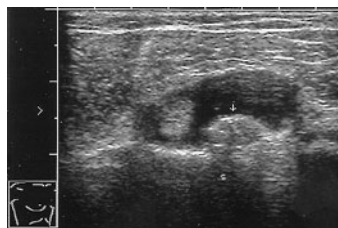

Fig. 219 Biceps tendon calcification in polyarthritis: convex echogenic zone within the biceps tendon sheath with a distal acoustic shadow, indicating calcification

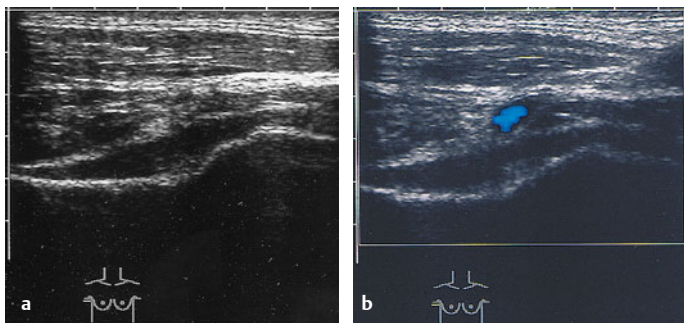
- Anterior scan planes may yield significant additional findings (e.g., subdeltoid bursitis or calcifications within the biceps tendon; Fig. 219).

## Arthritis of the Shoulder

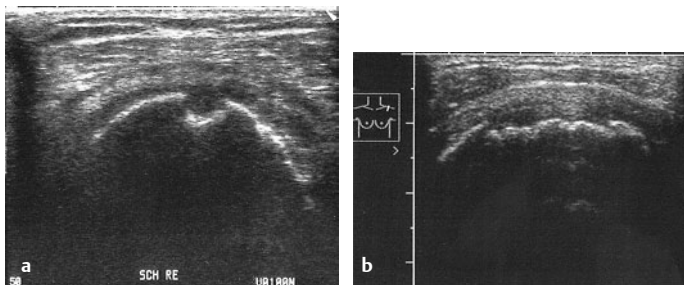
**Occurrence:** Shoulder involvement is common in the setting of primary inflammatory rheumatic diseases.

► **Sonographic findings:**

- **Shoulder arthritis (Fig. 220):**
  - Pericapital hypoechoic rim, teardrop-shaped expansion of the axillary recess in the axillary scan
  - Hypoechoic collections visible in anterior and posterior scans when copious effusion is present
  - Detection of erosive defects indicating a destructive rheumatoid joint disease
  - Frequent concomitant, nonspecific bicipital tenosynovitis or subdeltoid bursitis
- **Erosive shoulder arthritis (Fig. 221):**
  - Shallow irregularities in the humeral head contours or deep circumscribed defects (erosions), usually seen best in posterior and axillary scans



**Fig. 220a, b** Shoulder involvement in a patient with rheumatoid arthritis. **a** B-mode image: small effusion in the articular recess (longitudinal axillary scan). **b** CDS: longitudinal scan demonstrates axillary vascular structures (circumflex humeral artery)



**Fig. 221a, b** Erosive arthritis affecting both shoulder joints. **a** High-level echoes from the base of a deep bony defect. **b** Irregular, fragmented bone echoes in the arthritic left shoulder of a patient with ankylosing spondylitis

- Typical lesion location at chondro-osseous boundaries
- Erosions can be distinguished from pseudoerosions by defining the echogenic base of the erosive defect.

- ▶ **Role of sonography:** Ultrasound scanning can detect early inflammatory changes in patients who have subtle or equivocal clinical findings. Erosive changes due to pannus formation are typical in rheumatoid arthritis.

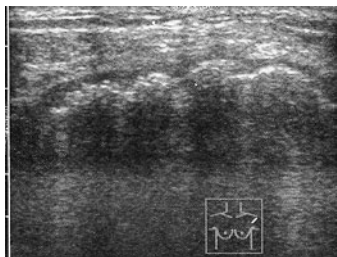


Fig. 222 Postinflammatory destruction of the rotator cuff in an osteoarthritic shoulder. Erosive defects appear along the lateral circumference of the humeral head ("battlement" pattern), with hypertrophy of the deltoid muscle

### Secondary Osteoarthritis of the Shoulder

- ▶ **Definition:** extensive productive and erosive changes resulting from a chronic inflammatory process
- ▶ **Sonographic findings:**
  - Alternating bony excrescences and erosions resembling the "battlements" on a fortress wall (Fig. 222)
  - Frequent complete destruction of the rotator cuff

### Acromioclavicular and Sternoclavicular Arthritis

- ▶ **Causes, occurrence:**
  - Acromioclavicular arthritis may occur in the setting of rheumatoid arthritis (Fig. 223).
  - Sternoclavicular arthritis may occur in patients with HLA-B27-associated spondylarthropathy (Fig. 224).
- ▶ **Sonographic findings:**
  - Convex hypoechoic or anechoic expansion of the joint capsule due to effusion in the acromioclavicular joint

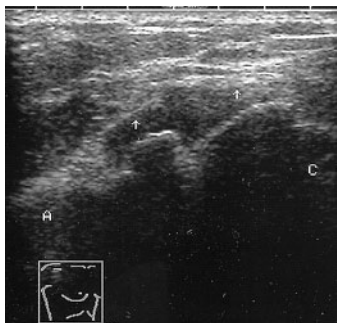


Fig. 223 Acromioclavicular arthritis in a patient with acute polyarthritis: inflammatory, hypoechoic thickening of the acromioclavicular joint capsule. A = acromion, C = clavicle

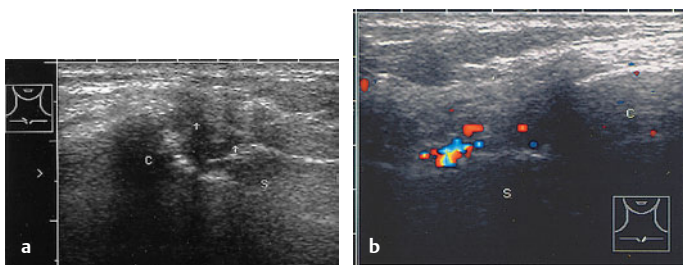


Fig. 224a, b HLA-B27-positive spondylarthritis of the sternoclavicular joint. **a** B-mode image: anechoic exudate (arrows). **b** CDS: inflammatory vascularization. S = sternum, C = clavicle

- Increased intra- or periarticular vascularity in the florid stage
- Erosions may be found in long-standing cases.

### Cubital Arthritis (Fig. 225)

- ▶ **Definition:** exudative or proliferative inflammation of the elbow joint in a setting of rheumatoid arthritis or other disease.
- ▶ **Sonographic findings:** anechoic effusions and hypoechoic synovitis, occurring mainly in capsular recesses (olecranon fossa, radial fossa, coronoid fossa).
- ▶ **Scanning tips:** Effusion can be dynamically provoked by flexing the elbow joint 30° (in anterior longitudinal scan).

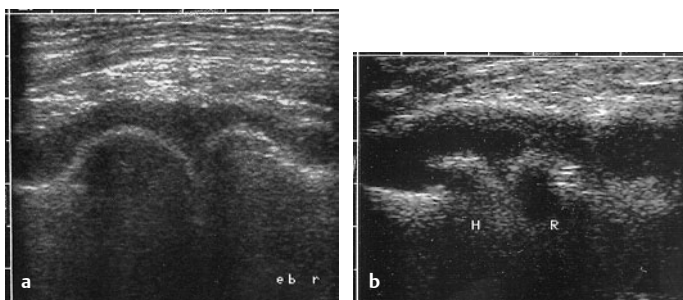


Fig. 225a, b Cubital arthritis in a patient with a long history of rheumatoid arthritis (anterior humeroradial longitudinal scan). **a** Hypoechoic synovitis. **b** Posterior longitudinal scan of the olecranon fossa

### Nodules in the Elbow Region

**Occurrence:** Masses and subcutaneous nodules are commonly found on the back of the elbow in patients with rheumatoid diseases.

- ▶ **Sonographic findings:**
  - Fluid-filled areas (e.g., olecranon bursitis or ganglion)
  - Solid structures that appear homogeneously hypoechoic (e.g., rheumatoid nodules, Fig. 226)

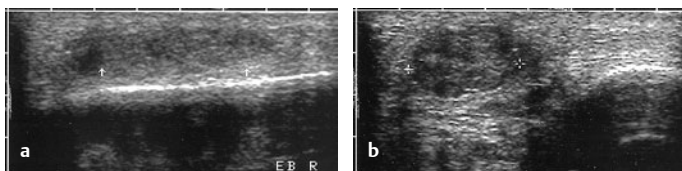


Fig. 226a, b Rheumatoid nodule: uniformly hypoechoic, noncompressible elliptical nodule. The patient presented clinically with arthralgia and strongly positive rheumatoid factors. **a** Longitudinal scan, **b** transverse scan

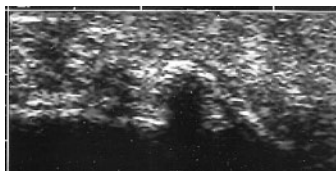


Fig. 227 Chronic gouty arthropathy: hyperechoic structures in the soft tissues with a posterior acoustic shadow (firm gouty nodules in the soft tissues about the elbow)

- Gouty tophi, which may contain high-level echoes with acoustic shadows or posterior comet-tail artifacts (Fig. 227)

### Articular Synovitis of the Finger and Toe Joints

- ▶ **Occurrence:** in inflammatory rheumatic diseases. The small joints of the fingers and toes tend to show early involvement, especially in rheumatoid arthritis.
- ▶ **Sonographic findings** (Figs. 228 and 229):
  - Convex hypoechoic or anechoicanechoic expansion of the joint capsule
  - Small, anechoic exudate
  - Erosive lesions
- ▶ **Scanning tips:**
  - Dynamic examination of the joints can accentuate subtle findings.
  - Always compare with adjacent and contralateral joints.

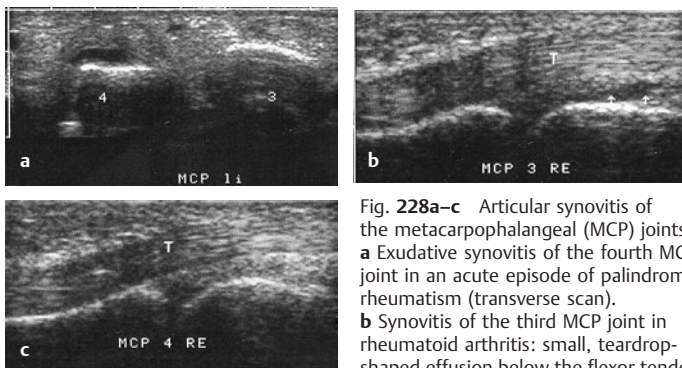


Fig. 228a–c Articular synovitis of the metacarpophalangeal (MCP) joints. **a** Exudative synovitis of the fourth MCP joint in an acute episode of palindromic rheumatism (transverse scan). **b** Synovitis of the third MCP joint in rheumatoid arthritis: small, teardrop-shaped effusion below the flexor tendon

(volar longitudinal scan). **c** Normal appearance of the fourth MCP joint of the right hand. T = flexor tendon

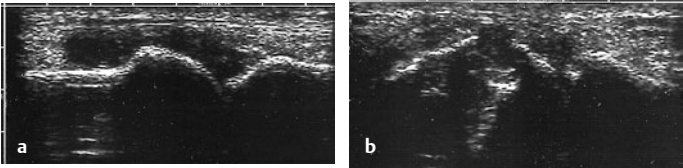


Fig. 229a–c Articular synovitis of the metatarsophalangeal (MTP) joint. **a** Erosive psoriatic arthritis; dorsal longitudinal scan over the first MTP joint shows exudation and marked hypoechoic expansion of the joint capsule with smooth dorsal bony contours. **b** Same patient: erosion detected by circumferential scanning. **c** Magnified view of **b** shows a deep defect with typical high-amplitude basal echoes

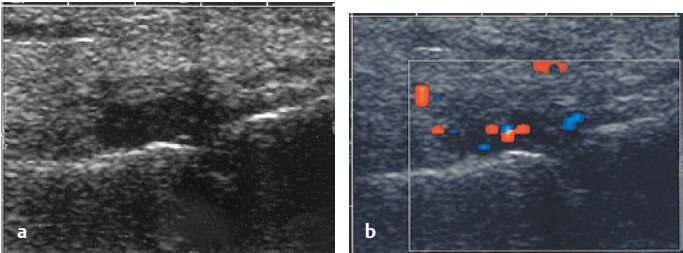


Fig. 230a, **b** Longitudinal scan over the third MTP joint during an attack of gout in a patient with gouty arthritis. **a** Hypoechoic expansion of the third MTP joint capsule of the right foot. **b** Marked increase in intra- and pericapsular vascularity

- With articular synovitis of the toes, ultrasound-guided percutaneous aspiration may be helpful in the detection of urate crystals, for example (differential diagnosis: gouty arthritis, Fig. 230).
- ▶ **Accuracy of sonographic diagnosis:** Ultrasound has established itself as a very sensitive modality for early diagnosis. Even mild erosions and synovitic changes that are not yet detectable by physical examination (e.g., teardrop-shaped exudates) can be detected sonographically.

### Arthritis of the Hip (Fig. 231)

- ▶ **Sonographic findings:** convex, hypoechoic area > 7 mm wide between the cortex and joint capsule at the junction of the femoral head and neck. A difference of > 2 mm between the right and left sides is abnormal.
- ▶ **Scanning tips:**
  - If findings are equivocal, it may be possible to increase the distance between the cortex and capsule by flexion.
  - Ultrasound-guided diagnostic aspiration may be required.

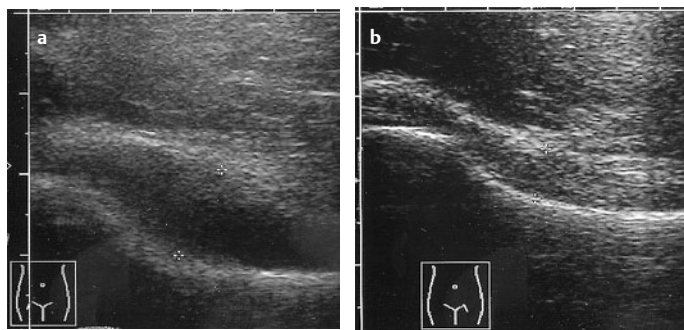


Fig. 231a, b Arthritis of the right hip in a patient with (presumably yersinia-reactive) spondylarthropathy. **a** Capsule of the right hip joint shows hypoechoic widening to 12 mm. **b** Capsule of the left hip joint is normal (6 mm). Ten days before, the patient presented with acute erythema nodosa; he presented now with peracute groin and leg pain and high *Yersinia* titers

- ▶ **Role of sonography in patients with suspected arthritis of the hip:**
  - *Detection of synovitis:* The anterior longitudinal scan can detect states of synovitic irritation with an increased intra-articular volume or effusion (convex hypoechoic expansion of the joint capsule).
    - Determine the distance between the femoral neck cortex and the echo of the fibrous joint capsule (see Table 7, p. 45, for normal and abnormal values).
    - Dynamic examination (slight flexion and rotation) can aid in the detection of even small effusion volumes.
  - *Ultrasound-guided joint aspiration:* accurate determination of the site and direction of needle insertion prior to diagnostic or therapeutic arthrocentesis
- ▶ **Differential diagnosis:** Synovitis requires differentiation from other intra- or peri-articular causes of pain (e.g., abscess, bursitis, hematoma).

### Arthritis of the Knee (Fig. 232)

- ▶ **Sonographic findings:**
  - Detection of hypoechoic effusion (exudative component) and echogenic villous synovial hypertrophy (proliferative component), chiefly in the anterior recess
  - Detection of erosive changes consistent with arthritis (see Fig. 211), p. 163)
  - Possible formation of a posterior C-shaped or dumbbell-shaped popliteal cyst
- ▶ **Scanning tips:**
  - Small amounts of exudate can be detected by active quadriceps contraction or palpation by the examiner.
  - With diffuse echogenic thickening of the capsule, use CDS to detect vascularity in the synovial villi.
- ▶ **Role of sonography in patients with suspected arthritis of the knee:**
  - *Detection of exudation:* It is common for marked exudative or proliferative synovitis to develop in the knee joint. Ultrasound can detect effusions in the supra- and papapatellar recesses. Synovial thickening is easily detected owing to the high impedance mismatch between the fluid effusion and the synovium.

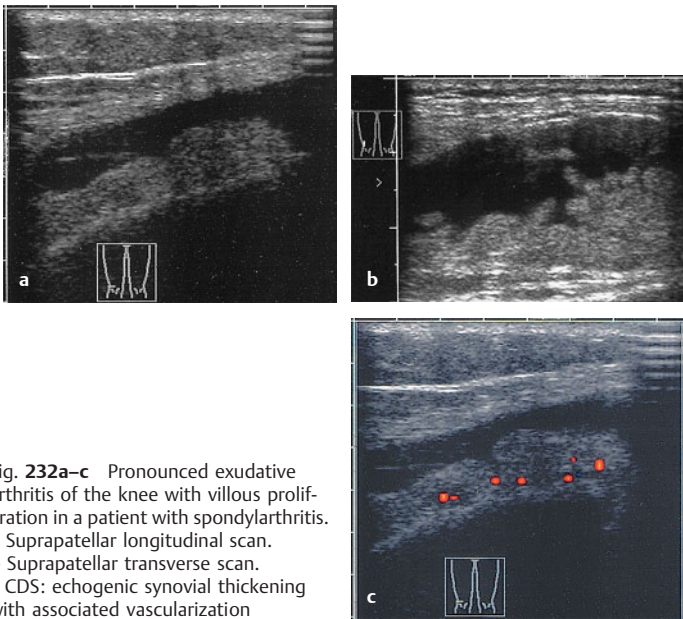


Fig. 232a–c Pronounced exudative arthritis of the knee with villous proliferation in a patient with spondylarthritis.  
**a** Suprapatellar longitudinal scan.  
**b** Suprapatellar transverse scan.  
**c** CDS: echogenic synovial thickening with associated vascularization

- **Detection of vascularity:** Hypertrophic villous synovitis is a common finding in many chronically arthritic knees. CDS can demonstrate peri- and intra-articular vascularization (signs of rheumatic synovial hypertrophy). A semiquantitative analysis can be done to assess the activity of the inflammation.

### Osteoarthritis of the Knee

- ▶ **Sonographic findings** (see Fig. 211), p. 163):
  - Marginal osteophytes in the medial or lateral joint space
  - Concomitant effusion signifying an activated osteoarthritis
- ▶ **Scanning tip:** Equivocal findings can be clarified by ultrasound-guided aspiration and synovial fluid analysis.

### Baker Cysts (Fig. 233)

- ▶ **Definition:** cystic outpouching of the synovium behind the knee
- ▶ **Occurrence:** in various inflammatory or degenerative diseases of the knee joint
- ▶ **Clinical manifestations:** Symptoms range from local pain to occasional acute episodes of severe, painful swelling of the calf and lower leg (differential diagnosis: below-knee deep venous thrombosis).
- ▶ **Sonographic findings:** The cyst appears in transverse section as a typical C-shaped or dumbbell-shaped mass bordering the gastrocnemius muscle. Generally it has a visible communication with the posterior joint space of the knee.
- ▶ **Accuracy of sonographic diagnosis:** In the typical case of an anechoic cystic mass, a typical Baker cyst can be quickly identified owing to the large impedance difference relative to the surrounding echogenic soft tissues (see Fig. 234).

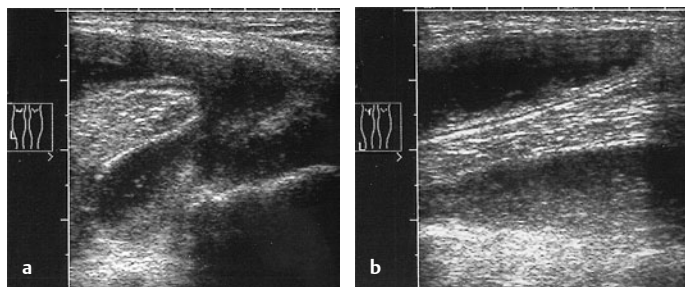


Fig. 233a, b Baker cyst appears as an elongated, tubular, almost anechoic mass. **a** Transverse scan, **b** longitudinal scan

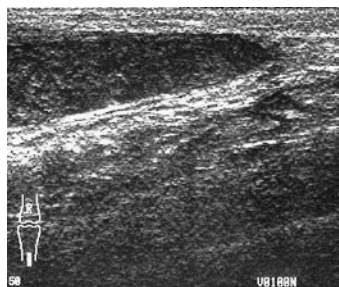


Fig. 234 Echogenic Baker cyst of the calf. A Baker cyst containing echogenic material extends some distance along the musculotendinous compartments of the lower leg. The patient presented clinically with chronic calf pain. A history of heavy smoking raised initial suspicion of peripheral arterial occlusive disease (PAOD), but vascular studies were normal. The symptoms resolved after cyst resection

### Arthritis of the Ankle Joint (Fig. 235)

#### ► Sonographic findings:

- Convex expansion of the anterior joint space between the tibia and talus
- The posterior joint space may show a tibiotalar effusion or synovitis.
- These findings are often accompanied by medial and lateral flexor tenosynovitis.

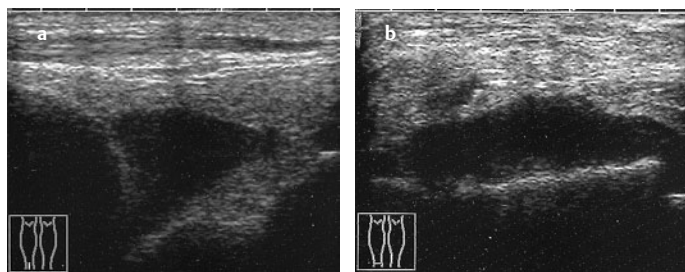


Fig. 235a, b Arthritis of the ankle joint: marked, hypoechoic expansion of the tibiotalar joint. **a** Longitudinal scan, **b** transverse scan

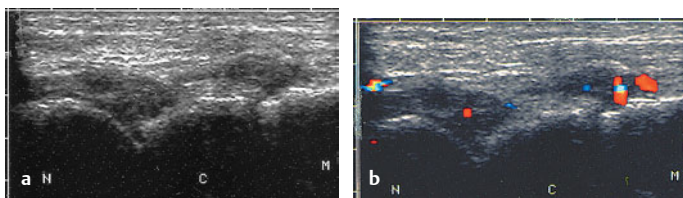


Fig. 236a, b Acute intertarsal synovitis between the navicular and cuneiform bones in a patient with SLE. N = navicular bone, C = first cuneiform bone, M = metatarsal bone

► **Scanning tips:**

- Dynamic examination with dorsiflexion of the ankle is helpful in detecting small amounts of effusion.
- If necessary, ultrasound can help locate a suitable site for diagnostic needle aspiration of the effusion.
- The examination should include metatarsal scans, as it is common to find associated inflammatory changes in that region (intertarsal or tarsometatarsal arthritis, see Fig. 236).

**Periarthritis (Fig. 237)**

- **Definition:** painful swelling involving the ankle joint and distal lower leg. Exudative synovitis is not present in the ankle joint.
- **Sonographic findings:** subcutaneous accumulations of fluid with no effusion in the ankle joint.

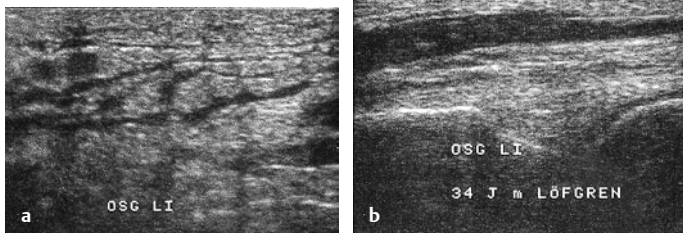


Fig. 237a, b Periarthritis in Löfgren syndrome. The patient presented clinically with acute ankle swelling. Erythema nodosa

**Tenosynovitis of the Malleolar Region (Fig. 238)**

- **Occurrence:** frequently accompanies inflammatory diseases of the ankle joint
- **Sonographic findings:** typical anechoicanechoic rim around the peroneus or tibialis posterior tendon

## Diffuse Goiter

- ▶ See also Palpable Masses, p. 102, and Thyroid Gland, p. 416.
- ▶ **Clinical manifestations:** increased neck circumference, possible globus sensation, swallowing difficulties. Large goiters may also cause superior vena cava compression, stridor, and recurrent respiratory tract infections. Adolescents are predominantly affected.
- ▶ **Diagnosis:**
  - *Examination, palpation:* painless, generally soft mass of varying consistency depending on the presence of regressive changes
  - *Laboratory findings:* thyroid function values within normal limits; basal TSH is usually satisfactory
  - Sonography
  - *Chest radiograph:* tracheal displacement? → tracheal spot film
  - Thyroid scintigraphy is rarely necessary.
- ▶ **Sonographic findings:**
  - Volume increased to more than 20 mL (volume = length (cm) × width (cm) × depth (cm) × 0.5)
  - Homogeneous normal or dense internal echo pattern; echogenicity slightly increased with a coarser texture
  - Secondary nodules may develop
  - *Regressive changes give rise to various features:*
    - *Cysts:* round, sharply circumscribed anechoic areas
    - *Calcifications:* echogenic specks with acoustic shadows
- ▶ **Accuracy of sonographic diagnosis:** The diagnostic accuracy is 85% when ultrasound findings are interpreted within the context of clinical and laboratory findings. CT and scintigraphy are unnecessary.

## Nodular Goiter (Figs. 240 and 241)

- ▶ See also Thyroid Gland, p. 422; Palpable Masses, Nodular goiter, p. 102.
- ▶ **Clinical manifestations:** same as diffuse goiter with palpable thyroid nodule (nodular transformation of a goiter)

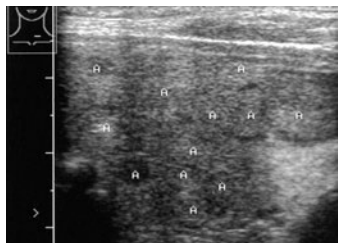


Fig. 240 Nodular goiter. The individual adenomatous nodules (A) are clearly delineated by their hypoechoic rims

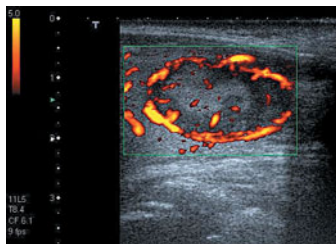


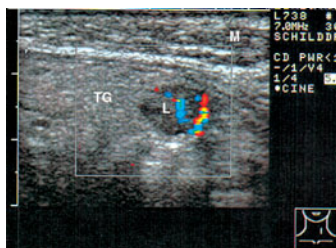
Fig. 241 Thyroid nodule with a hypoechoic halo, found to contain vascularity on power Doppler imaging

- ▶ **Diagnosis:**
  - *Laboratory findings:* hyperthyroid values (toxic nodular goiter)
  - Sonography
  - *Scintigraphy:* multifocal autonomy
- ▶ **Sonographic findings:** Multiple hypoechoic or isoechoic nodules.
- ▶ **Accuracy of sonographic diagnosis:** The sonographic findings plus the hyperthyroid metabolic state strongly suggest the correct diagnosis. Radionuclide scanning of the thyroid gland confirms multifocal autonomy
  - hypoechoic nodule that is “hot” by scintigraphy → unifocal autonomy
  - multiple hypoechoic nodules that are “hot” by scintigraphy → multifocal autonomy
  - “diffuse” goiter (nonhomogeneous = nodular goiter or homogeneous = thyroiditis, autoimmune thyreopathy) showing diffuse radionuclide uptake → disseminated autonomy.

### Adenoma (Fig. 242)

- ▶ See also Thyroid Gland, p. 419; Fig. 623, p. 419.
- ▶ **Clinical manifestations:** same as with a goiter. The clinical presentation with a hyperthyroid state may resemble that of Graves disease (with no ophthalmic symptoms or skin changes, see below).
- ▶ **Diagnosis:** Function values are changed according to the morphology of the adenoma.
  - *Sonography, scintigraphy:*
    - Macrofollicular adenomas are usually hyperechoic by ultrasound and functionally “cold” by scintigraphy.
    - Nodules that are hypoechoic by ultrasound are usually “hot” by scintigraphy.
    - Autonomy can be detected by suppression scintigraphy.
  - *Laboratory tests and further studies:*
    - Initially normal peripheral thyroid values and normal TSH (a “warm” nodule may still be found at scintigraphy). FNAB is necessary to exclude carcinoma, if scintigraphically “cold” nodule.
    - Later, peripheral thyroid values are still normal; scintigraphically “hot” nodule with suppressed (decreased) TSH
    - Possible hyperthyroidism (toxic adenoma)
- ▶ **Sonographic findings:**
  - Well-defined nodule with smooth margins (because adenomas have a capsule)
  - Markedly less echogenic than the rest of the thyroid gland (isoechoic to the surrounding neck muscles)
  - Somewhat nonhomogeneous echo distribution
  - Usually surrounded by a hypoechoic (vascular) halo.

Fig. 242 Thyroid adenoma. Nodular lesion (L) is markedly hypoechoic to the surrounding thyroid tissue (TG) and isoechoic to the surrounding neck muscles (M). CDS demonstrates the vascular supply to the adenoma



- ▶ **Accuracy of sonographic diagnosis:** The changes in the thyroid gland are clearly visualized. A complete hypoechoic or anechoicanechoic vascular halo, possibly combined with the absence of a scintigraphically “cold” nodule, strongly suggests the correct diagnosis. Additional tests are needed in these cases, depending on the functional status of the tumor. FNAB differentiates the lesion from a malignancy.

### Graves Disease (Autoimmune Thyropathy, Figs. 243 and 244)

#### ▶ Clinical manifestations:

- **Goiter** (frequently present): rapid increase in neck circumference, swallowing difficulties
- **Hyperthyroidism:** nervousness (often presents as apathy in the elderly, mimicking hypothyroidism); sleep disturbance, sweating, diarrhea, tremor, muscle weakness, weight loss, hair loss, tachycardia, heart failure, angina pectoris
- **Ophthalmic signs:** generally bilateral (lymphocytic histiocytic infiltration of the orbits), exophthalmos, chemosis, conjunctivitis, periorbital swelling. Complications involving the cornea and optic nerve may also occur.
- **Cutaneous changes:** localized myxedema (e.g., pretibial); orange-peel appearance of the skin, possible hyperpigmentation and pruritus

#### ▶ Diagnosis:

- **History, palpation:** A normal-sized thyroid gland makes the diagnosis unlikely
- **Laboratory tests, thyroid function values:**
  - TSH low or not measurable; FT<sub>3</sub> and FT<sub>4</sub> elevated
  - If the diagnosis is still uncertain, additional laboratory parameters can be determined: thyroid-stimulating immunoglobulin (TSI); TSH receptor antibodies (TRAb) detected in 90% of cases; microsomal antibodies (MAB, identical to peroxidase antibodies, TPO Ab) detected in 70% of cases.
- Percutaneous biopsy for histologic evaluation (diffuse lymphocytic infiltration) may be done if a thyroid malignancy is suspected.

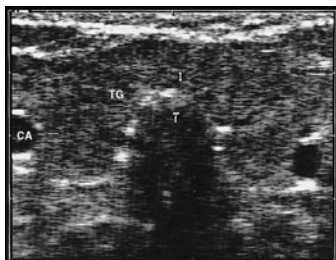


Fig. 243 Graves disease: hypoechoic thyroid tissue (TG) with a greatly enlarged isthmus (I).

CA = carotid artery, T = trachea

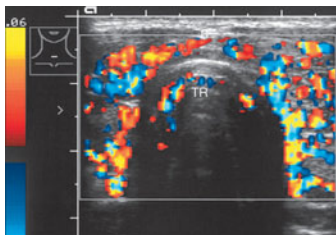


Fig. 244 The hypervascularity in Graves disease produces a “vascular inferno” pattern on CDS. Median transverse scan of the neck. TR = trachea

► **Sonographic findings:**

- Diffuse or asymmetrical enlargement of the thyroid gland
- Involvement of the isthmus
- Bounded borders
- Homogeneous, stippled hypoechoic parenchymal pattern
- Focal changes appear hyperechoic to their surroundings
- *CDS*: increased vascularity.

► **Accuracy of sonographic diagnosis:** The hypoechoic parenchymal pattern of Graves disease combined with marked, balloon-like swelling of the isthmus suggests the correct diagnosis. The presence of typical clinical signs further supports the diagnosis, and the detection of typical antibodies confirms it. If there are no definite signs of autoimmune disease, Graves disease may be indistinguishable from diffuse autonomous hyperthyroidism even by scintigraphy.

### Hashimoto Thyroiditis (Chronic Lymphocytic Thyroiditis, Autoimmune Thyroiditis, Fig. 245)

► **Clinical manifestations:** no pain or other complaints. As the disease progresses, the goiter regresses and the thyroid gland shrinks in size.

- *With hypothyroidism:* fatigue, hypersensitivity to cold, skin and hair changes (cold, dry, rough, pale yellow skin, coarse hair), thick tongue
- The disease may begin with a hyperthyroid phase.

► **Diagnosis:**

- *History and palpation:* The thyroid gland initially has a tense, rubbery consistency.
- *Laboratory findings:*
  - Anemia, elevated ESR, dysproteinemia, hypercholesterolemia
  - *Abnormal thyroid values:* elevated TSH, low FT<sub>3</sub>, low FT<sub>4</sub> in some cases. Antimicrosomal thyroid antibodies (MAb, specifically antibody-TPO Ab) elevated in 85% of cases; antithyroglobulin antibodies elevated in 50% of cases

• Sonography

- *Percutaneous biopsy:* Histology shows lymphocytic and plasma-cell infiltration with follicle formation, destruction, and atrophy.

► **Sonographic findings:**

- Diffusely hypoechoic (isoechoic or hypoechoic to the neck muscles)
- Nonhomogeneous echo pattern
- The thyroid gland is usually small (but may be enlarged).

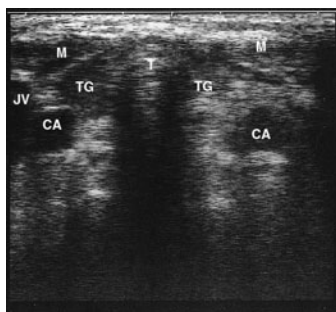


Fig. 245 Hashimoto thyroiditis: small, hypoechoic thyroid lobe (TG), approximately isoechoic to the neck muscles (M). Its size is reduced to the approximate diameter of the common carotid artery (CA). JV = jugular vein

- ▶ **Accuracy of sonographic diagnosis:** The echogenicity of the parenchyma should always be compared with that of the neck muscles. When this is done, Hashimoto thyroiditis can be diagnosed with reasonable confidence and is usually distinguishable from Graves disease. Additional laboratory tests are necessary.

### Acute Suppurative Thyroiditis

---

- ▶ See also Thyroid Gland, p. 419.
- ▶ **Clinical manifestations:** inflammatory signs: swelling, erythema, local warmth and tenderness, fever; transient signs of hyperthyroidism
- ▶ **Diagnosis:**
  - *History:* bacterial inflammation arising within hours, particularly after the incision and drainage of an abscess (e.g., perianal abscess, etc.)
  - *Laboratory findings:* leukocytosis with a left shift, elevated ESR and CRP
  - Sonography
  - Needle aspiration may be used to identify the infecting organism (while also evacuating the abscess); ultrasound-guided aspiration of the abscess (early antibiotic therapy is required)
- ▶ **Sonographic findings:**
  - Nonhomogeneous pattern of low- and high-level internal echoes
  - Normal-sized thyroid gland
  - Occasional hypoechoic to anechoic round lesions indicating abscess formation. In this case the thyroid is extremely tender to probe pressure, has smooth outlines, and contains coarse internal echoes.
- ▶ **Accuracy of sonographic diagnosis:** The sonographic signs are clearly defined, especially when liquefaction has occurred. A definitive diagnosis can be made when the sonographic signs are combined with clinical findings and percutaneous aspiration.

### Acute Nonsuppurative Thyroiditis (Subacute Granulomatous Thyroiditis, De Quervain Thyroiditis)

---

- ▶ See also Thyroid Gland, p. 415.
- ▶ **Clinical manifestations:** The disease begins with a viral infection. Early signs are dysphagia, hoarseness, and throat pain radiating to the ear. Transient manifestations of hyperthyroidism.
- ▶ **Diagnosis:**
  - *History, palpation:* firm, tender thyroid gland that may be swollen. Regional lymph nodes swollen and tender
  - *Laboratory findings:* elevated ESR, possible mild leukocytosis. Thyroid values initially normal, but hypothyroidism may supervene
- ▶ **Sonographic findings:**
  - Thyroid gland may be normal-sized or diffusely enlarged.
  - Patchy, hypoechoic parenchymal pattern. The echo pattern changes with the stage of the disease and in response to treatment.
  - Hypoechoic to anechoic areas with ill-defined margins
  - CDS: increased vascularity
- ▶ **Accuracy of sonographic diagnosis:** The diagnosis can be made only in conjunction with ultrasound-guided FNAB. The differential diagnosis includes silent and postpartum thyroiditis, which have no viral symptoms and a diffuse, hypoechoic appearance on ultrasound.

### Riedel Thyroiditis (Fibrous, Stony-Hard Goiter)

- ▶ See also Thyroid Gland, p. 426.
- ▶ **Clinical manifestations:** inflammation spreading past the thyroid boundaries, leading to fibrosis; stridor, hoarseness, inflow stasis
- ▶ **Diagnosis:**
  - *History, palpation:* stony-hard thyroid gland, immobile, usually affecting one lobe
  - *Laboratory findings:* low peripheral thyroid values with elevated TSH
  - *FNAB with histology:* hyaline connective tissue
- ▶ **Sonographic findings:**
  - Diffusely hypoechoic
  - Tense, rounded borders
- ▶ **Accuracy of sonographic diagnosis:** Ultrasound yields a presumptive diagnosis, which is confirmed by histology.

### Thyroid Malignancy (Fig. 246)

- ▶ See also Thyroid Gland, p. 420.
- ▶ **Classification:**
  - *Metastases:* Most frequent sources are malignant melanoma, bronchial carcinoma, breast carcinoma, and esophageal carcinoma.
  - *Parafollicular cells* (medullary C-cell carcinoma): four subgroups, such as MEN
    - Papillary carcinoma (70%)
    - *Follicular carcinoma* (15%): like normal thyroid epithelium; has a capsule like adenoma but is distinguishable from adenoma by infiltration of the capsule or vessels; undergoes early distant metastasis (to lung, bone, CNS). Hürthle's tumor is particularly unfavorable because of its invasiveness
    - *Anaplastic carcinoma* (5%): high-grade malignancy marked by extensive local infiltration, refractory to treatment
- ▶ **Clinical manifestations:** frequent neoplastic disease (bronchial tumor, breast carcinoma, malignant melanoma, esophageal carcinoma, also thyroid lymphoma) with metastasis; possible hyperthyroidism; stridor
- ▶ **Diagnosis:**
  - *History:*
    - Patients 50–70 years of age (papillary carcinoma has a second peak incidence in the second and third decades of life)
    - Roentgen exposure in infancy and childhood, no hoarseness, known chronic lymphocytic thyroiditis (Hashimoto), and a rapidly enlarging mass are strongly suggestive of lymphoma.
  - *Palpation:* goiter with a solitary nodule, fast-growing. Lymph node metastases are often already present at the time of diagnosis. Tumor nodule has a hard consistency and is nontender.
  - *Laboratory findings* (usually have little significance): Most patients are euthyroid, and a small number are hyperthyroid. Serum calcitonin is a tumor marker for medullary C-cell carcinoma.
  - Sonography
  - FNAB is an essential study.
  - Scintigraphy may be done as an adjunct, demonstrating a cold nodule.

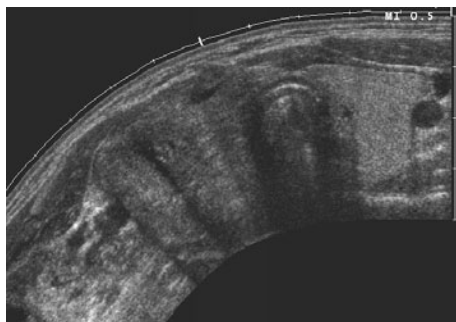


Fig. 246 Papillary carcinoma of the right lobe of the thyroid gland: multiple hypoechoic masses, partially infiltrating the anterior neck muscles. The left thyroid lobe appears normal (SieScape panoramic image, courtesy of Dr. Strobel, Erlangen, Germany)

- ▶ **Sonographic findings:** A very dominant, hypoechoic nodule is strongly suggestive of carcinoma, especially in cases where bleeding has caused rapid enlargement.
  - *Cystic node morphology:* anechoicanechoic round lesion; percutaneous aspiration and cytologic examination of the cyst contents are usually diagnostic and therapeutic.
  - *Solid node morphology:* hypoechoic, nonhomogeneous, ill-defined margins, with or without a peripheral halo. Possible diagnoses:
    - Parafollicular (C-cell) carcinoma
    - Follicular carcinoma with a capsule
    - Papillary carcinoma without a capsule, glows slowly by infiltration, spreads to cervical lymph nodes
    - Anaplastic carcinoma
  - *Mixed node morphology:* May be seen with any carcinoma:
    - Cystic lesions with intralesional hemorrhage, nonhomogeneous
    - Stippled and coarse calcification patterns
  - *Metastases:* round lesions, can be differentiated only by FNAB; primary tumors at other sites
  - *Lymphoma:* focal, relatively hypoechoic, ill-defined margins
- ▶ **Accuracy of sonographic diagnosis:** Solid and cystic lesions can be identified sonographically in almost all cases. The differentiation of benign and malignant lesions relies on aspiration cytology or, if necessary, excisional biopsy for further (operative) treatment planning.
- **Caution:** All hypoechoic nodules > 10 mm that do not have a closed hypoechoic rim require cytologic or even surgical investigation.

## Amyloidosis

- ▶ **Classification:**
  - Primary amyloidosis
  - Amyloidosis associated with plasmacytoma
  - *Secondary or reactive amyloidosis:* in chronic infectious diseases or chronic inflammatory processes
  - Familial amyloidosis
  - *Local amyloidosis:* presents like a tumor, occurs predominantly in endocrine organs
  - Age-related amyloidosis
  - Amyloidosis during chronic dialysis therapy

- ▶ **Clinical manifestations:** depend on the underlying disease. Local amyloidosis of the thyroid gland may present like a simple goiter (see above). Functional deficits are generally rare but are common with medullary thyroid carcinoma.
- 🚩 **Caution:** The carcinoma cells may be missed by FNAB.
- ▶ **Diagnosis:**
  - *Palpation:* firm thyroid gland
  - Sonography of the thyroid gland and parenchymal abdominal organs; echocardiography
  - Percutaneous thyroid biopsy
  - Rectoscopy with rectal biopsy to distinguish a systemic disease from local amyloidosis (biopsy specimen is fixed in alcohol and sent to pathology for definitive evaluation)
  - Investigation of other underlying diseases (see above)
- ▶ **Sonographic findings:**
  - Enlarged thyroid gland
  - Echo pattern is usually homogeneous but may be irregular in some cases
  - Coarse, high-level internal echo pattern.
- ▶ **Accuracy of sonographic diagnosis:** As with most focal lesions, a specimen should be taken for cytologic evaluation.

## 7 Arteries and Veins

### 7.1 Examination

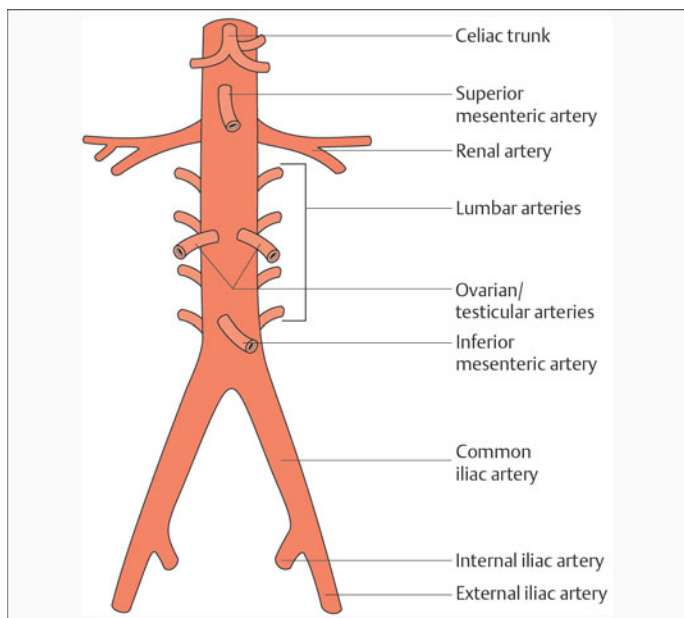
#### Abdominal Vessels

##### ► Scan planes:

- Upper abdominal transverse scan (see p. 22)
- Upper abdominal longitudinal scan (see p. 29)
- Supplementary scan planes

##### ► Sonographic anatomy and normal findings:

- **Aorta** (Figs. 247–249):
  - The aorta runs anterior and slightly to the left of the vertebral column, appearing as a smooth, throbbing, largely anechoic vascular band. It gives off parietal and visceral branches before dividing into the common iliac arteries just below the umbilicus.
  - The aortic wall presents a three-layered structure: two echogenic zones separated by a hypoechoic zone (the two inner layers represent the thickness of the intima and media, respectively).
- **Inferior vena cava** (see Fig. 35), p. 28; Fig. 476, p. 324): The inferior vena cava ascends to the right of and parallel to the aorta, its parietal and visceral tributaries (renal veins) corresponding to the aortic branches. It has a “soft” consis-



188 Fig. 247 Parietal and visceral branches of the aorta

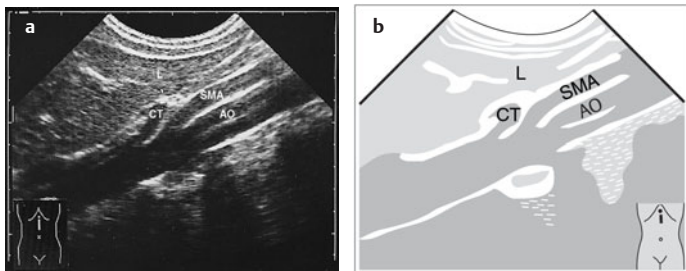


Fig. 248a, b Upper abdominal longitudinal scan of the celiac trunk. CT = celiac trunk, SMA = superior mesenteric artery, AO = aorta, L = liver

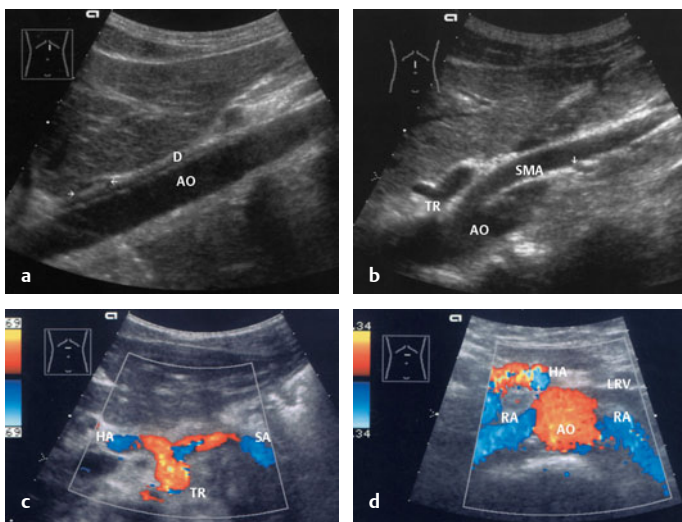


Fig. 249a–d a, b Upper abdominal longitudinal scan of the aorta (AO), the celiac trunk (TR), and the superior mesenteric artery (SMA) with the first jejunal branch (arrow). Horizontal arrows: lower esophagus. D = shank of the muscular diaphragm c, d Upper abdominal transverse scan of the celiac trunk (TR), the common hepatic artery (HA) and the splenic artery (SA), and the branch of the renal arteries (RA). AO = aorta, LRV = left renal vein, crossing the aorta

tency, and its caliber can be seen to fluctuate with respirations. It contains no internal echoes and shows typical double pulsations.

- **Portal vein** (Figs. 250 and 251): The portal vein is formed by the confluence of the visceral veins. It passes behind the head of the pancreas to the porta hepatis, where it divides into a right and left main branch that undergo further arborization in a capillary system.
- **Venous confluence** (Figs. 250 and 252): The venous confluence is located behind the head of the pancreas, appearing sonographically as an elliptical expansion of the vena cava. It is formed by the superior mesenteric vein, the inferior

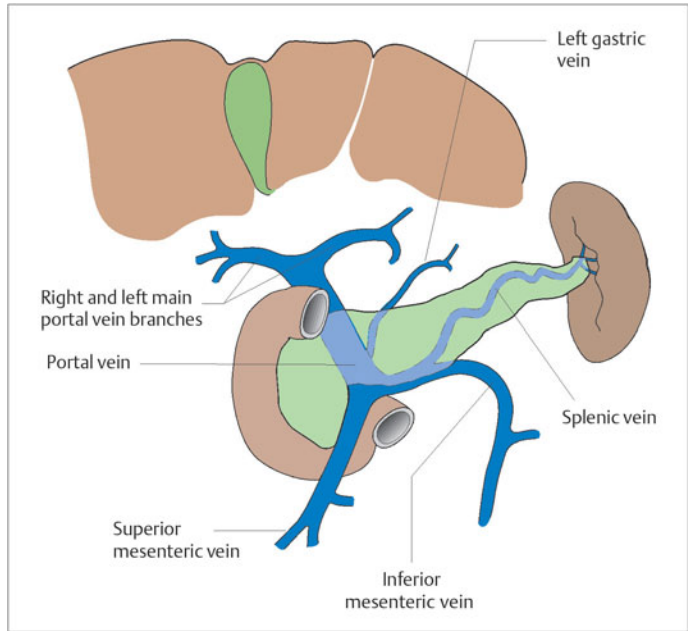


Fig. 250 Portal vein and its tributaries

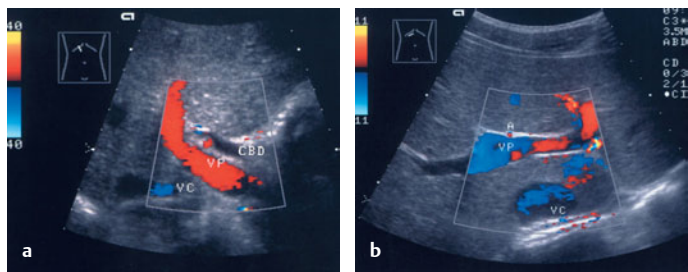


Fig. 251a, b Course of the portal vein. **a** Longitudinal scan: the portal vein in its longitudinal axis (red) behind the common bile duct (CBD) and the hepatic artery (red spot). VC = vena cava **b** Oblique scan: T-shaped division of the portal vein (VP) into the right and left main branches. A = hepatic artery, VC = caval vein

mesenteric vein (which usually empties into the splenic vein), the left gastric vein, and the splenic vein.

► **Scanning tips:**

- Look for respiration-dependent volume changes in the venous system (inspiratory collapse of the vena cava; end-inspiratory expansion of the portal vein >2 mm or 50–100%).
- Compress and push aside overlying gas-filled loops of bowel.

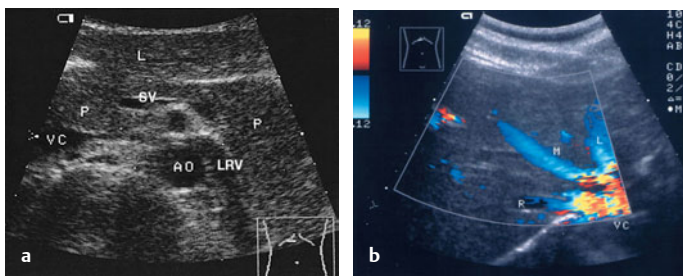


Fig. 252a, b Venous vessels in the upper abdomen. **a** Upper transverse scan. AO = aorta, P = pancreas, SV = splenic vein, L = liver, VC = vena cava, LRV = left renal vein, crossing the aorta **b** Upper abdominal oblique scan: right (R), middle (M), and left (L) hepatic veins confluent into the inferior caval vein (VC)

### Peripheral Vessels

- ▶ **Scan planes:** The scan planes should conform to the anatomical course of the imaged vessels.
- ▶ **Sonographic anatomy and normal findings:**
  - As in the abdomen, typical differences are noted between the arteries and veins of the peripheral vascular system (pulsations, caliber changes with respirations)
  - The anatomical relationships of the principal lower-extremity vessels are shown in Fig. 253 and in Figs 286 and 287 on p. 210.
  - The veins of the lower extremity generally run posterior to the arteries.
  - Arteries are almost incompressible, whereas veins are highly compressible in response to transducer pressure.
- ▶ **Scanning protocol:**
  - *Transducer:* 3.5–7.5 MHz
  - *Supine position:* The lower leg veins are scanned with the leg hanging over the edge of the table. The popliteal vessels are scanned in the prone position (where the popliteal vein is closer to the transducer and the artery is farther away).
  - Begin the examination with transverse survey scans, then scan longitudinally in planes that conform to the course of the vessels.
  - Standard scans may be supplemented by CDS (p. 7) to detect peripheral flow (floating thrombi?), collateral channels, recanalization processes, or pelvic venous thrombi.
- ▶ **Scanning tips:**
  - Carefully controlled transducer pressure will reduce scattering artifacts.
  - Gentle transducer movements make it easier to detect arterial pulsations.
  - Slipping of the transducer under pressure leads to errors of interpretation; the incompressible artery should therefore be defined along with the vein whenever possible.
  - The probe should be applied very carefully in the popliteal fossa because the popliteal vein is subcutaneous and easily compressible, and cannot be visualized when in a normal state.
  - The vessels at the pelvic level are easier to define when the bladder is slightly distended.

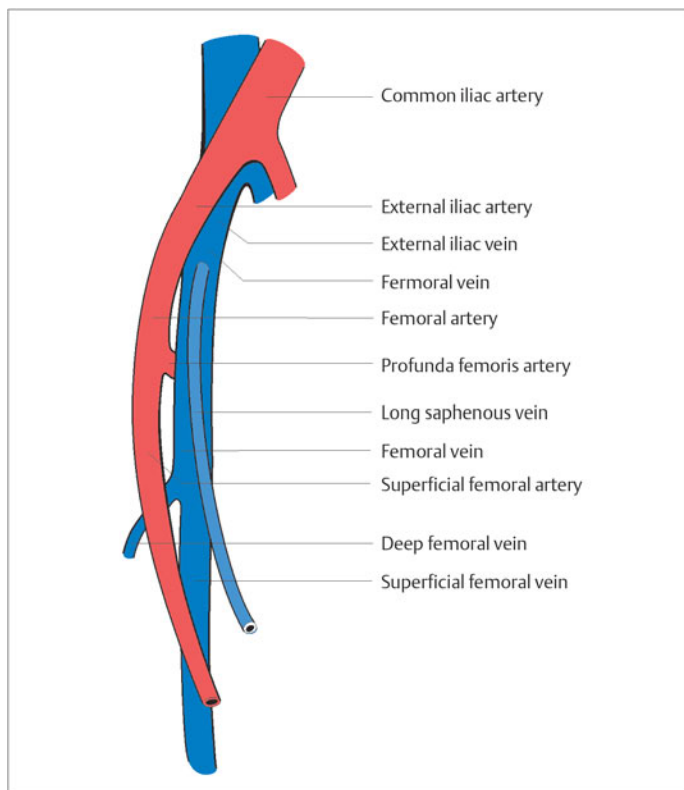


Fig. 253 Vascular topography of the right upper leg

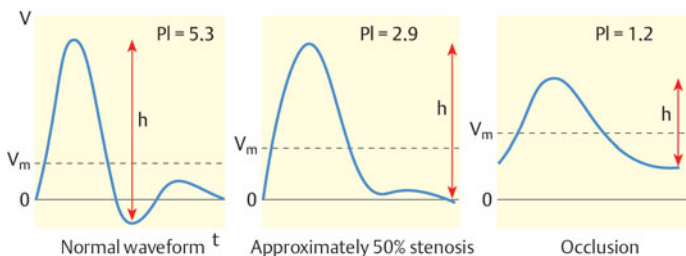
### Overview of Findings, Classification

- ▶ **Aorta and arteries:** The intra- and retroperitoneal vessels provide important landmarks for localization and anatomical orientation (just as the neck vessels aid in examination of the thyroid gland and lymph nodes).
  - *Changes due to atherosclerosis:* Diseases of the aorta and arteries most commonly result from atherosclerosis, which leads to expansion, narrowing, and occlusion of the affected vessel (see p. 197).
  - *Hemodynamic changes:*
    - Detectable only by Doppler scanning or CDS (see p. 7). The B-mode image reflects only morphological changes.
    - *Detection of stenoses:* Stenotic lesions can be described morphologically by spectral analysis and analyzed semiquantitatively by the measurement of flow velocities (see Table 30 and Fig. 254).

**Table 30** · Normal values for flow velocities and Doppler indices

Vessel	PI	RI	$V_{\max}$ (cm/s)	$V_{\min}$ (cm/s)
Abdominal aorta	2–6		50–120	
Common femoral artery	5–10		100	
Popliteal artery	6–12			
Renal artery		0.6–0.8	60–180	30
Celiac trunk		0.6–0.8	100–240	
Superior mesenteric artery		0.75–0.9	120–220	
Inferior mesenteric artery		0.8–0.9	100–150	

PI = pulsatility index (for peripheral arteries), RI = resistance index (for parenchymal arteries, e.g., the renal arteries)



**Fig. 254** Pulsatility index (PI) and velocity waveform versus degree of stenosis in normal and abnormal extremity waveforms. The PI is calculated by dividing the difference between the maximum forward and reverse flow velocities ( $h$ ) by the mean value of the flow velocity ( $V_m$ ) (from Neuerburg-Heusler D, Hennerici M. *Gefäßdiagnostik mit Ultraschall*. Thieme, 1995)

- **Classification of findings:**
  - *By etiology:* see Table 31, p. 194.
  - *By location:* see Table 32, p. 201.

► **Vena cava and peripheral veins:**

- Veins are important sonographically both as landmarks for anatomical orientation and as potential sites of pathologic change. Thrombosis has the greatest clinical significance.
- *Classification of findings:* see Table 34, p. 208.

## 7.2 Aorta and Arteries

### Overview: Etiologic Classification of Changes (Table 31):

**Table 31** · Classification of sonographic findings by etiology

Anomalies	Traumatic and postoperative lesions
Duplications	False aneurysm (p. 195)
Arterial variants (p. 194)	Arteriovenous fistula (p. 195)
	Arterial prosthesis (p. 195)
Sequelae of hypertension and atherosclerosis	Displacement, compression, infiltration
Aortic or arterial elongation (p. 197)	Benign masses (p. 200)
Aortic ectasia (p. 197)	Malignant masses (p. 200)
Aortic or arterial stenosis (p. 197)	
Aneurysms (p. 198)	

### Anomalies

- ▶ **Duplication anomalies:** renal artery (Fig. 255), rarely the aorta
- ▶ **Arterial variants:**
  - **Renal arteries:** course anterior (usually posterior) to the vena cava
    - Left gastric artery arises from the superior mesenteric artery or from the aorta (“hepatosplenic trunk”)
    - Common origin of the superior mesenteric artery and celiac trunk (“celiacomesenteric trunk,” Figs. 256 and 257)
  - **Aorta:** may show an oblique or transverse course as a result of spinal scoliosis

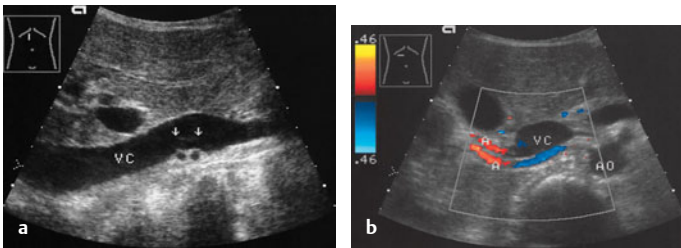


Fig. 255a, b Duplicated renal artery. **a** Longitudinal scan: two arterial cross-sections (arrows) are visible behind the vena cava (VC). **b** Transverse scan through the right upper abdomen. CDS demonstrates both renal arteries (A). The possibility of duplication should always be considered when renal artery stenosis is suspected

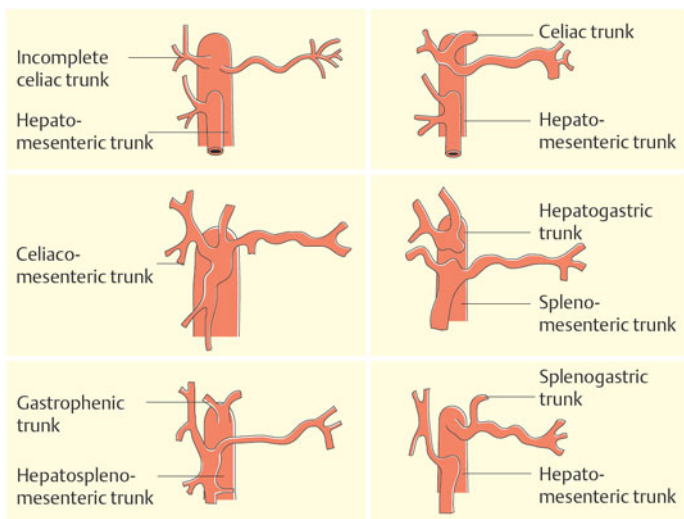
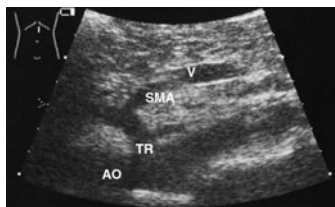


Fig. 256 Variants of the celiac trunk (after Netter)

Fig. 257 Atypical origin of the superior mesenteric artery (SMA) from the celiac trunk (TR): celiacomesenteric trunk. V = superior mesenteric vein



### Traumatic and Postoperative Lesions

- ▶ **Pseudoaneurysm (false aneurysm)** (Fig. 258): most commonly results from puncture of the femoral artery; arterial wall defect with pulsatile blood jets into the adjacent tissue. CDS: systolic–diastolic “to and fro” pulsed Doppler waveform
  - *Treatment:* graded groin compression under CDS guidance is usually successful in closing the leak (alternative: adhesive).
- ▶ **Arteriovenous fistula:** Abnormal communication between a high-resistance artery and a low-resistance vein without an intervening capillary bed (Figs 259, 260).
- ▶ **Arterial prosthesis** (see Fig. 279a), p. 205, and Fig. 281a, p. 206):
  - Smooth, straight echogenic structure (polyethylene), occasionally with a finely meshed texture (Dacron)
  - *Rare:* periprosthetic infection or hematoma due to leakage. An irregular, hypoechoic structure can be seen around the prosthesis.

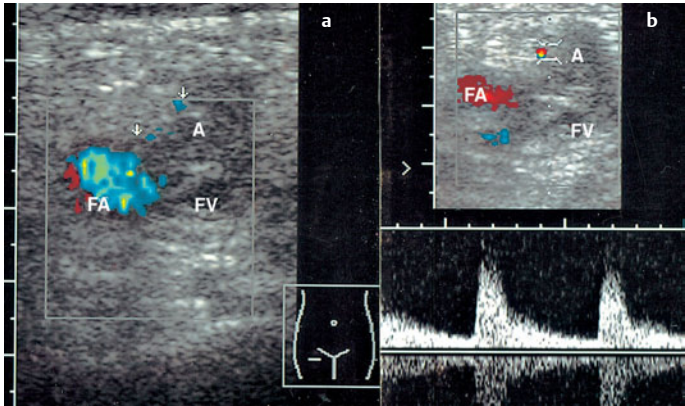


Fig. 258a, b Heavily thrombosed pseudoaneurysm (A) of the femoral artery (FA) following percutaneous catheterization. **a** Residual flow (blue, arrows). **b** Arterial Doppler signal (red). FV = thrombosed femoral vein

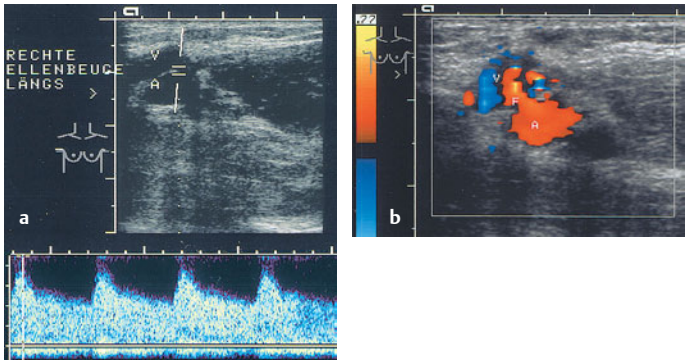


Fig. 259a, b Arteriovenous fistula of the cubital artery and vein (A, V). **a** B-mode image with spectral analysis demonstrates a fistulous connection between the artery and vein. The sampled spectral waveform shows an arterial signal at the fistula site. **b** CDS directly defines the fistula (F) and shows a turbulent pattern in the vein (blue-red)

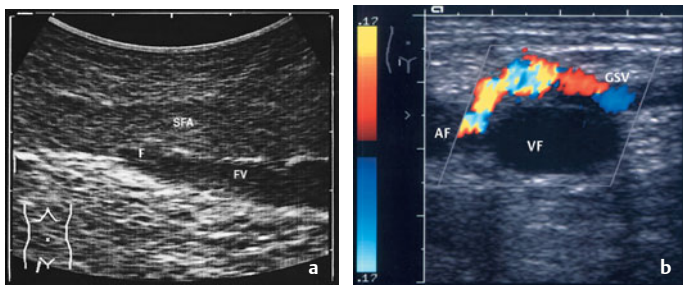


Fig. 260a, b Arteriovenous fistula (F). **a** From the superficial femoral artery (SFA) to the femoral vein (FV) following a shrapnel injury. The patient presented clinically with signs of left heart failure, which resolved after closure of the fistula. **b** Between the femoral artery (AF) and the greater saphenous vein (GSV) after catheterization showing a turbulent yellow–blue–red pattern in the fistula. VF = femoral vein

### Sequelae of Hypertension and Atherosclerosis

- ▶ **Aortic or arterial elongation** (Figs. 261 and 262): Tortuosity and kinking may develop as an adaptive response to pressure.
- ▶ **Aortic ectasia** (see Fig. 261): dilatation of the aorta to 25–30 mm (often with an associated aneurysm)
- ▶ **Aortic and arterial sclerosis** (Fig. 263; see also Fig. 261):
  - Vascular stenosis resulting from lipid-containing atheromatous wall lesions
  - Complicated atherosclerotic plaques: protuberant, calcified sites of luminal narrowing (see p. 201)

Fig. 261 Elongation, ectasia, and sclerosis of the aorta. The aorta is slightly elongated and presumably has undergone marked lateral kinking because its full length cannot be visualized (a similar pattern is seen with spinal curvature). The aorta is markedly ectatic (cursors) and shows echogenic wall sclerosis with associated acoustic shadows

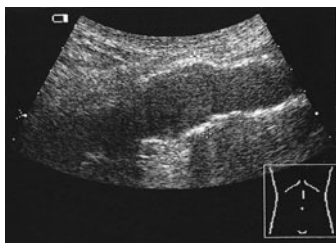
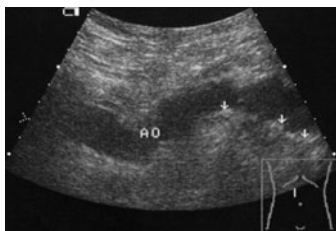
Fig. 262 Tortuosity of the aorta (AO) secondary to hypertension and atherosclerosis. Arrows: atherosclerotic lesions



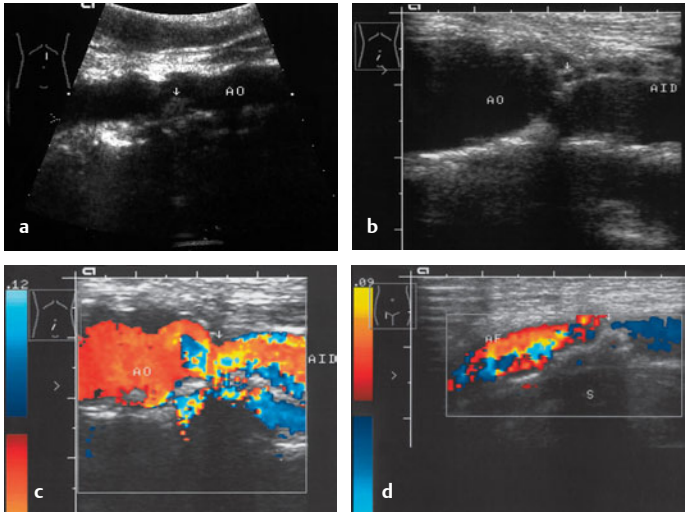


Fig. 263a–d Atherosclerosis and stenosis. **a** Protuberant plaque in the aorta (AO, arrow) with luminal narrowing and atherosclerotic wall irregularities. **b** Iliac artery stenosis. B-mode image shows high-grade narrowing of the proximal iliac artery (arrow). **c** Iliac artery stenosis. CDS demonstrates the stenosis (arrow). Zones of color reversal indicate turbulent flow. **d** Stenosis (arrow) of the femoral artery. CDS shows prestenotic color change and turbulence. The high-grade luminal narrowing is caused by a calcifying plaque with an associated acoustic shadow (S)

► **Aneurysms** (Figs. 264–268; see also Figs. 276–278, p. 204):

- *Types of aneurysm* (Fig. 264):
  - Berry (pouch-)shaped
  - Saccular
  - Fusiform (spindle-shaped)
  - Dissecting

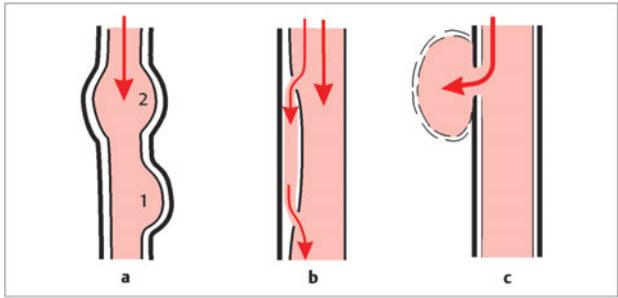


Fig. 264 Types of arterial aneurysm. **a** True aneurysms, saccular or fusiform (2) and berry (pouch-)shaped (1). **b** Dissecting aneurysm. **c** Pseudoaneurysm (or false aneurysm)

- **Note:** A dissecting aneurysm may occur without luminal enlargement.
- False aneurysm (“pulsating hematoma”; see above)
  - Arteriovenous fistula without luminal enlargement; see above
  - **Sonographic criteria:**
    - Circumscribed or diffuse dilatation (aorta >30 mm)
    - Atherosclerotic plaques (see p. 203)
    - Thrombi

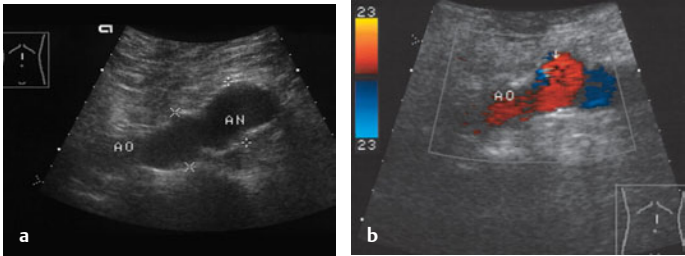


Fig. 265a, b **a** Serpentine aneurysm (cursors, AN) arising from a normal-sized aorta (AO) and forming a largely asymmetrical series of dilations. **b** CDS appearance of a typical small, asymmetrical anterior wall protrusion (arrow)

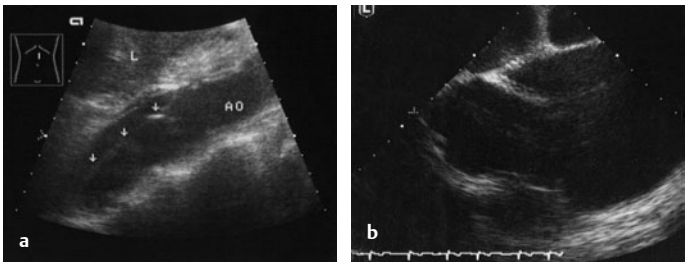


Fig. 266a, b **a** Dissecting aneurysm. **a** Intraluminal echogenic intima (arrows). **b** TEE demonstrates the intimal flap in the aortic lumen of the thoracic aorta, longitudinal scan

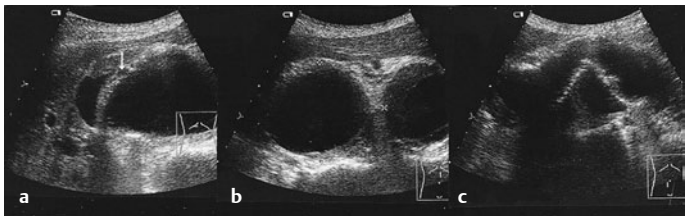


Fig. 267a-c “Aneurysmosis” involving all of the infradiaphragmatic aorta with ectasia, thromboses, and apparent intimal dissection (prebifurcation, cranial?) with a thin flap (arrow) extending into the gallbladder bed.

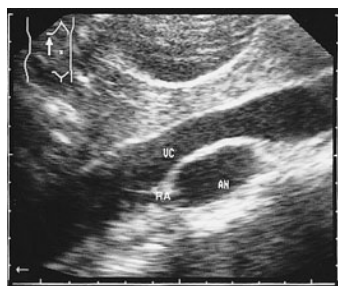


Fig. 268 Aneurysm (AN) of the right renal artery (RA) posterior to the vena cava (VC)

### Displacement, Compression, and Infiltration

- ▶ **Benign masses** (such as cyst or abscess): These lesions tend to displace arteries rather than compress them. Infiltration does not occur.
- ▶ **Malignant masses** (such as malignant lymphoma and carcinoma, Figs. 269, 270): Lymphomas tend to displace and compress vessels, whereas carcinomas infiltrate them.

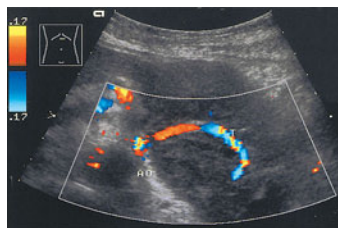


Fig. 269 High-grade non-Hodgkin lymphoma of the pancreas (T) causing convex displacement and slight compression of the splenic artery. CDS shows no turbulence, indicating a small stenosis. AO = aorta

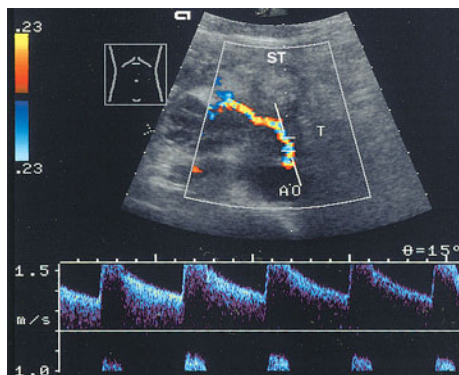


Fig. 270 Inoperable pancreatic carcinoma (T) infiltrating the celiac trunk. CDS and spectral analysis show irregular vascular calibers and increased flow velocities > 240 cm/s. ST = stomach, AO = aorta

## Overview: Classification of Changes by Location (Table 32):

**Table 32 · Classification of sonographic findings by location**

### Wall changes

#### Hypoechoic

Thrombotic plaques (p. 201)

#### Luminal changes

#### Hypoechoic

Embolus (p. 203)

Thrombus (p. 204)

Floating thrombi (p. 204)

#### Echogenic

Atherosclerotic plaques (p. 201)

#### Echogenic

Intimal flap, prosthesis (p. 205)

Protuberant calcifying plaques (p. 205)

### Combined changes (involving the lumen and wall)

#### Malignant

Metastases (p. 205)

Lymphoma (p. 205)

#### Benign

Retroperitoneal fibrosis (p. 205)

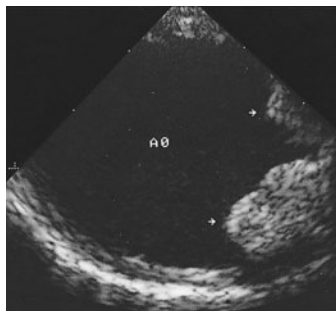
Abscess (p. 206)

Periprosthetic infection, anastomotic leak (p. 206)

## Hypochoic Wall Changes

- ▶ **Atheromatous plaques** (see Figs. 261 and 263, pp. 197 and 198).
- ▶ **Hypochoic, protuberant intraluminal platelet thrombi** (Figs. 271 and 272):
  - Sessile or pedunculated, occasionally laminar
  - Rarely with an echogenic cap, sometimes with associated intimal dissection.

Fig. 271 Protuberant intraluminal atheromatous plaques (arrows) with echogenic atherosclerotic wall thickening of the descending aorta (AO). TEE was used to locate the source of the emboli



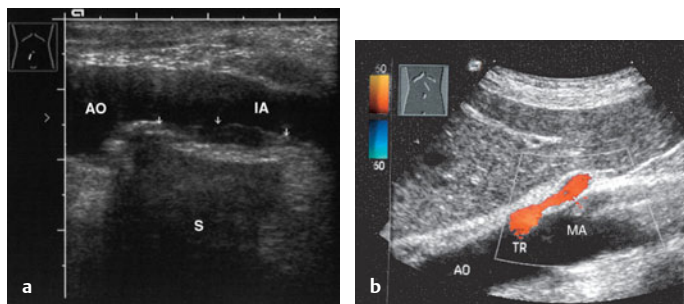


Fig. 272a, b Hypochoic, protuberant thrombotic lesion filling the arterial lumen. **a** Protuberant atherosclerotic lesion of the aorta (AO) extending into the right iliac artery (IA). All criteria of atherosclerosis are present: significant bandlike wall thickening, luminal narrowing (arrows), a hypochoic thrombus with a fibrous cap, a broad band of calcification, and an acoustic shadow (S). **b** Occlusion of the mesenteric artery (MA): absence of arterial flow. TR = thrombus

### Echogenic or Sonodense Wall Changes

#### ► Echogenic wall thickening, complex wall thickening:

- Hypochoic = thrombus (see Fig. 272a), p. 202)
- Echogenic = calcification (see Fig. 263c), p. 198)

#### ► Atherosclerotic plaques (Fig. 273): see classification in Table 33.

- *Simple plaques* (Fig. 274):
  - Segmental or circumscribed wall thickening with no acoustic shadowing
  - Echogenic plaques without calcification, cholesterol deposits
- *Complicated plaques* (Fig. 273; see also Fig. 272a, p. 202, and Fig. 271, p. 201): atherosclerotic plaques with calcification, necrosis, and ulceration (the latter cannot be detected sonographically)

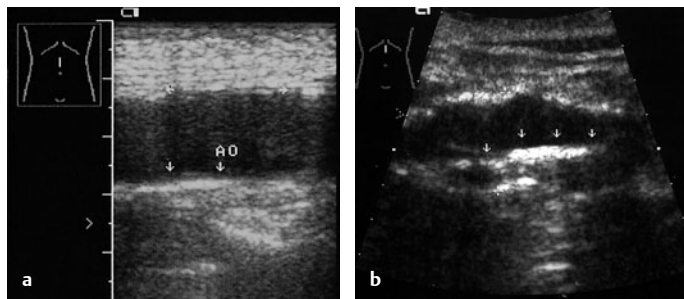


Fig. 273a, b Atherosclerosis. **a** Simple atherosclerotic lesion of the aorta (AO). Atheromatosis: echogenic wall thickening without an acoustic shadow (arrows). **b** Complicated atherosclerotic lesion: slightly raised, echogenic lesion with significant wall thickening (arrows), a faint bandlike acoustic shadow, and irregular vessel contours

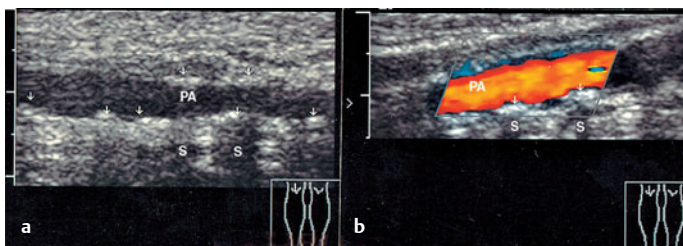


Fig. 274a, b Mönckeberg sclerosis. **a** B-mode image shows diffuse, patchy wall calcification (arrows) of the popliteal artery (PA) with partial acoustic shadowing (S). **b** CDS shows no significant stenosis. The patient had diabetic neuropathy with pedal ulcers and a palpable pedal pulse, Doppler pressure >300 mmHg

### Table 33 · Classification of atherosclerotic plaques

Simple plaques	Complicated plaques
Focal echogenic intimal thickening	Irregular surface, disruptions, ulceration, (secondary) calcifications
Smooth protuberances < 5 mm	Protuberances extending > 5 mm into the lumen <ul style="list-style-type: none"> <li>– Sessile</li> <li>– Pedunculated (prone to embolism)</li> </ul>

- ▶ **Mönckeberg sclerosis** (Fig. 274): diffuse calcific deposits in the media of diabetic patients with symptoms of arterial occlusive disease (AOD) (severe occlusive symptoms are rare, however)
  - Extremely high Doppler wedge pressures
  - Diffuse, patchy echogenic wall calcification, sometimes with acoustic shadowing

### Hypochoic Luminal Changes

- ▶ **Embolus** (Fig. 275): hypochoic intraluminal flow void. B-mode imaging is less rewarding than CDS, which can confirm the absence of flow.

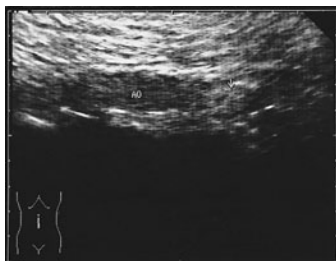


Fig. 275 Embolus (arrow) straddling the bifurcation of the aorta (AO). The patient presented clinically with acute bilateral leg pain and other manifestations of AOD

- ▶ **Conglutination thrombus in aortic or arterial aneurysms** (Figs. 276–278):
  - Eccentric or concentric, weakly echogenic material on the vessel wall
  - Frequent lamination
  - Doppler ultrasound occasionally shows an anechoic crescent devoid of flow
- ▶ **Floating thrombi, “erythrocyte noise”**: pulsating, swaying hypochoic structure or erythrocyte clusters in slow-moving flow

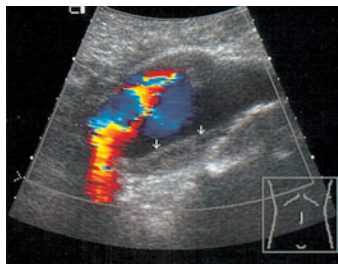


Fig. 276 Circumferential thrombus (arrows) in an aortic aneurysm. CDS shows color reversal indicating zones of turbulent flow

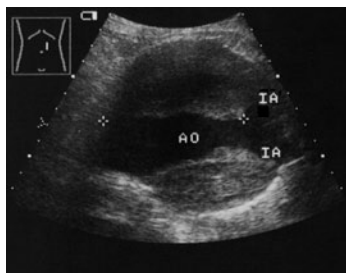


Fig. 277 Saccular aneurysm: circumferential thrombosis surrounding a central residual lumen (AO). The aneurysm occludes the proximal portions of the iliac arteries (IA). Typical features: size > 10 cm, balloon-like shape

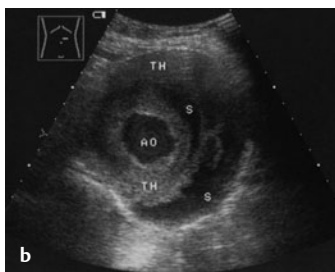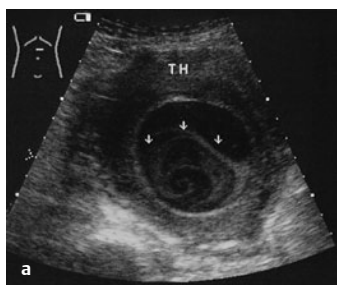


Fig. 278a, b Conglutination thrombi in a saccular aortic aneurysm, visualized in upper abdominal transverse scans. **a** Peripheral laminar thrombus (TH) and a central whorled thrombus (arrows) with a crescent-shaped, anechoic residual lumen. Both are enveloped by an echogenic intimal flap (dissecting aneurysm). **b** Scan at a more distal level shows a regular central aortic lumen (AO) alternately surrounded by a thrombus (TH) and serosanguinous fluid (S)

## Echogenic Luminal Changes

- ▶ **Intimal flap** (see Fig. 266, p. 199): e.g., in aortic dissection
  - Hyperechoic intraluminal membrane, usually showing an irregular thickness
- ▶ **Intraluminal aortic prosthesis** (Fig. 279): smooth, echogenic intraluminal membrane
- ▶ **Protuberant echogenic plaques** (see Fig. 263), p. 198; Fig. 274, p. 203)

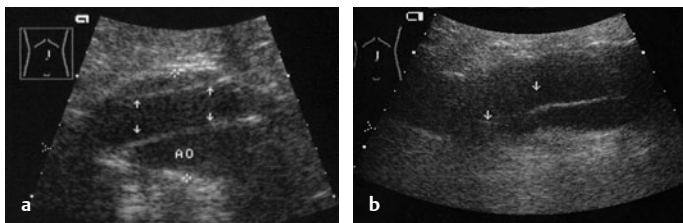


Fig. 279a, b Intraluminal aortic prosthesis and intimal dissection. **a** Intraluminal aortic prosthesis: fine, echogenic intraluminal walls of the prosthesis in an aortic aneurysm (41 mm in diameter, cursors). **b** Almost identical intraluminal structure as in **a**. The entry tear of the intimal dissection (arrows) can be identified

## Paravascular Changes

- ▶ **Metastases, lymphadenopathy** (Fig. 280; see also Fig. 658, p. 438; Fig. 152, p. 112; Fig. 158, p. 115):
  - Well-defined masses or bulky, hypoechoic perivascular structures
  - Increased aorto-spinal distance ( $> 5$  mm)
  - Sandwich sign (vessel “sandwiched” between conglomerates of lymph nodes, suggestive of high-grade lymphoma)

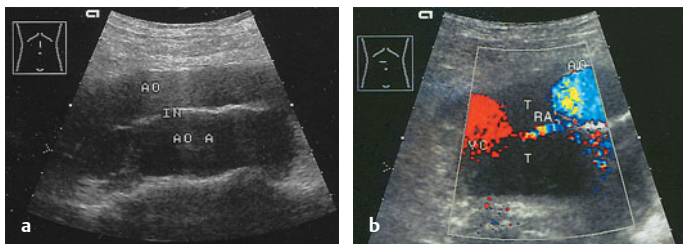


Fig. 280a, b Differentiation of an aortic aneurysm from a perivascular tumor. **a** Initial sonographic diagnosis: dissecting aortic aneurysm (AO, AO A) with an intimal flap (IN). **b** CDS: anechoic lymphomatous tumors (T) around the aorta and vena cava (AO, VC). The renal artery (RA) passes through the tumor masses. Diagnosis: high-grade NHL

- ▶ **Retroperitoneal fibrosis:**
  - Diffuse, hypoechoic periaortic structures
  - Usually associated with urinary tract obstruction

- ▶ **Para-aortic or para-arterial abscess** (see also Figs. 124 and 125, p. 95): hypochoic mass with irregular margins:
  - Hypochoic, irregular, bandlike structure surrounding the prosthesis
  - Perivascular mass in the area of the prosthetic anastomosis, often manifesting arterial flow (by CDS).
- ▶ **Graff infection, suture-line breakdown** (Fig. 281a, b): hypochoic mass surrounding the graff

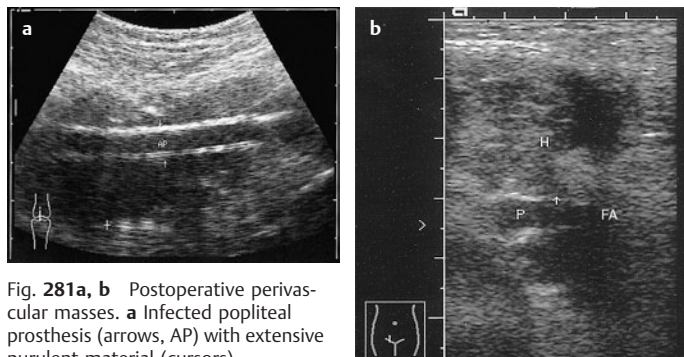


Fig. 281a, b Postoperative perivascular masses. **a** Infected popliteal prosthesis (arrows, AP) with extensive purulent material (cursors).

The patient presented clinically with unexplained fever and suspected popliteal vein thrombosis. **b** Anastomotic leak (arrow) with a perivascular hematoma (H) following the insertion of an aortofemoral vascular prosthesis (P). FA = femoral artery

### Interpretation and Further Testing

- ▶ **Sonography:** Ultrasound is a mainstay for the initial evaluation and postoperative follow-up of all aortic and arterial diseases.
  - *Classification of an aneurysm:* according to type (true, dissecting, or false)
  - *Preoperative planning:* Ultrasound aids in treatment planning based on the location (infrarenal, iliac) of an aortic aneurysm. The sonographic criteria for extension above the origins of the renal arteries are as follows:
    - Direct visualization of the renal artery arising from the aortic aneurysm
    - Superior border of the aneurysm is above a horizontal line drawn from the renal hilum to the aorta

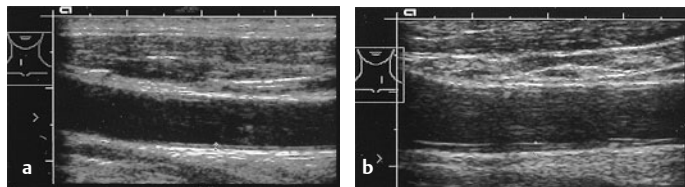


Fig. 282a, b Sonographic determination of intima-media thickness in the common carotid artery. **a** Normal finding (0.6 mm) in a healthy 68-year-old man. **b** Intima-media thickness of 1.4 mm in a 53-year-old man with a high cardiovascular risk profile

- The distance from the aortic bifurcation to the superior border of the aneurysm is  $> 9.5$  cm.
- ▶ **New sonographic techniques:** US contrast agents have been shown to be highly effective in enhancing Doppler signals within the macrovasculature and the microvasculature. Contrast enhanced US increases the accuracy in detection of abnormalities in peripheral arteries and portal veins.
- ▶ **Angiography:** Other tests can reduce the need for conventional angiography but cannot replace it. Angiograms are essential for preoperative planning and for selecting the optimum therapeutic procedure (catheter-directed thrombolysis and atherectomy, stent graft, patch graft, operative thrombectomy).
- ▶ **MR angiography:** has already become a standard tool for surveying the arterial vascular system to verify stenoses, especially in patients who are poor candidates for conventional angiography (renal failure). It can be particularly useful as a prelude to interventional angiography.
  - *Advantages:* less contrast medium, single sitting
  - *Disadvantage:* cannot adequately quantify stenoses
- ▶ **CT:** Better than sonography for defining the extent of supradiaphragmatic aortic aneurysms and evaluating the dissection
- ▶ **Echocardiography:** establishes the presence of a dissecting aneurysm (e.g., involving the aortic root)
- ▶ **Staged protocol for arterial studies:**
  - History (e.g., walking distance)
  - Vascular physical examination (palpable pulses, stress tests)
  - Doppler examination with pressure measurement, determination of Doppler index
  - Duplex or CDS
  - Angiography
- ▶ **Procedure for aortic aneurysms:**
  - *Diagnostic workup:* begins with ultrasound, which may be done as a routine examination (lesion detected incidentally), a selective examination for suspected disease, or an emergency examination (dissection, perforation)
  - *Follow-ups:* at 3–6 month intervals for aneurysms that do not require acute operative treatment (see below)
  - *Indications for operative treatment:*
    - Aneurysm size is the main criterion. Aneurysms  $< 5$  cm have a 5–15% likelihood of rupture within 5 years, and this increases to 75% for aneurysms  $> 8$  cm. Aneurysms  $> 5$  cm should therefore be treated operatively.
    - Another criterion is the sonographically determined growth rate. Aneurysms  $> 5$  cm grow by an average of 0.6 cm in 1 year, whereas smaller aneurysms grow by 0.2 cm. Rapid growth noted at 4–6-month ultrasound follow-ups strengthens the indication for early operative treatment.

## 7.3 Vena Cava and Peripheral Veins

### Overview (Table 34):

**Table 34 · Venous changes detectable by ultrasound**

Luminal/flow changes	Intraluminal changes	Associated effects	Anomalies
Congestion (p. 208)	Thrombosis (p. 210)	Compression (p. 211)	Duplication of the vena cava or popliteal vein (p. 211)
Vascular collapse (p. 209)	Tumor invasion (p. 210)	Infiltration (pp. 211 and 449)	
Chronic venous insufficiency, saphenous incompetence (p. 209)			

### Luminal Changes

- ▶ **Congestion** (Figs. 283 and 284): e.g., vena cava–hepatic venous congestion; systemic venous congestion
  - **Clinical signs:** unexplained dyspnea or lower-extremity edema. In this case a simple evaluation of the vena cava can quickly furnish a diagnosis or exclude heart failure. Severe vena caval congestion due to right-sided heart failure is characterized by pulsatile reflux into the hepatic veins.
  - **Sonographic criteria:**
    - **Vascular dilatation:** vena cava > 20 mm, hepatic veins > 10 mm. This is not a definitive sign.
    - Decreased inspiratory collapse. This is a reliable sign.
    - Decreased compressibility
    - Absence of soft double pulsations

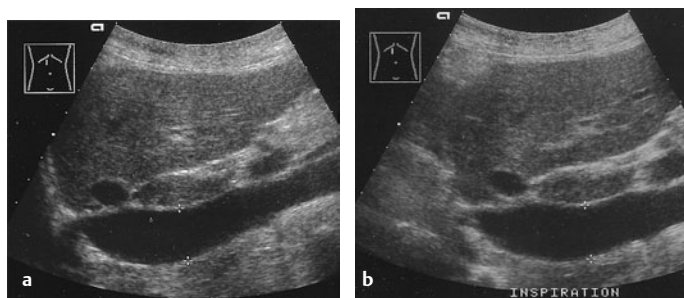


Fig. 283a, b Vena caval congestion (cursors) due to right heart failure. The caliber of the vena cava does not expand during inspiration (paramedian upper abdominal longitudinal scan). **a** Expiration, **b** inspiration

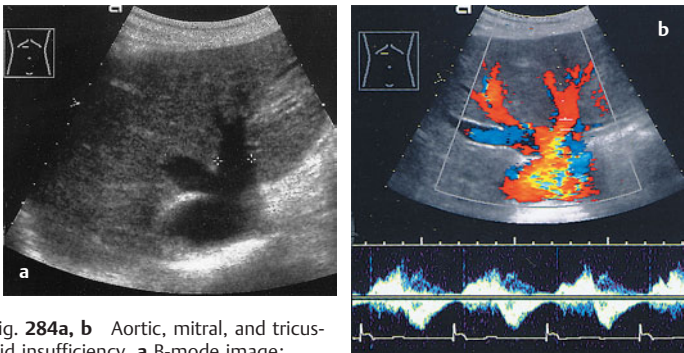


Fig. 284a, b Aortic, mitral, and tricuspid insufficiency. **a** B-mode image: hepatic vein dilated to 14.6 mm (cursors). **b** CDS: pulsatile reflux (encoded in red) in the hepatic veins. Spectral analysis indicates systolic reflux (positive waveform component)

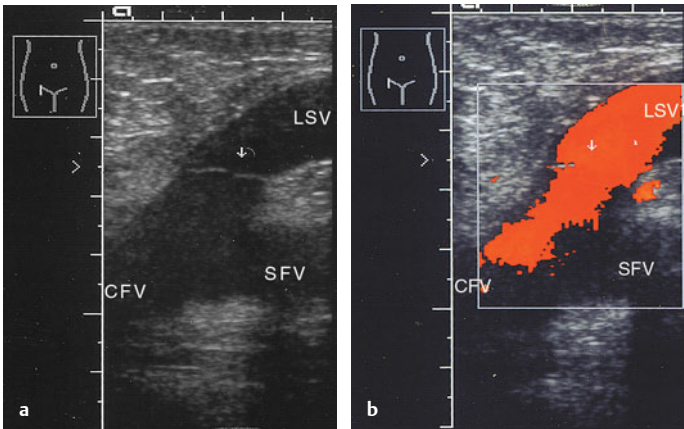


Fig. 285a, b Chronic venous insufficiency resulting from saphenous incompetence. **a** An incompetent venous valve (arrow) **b** is detected at the termination of the dilated long saphenous vein (LSV). CFV = common femoral vein, SFV = superficial femoral vein

- ▶ **Vascular collapse due to dehydration:** The peripheral veins of the lower leg, for example, cannot be visualized with ultrasound.
- ▶ **Note:** This is an important guide for treatment.
- ▶ **Differentiation from thrombosis:** Thrombosis is marked by an increase in luminal diameter; the nonvisualization of veins is not characteristic of thrombosis
- ▶ **Chronic venous insufficiency, saphenous incompetence** (Fig. 285): saphenofemoral, saphenopopliteal and perforator incompetence are easily diagnosed by detecting flow reversal when the patient performs a Valsalva maneuver.

### Intraluminal Changes

- ▶ **Thrombosis** (Figs. 286 and 287; see also Fig. 663, p. 441; Table 35, p. 213):
  - Incompressibility (most important sign)
  - Luminal diameter increased by a factor of  $> 1.5$
  - Intraluminal echogenicity
  - CDS: absence of color flow signals even at a low PRF setting. A correspondingly low initial flow-velocity setting should be used (e.g., 0.10–0.24 m/s).
- ▶ **Tumor invasion** (Fig. 288; see also Fig. 677, p. 449):
  - Flow voids caused by scalloped, echogenic tumor thrombi (indistinguishable from blood clots in the B-mode image)
  - Vascular dilatation
  - The primary tumor can usually be visualized (often renal cell carcinoma).

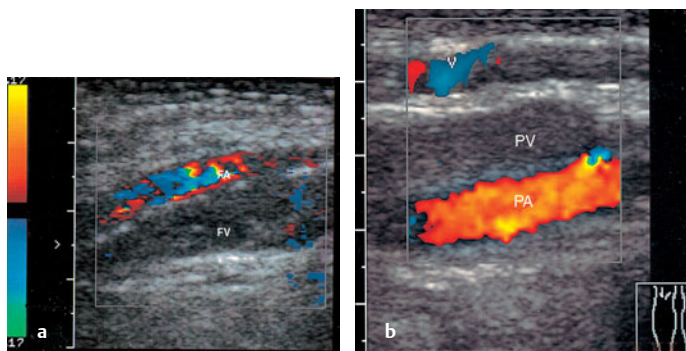


Fig. 286a, b Signs of thrombus: luminal expansion, intraluminal echoes, and absence of flow by CDS. **a** Thrombosis of the femoral vein (FV). FA = femoral artery. **b** Thrombosis of the popliteal vein (PV). V = short saphenous vein, PA = popliteal artery. Posterior scan in the prone position

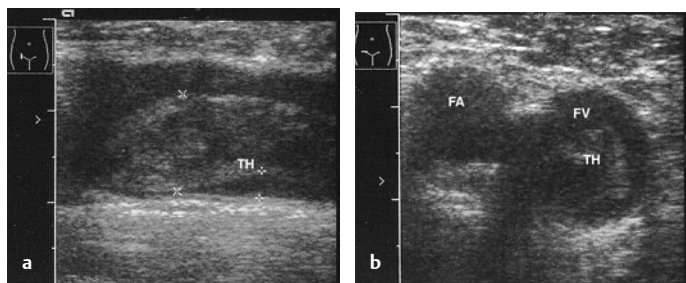


Fig. 287a, b Thrombosis (TH, cursors) of the femoral vein (FV): high-level intraluminal echoes with residual peripheral perfusion (small cursors). **a** Longitudinal scan, **b** transverse scan. Note the increased femoral vein diameter compared with the femoral artery (FA)

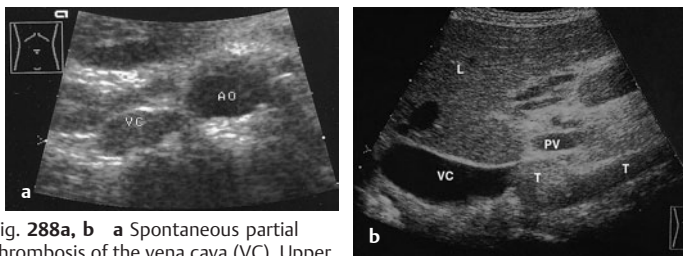


Fig. 288a, b **a** Spontaneous partial thrombosis of the vena cava (VC). Upper abdominal transverse scan: high-level intraluminal echoes. Only CDS can detect residual flow. AO = aorta. **b** Tumor (T) infiltrating the vena cava (VC). L = liver, PV = portal vein

### Associated Effects

- ▶ **Compression** (Fig. 289; see also Fig. 677, p. 449; Fig. 269, p. 200):
  - *Occurrence*: organ enlargement or displacement due to benign or malignant tumors
  - Sonographic criteria:
    - Vascular displacement
    - Extrinsic narrowing
- ▶ **Infiltration** (Fig. 290): always signifies a malignant tumor (see also Fig. 677, p. 449)

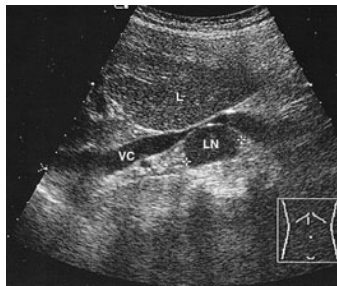


Fig. 289 Compression of the vena cava (VC) by a large lymph node (LN). Infiltration of the liver (L) by chronic lymphatic leukemia. L = liver

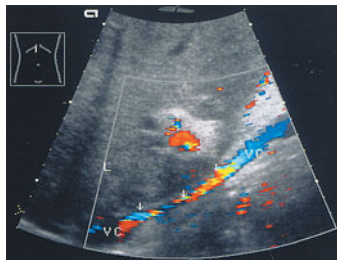


Fig. 290 Infiltration of the vena cava (inferior vena cava syndrome) by a pancreatic carcinoma that has undergone regional and hepatogenic metastasis. CDS: marked caliber changes (arrows) in the vena cava (VC) with zones of color reversal indicating flow acceleration and turbulence

### Anomalies

- ▶ **Duplication of the vena cava** (Fig. 291a): rare
- ▶ **Duplication of the popliteal vein** (Fig. 291b): common
- ▶ **Caution**: Thrombosis involving only one vessel may give a false-negative result.

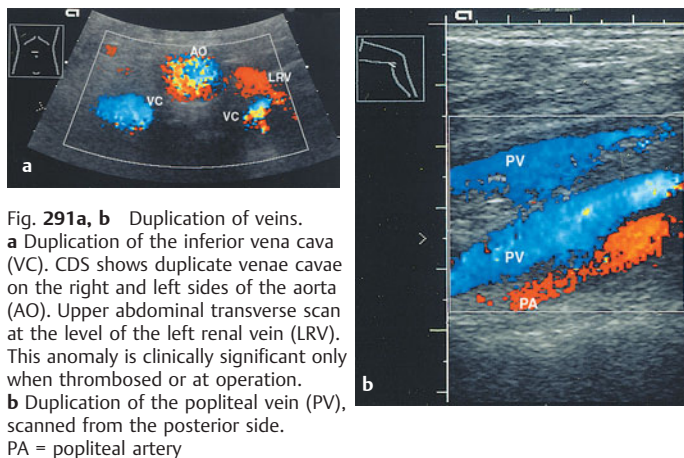


Fig. 291a, b Duplication of veins.  
**a** Duplication of the inferior vena cava (VC). CDS shows duplicate venae cavae on the right and left sides of the aorta (AO). Upper abdominal transverse scan at the level of the left renal vein (LRV). This anomaly is clinically significant only when thrombosed or at operation.  
**b** Duplication of the popliteal vein (PV), scanned from the posterior side.  
 PA = popliteal artery

### Interpretation and Further Testing

#### ► Sonography:

- Congestion of the vena cava and hepatic veins permits a diagnosis of right-sided heart failure.
- *Origin of lower-extremity edema*: High-resolution vascular ultrasound has become the method of choice in the diagnosis of varicose veins, saphenous incompetence, and perforator incompetence when practiced by an experienced examiner.
- *Deep lower-extremity venous thrombosis* (see also Table 35, p. 213): In patients with unilateral or bilateral leg edema, venous compression ultrasound (even without CDS) can quickly confirm or exclude deep venous thrombosis with almost 100% confidence, eliminating the need for invasive tests. (Accuracy is limited in the distal femoral vein, certain lower leg veins, and pelvic veins.)
- *Follow-up of thrombolytic therapy*: Sonography is the method of choice for daily follow-ups.
- *Vena cava thrombosis and tumor compression* (inferior vena cava syndrome due to metastasis in the caudate lobe of the liver)
- *Invasion by renal carcinoma*: Ultrasound is not such a well-recognized indication in these cases but still has an important role in diagnostic evaluation.

► **Venography**: Conventional venography (phlebography) is a standardized technique that defines all groups of lower extremity veins, largely independent of the examiner, and is therefore the standard by which ultrasound must be evaluated (except in the pelvic veins and vena cava). Table 35 shows the indications for conventional venography in patients with suspected thrombosis.

► **CT**: This is largely examiner-independent and may be rewarding even under unfavorable conditions, although it can delineate only relatively large veins. It provides excellent views of the iliac veins when they have been opacified by injecting contrast medium through a dorsal pedal vein.

**Table 35** · Indication for venography based on clinical and sonographic findings*Deep venous thrombosis of the lower extremity*

Clinical	Unlikely	Possible	Very likely
Sonographic evidence of thrombosis	Yes/no	No	No
Indication for venography	No	May be done after preliminary ultrasound	Yes

## 8 Cervical Vessels

### 8.1 Examination

#### Duplex Sonography of the Cervical Vessels

► **Indications:**

- *Physical findings:* e.g., audible bruits, neck swelling
- *History:* e.g., headache, vertigo, syncopal episodes
- Previous interventions (e.g., stent implantation) or previous stroke

► **Overview of duplex methods:** see Table 36.

**Table 36** · Duplex examination of the cervical vessels

Method	Yields information on:
B-mode image	Morphological changes
CDS	Flow characteristics, vascularity
Pulsed Doppler	Time course of blood flow, flow velocities (displayed in a spectral waveform; the spectrum reflects frequency distribution)

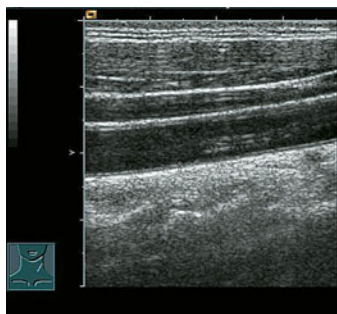
■ **Note:** Angle correction is essential in determining flow velocities.

► **B-mode imaging:** for morphological evaluation of the vessel wall

- Detection of hard or soft plaques
- Determination of the intima-media thickness (IMT) of the common carotid artery 1 cm proximal to the carotid bulb (Fig. 292; see also Fig. 282, p. 206). The IMT is determined in the vessel's far wall (the blood providing a "fluid offset") by measuring from the high-amplitude entry echo of the intima to the high-amplitude exit echo of the adventitia
  - *Normal values* (age-dependent): see Table 37.
  - An increased IMT is associated with an increased risk of cardiovascular events.

► **CDS:** for evaluating flow characteristics

- Determination of the flow direction
- Detection of turbulence



**Fig. 292** Common carotid artery, measurement of the intima-media thickness. The IMT is slightly increased, measuring 0.82 mm

**Table 37** · Normal IMT values for age

Age (years)	Thickness (mm)
20–40	0.5
40–60	0.6–0.8
> 60	0.8–1.0

- *Anomalous position or course* (Fig. 293): Possible variants or anomalies in the course of the vessels must be taken into account to correctly interpret flow directions and presumed zones of turbulent flow.

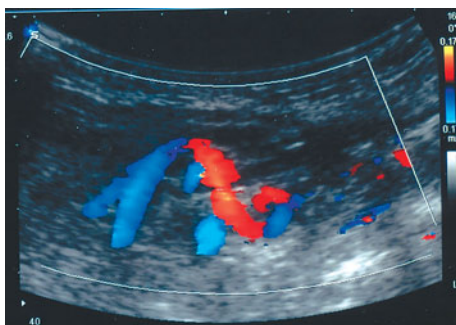


Fig. 293 Looping of the internal carotid artery

- ▶ **Pulsed Doppler:** Each of the arteries has a characteristic spectral waveform by which it can be identified. When the waveforms are analyzed, they should always be compared between the sides in order to detect abnormalities.
  - *Positioning the transducer:* The transducer should be positioned so that the beam angle relative to the long axis of the vessel is less than 60°. If manual transducer orientation is not sufficient for this purpose, the insonation angle can also be set electronically on the ultrasound unit (most scanners have this feature).
  - *Determination of peak systolic velocity (PSV)* (Table 38): The measuring system of the ultrasound scanner is used to measure the PSV.

**Table 38** · Reference values for internal carotid artery stenosis

$V_{\max}$ (cm/s)	Degree of stenosis (%)
< 120	< 50
120	approx. 60
200	approx. 70
300	approx. 80

## 8.1 Examination

- *Doppler indices* (see also p. 193): The indices that can be determined by spectral analysis are considered indirect signs of stenosis. They are difficult to interpret, however, because of marked variations in the stiffness of the vessel walls (e.g., leading to pulsatility changes with ageing). Normal values:
  - *Resistance index (RI)*: < 0.75
  - *Pulsatility index (PI)*: < 1

### Sonographic Anatomy and Normal Findings

- **Topography of the cervical vessels:** see Fig. 294).

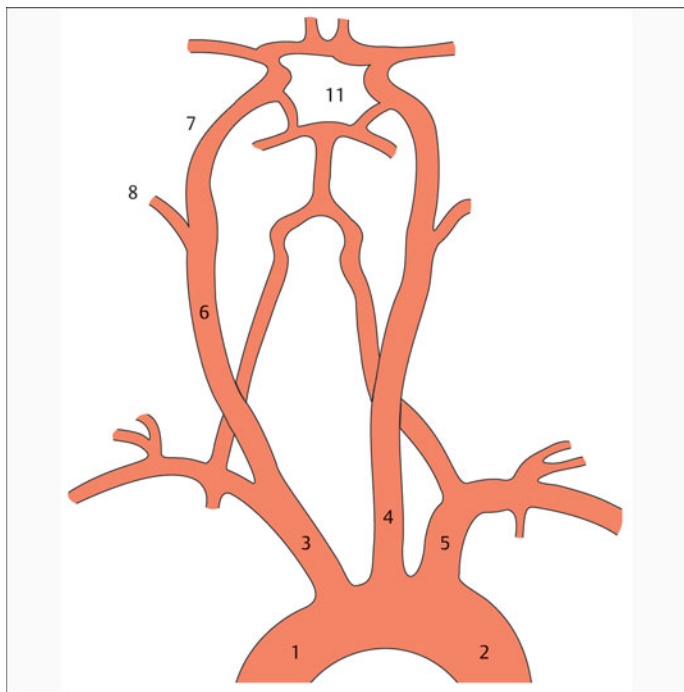


Fig. 294 Vascular topography of the neck. **1** = Ascending thoracic artery, **2** = descending thoracic artery, **3** = brachiocephalic trunk, **4** = left common carotid artery, **5** = left subclavian artery, **6** = right common carotid artery, **7** = right internal carotid artery, **8** = right external carotid artery, **9** = right vertebral artery, **10** = basilar artery, **11** = circle of Willis

► **Common carotid artery (CCA, Figs. 295–297):**

- The CCA arises from the aortic arch on the left side and from the brachiocephalic trunk on the right side. It bifurcates into the internal carotid artery (ICA) and external carotid artery (ECA).
- *Spectral waveform*: The diastolic flow velocity of the CCA is intermediate between the diastolic velocities of the ICA and ECA.

Fig. 295 Common carotid artery with a typical spectral waveform. The clear spectral window below the waveform indicates an absence of turbulent flow

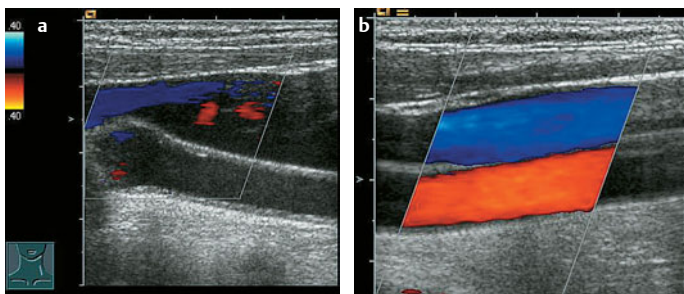
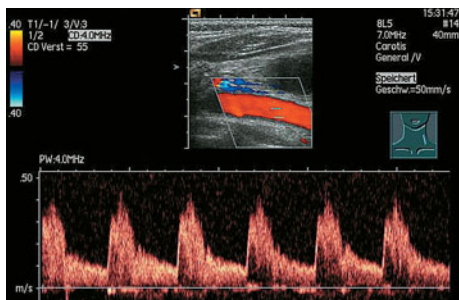
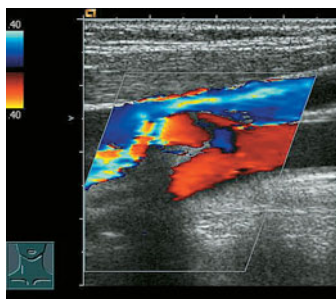


Fig. 296a, b Common carotid artery. **a** CCA with the carotid bulb and jugular vein: relatively hyperechoic vessel wall. The CCA dilates normally toward the bulb, with a change in the audible flow signal. **b** CCA with the jugular vein. The jugular vein is closer to the transducer and encoded in blue; the CCA is encoded in red

Fig. 297 Carotid bifurcation with zones of apparent turbulence in the ICA (mixed color pattern). Cause: flow in the overlying jugular vein



► **Internal carotid artery (ICA, Fig. 298):**

- The ICA gives off no extracranial branches
- *Spectral waveform:* As a parenchymal artery (supplying the brain), the ICA has a monophasic spectral waveform with a higher diastolic velocity than the CCA.

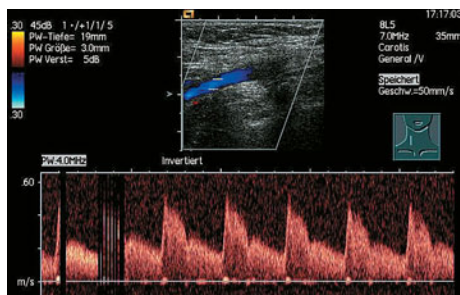


Fig. 298 Internal carotid artery with a typical spectral waveform. The diastolic flow velocity is higher than in the CCA

► **External carotid artery (ECA, Fig. 299):**

- The ECA gives off numerous extracranial branches.
- *Spectral waveform:* As a resistance vessel, the ECA has a triphasic waveform with a low diastolic velocity.
- *Scanning tip:* The ECA is easily distinguished from the ICA by repeatedly compressing a terminal branch of the ECA and watching for retrograde pulsation in the waveform sampled from the ECA.

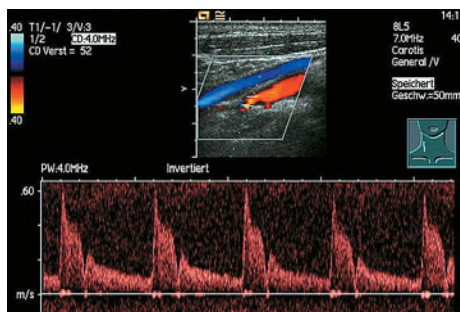

Fig. 299 External carotid artery with a typical spectral waveform. The ECA (encoded in red) is easily identified by the vessels arising from it. The diastolic flow velocity is lower than in the ICA, and a small negative dip appears at end-diastole (typical of resistance vessels)

► **Vertebral artery (VA, Figs. 300 and 301):**

- The VA arises from the subclavian artery on each side, at a more lateral site than the CCA.
- *Spectral waveform:* resembles that of the ICA

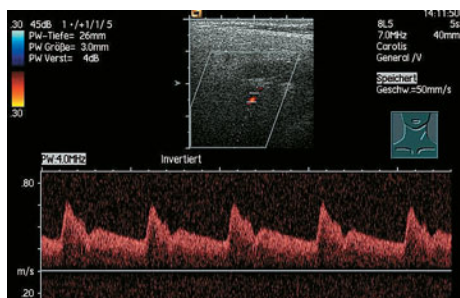


Fig. 300 Vertebral artery with a typical spectral waveform. The vertebral artery exhibits a higher diastolic flow velocity than the ICA

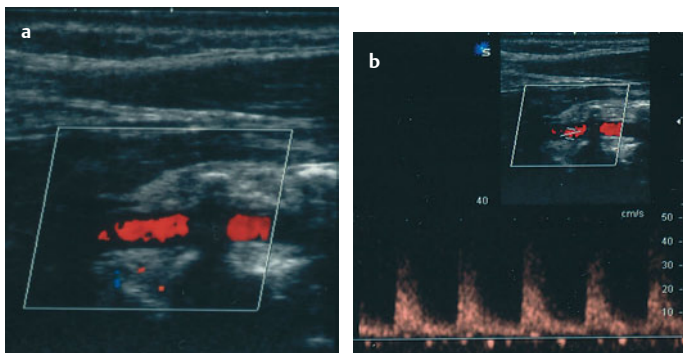


Fig. 301a, b Vertebral artery. **a** Portions of the vertebral artery can be identified in the intervertebral foramina. **b** Waveform sampled from the vertebral artery resembles that of the ICA

### Scanning Protocol

- ▶ The patient is examined in the supine position with the head turned slightly to the opposite side (Fig. 302).

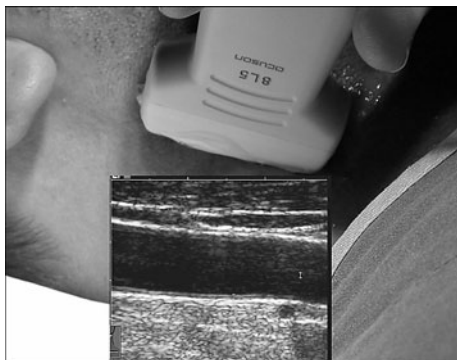


Fig. 302 Transducer positioned on the right side of the neck in a supine patient

- ▶ The cervical vessels are scanned in transverse and longitudinal sections over their entire accessible length.
- ▶ Generally the examination covers all of the carotid arteries (common, internal and external), the vertebral arteries, and the right and left internal jugular veins.
- ▶ **Transducer:** longitudinal array, generally with an operating frequency of 5 MHz
- ▶ **Locating the vessels in longitudinal scans:**
  - First identify the ICA in longitudinal section.
  - *ECA:* Angle the probe slightly anteromedially from its position over the ICA.
  - *VA:* From the ICA position, angle the probe slightly posterolaterally to scan between the intervertebral foramina.
- ▶ **Locating the vessels in transverse scans:**
  - First locate the CCA, then the ICA.

## 8.1 Examination

- The ICA usually has a larger caliber than the ECA (Fig. 303).
- The VA is posterolateral to the ICA, and the ECA is anterior.
- The internal jugular vein lies anterior to the carotid artery and can be compressed by applying gentle transducer pressure.

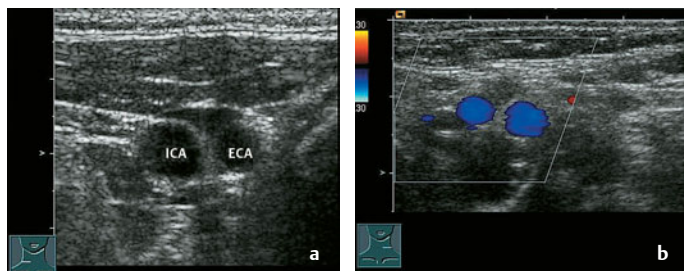


Fig. 303a, b Transverse scans of the external carotid artery (ECA) and internal carotid artery (ICA). **a** The internal carotid artery has a larger diameter than the external carotid artery (right side of the neck). **b** CDS appearance of the carotid arteries (left side of the neck)

- ▶ **Intracranial Doppler sonography** (Fig. 304): Some intracranial vascular segments can be examined by transcranial ultrasound scanning: ICA, middle cerebral artery (MCA), posterior cerebral artery (PCA), and anterior cerebral artery (ACA).
  - **Prerequisites:**
    - Proper ultrasound equipment
    - Use of a low transducer frequency (here, 2 MHz). Delineation can be enhanced by the use of ultrasound contrast agents.
    - Previous interventions (stent implantations) or preceding stroke

**Table 39 · Criteria for interpreting sonographic findings**

Criterion	Possible findings
<i>Morphology of the vessel wall</i>	Hard and soft plaques Abnormal intima-media thickness
<i>Flow characteristics (flow direction, flow velocity, flow disturbances)</i>	Turbulence  Waveform changes Flow direction, flow reversal, absent flow Stenosis

**Table 40 · Abnormal findings in the cervical vessels**

Atherosclerotic plaques	Stenosis, occlusion	Thrombosis, dissection
Soft plaque (p. 221)	Carotid stenosis, previous stent implantation (p. 223)	Jugular vein thrombosis (p. 229)
Hard plaque (p. 222)	ECA stenosis (p. 225) ICA stenosis (p. 225) ICA occlusion (p. 226)	

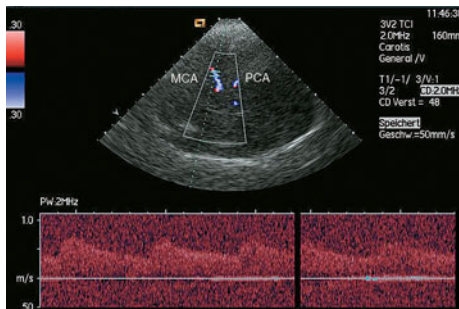


Fig. 304 Transtemporal scan of the MCA and PCA on the left side

► **Indirect signs of carotid artery stenosis** (spectral analysis):

- *Prestenotic*: increased pulsatility, decreased systolic amplitude
- *Intrastenotic*: decreased pulsatility, increased amplitude
- *Poststenotic*: delayed systolic peak, decreased pulsatility

## 8.2 Abnormal Findings

### Atherosclerotic Plaques

- **Soft plaques** (Fig. 305): luminal narrowing without an acoustic shadow

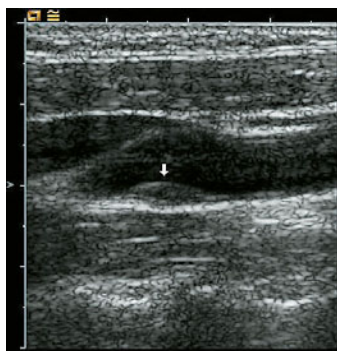


Fig. 305 Small, soft plaque (arrow) in the CCA: faint, smoothly curved area of luminal narrowing without an acoustic shadow

▶ **Hard plaques** (Figs. 306, 307):

- Irregular surface
- Calcifications, sometimes with acoustic shadows (Fig. 307)
- Luminal narrowing

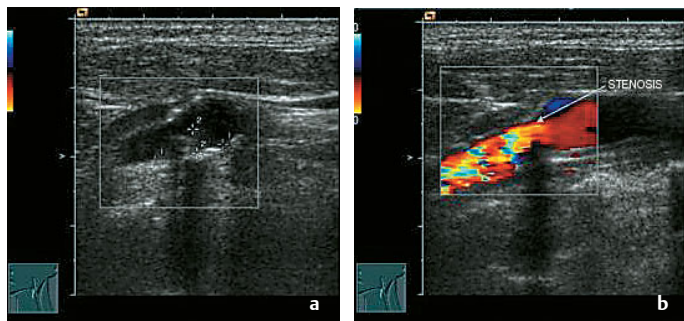


Fig. 306a, b Luminal narrowing by hard plaques. **a** Calcified plaque in the carotid bulb. Luminal narrowing by plaque with an irregular surface is associated with a higher risk of thromboembolism. **b** Luminal narrowing by hard plaque with zones of turbulent flow

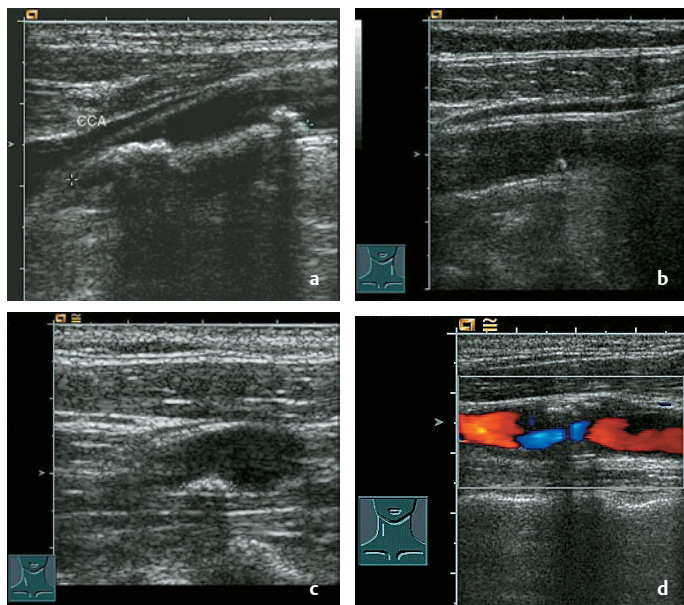


Fig. 307a–d Hard plaques with and without acoustic shadowing. **a** Rough, calcified plaques with acoustic shadowing in the CCA. **b** Small, hard, echogenic plaque without an acoustic shadow. **c** Small, flat, shadowing plaque in the CCA. **d** Acoustic shadow behind a calcified plaque mimics reverse flow

## Stenosis, Occlusion

► Carotid stenosis following stent implantation: See Figs. 308–311.

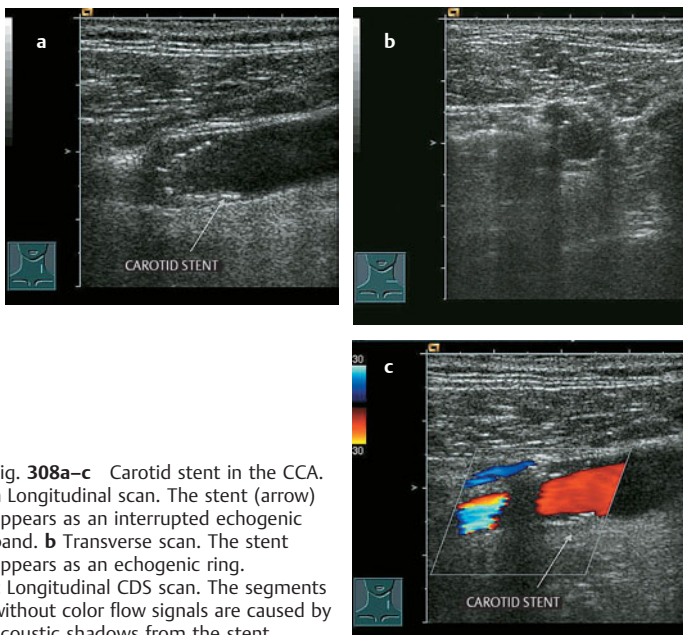


Fig. 308a–c Carotid stent in the CCA. **a** Longitudinal scan. The stent (arrow) appears as an interrupted echogenic band. **b** Transverse scan. The stent appears as an echogenic ring. **c** Longitudinal CDS scan. The segments without color flow signals are caused by acoustic shadows from the stent

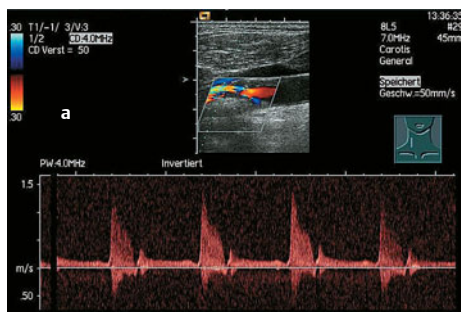


Fig. 309a **a** Carotid stent near the origin of the ECA: flow acceleration in the ECA with turbulent flow (mixed color pattern)

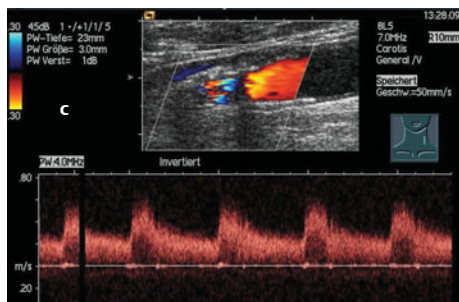
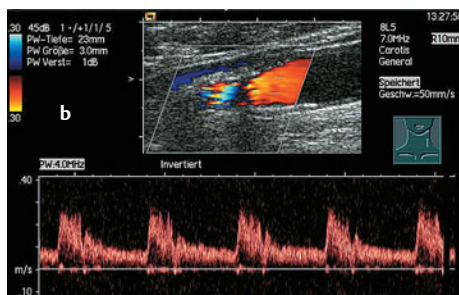

Fig. 309b, c **b** Carotid stent near the origin of the ICA: turbulence with-out flow acceleration in the CCA. **c** Doppler trace from the ICA with a stent in the CCA

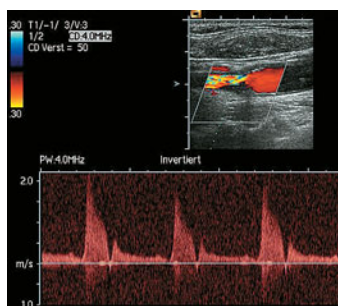


Fig. 310 This patient previously had a stent implanted for carotid stenosis, presented now with a proximal stenosis of the ECA. Measurement of the maximum flow velocity ( $V_{max}$ ) indicates a 60–70% stenosis

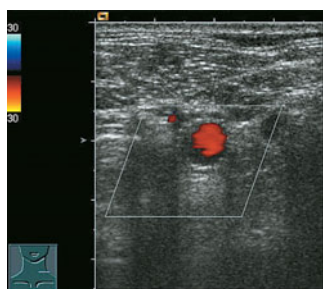


Fig. 311 Transverse scan of a stented ECA. The color flow signals confirm patency of the stent

► **ECA stenosis:** See Fig. 312.

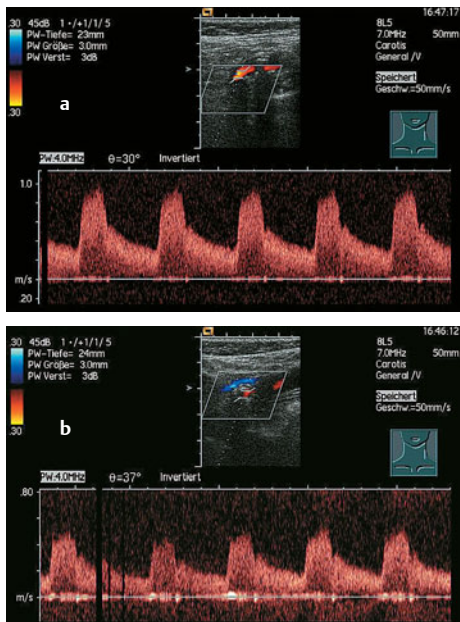


Fig. 312a, b Flow in the ICA associated with a 50% stenosis of the ECA.  
**a** No alteration of ICA flow.  
**b** Alteration of ICA flow in the presence of a 50% ECA stenosis

► **ICA stenosis:** See Figs. 313 and 314.

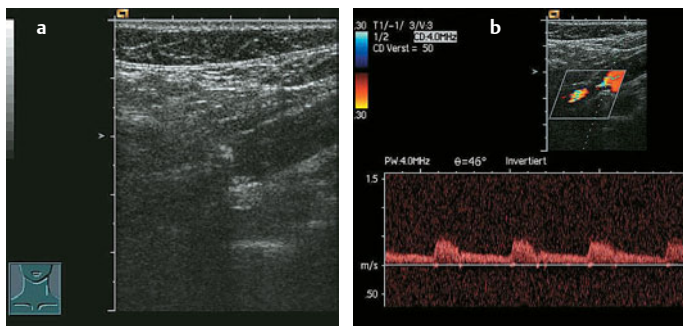


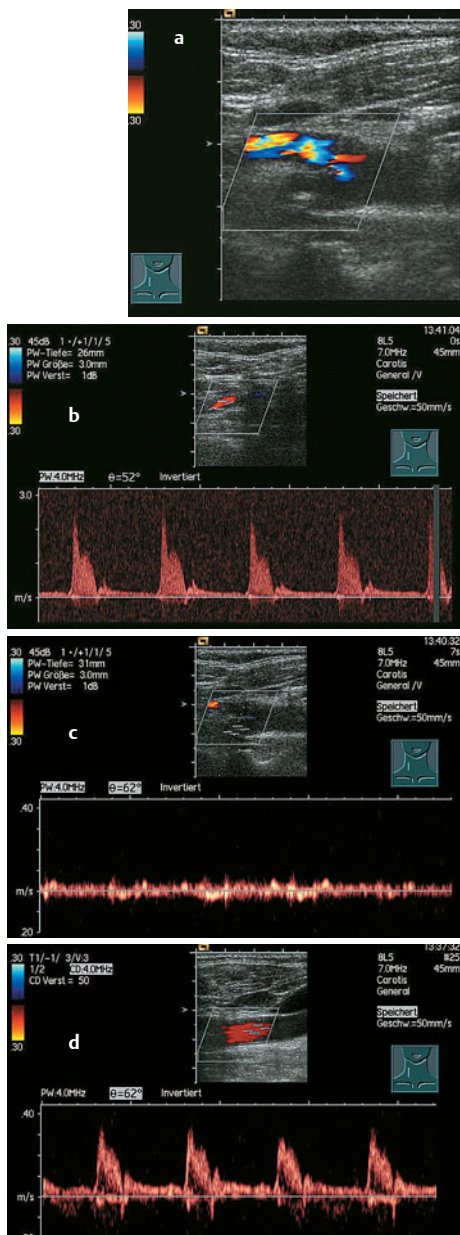
Fig. 313a, b ICA stenosis. **a** Conspicuous echogenic plaques in the ICA with luminal narrowing. **b** CDS: turbulence (green/blue/yellow pixels) and acoustic shadowing in the stenosis (the “shadow” from the plaque obscures color flow)

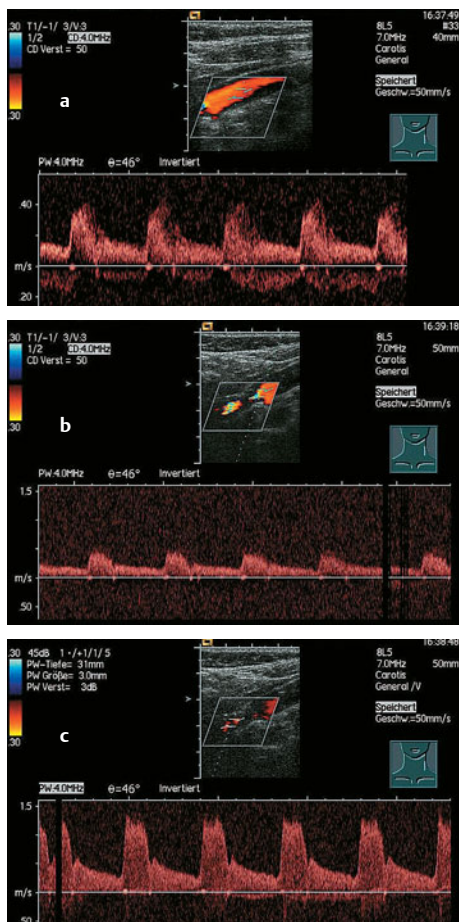

Fig. 314a–c ICA stenosis.  
**a** Decreased flow velocity with an intact frequency spectrum upstream of the stenosis.  
**b** Markedly decreased flow velocity just proximal to the stenosis.  
**c** Increased flow velocity in the stenosis, with  $V_{max}$  up to 140 cm/s

► ICA occlusion:

- *Ipsilateral ICA*: spectral waveform cannot be recorded (Figs. 315c and 316f)
- *Ipsilateral ECA*: turbulence and increased flow velocity (Fig. 315)
- *Ipsilateral CCA*: spectral waveform resembles that of the ECA (with ICA occlusion, the CCA becomes a pure resistance vessel, Fig. 316)



**Fig. 315a–d** Typical findings in the cervical vessels associated with occlusion of the ICA. **a** CDS appearance of the ECA in the presence of an ICA occlusion. Turbulent flow (mixed color pattern) in the ECA. **b** Spectrum from the ECA:  $V_{\max} > 2$  m/s. **c** A spectrum cannot be recorded from the ICA. **d** Spectrum from the CCA in the presence of an ICA occlusion. The spectral waveform resembles that of the ECA (the CCA becomes a pure resistance vessel in cases where the ICA is occluded)

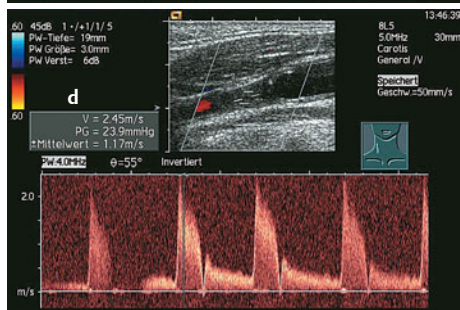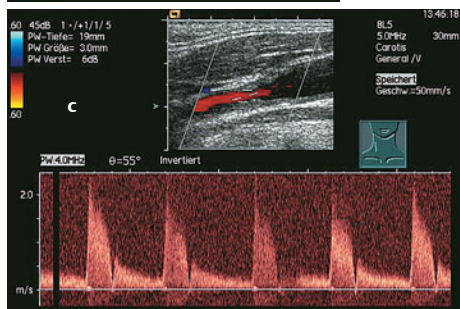
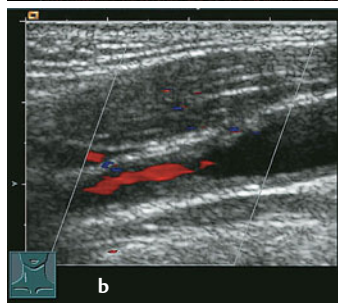
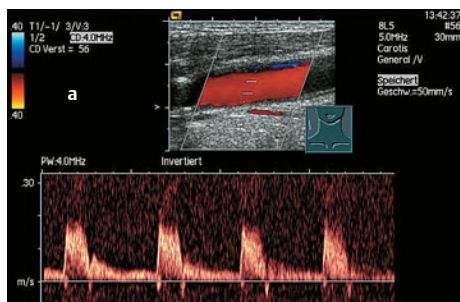


Fig. 316a–d Typical findings in the cervical vessels associated with occlusion of the ICA. **a** Abnormal spectrum from the CCA shows an end-diastolic dip with a relatively low diastolic flow velocity. The wave-form resembles that of the ECA. **b** > 50% luminal narrowing of the ICA. Turbulent signals are not detected in this case. **c** ECA stenosis. The spectrum from the ECA indicates flow acceleration. **d** Doppler interrogation of the ECA stenosis. The maximum measurable flow velocity in the ECA, at 2.45 cm/s, indicates an approximately 70% stenosis of the ECA

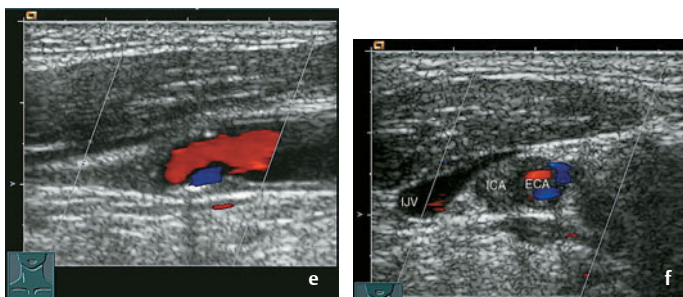


Fig. 316 **e, f** Typical findings in the cervical vessels associated with occlusion of the ICA. **e** Longitudinal scan of the CCA shows an abrupt cutoff of blood flow in the ICA with color reversal (blue). **f** Transverse scan of the ICA and ECA. The ICA appears occluded with echogenic material in cross section, with no evidence of color flow signals. By contrast, the color signals in the ECA indicate flow. An oblique section of the anechoic internal jugular vein (IJV) appears adjacent to the ICA

### Thrombosis, Dissection

- ▶ **Jugular vein thrombosis following insertion of a central venous catheter:**  
See Fig. 317).

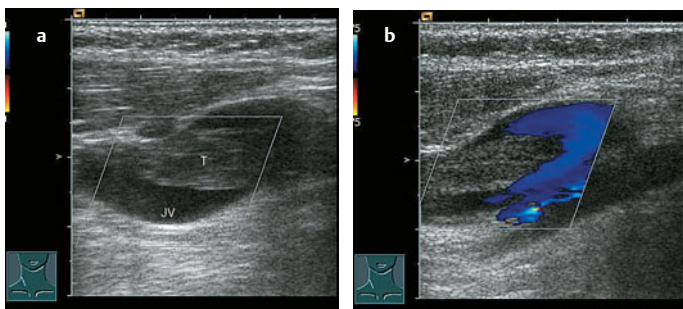


Fig. 317**a, b** Thrombosis of the jugular vein. **a** Echogenic thrombus (T) in the jugular vein (JV) following insertion of a CVC. **b** CDS demonstrates flow (encoded in blue) around the thrombus

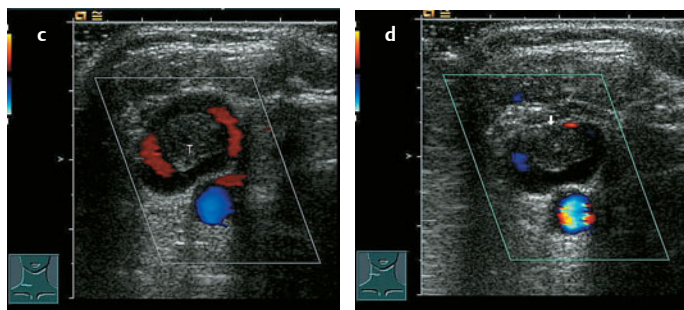


Fig. 317 **c, d** Thrombosis of the jugular vein. **c** Transverse scan of the jugular vein demonstrates circumferential flow around the thrombus. **d** Scan at a higher level shows the thrombus adherent to the vessel wall

## 9 Liver

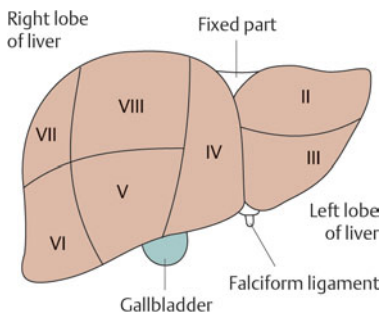
### 9.1 Examination

#### Scan Planes

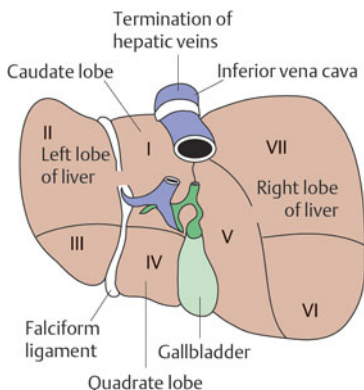
- ▶ Upper abdominal transverse scan (to demonstrate the left lobe of the liver, see p. 22)
- ▶ Right subcostal oblique scan (see p. 22)
- ▶ High and extended right intercostal scans (see pp. 33 and 24)
- ▶ Paramedian upper abdominal longitudinal scans (see p. 24)

#### Sonographic Anatomy and Normal Findings

- ▶ The liver exhibits a diaphragmatic surface and a visceral surface.
- ▶ Both surfaces meet anteroinferiorly at the sharp inferior hepatic border and posterosuperiorly at the fixed part of the diaphragm.
- ▶ The liver is divided anatomically into the right and left lobes, the falciform ligament separating the larger right lobe from the smaller left lobe. The quadrate lobe (segment IV) and the caudate lobe (segment I) belong physiologically to the left lobe (Figs. 318 and 319).



**Fig. 318** Segmental anatomy of the liver, diaphragmatic surface. A line between the gallbladder and inferior vena cava divides the liver into right (Segment V–VIII) and left physiologic lobes (Segment I–IV)



**Fig. 319** Segmental anatomy of the liver, visceral surface. Boundaries of the caudate lobe: upper hepatic border, falciform ligament, portal vein, and vena cava. Boundaries of the quadrate lobe: lower hepatic border, falciform ligament, gallbladder, and portal vein

- ▶ **Normal values:** craniocaudal liver diameter on the midclavicular line (MCL) in heavy-set patients < 120 mm, in asthenic patients < 140 mm. Sum of length plus depth < 24–26 mm. Depth over the aorta at the level of the celiac trunk < 40 mm.

### Scanning Protocol

- ▶ **Transducer:** 2.5–5.0 MHz (depending on the abdominal circumference)
- ▶ **Right subcostal oblique scan:** Ask the patient to take a deep breath and hold it. Define the dome of the liver with the diaphragm, hepatic veins, portal venous branches (common hepatic duct), the intrahepatic bile ducts, the gallbladder, and the hepatic parenchyma (see Fig. 320).

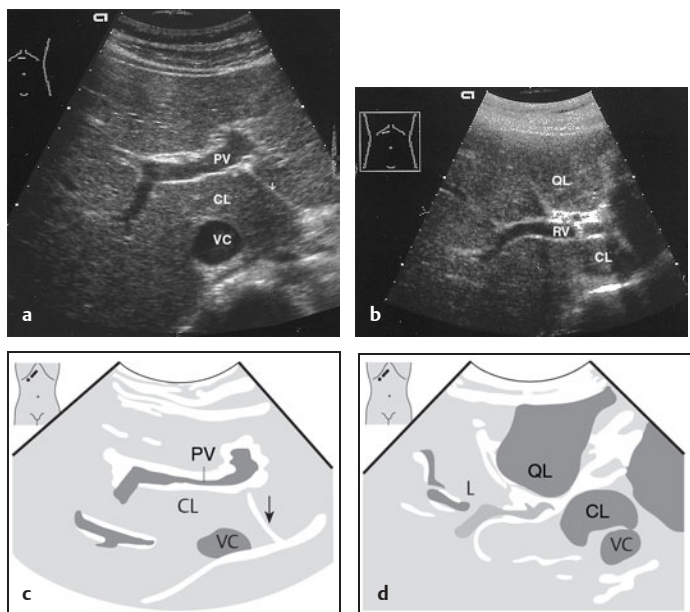


Fig. 320a–d Subcostal oblique scans. **a, c** Scan through the porta hepatis into the upper part of the liver. PV = right and left branch of the portal vein. V = inferior vena cava, arrow = ligamentum venosum. **b, d** Scan directed from the inferior hepatic border (at top of image) to the fixed part (at bottom of image) demonstrates the quadrate lobe (QL) and caudate lobe (CL) anterior to the vena cava (VC). L = right lobe of liver, PV = portal vein

- ▶ Scan through all portions of the liver in a fan-shaped pattern.
- ▶ **Upper abdominal longitudinal and intercostal scans:** Evaluate the porta hepatis, the bile ducts, the portal vein, and the lateral portions of the liver (see Fig. 321).
- ▶ **Scanning tip:** When examination conditions are not ideal, these same planes can be used for scanning the other portions of the liver and the gallbladder.

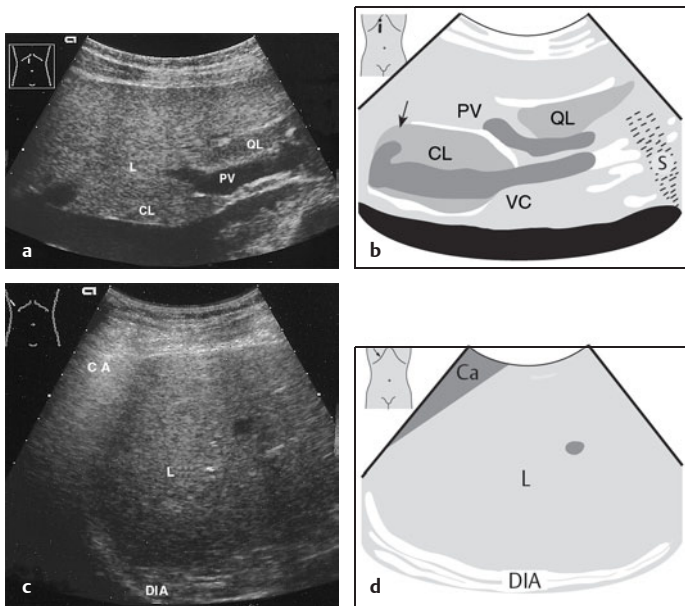


Fig. 321a–d **a, b** Upper abdominal longitudinal scan of the subdiaphragmatic vena cava and the termination of the hepatic veins (arrow). QL = quadrate lobe, PV = portal vein, CL = caudate lobe, VC = inferior vena cava, L = liver. **c, d** High intercostal scan on the right side demonstrates the costophrenic angle (CA), posterior portions of the diaphragm (DIA) and the entry echo of the lung (L)

### Overview of Findings, Classification

- ▶ **Changes in the liver:** Sonographic abnormalities of the liver may consist of diffuse or circumscribed changes in the normal hepatic architecture:
  - *Diffuse changes* (see Table 41, p. 234): These refer to a general alteration of normal liver architecture with regard to size, echogenicity, contours, vasculature, and tubular tracts. Changes in echo texture and contours are particularly significant.
  - *Circumscribed changes* (see Table 44, p. 241): focal alterations in the normal echo texture of the liver. Their detectability depends on the difference in acoustic impedance between the change and normal surrounding liver (anechoic lesions such as cysts are easily recognized). A lesion that is isoechoic to surrounding liver can be distinguished only by the presence of a hypoechoic rim or vascular displacement
- ▶ **Changes in the portal veins** (see Table 45, p. 257): Abnormalities of the portal vein and its tributaries may produce changes identical to those found in the systemic veins (see Table 34, p. 208).

## 9.2 Diffuse Changes

### Overview (Table 41):

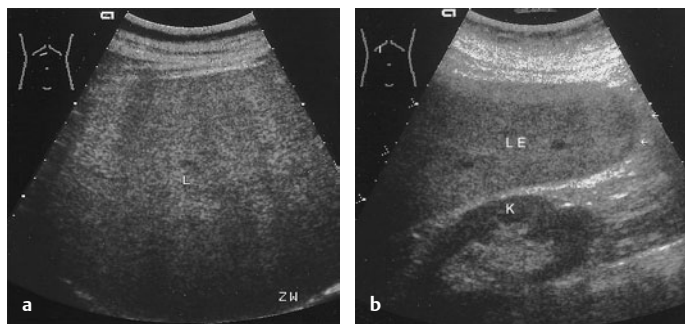
**Table 41** · Diffuse changes in hepatic echogenicity or contours

Subtle	Pronounced
Alimentary or diabetic fatty liver (p. 234)	Sarcoidosis (p. 237)
Acute hepatitis (p. 235)	Micronodular abscesses, metastases (p. 237)
Chronic hepatitis (p. 235)	Toxic fatty liver, chronic toxic liver disease (p. 237)
Fibrosis (p. 235)	Severe chronic hepatitis, hepatic cirrhosis (p. 238)
Congestive cirrhosis (p. 236)	Diffuse metastasis, metastatic liver during chemotherapy
Incipient hepatic cirrhosis (p. 236)	
Diffuse metastasis, systemic hematologic disease (p. 239)	

### Subtle Changes in Echogenicity or Contours

#### ► Alimentary or diabetic fatty liver (Fig. 322):

- Slight coarsening of the parenchymal echo pattern and increased echogenicity in relation to the kidney
- Moderate (14–16 cm) to severe (17–20 cm) hepatic enlargement in longitudinal section on the MCL
- Minimal acoustic shadowing on the far side of the liver
- Rounded hepatic contours



**Fig. 322a, b** Fatty liver (L, LE). **a** Slight coarsening of the parenchymal echo pattern, increased echogenicity, distal acoustic shadowing, and organ enlargement. **b** Longitudinal scan shows increased hepatic echogenicity (relative to the kidney) and a rounded inferior border (arrows). K = kidney

► **Acute hepatitis:**

- Markedly good sound transmission or slightly increased echogenicity
- Inflammatory hilar lymphadenopathy
- Splenomegaly
- Empty gallbladder with a thickened wall

► **Chronic viral hepatitis (Fig. 323):** variable echogenicity and contour changes, ranging from a normal-appearing liver (mild or “persistent” hepatitis with low activity) to changes like those seen in an early form of hepatic cirrhosis (severe or “aggressive” hepatitis with high activity).

• *Sonographic signs:*

- Slight coarsening of the parenchymal echo pattern. Acoustic shadowing is seen in chronic toxic liver disease.
- Slight lobulation of the contours
- Incipient dilatation of the portal vein
- Frequent splenomegaly
- Caliber irregularities in the hepatic veins

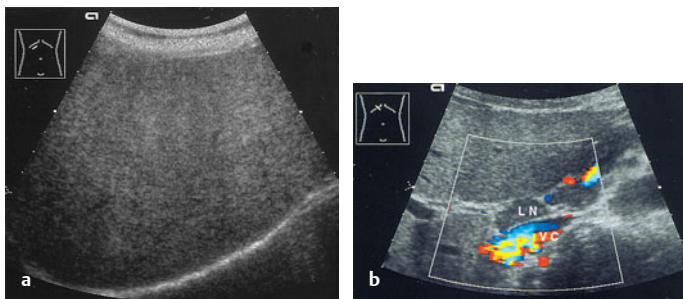


Fig. 323a, b Chronic hepatitis C, mild form. **a** Very slight coarsening of the parenchymal echo pattern and increased sonodensity with faint acoustic shadowing. Right subcostal scan. **b** CDS: inflammatory hilar lymphadenopathy (LN). Right intercostal scan through the porta hepatis. VC = vena cava

► **Fibrosis (Fig. 324):**

- Slightly coarsened or mottled echo texture (if secondary to inactive chronic hepatitis or cirrhosis, resembles the appearance of chronic hepatitis or cirrhosis but with essentially normal liver values).

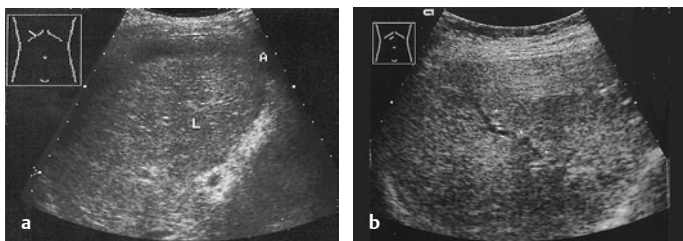
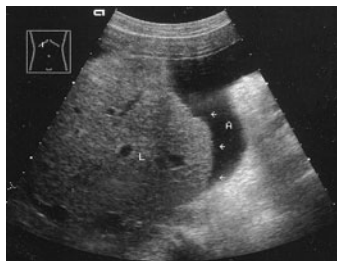

Fig. 324a, b Hepatic fibrosis. **a** Congenital fibrosis in a 23-year-old woman with portal hypertension following the placement of a portosystemic shunt. A = ascites. **b** Inactive chronic sclerosing cholangitis with marked fibrosis: coarse high-level echoes, wavy course of the hepatic vein (arrows)

- Coarse, heterogeneous echo pattern
- Possible distal acoustic shadowing as in a fatty liver
- ▶ **Congestive cirrhosis** (Fig. 325):
  - Hepatic echogenicity is normal or slightly increased (can be clearly evaluated owing to increased vascularity); rounded contours
  - Hepatomegaly
  - Hepatic veins and vena cava are dilated, do not show caliber variations with respiration
  - Enlarged caudate lobe
  - *Possible associated findings:* ascites, portal vein dilatation, splenomegaly



**Fig. 325** Congestive cirrhosis. The liver still has a normal parenchymal echo pattern, but note the curved, bulging inferior border and the tiny breaks in the capsule (arrows). A = ascites

- ▶ **Hepatic cirrhosis** (Fig. 326): In early and intermediate stages (Child A and B), there may be only slight coarsening of the parenchymal echo pattern with very little disruption or lobulation of the liver contours, resulting in an absence of characteristic changes (Table 42).

**Table 42** · Sonographic features of hepatic cirrhosis

Direct signs	Indirect signs
Coarsening of the parenchymal echo pattern (stippled to mottled pattern)	Intrahepatic portal vein dilatation > 11 mm, flow changes (see p. 259)
Enlargement and hypoechoic transformation of the caudate lobe	Portal vein dilatation in the hepatoduodenal ligament > 13–15 mm
Bulging contours	Splenomegaly
Vascular irregularities, bowing, abrupt caliber changes	Ascites
Recanalized umbilical vein	Portosystemic collaterals
Breaks in the capsule (“brush” or “shingled roof” appearance)	
Luminal expansion of the hepatic artery (see Fig. 368, p. 259)	

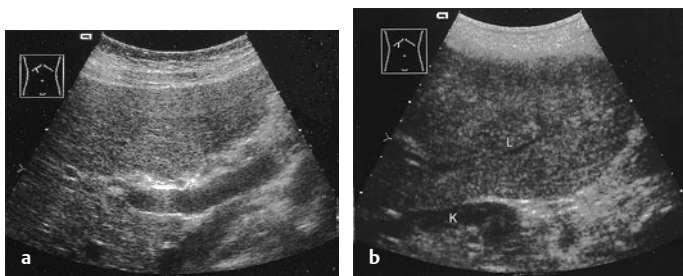


Fig. 326a, b Hepatic cirrhosis, Child stage A. **a** Autoimmune cirrhosis: minimal changes in the echo pattern, slightly wavy contour, increased portal vein diameter (14.2 mm, cursors). **b** Hepatic cirrhosis in GAVE syndrome: bulky, slightly wavy hepatic border with hepatomegaly. The patient presented clinically with recurrent gastric bleeding, a Quick PT of 60%, and a history of alcohol abuse. L = liver, K = kidney

### Very Pronounced Changes in Echogenicity or Contours

#### ► Sarcoidosis (Fig. 327):

- Pronounced coarsening of the parenchymal echo pattern
- Hypochoic micronodular infiltrates

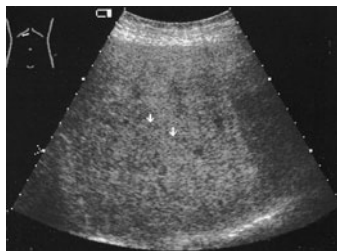


Fig. 327 Sarcoidosis of the liver: coarse parenchymal echo pattern, nonvisualization of the vessels, and multiple small hypochoic foci (arrows)

#### ► Micronodular abscesses or metastases (Fig. 328):

- Coarse, grainy hypochoic texture
- Vessels faint or not visualized (compression by portal vessels, hepatic veins)

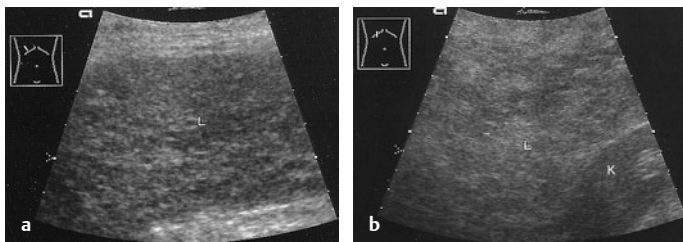


Fig. 328a, b Micronodular infiltrates in the liver (L). **a** Microabscesses in urosepsis: grainy hypochoic texture (same appearance as mycotic abscesses). **b** Micronodular hypochoic metastases from a neuroendocrine tumor. K = kidney

- ▶ **Toxic fatty liver, chronic toxic (drug- or alcohol-induced) liver disease** (Fig. 329): With increasing severity and fibrous transformation, structural changes tend to occur:
- Generally increased echogenicity with individual coarse echoes
  - Acoustic shadowing, even with minimal depth of involvement
  - Caliber irregularities and nonvisualization of hepatic veins and small portal venous branches
  - Incipient lobulation and granularity of hepatic contours
  - Progressive increase in portal vein diameter

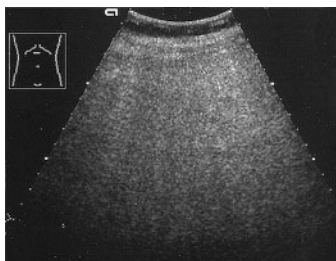


Fig. 329 Severe chronic, drug-induced toxic liver disease with fibrosis: dense, granular hyperechoic texture with no detectable vessels and marked acoustic shadowing (same appearance as chronic toxic alcoholic liver disease with structural transformation)

- ▶ **Severe chronic hepatitis with structural change or cirrhosis** (Figs. 330 and 331):
- ▶ **Note:** The echo pattern and contours of the liver depend on the extent of the changes, the degree of fibrous transformation that has occurred, and the etiology of the cirrhosis. The appearance of the portal vessels, the presence of ascites, and the size of the spleen depend on the severity of portal hypertension and on inflammatory activity.
- *Direct and indirect sonographic signs:* see Table 42, p. 236
  - *Sonographic signs indicating the etiology of cirrhosis:* see Table 43.

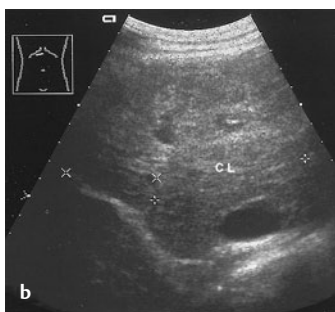
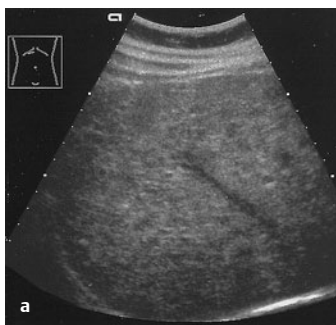


Fig. 330a, b Advanced chronic viral hepatitis, hepatic cirrhosis. **a** Severe chronic hepatitis B: patchy structural transformation with poor delineation of the hepatic veins. **b** Child stage B hepatic cirrhosis in hepatitis C: coarse, echogenic areas of fibrosis with massive enlargement of the caudate lobe (CL). CL:RL (right liver) = 74:43 mm = 1.7 (cursors; normal ratio  $\leq 0.55$ )

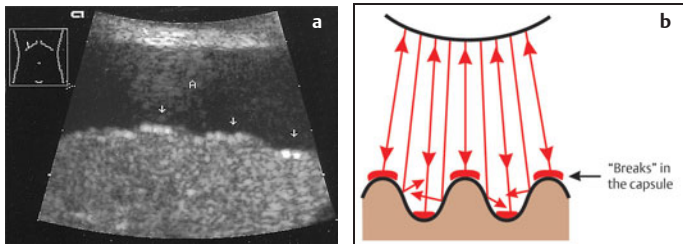


Fig. 331a, b Decompensated alcoholic cirrhosis. **a** Discontinuities in the capsule (arrows). A = ascites. **b** Apparent breaks in the capsule due to the lobulated liver surface. “Brush” or “file” appearance due to fine surface nodularity (after Rettenmaier)

**Table 43 · Sonographic signs indicating the etiology of cirrhosis**

Hepatic cirrhosis	Alcoholic cirrhosis	Congestive cirrhosis
Coarsening of the parenchymal echo pattern	Organ enlargement	Enlarged liver
Bulging contours	Fine, diffuse coarsening of the echo pattern	Mostly smooth but often bulging contours, good through transmission due to hepatic venous congestion (no luminal change with respirations)
Hypoechoic regenerative nodules (caution: primary hepatic carcinoma!)	Increased echogenicity	Vena cava congestion
Altered vascular architecture on CDS (curved veins with irregular calibers, “pruned” portal veins, dilated hepatic artery)	Distal acoustic shadowing	No bowing of vessels or caliber irregularities by CDS
	Small contour bulges with breaks in the capsule (brush or file appearance)	Ascites
	Altered vascular architecture on CDS	

► **Diffuse metastasis or hepatic metastases during chemotherapy, systemic hematologic diseases** (Figs. 332 and 333):

- Increased parenchymal echogenicity
- Distal acoustic shadowing (as in a fatty liver)
- Slightly irregular or hazy echo pattern
- Bulging contours
- CDS: vascular displacement, infiltration, spot-like vascularity
- Possible associated finding: microcalcification

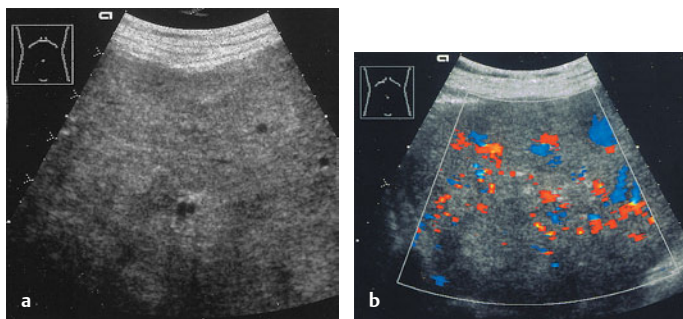


Fig. 332a, b Metastatic liver in a patient with colorectal carcinoma. **a** B-mode: heterogeneous parenchymal echo pattern with no evidence of discrete metastases. **b** CDS: A normal vascular architecture is no longer detectable. The irregular spots of vascularity indicate the extent of liver destruction

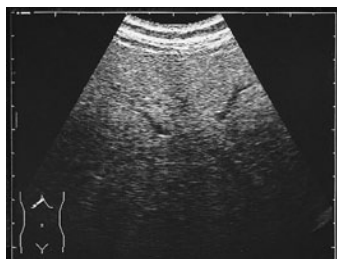

Fig. 333 Chronic myeloid leukemia with diffuse cellular infiltration: slight coarsening of the parenchymal echo pattern with distal acoustic shadowing

### Interpretation and Further Testing

- ▶ **Role of sonography:** Ultrasound cannot replace histology, but it can do the following:
  - Detect previously unknown findings with high confidence
  - Narrow the differential diagnosis based on sonographic features
  - Classify a clinically presumed liver disease as diffuse or focal, often permitting a specific diagnosis to be made
  - Eliminate or lessen the need for invasive endoscopic procedures (laparoscopy)
  - Provide an accuracy rate of almost 80% in the diagnosis of hepatic cirrhosis
- ▶ **Indications for histology:**
  - Diagnosis of hepatitis and evaluation of its inflammatory activity
  - Differentiation of hepatic cirrhosis from siderocirrhosis; differentiation of alcoholic fatty liver from diabetic or toxic drug-induced fatty liver and from a storage disease
- ▶ **Further tests:** These depend upon sonographic and clinical findings:
  - *Findings characteristic of a fatty liver:*
    - Additional tests are unnecessary unless there is a discrepancy between clinical and ultrasound findings. In this case an ultrasound-guided percutaneous liver biopsy should be done to differentiate other conditions with a similar

- echo pattern: chronic hepatitis C, Gaucher disease, toxic liver disease, NASH, diffuse malignant infiltrates
- Only exceptional cases require confirmation by blind liver biopsy (after locating the puncture site sonographically) or by laparoscopy
  - *Suspected metastasis or unexplained ascites:*
    - Laparoscopy and histologic evaluation
    - *Sonography:* use CDS, contrast-enhanced sonography, and THI
    - Other imaging studies such as CT angiography and MRI
  - *Symptoms of cholestasis* (e.g., sclerosing cholangitis): Evaluate by ERC.

## 9.3 Circumscribed Changes

### Overview (Table 44):

**Table 44 · Circumscribed hepatic changes**

Anechoic	Hypoechoic	Isoechoic	Echogenic, hyperechoic
Hepatic cysts (p. 242)	Focal sparing in fatty infiltration (p. 245)	Atypical lobulation (p. 251)	Diaphragmatic crura (p. 251)
Portal vein ectasia (p. 243)	Hypoechoic transformation of the caudate lobe (p. 246)	Isoechoic metastases (p. 251)	Focal fatty infiltration (p. 252)
Aneurysms, shunts (p. 243)	Regenerative nodule in hepatic cirrhosis (p. 246)	Focal nodular hyperplasia (p. 248)	Echogenic ligamentum teres (p. 252)
Cystic lesions (p. 244)	Hemorrhagic hepatic cyst (p. 247)		Echogenic portal tracts ("starry sky") (p. 253)
	Portal vein thrombosis (p. 247)		Fresh hematoma (p. 253)
	Abscess (p. 247)		Hemangioma (p. 253)
	Focal nodular hyperplasia (p. 248)		Lesions in porphyria (p. 254)
	Adenoma (p. 248)		Primary hepatic carcinoma (p. 254)
	Atypical hemangioma (p. 49)		Metastasis (colon carcinoma, carcinoid, p. 254)
	Primary hepatic carcinoma (p. 49)		Calcification (p. 254)
	Metastases (p. 250)		Intraductal stones (p. 254)
	Systemic hematologic diseases (p. 250)		Pneumobilia (p. 254)
			Hemorrhagic cyst (p. 254)

## Anechoic Changes

- ▶ **Liver cysts** (Figs. 334–336): congenital or acquired. May be solitary or multiple and may occur in a cystic liver, as biliary cysts, or in Caroli syndrome
  - **Solitary and multiple cysts:**
    - Anechoic round lesions (or elliptical when flattened by other organ structures; show tapered extensions when close to portal tracts); smooth margins
    - Distal acoustic enhancement
    - Weakly echogenic wall (with edge shadowing)
    - Occasional septations
    - High-resolution scan may provide an edge-on view of the cyst wall
    - Associated mass effects (on vessels, vena cava, or portal vein)
  - **Cystic liver:** greatly enlarged liver of variable size (> 17–20 cm). In 50% of patients other organ systems are involved (polycystic kidneys, pancreatic cysts)
  - **Biliary cysts:** Ultrasound can define the affected bile duct, which occasionally contains a stone.
  - **Caroli syndrome** (congenital dilatation of the intrahepatic bile ducts, Fig. 336): segmental, saccular dilatation of the bile ducts

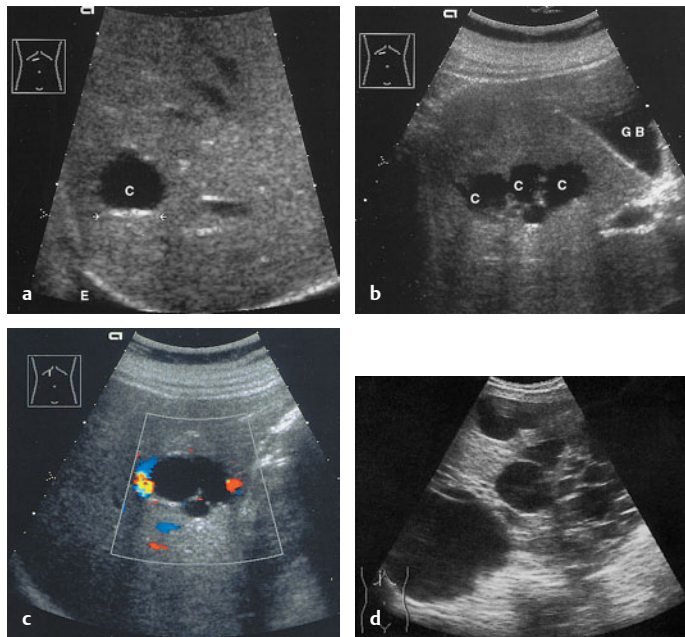


Fig. 334a–d Cystic masses in the liver. **a–c** Simple cysts (C). **a** Typical cystic criteria with wall echoes (arrows). **b** Septated cysts. **c** CDS: no internal vascularity. **d** Multiple anechoic round masses with acoustic enhancement posterior to the cysts

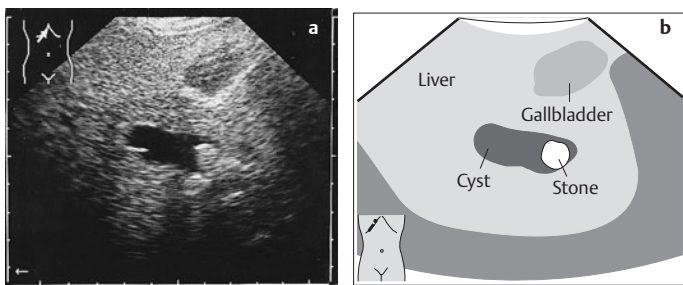


Fig. 335a–c Cystic lesions: **a, b** Stone in a biliary cyst communicating with the right hepatic duct (confirmed at operation): incomplete acoustic shadow. The patient presented clinically with biliary colic (but no stones in the gallbladder). **c** Peliosis hepatis. The appearance is similar to that of hepatic cysts (left), but the liver presents an irregular, patchy hypoechoic structure with multiple echo-free cystic masses up to 10 mm in size (arrows). When the image is magnified, the relationship of the cysts to portal vessels can be appreciated. IVC = inferior vena cava

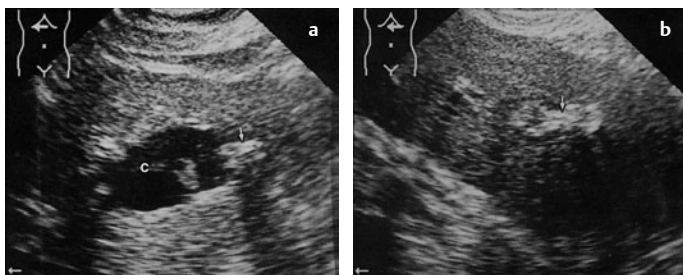
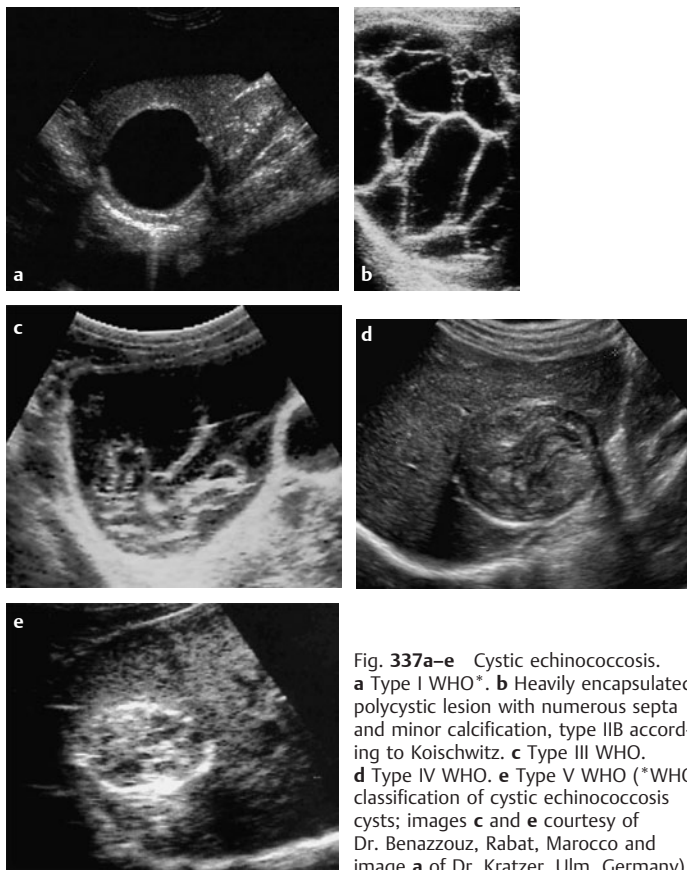


Fig. 336a, b Cystic dilatation of intrahepatic bile ducts (C) in Caroli syndrome. **a** Stones and incomplete shadowing (arrow) with intra- and extrahepatic duct stones. **b** Residual intrahepatic stones (arrow) following operative treatment; cystic duct expansion has resolved

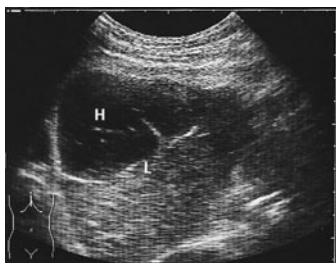- ▶ **Portal vein ectasia** (peliosis hepatis; rare; Fig. 335):
  - Multiple round or oval, tapered, or angular anechoic lesions that communicate with portal venous branches
  - No detectable Doppler flow
- ▶ **Hepatic artery aneurysm, arteriovenous shunts, Osler disease:**
  - Round, anechoic, pulsating lesion
  - Communicates with the artery (Doppler signal, color flow detection by CDS)

- **Cystic lesions** (Figs. 337–339): inflammatory, infectious (echinococcosis, abscess), traumatic (hematoma), or neoplastic (cyst-like metastasis, regressive liquefied metastasis)
- *Echinococcal cyst* (*E. granulosus*, Fig. 337): anechoic round lesion (see also cystic liver, p. 153) echogenic wall, and calcifications in cystic echinococcosis
  - **Note:** Alveolar echinococcosis (*E. multilocularis* = fox tapeworm) presents as a solid, infiltrating tumor-like mass.
  - *Hematoma, abscess* (Fig. 338): usually has irregular margins without a cyst wall. May contain low-level internal echoes
  - *Cyst-like metastases* (Fig. 339)



**Fig. 337a–e** Cystic echinococcosis. **a** Type I WHO\*. **b** Heavily encapsulated polycystic lesion with numerous septa and minor calcification, type IIB according to Koischwitz. **c** Type III WHO. **d** Type IV WHO. **e** Type V WHO (\*WHO classification of cystic echinococcosis cysts; images **c** and **e** courtesy of Dr. Benazzouz, Rabat, Morocco and image **a** of Dr. Kratzer, Ulm, Germany)

Fig. 338 Hematoma (H) in the upper portion of the left liver (L). Detected incidentally several weeks after resuscitation



### Hypoechoic Changes

► **Focal sparing of the liver in fatty infiltration** (Figs. 340 and 342):

- Most commonly found in the periportal region and adjacent to the gallbladder bed of the liver
- Elliptical to triangular shape
- May occasionally show a patchy or flame-shaped distribution throughout the liver

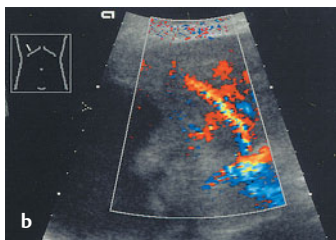
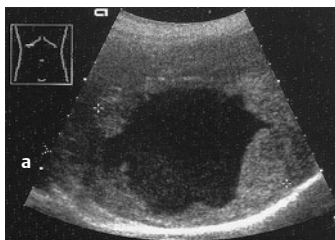


Fig. 339a, b Carcinoid metastases (neuroendocrine tumor). **a** Typical, predominantly liquefied mass lined by peripheral, echogenic tumor tissue. **b** CDS demonstrates a hypervascular mass (unlike other metastases)

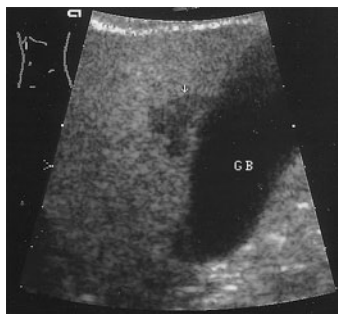

Fig. 340 Focal sparing in fatty infiltration; Polygon-shaped hypoechoic area (arrow) adjacent to the gallbladder bed of the liver

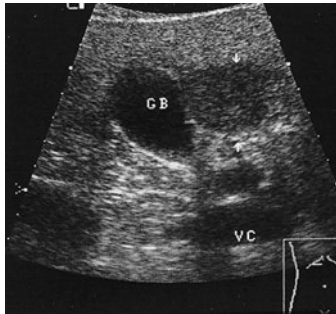


Fig. 341 Hypoechoic quadrate lobe (segment IV, arrows) adjacent to the gallbladder (GB) in an otherwise fatty liver

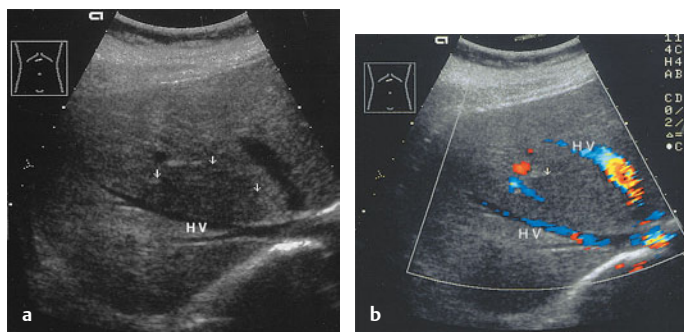


Fig. 342a, b Regional differences in fatty infiltration with focal sparing (arrows) in segment VIII between the right and left hepatic veins (HV), which pass unchanged through the spared area. No additional tests were required.

a B-mode image, b CDS

► **Decreased echogenicity of the caudate lobe** (Fig. 343):

- Relatively coarse, hypoechoic texture
- Enlarged liver with bulging contours in hepatic cirrhosis

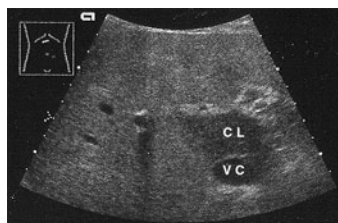


Fig. 343 Decreased echogenicity of the caudate lobe (CL, segment I) anterior to the vena cava (VC) in an otherwise normal-looking liver

► **Regenerative nodule in a cirrhotic liver** (Fig. 344):

- **Note:** Differentiation is mainly required from primary hepatocellular carcinoma
- Pea- to cherry-sized nodule
- *Intrahepatic regenerative nodule:* round, hypoechoic
- *Peripheral regenerative nodule:* rounded bulge in the liver contour

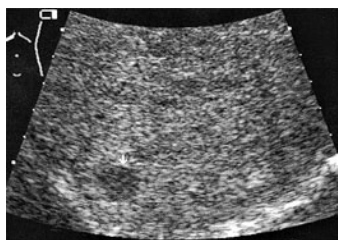

Fig. 344 Regenerative nodule in severe alcoholic toxic cirrhosis (arrow), confirmed cytologically

► **Hemorrhagic liver cyst** (Fig. 345):

- Hypoechoic mass with smooth margins
- Internal echoes are often seen with position changes

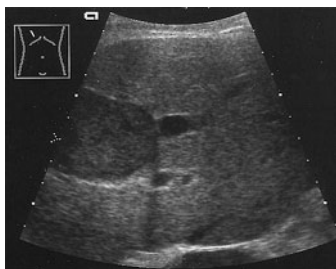

Fig. 345 Hemorrhagic liver cyst: hypoechoic, sharply circumscribed mass with a faintly echogenic wall

► **Intrahepatic portal vein thrombosis** (Fig. 346):

- Round, elliptical or elongated, depending on the plane of section
- Loose echo texture, isoechoic to slightly hypoechoic

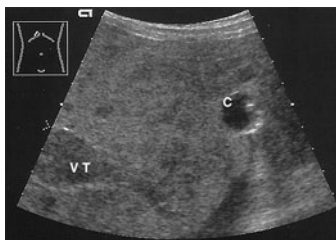


Fig. 346 Intrahepatic portal vein thrombosis (VT): enlarged vessel lumen with intraluminal echoes. All of the small branches (hypoechoic foci) are thrombosed together with the main trunk and tributaries. Clinical presentation: portal vein thrombosis with a fatal outcome. C = liver cyst

► **Abscess** (Fig. 347):

- Hypoechoic (anechoic) to hyperechoic, heterogeneous echo pattern
- Irregular margins, frequently ill-defined
- Often contains fine, echogenic gas bubbles with incomplete acoustic shadows or reverberations
- Hyperechoic pyogenic membrane is often present

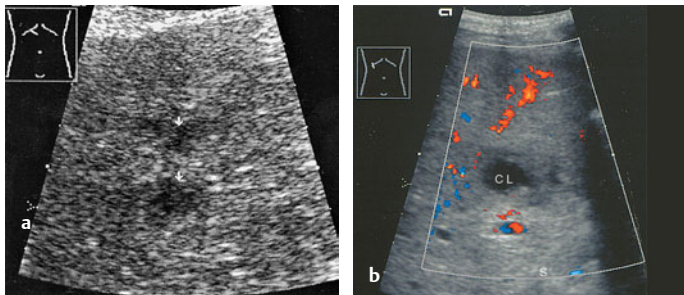


Fig. 347a, b Liver abscess. **a** Liver abscesses resulting from septic cholangitis: lesions with ill-defined margins (arrows). **b** Liver abscess resulting from the biliary spread of infection: nonhomogeneous mass with ill-defined margins, a faintly hypoechoic rim, and central liquefaction (CL). The lesion is avascular on CDS

► **Focal nodular hyperplasia (FNH, Fig. 348):**

- Hypoechoic round or elliptical mass, usually with smooth margins
- Echo pattern is often heterogeneous due to the presence of (central) connective tissue (= scars)
- Echogenic extensions radiating toward the periphery (stellate scar)
- CDS: vessels passing through the radial connective tissue (“spoked-wheel” pattern)

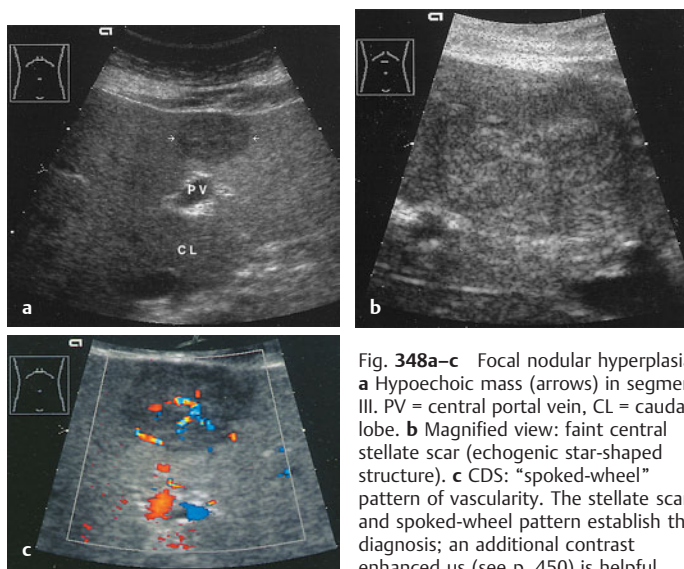


Fig. 348a–c Focal nodular hyperplasia. **a** Hypoechoic mass (arrows) in segment III. PV = central portal vein, CL = caudate lobe. **b** Magnified view: faint central stellate scar (echogenic star-shaped structure). **c** CDS: “spoked-wheel” pattern of vascularity. The stellate scar and spoked-wheel pattern establish the diagnosis; an additional contrast enhanced us (see p. 450) is helpful

► **Adenoma (Fig. 349; see p. 450):** resembles in B-mode FNH, as it consists entirely of hepatocytes and blood vessels:

- Uniformly isoechoic or hypoechoic mass
- Smooth margins

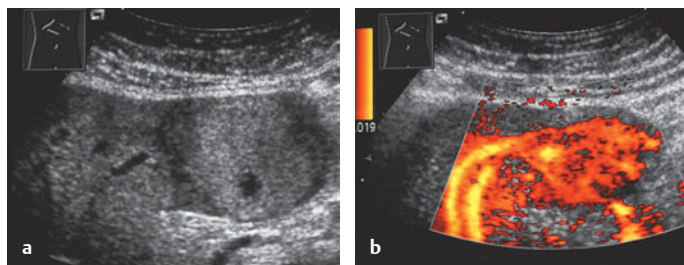


Fig. 349a, b Liver adenoma. **a** Isoechoic tumor with focal anechoic necrosis/hemorrhage. **b** Power Doppler: distinctive vascularization with arterial supply.

248 Histology: hepatocellular adenoma

- Pseudocapsule or hypoechoic rim
  - Possible low-level internal echoes due to intralesional hemorrhage
  - CDS: well-vascularized tumor without a characteristic vascular pattern. Arterial feeding vessels can be demonstrated.
- ▶ **Atypical hemangioma** (Fig. 350):
- Cloudy hypoechoic texture (especially in a fatty liver)
  - Large tumors present a complex, patchy hypoechoic to hyperechoic pattern due to regressive changes (calcifications, intralesional hemorrhage).
  - A peripheral halo or vascular pedicle may be present.

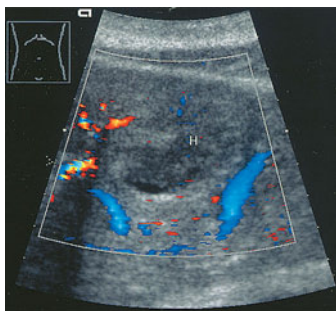

Fig. 350 Atypical hypoechoic hemangioma (H) penetrated by an arterial vessel (red). Other sonographic features are indistinguishable from those of other tumors

▶ **Primary hepatic carcinoma:**

- *Hepatocellular carcinoma* (Fig. 351):
  - Variable appearance; typical metastatic appearance when found in an intact liver
  - Hypoechoic, isoechoic, hyperechoic, or nonhomogeneous. Solitary or isolated lesions in a cirrhotic liver often do not have a peripheral halo.
  - Frequent regressive changes (intralesional hemorrhage, calcification)
  - CDS: marked vascularization by arterial tumor vessels with no typical pattern of arrangement (“chaotic”)

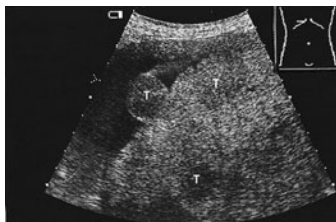

Fig. 351 Primary hepatocellular carcinoma: several slightly hypoechoic tumor masses (T) in a liver affected by alcoholic toxic cirrhosis; ascites

- *Cholangiocellular carcinoma* (Fig. 352):
  - Diffuse type of growth
  - Isoechoic or sometimes hypoechoic texture (due to heavy fibrosis)
  - Infiltration
  - Locoregional metastases, ascites

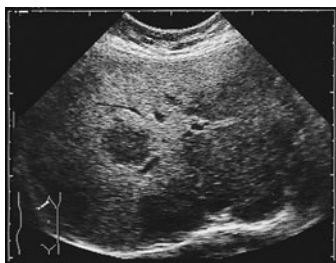

Fig. 352 Primary cholangiocellular carcinoma (CCC) of the liver: lesion with ill-defined margins. Changes identical to CCC have been observed in thorostrastosis (NB: these cannot be positively distinguished from focal sparing by fatty infiltration)

- ▶ **Metastases** (Fig. 353; Fig. 195, p. 150; Figs. 665–668, p. 443, 444):
  - Cyst-like metastases often have irregular margins
  - Small, intensely hypoechoic metastases, with or without a hypoechoic rim, represent young lesions. Multiple lesions with the same appearance indicate synchronous metastasis. Lesions of varying size and appearance represent multiple tumor generations.
  - *CDS*: no detectable intratumoral or peripheral vessels (except in metastases from neuroendocrine tumors, hepatocellular carcinoma, or renal cell carcinoma)

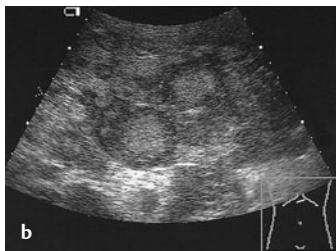
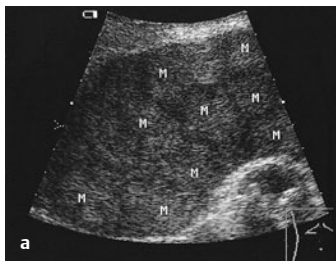
Fig. 353a, b Hepatic metastases. **a** Multiple intensely hypoechoic metastases (M) of the same shape and size (synchronous lesions) with peripheral halos. **b** Metastases of varying size and echogenicity, partially confluent (multiple tumor generations)

- ▶ **Hematologic malignant systemic diseases** (Figs. 354, 333, p. 240):
  - Micronodular lesions (in chronic myeloid leukemia) or macronodular lesions (with high-grade lymphomas, lymphogranulomatosis)
  - Intensely hypoechoic, usually without a peripheral halo

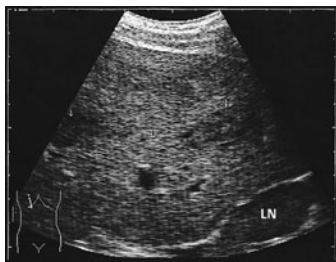

Fig. 354 Chronic myeloid leukemia: pronounced hypoechoic nodular infiltrates (arrows) in the liver (L). LN = enlarged, infiltrated lymph node

- Often accompanied by other intra-abdominal sites of lymph node infiltration; similar appearance with splenic involvement

### Isoechoic Changes

#### ► Atypical lobulation (Fig. 355):

- Rounded, sharply circumscribed bulge in the liver contour
- Internal echo pattern identical to that of the liver parenchyma
- Bulging contours
- *With a Riedel lobe:* may project past the kidney or gallbladder

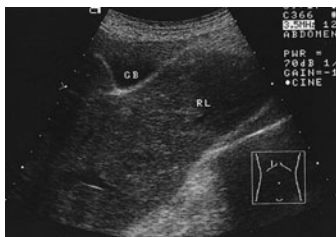


Fig. 355 Atypical lobulation: Riedel lobe (RL). GB = gallbladder

#### ► Isoechoic metastases (Fig. 356): can be identified only by the presence of a hypoechoic rim, displacement, or infiltration. Better delineation is obtained with THI, CDS, or contrast-enhanced sonography.

- Isoechoic lesion, detectable only by a hypoechoic rim
- Possible displacement or infiltration

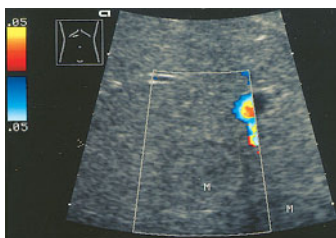


Fig. 356 Isoechoic hepatic metastases (M) from pancreatic carcinoma. The lesions are demarcated from normal liver tissue only by a hypoechoic rim (this accounts for a certain percentage of sonographically occult metastases that are detectable by other modalities). The lesions are avascular on CDS

### Echogenic and Hyperechoic Changes

#### ► Diaphragmatic crura (Fig. 357):

- Relatively echogenic band extending into the liver from the diaphragm (subcostal scan)
- **Note:** Diaphragmatic crura constricting the liver surface correspond to the indentations visible at laparoscopy.

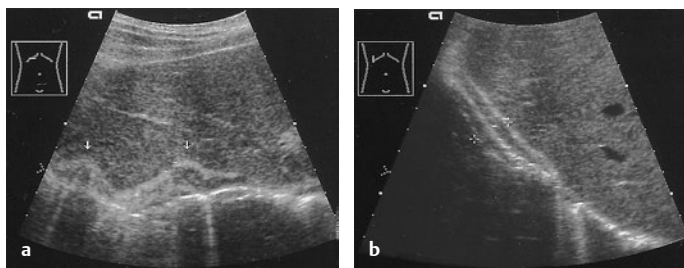


Fig. 357a, b Echogenic diaphragmatic crura (arrows). **a** Subcostal oblique scan. **b** Constriction of the liver by a diaphragmatic crus, displayed in an approximate longitudinal scan

► **Focal fatty infiltration** (Fig. 358):

- Echogenic elliptical or tapered lesion in an otherwise normal-appearing liver
- Same location as focal sparing (gallbladder bed, periportal region)

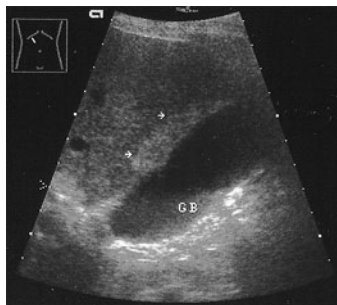


Fig. 358 Focal fatty infiltration (arrows), typical location adjacent to the gallbladder bed: elliptical echogenic structure. GB = gallbladder

► **Echogenic ligamentum teres** (Fig. 359):

- Rounded, triangular, or elliptical structure between the right and left anatomic lobes of the liver (in the subcostal scan), or

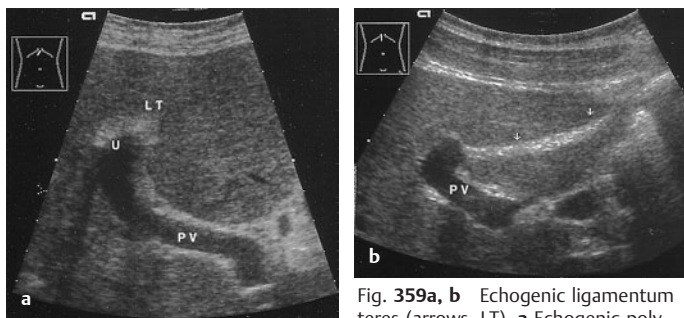


Fig. 359a, b Echogenic ligamentum teres (arrows, LT). **a** Echogenic poly-

hedrad figure at the end of the umbilical branch (U) of the portal vein (PV).

**252 b** Longitudinal scan shows the ligament coursing to the anterior abdominal wall

- Elongated echogenic band, located on or to the right of the midline, extending from the umbilical branch of the portal vein to the anterior abdominal wall
- ▶ **Echogenic portal tracts, “starry sky” appearance (Fig. 360):**
  - Normal variant; markedly echogenic portal tracts
  - Fine, diffuse echogenic foci, often with associated bandlike vascular structures

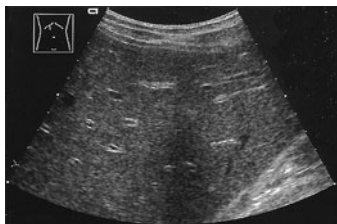

Fig. 360 “Starry sky” appearance of the liver (after Rettenmaier) caused by echogenic portal tracts

- ▶ **Fresh hematoma:**
  - Patchy area with irregular margins
  - Echogenic (unlike an old hematoma)
- ▶ **Hemangioma (Fig. 361a):**
  - Echogenic or isoechoic
  - Smooth margins

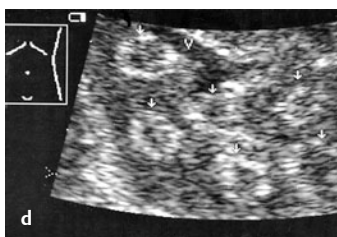
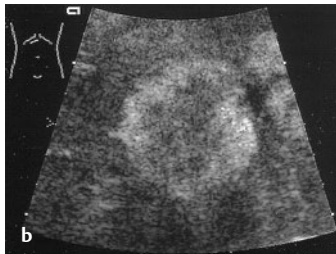
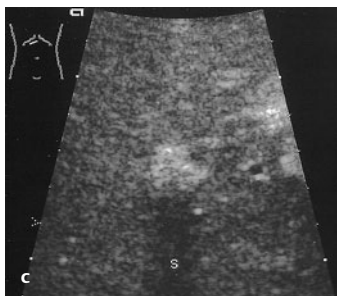
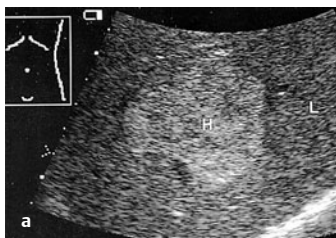Fig. 361a–d Echogenic mass in the liver. **a** Hemangioma (H) of the liver (L): typical echogenic, round to oval mass with smooth margins. **b** Metastasis from colon carcinoma: echogenic round mass with a less echogenic center. **c** Calcifying metastasis from colorectal carcinoma. S = acoustic shadow. **d** Chronic hepatic porphyria (porphyria cutanea tarda): disseminated, echogenic target lesions (arrows), no longer detectable several years later (misinterpreted initially as multiple hemangiomas). Clinical presentation: history of alcohol abuse, signs of porphyria. V = hepatic vein

- Round to oval shape
- Often multiple, may contain calcifications, rarely has a peripheral rim
- ▶ **Metastasis from colon carcinoma, carcinoid metastasis** (see Fig. 361b):
  - Round shape
  - Echogenic (or isoechoic) texture
  - Often lacks a peripheral rim (not unlike a hemangioma)
  - In other respects the lesion meets the standard sonographic criteria for metastases (see p. 442).
- ▶ **Primary hepatic carcinoma** (see Fig. 667, p. 444):
  - Round echogenic lesions, generally in a setting of hepatic cirrhosis
  - Lobulated contours
- ▶ **Echogenic lesions in porphyria** (Fig. 361d):
  - Multiple hemangioma- or cholangioma-like lesions of the same size
  - Target pattern (hypoechoic center)
  - Reversible
- ▶ **Calcification** (Fig. 337c; Figs. 666, 667, p. 444): very high-amplitude echo with an acoustic shadow (e.g., calcified hematoma, calcification or gas bubbles in an abscess, intracystic calcification)
- ▶ **Duct stones** (see Fig. 182, p. 141):
  - Intensely echogenic focus projected into a bile duct, often multiple
  - Zone of acoustic shadowing
  - Frequent dilatation of the bile duct
- ▶ **Pneumobilia** (see Fig. 648, p. 433):
  - String-of-beads or bandlike echogenic structure distributed along the bile ducts
  - Reverberation artifacts
- ▶ **Hemorrhagic cyst** (Fig. 362):
  - Smooth margins, round shape
  - Fine, floating echoes that swirl when tapped
  - Echogenic clots
  - Usually accompanied by other cysts

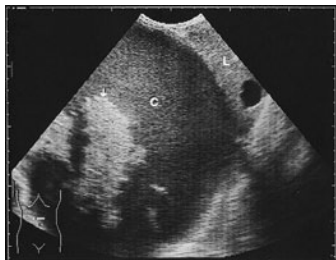

Fig. 362 Hemorrhagic liver cyst (C) with echogenic clotted blood (arrow), producing a complex overall echo pattern. The small original cyst is in the left lobe (L)

### Changes with a Complex Echo Pattern

- ▶ **Hepatic lesions with a complex echo pattern:** See Fig. 363).

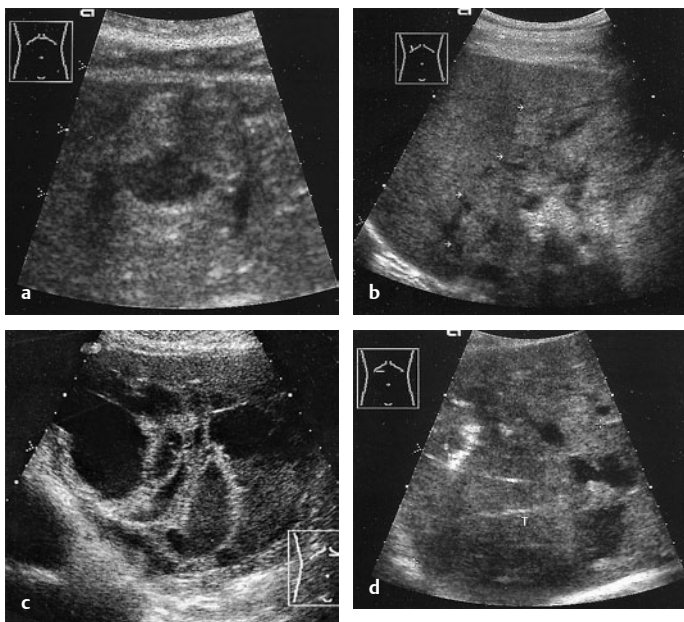


Fig. 363a–d Complex masses in the liver. **a** Atypical hepatic hemangioma. **b** Traumatic rupture of the liver with heterogeneous anechoic to echogenic areas (arrows). **c** Zones of liquefaction in a tumor metastatic to breast carcinoma. **d** Abscess formation in a metastasis from renal cell carcinoma (T, cursors)

### Interpretation and Further Testing

- ▶ **Role of sonography:** Ultrasound is the most widely utilized, economical, and safest modality for hepatic imaging. Most lesions can be detected quickly and with a very high accuracy rate (> 90%).
  - **Vascularity:** With new sonographic techniques such as harmonic imaging, power duplex scanning, and contrast-enhanced Doppler sonography, ultrasound is becoming comparable to CT angiography in its vascular imaging capabilities:
    - Ultrasound can demonstrate the central artery and “spoked-wheel” pattern that are characteristic of FNH, and it can also show the “iris diaphragm” sign (peripheral-to-central enhancement) that is characteristic of hemangiomas.
    - Hepatocellular carcinoma shows only a slight increase in vascularity relative to surrounding liver, whereas adenomas and malignant metastases in particular (except for neuroendocrine metastases and metastases from renal cell carcinoma and melanoma) display little or no vascularity.
  - **Detection of metastases:** This depends on the size, echogenicity, and location of the primary tumor. Ultrasound has a > 80% accuracy rate in the detection of metastases that are not much smaller than 1 cm.
  - **Detection of cysts** (intensely hypoechoic lesions): Cysts can be identified sonographically with no need for other imaging studies.

### 9.3 Circumscribed Changes

- Typical echogenic hemangiomas (75% are homogeneously echogenic), focal sparing in fatty infiltration, and typical metastases (from a known primary tumor) can also be positively identified with ultrasound. Newly detected hemangiomas require at least a 6 month sonographic follow-up. If they are > 3.5 cm, additional imaging modalities should be used.
- **FNH:** When the examination includes CDS, this lesion can be diagnosed sonographically in 70% of cases based on the typical criteria of a stellate scar and spoked-wheel pattern. Thirty percent of lesions are atypical.

#### ► Further investigations:

- **FNAB with fine-needle histology:**
  - **Advantages:** cost-effective, largely free of side effects, relatively short examination time; a routine procedure for experienced examiners
  - **Indications:** all indeterminate circumscribed lesions: abscess (complete removal), FNH, hematoma, and malignant tumors
  - **Exceptions:** suspected echinococcosis, superficial metastases, and hemangioma or adenoma (because of the risk of uncontrolled bleeding)
- **CT:**
  - **Indications:** hemangiomas, focal sparing, and metastases that have an isoechoic or atypical appearance. Often these lesions cannot be adequately evaluated with ultrasound, and CT should be used in all suspected cases. CT is also indicated in patients with a suspected primary hepatic carcinoma.
  - **Features of primary hepatocellular carcinoma:** Tumor often contains hemorrhagic areas with attenuation values < 30 HU that do not enhance after intravenous contrast administration. Hypodense tumors show marked contrast enhancement and become hyperdense in the arterial phase.
- **CT angiography:** used in sonographically equivocal cases that show evidence of hemangioma, adenoma, or FNH
  - **Adenoma:** hypodense mass that may contain hemorrhagic areas; enhances rapidly, becoming hyperdense in the arterial phase. Enhancement slowly fades over a period of 3–10 min.
  - **FNH:** hypodense mass that contains a pathognomonic central scar in 30–40% of cases. On dynamic CT, it enhances very rapidly to hyperdensity in the arterial phase and fades rapidly to low attenuation within 1–2 min.
  - **Hemangioma:** hypodense mass with ill-defined margins and attenuation values of 35–55 HU on unenhanced CT scans. On dynamic CT, peripheral “puddle” enhancement occurs in the early arterial phase (80% of cases). Shows peripheral-to-central fill-in at the start of the portal phase (“iris diaphragm” sign)
- **MRI:** may be used in cases with equivocal sonographic findings, an unknown primary tumor, or primary hepatocellular carcinoma:
  - **Primary hepatocellular carcinoma:** hypointense to the liver parenchyma on T1-weighted images, hyperintense on T2-weighted images. Difficult to distinguish from other hepatic lesions
  - **Hemangioma:** T2-weighted spin-echo sequence shows very high signal intensities, which persist in multi-echo sequences even as T2-weighting is increased. Useful in differentiating hemangioma from other focal hepatic changes
- **Laparoscopy:**
  - **Hemangioma:** irregular reddish mass (when in an accessible, superficial location)

- *Other indications:* unexplained ascites; unexplained hepatic cirrhosis; differentiation of hepatic cirrhosis, hepatic metastases, FNH, and tuberculosis. May be carried out before metastasectomy
- ▶ **Ultrasound-guided therapeutic intervention:** ethanol injection for inoperable primary hepatic carcinoma (see also p. 60)
  - *Procedure:*
    - Same preparations as for FNAB (p. 58)
    - Instillation of 4–10 mL of 96% ethanol for small lesions (or 20–180 mL for extensive lesions) at a single point or in a fan-shaped pattern under continuous vision under local resp. general anesthesia
    - The injection needle is left in place for 3–5 min, then withdrawn stepwise.
  - *Complications:* pain (peritoneal irritation), fever due to tumor necrosis

## 9.4 Changes in the Portal Venous System

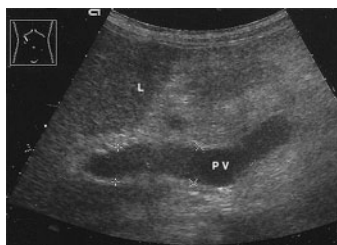
- ▶ In portal hypertension, the luminal size (transverse diameter) of the portal veins correlates poorly with the portal pressure. Thus, the diagnosis of portal hypertension relies not only on increased portal vein diameter but also on the results of CDS with spectral analysis and the assessment of flow characteristics.
  - Definite signs of portal hypertension (by CDS) are flow reversal and an absence of flow.
- ▶ The causes of raised portal venous pressure are classified as follows:
  - *Prehepatic* (portal vein thrombosis)
  - *Intrahepatic* (cirrhosis)
  - *Posthepatic* (Budd–Chiari syndrome)
- ▶ **Examination:** see p. 189.
- ▶ **Overview:** See Table 45.

**Table 45 · Changes in the portal veins**

Luminal dilatation (portal hypertension)	Flow changes and collaterals
Dilatation of the portal vein (p. 257)	Flow changes (p. 259)
Dilatation of the tributaries (lack of compressibility, p. 258)	Portosystemic collaterals (p. 259)
Compression or occlusion of a tributary vein (segmental portal hypertension, p. 259)	
Intraluminal changes	Associated effects
Acute portal vein thrombosis (p. 260)	Displacement, compression (p. 261)
Chronic portal vein thrombosis (p. 260)	Infiltration (p. 261)

### Luminal Dilatation (Portal Hypertension)

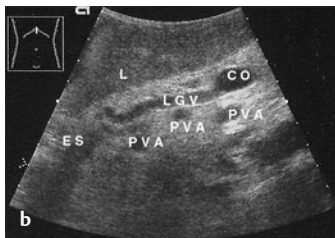
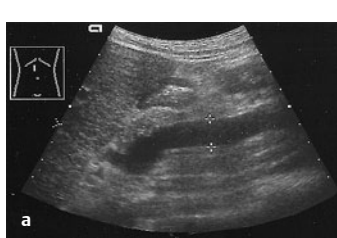
- ▶ **Increased portal vein diameter, indirect signs (Fig. 364):**
  - > 11 mm intrahepatic, > 13–15 mm in the hepatoduodenal ligament
  - Caliber variations < 2 mm or 50–100% with respirations
  - Detection of hepatic cirrhosis
  - Splenomegaly
  - Possible ascites
  - Wall thickening of the gallbladder and stomach



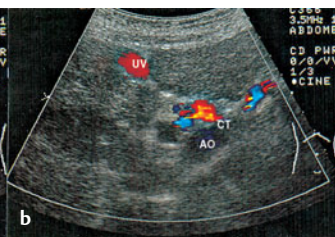
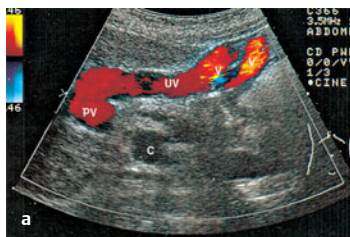
**Fig. 364** Incipient portal hypertension. The portal vein (PV) is marginally dilated: 12.9 mm intrahepatic, 13.7 mm in the hepatoduodenal ligament (cursors). L = liver

► **Dilated tributaries, lack of compressibility** (Figs. 365, 366):

- Left gastric vein dilated to > 4 mm
- Superior mesenteric vein dilated to > 10 mm (often exceeding the portal vein diameter)
- Good visualization of the inferior mesenteric vein
- Splenic vein, usually with splenomegaly



**Fig. 365a, b** Portal hypertension, portosystemic collaterals. **a** Superior mesenteric vein dilated to 14 mm (cursors). Arrow: dilatation of the left gastric vein, which descends to the portal vein (PV) from the left side. **b** Scan higher and to the left demonstrates the left gastric vein (LGV) passing from the venous confluence (CO) to the esophagus (note varices). ES = esophagus, PVA = perigastric varices



**Fig. 366a, b** Recanalized umbilical vein, paraumbilical vein (UV) arising from the umbilical branch of the left portal vein (VP). CDS: portosystemic collaterals with tortuous periumbilical vessels (“caput medusae”) that generally empty into the right or left iliac vein. **a** High upper abdominal longitudinal scan. **b** Right subcostal oblique scan. AO = aorta, CT = celiac trunk, C = venous confluence

- ▶ **Compression or occlusion of a tributary vein** (Fig. 367): segmental portal hypertension
  - Usually encased by tumor masses
  - With splenic vein involvement, also inflammatory obliteration or thrombosis due to chronic pancreatitis.

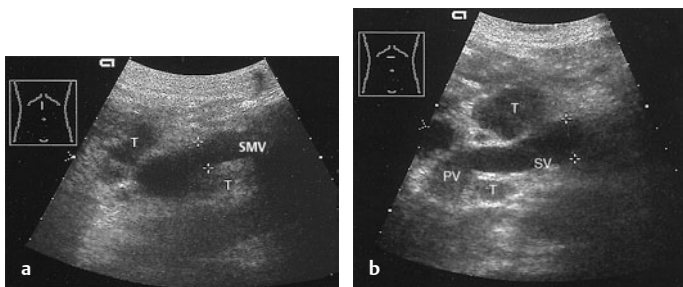


Fig. 367a, b Segmental portal hypertension resulting from superior mesenteric lymph node metastasis (T). Tumor stenosis with dilated portal tributaries. **a** Superior mesenteric vein (SMV) dilated to 12.4 mm (cursors). **b** Splenic vein (SV) dilated to 17.6 mm (cursors). PV = portal vein

### Flow Changes and Collaterals

- ▶ **Flow changes** (Fig. 368):
  - Flow velocity is slowed to  $< 10$  cm/s (normal = 15–20 cm/s) (Fig. 368a)
  - Luminal diameter  $> 15$  mm, does not vary with respirations
  - Bidirectional, absent or reverse flow in the portal vein or its tributaries (Fig. 368b)
- ▶ **Collaterals** (Fig. 369): detection of portosystemic collaterals

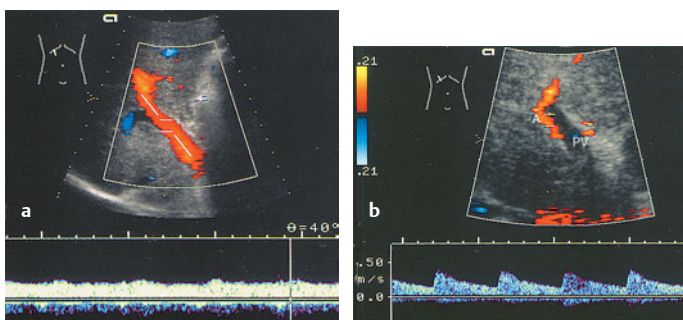


Fig. 368a, b Portal hypertension in liver cirrhosis. CDS: decreased flow velocity with absence of flow in the portal vein. **a** Flow is in the normal hepatopetal direction (encoded in red), but its velocity is slowed to 9 cm/s. **b** Absence of flow in the portal vein (PV). Additional sign: large-caliber hepatic artery (A), arterial waveform

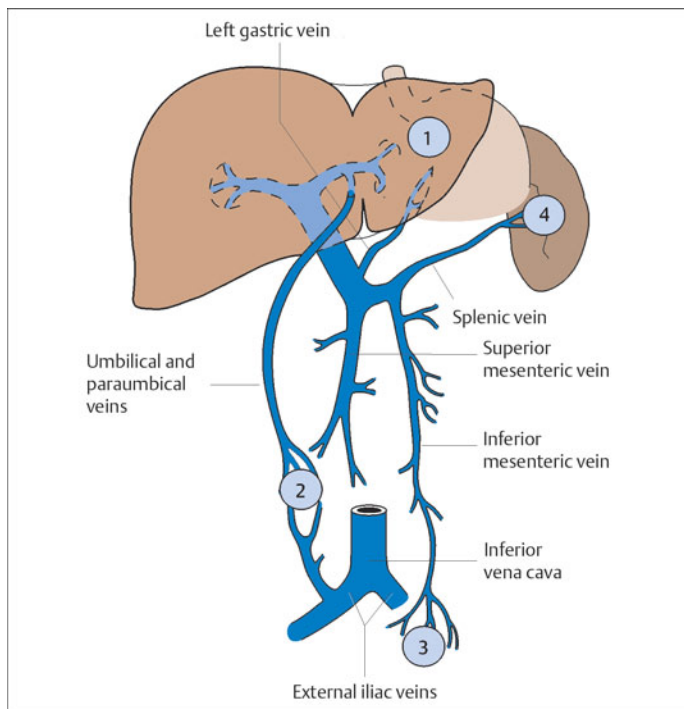


Fig. 369 Portosystemic collaterals: 1 = fundal and esophageal varices, 2 = recanalized paraumbilical and umbilical veins, 3 = hemorrhoidal venous collaterals, 4 = splenic hilar collaterals

### Intraluminal Changes

- ▶ **Acute portal or mesenteric vein thrombosis** (see Fig. 116, p. 85):
  - Echogenic filling defect
  - Vascular dilatation
  - Absence of color Doppler flow signals
  - **Note:** Clinical picture of acute abdomen.
- ▶ **Chronic portal vein thrombosis** (Fig. 370):
  - Little or no luminal dilatation
  - Echogenic intraluminal thrombus
  - No measurable flow by Doppler ultrasound, resulting in collateral formation and recanalization (cavernous transformation of the portal vein, see Fig. 371)

Fig. 370 Chronic portal vein thrombosis (PVT) in the setting of a paraneoplastic syndrome. Hepatic metastases: very little increase in luminal diameter, intraluminal echoes in thrombosed portal vein segments. Intrahepatic portal vein (PV) is clear

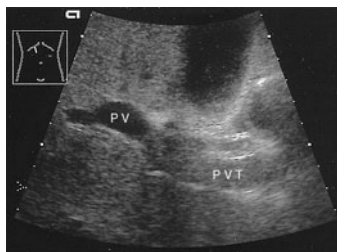
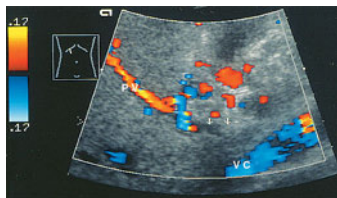


Fig. 371 Cavernous transformation of the portal vein. Tortuous vessels resulting from tumor infiltration of the portal vein (patchy red/blue vessels representing tortuous collaterals) and portal vein occlusion (arrows). PV = intrahepatic portal vein with normal course, VC = inferior vena cava



### Associated Effects

► **Displacement, compression:**

- Intrahepatic due to cirrhosis or tumors
- Extrahepatic due to chronic pancreatitis or pancreatic tumors

► **Infiltration (Fig. 371):**

- Faint, irregular vascularity
- The causative malignancy can usually be detected (see Search for Occult Tumors, p. 447)

### Interpretation and Further Testing

- **Sonography:** CDS with the analysis of spectral indices has become the standard method of choice for evaluating the portal venous system.
- **Pressure measurements and splenoportography:** These are no longer used in routine examinations.
- **Esophagoscopy and conventional esophagography:** Gastroscopy or esophagography is essential for the detection of esophageal varices in patients with hepatic cirrhosis.

## 10 Kidney and Adrenal Gland

### 10.1 Examination

#### Kidney

##### ► Scan planes:

- Flank scan (see p. 25, 26)
- Upper abdominal transverse scan (see p. 22)
- Lateral upper abdominal longitudinal scan (see p. 24)

##### ► Sonographic anatomy and normal findings (Figs. 372 and 373):

- The kidneys are located in the retroperitoneum on the iliopsoas muscles. Their longitudinal axes point laterally downward at a divergent angle. They are tilted laterally, and their lower poles are directed forward.
- An imaginary line joining the bases of the medullary pyramids separates the cortical substance of the kidney from the medulla.
- The center of the renal ellipse (central echo complex, CEC) appears hyperechoic and consists of vessels, connective tissue, renal sinus fat, and the actual renal pelvis.

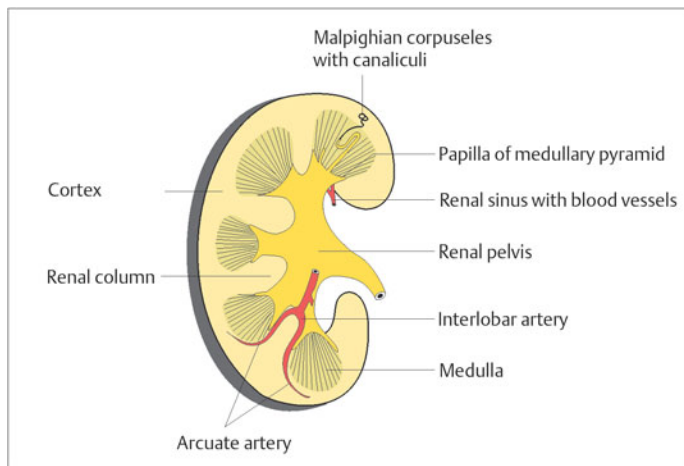


Fig. 372 Section through the kidney

##### ► Normal values:

- Length 100–115 mm, width 50–70 mm, thickness 30–50 mm.
- *Parenchyma*: The parenchymal–pelvic ratio (ratio of the combined anterior and posterior parenchymal thickness to the CEC) is 1.7 up to 60 years of age and 1.1 after age 60.

► **Note:** Because of the position of the kidneys (see above), their size cannot be accurately determined. It tends to be underestimated, and their sonographically determined size is approximately 20 mm below the normal value. Unless the

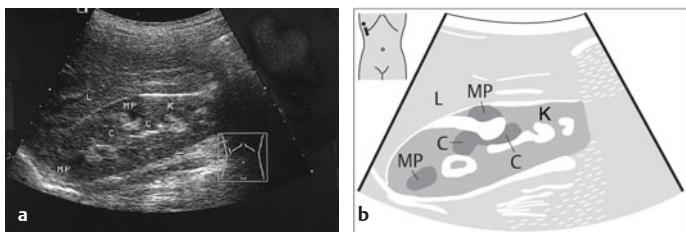


Fig. 373a, b Normal right kidney (K). L = liver, MP = hypoechoic medullary pyramids, C = renal columns

longest renal dimension is accurately visualized, ultrasound measurements will be too low.

► **Scanning protocol:**

- *Transducer:* 3.5–5.0 MHz
- Patient generally supine. Left lateral decubitus occasionally used
- *Right kidney:* The right liver provides a good acoustic window for scanning the right kidney. The lower pole is occasionally obscured by the right colic flexure but is accessible to scanning from the posterior side.
- *Left kidney:* An acoustic window is not available for the left kidney. Scanning from the posterolateral side is advantageous as it avoids overlying gas in the colon and gastric fornix.
- Always scan the kidneys during inspiration and expiration to ensure that they are completely visualized (rib shadows and bowel gas are often troublesome) and move normally with respiration (i.e., are not fixed by perirenal abscesses).
- Both kidneys are systematically surveyed in longitudinal and transverse planes.

► **Scanning tips:**

- If a kidney is not visualized, think of agenesis or nephrectomy. An ectopic kidney is often located in the lesser pelvis anterior to the iliac vessels. The possible causes of nonvisualization are listed below.

► **Note:** Take measurements to determine renal size. A visual estimate is often incorrect.

► **Causes of large or small kidneys** (see also Table 47, p. 267):

- *Small kidneys:* May be constitutional or may result from hypoplasia or ectopia, making the organs difficult to locate (Fig. 374).

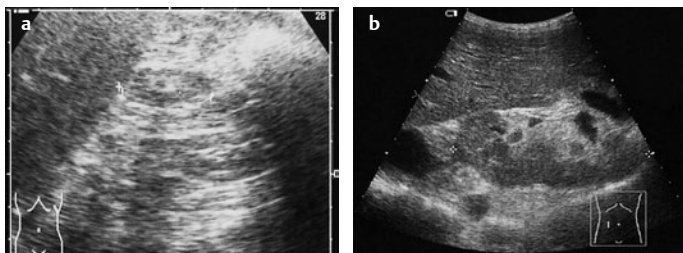


Fig. 374a, b a Renal hypoplasia. The “absent left kidney” is probably a tiny hypoplastic kidney (cursors). b Malrotated kidney at a slightly ectopic location (cursors). The renal hilum is directed anteriorly

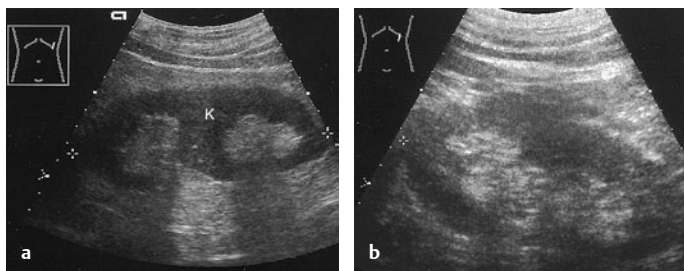


Fig. 375a, b Large kidneys. **a** Duplex kidney (K, cursors 132.5 mm) with a parenchymal band, **b** Acromegaly (cursors 138.1 mm)

- *Large kidneys*: May be constitutional or may result from duplex kidneys, unilateral aplasia, acromegaly, or compensatory enlargement of the remaining kidney after nephrectomy (Fig. 375).
- ▶ **Causes of difficult visualization or nonvisualization:**
  - *Ectopic kidney*: Located along the path of its normal ascent, usually in the lesser pelvis near the iliac vessels; “lower abdominal mass” (see Fig. 376)
  - *Unilateral renal agenesis*: Characterized by enlargement of the contralateral kidney
  - *Hypoplastic kidney*: Careful inspection of the renal fossa in a close-up view should reveal a small kidney with normal-appearing parenchyma.
  - *Atrophic kidney*: Shrunken kidney that displays abnormalities in its contours, internal echo pattern, or both
  - *Renal fusion anomaly*: A bilateral “horseshoe kidney” initially appears as two normal kidneys, but the lower poles are found to be fused across the midline in the lesser pelvis.

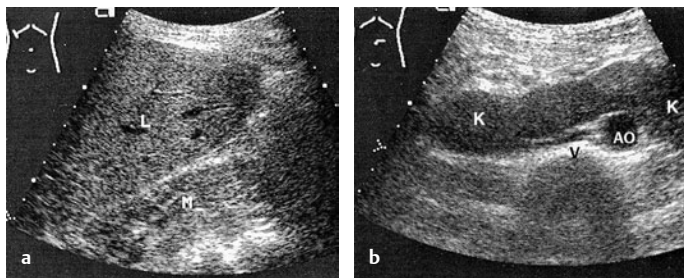


Fig. 376a, b Empty right renal fossa, caused by a partial horseshoe kidney on the left side (K). AO = aorta, V = compressed vena cava, M = lumbar muscle, L = liver

## Adrenal Glands

### ▶ Scan planes:

- Upper abdominal transverse scan (right adrenal gland)
- Upper abdominal oblique scan (right adrenal gland)

- High flank scan (left adrenal gland)
- High upper abdominal transverse scan (left adrenal gland)
- ▶ **Sonographic anatomy and normal findings** (Figs. 377 and 378):
  - The normal adrenal glands have a variety of ultrasound appearances, usually presenting a forked, Y, or triangular shape.
  - The right adrenal gland is located between the upper pole of the kidney and the inferior vena cava. The left adrenal gland lies between the upper pole of the kidney and the aorta.

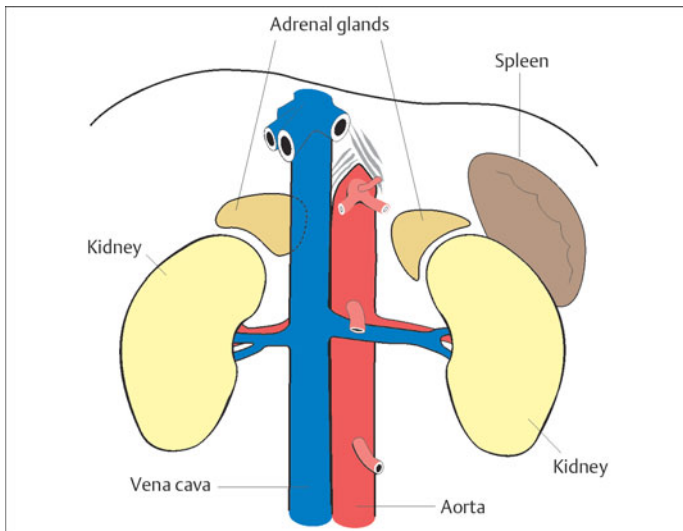


Fig. 377 Topography of the adrenal glands

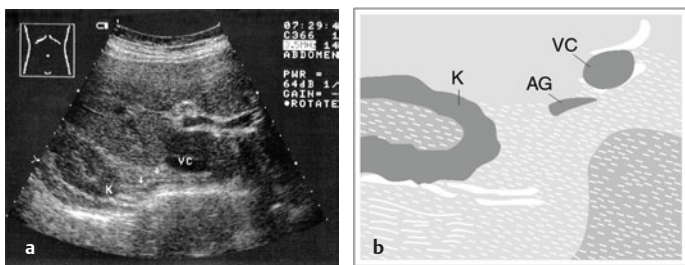


Fig. 378a, b Normal right adrenal gland (arrows, AG) located between the kidney (K) and vena cava (VC)

▶ **Scanning protocol:**

- ▶ **Note:** Normal adrenal glands can be identified only by prolonged scanning with high-resolution equipment. They are easier to image when they are enlarged (see Fig. 422a–d, p. 292).
- **Right adrenal gland:** High lateral upper abdominal transverse or oblique scan defining the renal upper pole and the inferior vena cava (the adrenal gland should be between them), and an upper abdominal longitudinal scan in the midclavicular line or anterior axillary line demonstrating the vena cava
- **Left adrenal gland:** High flank scan through the lower pole of the spleen and the upper pole of the kidney, with the transducer angled medially toward the aorta. As on the right side, the gland can be identified between the aorta and renal upper pole in a high upper abdominal transverse scan.

### Overview and Classification of Findings

- ▶ **Size changes:** Acute diffuse diseases are generally associated with renal enlargement due to inflammatory edematous swelling, whereas chronic diseases are marked by a decrease in renal size caused by loss of parenchyma. In chronic glomerulonephritis and diabetic nephropathy, the kidneys do not shrink in size until the disease has progressed to the dialysis stage.
- ▶ **Echogenicity changes:** Increased or decreased echogenicity reflects tissue changes at the histologic level (see Table 46).

**Table 46 · Relationship between histologic change and renal echogenicity**

Decreased echogenicity	Increased echogenicity
Interstitial edema	Leukocytic or tumor-cell infiltration
	Hyaline or crystalline deposition
	Tubular atrophy
	Fibrosis or sclerosis

- ▶ **Diffuse renal changes** with or without a change in size: see p. 267 and Table 47.
- ▶ **Circumscribed changes in the renal parenchyma:** see p. 272 and Table 48.
- ▶ **Circumscribed changes in the renal pelvis or renal sinus:** see p. 283 and Table 49.
- ▶ **Perirenal masses:** see p. 292.
- ▶ **Adrenal glands:** see p. 292.

## 10.2 Diffuse Renal Changes

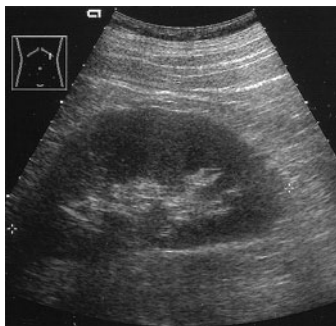### Overview (Table 47):

**Table 47** · Diffuse renal changes

Hypoechoic	Hyperechoic
<i>Enlarged or normal-sized kidneys</i>	
Acute renal failure, transient renal insufficiency	Acute renal failure (hyperuricemia, sepsis, p. 268)
Acute bacterial interstitial nephritis (pyelonephritis, p. 268)	Diabetic nephropathy, early stage (see p. 269)
Renal vein thrombosis (p. 268)	Acute glomerulonephritis (p. 269)
	Renal myeloma, adrenal amyloidosis (p. 269), gouty nephropathy
<i>Small or normal-sized kidneys</i>	
Hypoplastic kidney (p. 269)	Chronic glomerulonephritis (p. 270)
Renal atrophy due to vascular occlusive disease (p. 270)	Diabetic nephropathy (p. 270)
	Chronic pyelonephritis (p. 271)
	Analgesic nephropathy (p. 271)

### Enlarged or Normal-Sized Kidneys with Decreased Echogenicity

- ▶ **Acute renal failure or transient renal insufficiency** (Fig. 379): Prerenal–cardiovascular or postrenal.
  - *Sonographic findings:*
    - Parenchymal thickening with associated thinning of the CEC; renal sinus echo
    - Decreased echogenicity



**Fig. 379** Transient renal insufficiency in a patient with alcohol-related disease and diarrhea: Enlarged hypoechoic kidneys with swollen parenchyma and loss of corticomedullary differentiation. Length = 170 mm!

- ▶ **Acute bacterial interstitial nephritis = pyelonephritis** (Fig. 380; emphysematous pyelonephritis, see Fig. 397, p. 278; acute suppurative pyelitis, see Fig. 412, p. 286)
  - Thickened, hypoechoic, hazy parenchyma with a thinned sinus echo. A rim of fluid is often visible in the renal pelvis. Incipient abscess appears as a hypoechoic zone.
  - *CDS*: Perfusion defect with an increase in surrounding vascularity

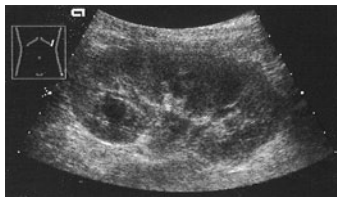

Fig. 380 Acute pyelonephritis: Large, hypoechoic kidney with an obliterated sinus echo and a rim of fluid in the renal pelvis

- ▶ **Renal vein thrombosis** (Fig. 381a, b):
  - Hazy, hypoechoic renal echo pattern
  - Evidence of venous thrombosis
  - Tumor thrombosis is common (see Fig. 393e, p. 275)
  - *CDS*: Veins not visualized. Absence of flow in the renal vein, reverse flow in arteries with a high RI; see Table 30, p. 193.

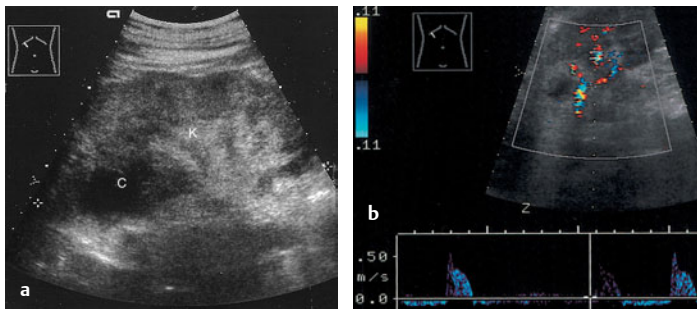


Fig. 381a, b Renal vein thrombosis. **a** Acute renal vein thrombosis in septic pyelonephritis: Enlarged kidney (K, cursors) with a hazy, hypoechoic structure and patchy-streaky hypoechoic transformation of the central echo complex. C = atypical cyst. **b** Spectral analysis shows an extremely high RI of 0.96

### Enlarged or Normal-Sized Kidneys with Increased Echogenicity

- ▶ **Acute renal failure:**
  - *With massive hyperuricemia* (Fig. 280): echogenic parenchyma
  - *With sepsis*: large, echogenic kidneys
  - *With diabetic nephropathy* (Fig. 382a):
    - Enlargement, sometimes massive
    - Hyperechoic parenchyma
    - Hypoechoic medullary pyramids

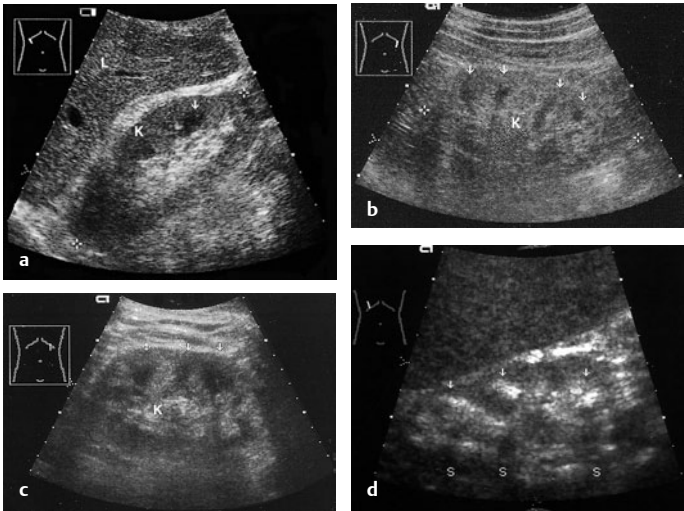


Fig. 382a–d Increased renal echogenicity. **a** Diabetic nephropathy: Large kidney (12.5 cm) with prominent hypoechoic medullary pyramids (arrow). **b** Subacute glomerulonephritis: Increased cortical echogenicity with very hypoechoic medullary pyramids (arrows). **c** Renal myeloma, renal insufficiency: Basically the same features as in **a**, with an echogenic parenchyma and hypoechoic medullary pyramids (arrows; K = kidney). **d** Gouty nephropathy: Increased echogenicity of the medullary pyramids reflects the precipitation of uric acid in the tubules (arrows; S = acoustic shadows). Patient presented with ubiquitous gouty tophi, hyperuricemia, and mild renal function impairment. Differential diagnosis: medullary nephrocalcinosis, medullary sponge kidney (tuberulosis)

- ▶ **Diabetic nephropathy, early stage** (Mogensen stage I–IV; Fig. 382a):
  - Increase in renal volume
  - Hyperechoic parenchyma
  - Prominent hypoechoic medullary pyramids
- ▶ **Acute glomerulonephritis** (Fig. 382b): Clinical signs include fever, somnolence, weakness, oliguria, and hypertension.
  - *Laboratory findings:* elevated creatinine, erythrocyturia, proteinuria
  - *Sonographic findings:*
    - Marked renal enlargement due to parenchymal swelling
    - Consequent narrowing of the CEC
    - Increased echogenicity
    - Prominent hypoechoic medullary pyramids
- ▶ **Renal myeloma, renal amyloidosis, gouty nephropathy** (Fig. 382c):
  - Significant increase in echogenicity
  - Prominent hypoechoic medullary pyramids

### Small Kidneys with Normal Echogenicity

- ▶ **Hypoplastic kidney** (see Fig. 374a, p. 263): small kidney with normal parenchymal echogenicity

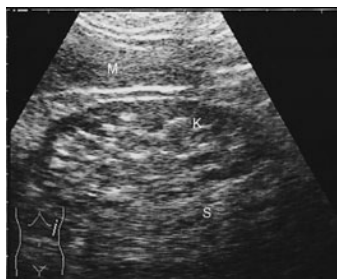

Fig. 383 Hypoplastic kidney (K) due to renal artery stenosis: Small kidney with parenchymal thinning. Patient presented clinically with severe hypertension. S = faint acoustic shadow

- ▶ **Renal atrophy due to vascular occlusive disease** (Fig. 383): Small kidney, usually showing loss of parenchyma → CDS with determination of RI values (see p. 193)

### Small Kidneys with Increased Echogenicity

- ▶ **Chronic glomerulonephritis** (predialysis, dialysis; Fig. 384): Kidneys are not decreased in size until the dialysis stage.
  - Increased echogenicity
  - Loss of corticomedullary differentiation
  - Hypochoic cystic or ill-defined medullary pyramids

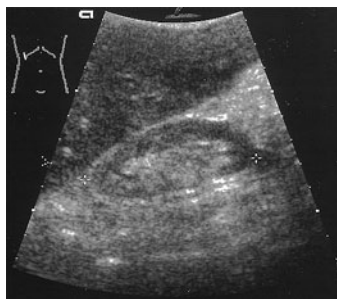


Fig. 384 Chronic glomerulonephritis (IgA nephropathy requiring dialysis): Small kidney (cursors) showing increased echogenicity, loss of corticomedullary differentiation, and a hazy internal echo pattern

- ▶ **Diabetic nephropathy** (Fig. 385):
  - Renal size is not decreased until the dialysis stage
  - Parenchymal thinning
  - Increased parenchymal echogenicity
  - Hazy parenchyma with irregular contours
  - Loss of corticomedullary differentiation
  - Loss or cystic transformation of the medullary pyramids
  - CDS: Loss of regional vascularity
  - End stage: Calcification (optional), secondary cysts (optional), loss of parenchyma

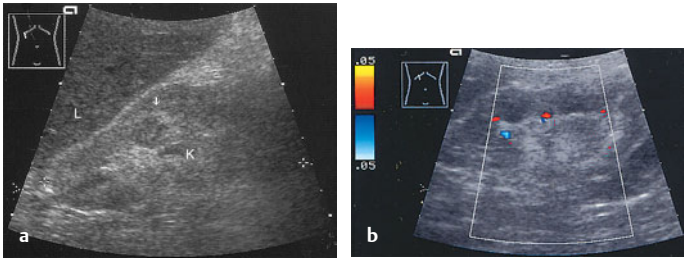


Fig. 385a, b Diabetic nephropathy at the dialysis stage. **a** Small kidney (K, 91.8 mm long) shows increased echogenicity. Arrow: Medullary pyramid with a patchy echo pattern. L = liver **b** CDS prior to dialysis shows very little vascularity

► **Chronic pyelonephritis** (Fig. 386):

- Kidneys often remain normal in size for years and do not shrink until the advanced stage.
- Focal echogenic scarring and thinning of the parenchyma accompanied by hypoechoic areas of hypertrophy
- Possible calyceal cysts, renal pelvic abscess

► **Analgesic nephropathy** (Fig. 387):

- Irregular, ill-defined contours, poor delineation, irregular parenchymal echogenicity
- Echogenic papillary microcalcifications
- Possible secondary retention cysts due to inflammation and scarring

Fig. 386 Decreased renal size in pyelonephritis (83.9 mm, cursors): Foci of parenchymal thinning due to scarring, producing a wavy surface contour. C = flat cyst. Fine-needle aspiration of a suspected abscess → adrenal epithelium

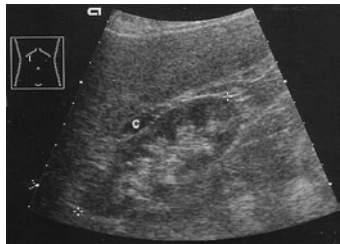
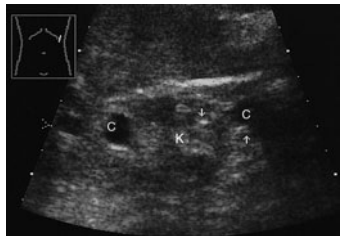


Fig. 387 Analgesic nephropathy (K). Harmonic imaging shows marked parenchymal thinning with a hazy internal echo pattern and fine calcifications projected over the papillary tip (arrows). Secondary cyst (C)



## 10.3 Circumscribed Changes in the Renal Parenchyma

### Overview (Table 48):

**Table 48 · Circumscribed changes in the renal parenchyma**

Anechoic	Hypoechoic	Isoechoic	Echogenic, hyperechoic
Simple cysts (p. 272)	Metastases (p. 276)	Bulge, lobulation (see p. 278)	Renal cell carcinoma (p. 279)
Polycystic kidneys (p. 273)	Malignant lymphoma (see p. 276)	Parenchymal bands (p. 278)	Angiomyolipoma (p. 279)
Secondary cysts (p. 274)	Renal adenoma (see p. 277)	Hematoma (p. 279)	Scars (p. 280) Renal infarction (p. 281)
Atypical or complicated cysts (p. 274)	Abscess, carbuncle (p. 277)	Renal cell carcinoma (p. 279)	Medullary nephrocalcinosis (p. 281)
Obstructive pyelocalyceal ectasia (p. 275)	Oncocytoma (p. 278)		Cortical nephrocalcinosis (see p. 282)
Cystic renal cell carcinoma (p. 276)			Vascular calcification, parenchymal calcification (p. 283)
Benign cystic lymphangioma (p. 275)			
Lymphocele (p. 275)			
Tuberculosis (p. 275)			
Intracystic hemorrhage (p. 275)			
Hematoma (p. 275)			

### Anechoic Changes in the Renal Parenchyma

- ▶ **Simple cysts** (Bosniak type I, Fig. 388): dysontogenetic cysts = tubular retention cysts
  - **Classification by location:**
    - Subcapsular (perirenal) cysts
    - Cortical cysts
    - Parapelvic cysts of the renal sinus (generally lymphatic cysts, but occasionally tubular retention cysts projecting into the central echo complex)
  - **Classification by number:**
    - Solitary
    - Multiple
  - **Sonographic criteria:**
    - Anechoic
    - Smooth margins with a thin wall and lateral edge shadowing
    - Round shape; parapelvic cysts may also have a flattened or oval shape
    - Distal acoustic enhancement

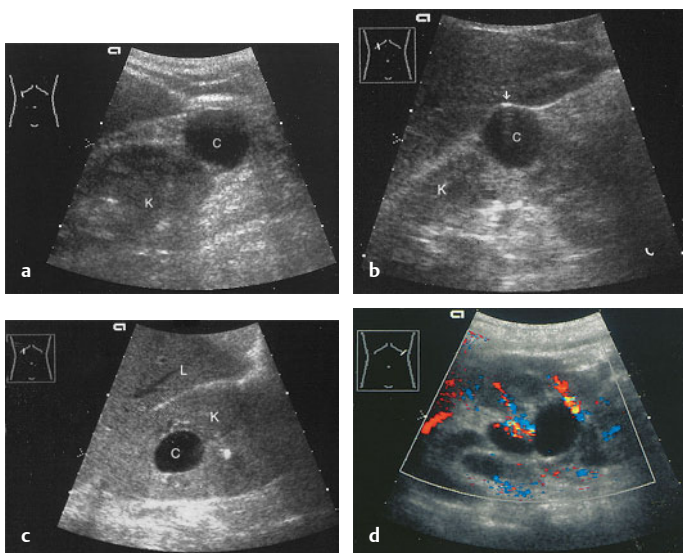


Fig. 388a–d Simple renal cysts (C). **a** Perirenal (subcapsular, “extrarenal”) cyst. **b** Cortical cyst. Arrow: orthograde projection of the renal capsule. **c** Parapelvic cyst. **d** CDS of parapelvic cysts shows absence of internal vascularity (this excludes a tumor). K = kidney

- A fine, echogenic capsule can often be identified in an orthograde projection (entry and exit echoes).

► **Polycystic kidneys** (adult type polycystic kidney disease, see Fig. 389):

- **Clinical features:** autosomal dominant mode of inheritance. Renal swelling, hypertension, and slowly progressive renal failure starting at about 40 years of age. Often accompanied by a cystic liver. The pediatric form becomes symptomatic at an early age.

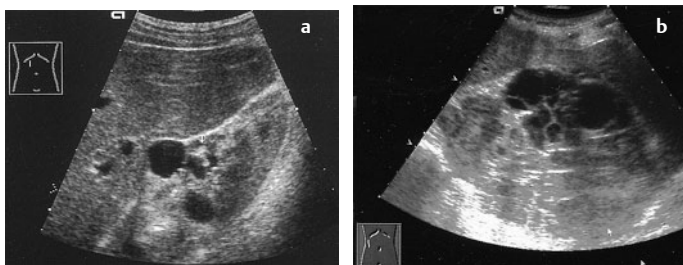


Fig. 389a, b Differentiation of polycystic kidney from multiple renal cysts. **a** Multiple renal cysts: The kidney is normal-sized with definable parenchyma. Arrow: parapelvic cysts. **b** Polycystic kidney: The kidney is enlarged and poorly defined with little evidence of residual parenchyma. A central echo complex is not visualized

- **Sonographic criteria:**
  - Small or large cystic masses, or a combination of both, permeating both kidneys
  - Significant renal enlargement
  - Little identifiable parenchyma
  - Absence of the CEC and loss of corticomedullary differentiation

▶ **Secondary cysts (Fig. 390):**

- **Occurrence:** secondary to an underlying renal disease such as nephritis, renal abscess, parenchymal scarring, diabetic nephropathy, or renal tuberculosis
- **Sonographic criteria:**
  - Usually have a noncircular shape
  - Often located near scar tissue
  - Cystic degeneration of medullary pyramids
  - Evidence of inflammatory renal disease

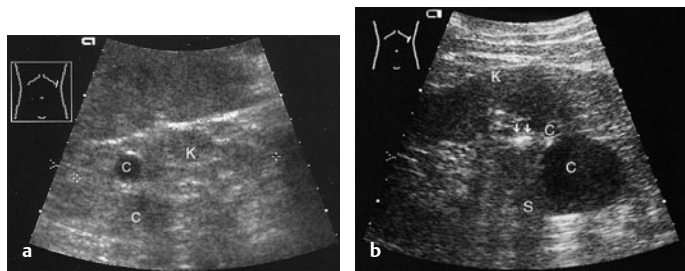


Fig. 390a, b Secondary cysts. **a** Secondary cysts (C) in analgesic nephropathy (decreased renal size, cursors). **b** Cavernous cysts (C) in renal tuberculosis with calcifications (arrows) and acoustic shadows (S). K = kidney

▶ **Atypical or complicated cysts (Bosniak types II and III):** Figs. 391, 392, 393c.

- **Atypical:** extrarenal extension
- Septation, calcification, intracystic hemorrhage; echinococcal cyst: single or septated cyst, hyperechoic wall
- **Vascularized septa:** cystic renal carcinoma (Bosniak type IV)

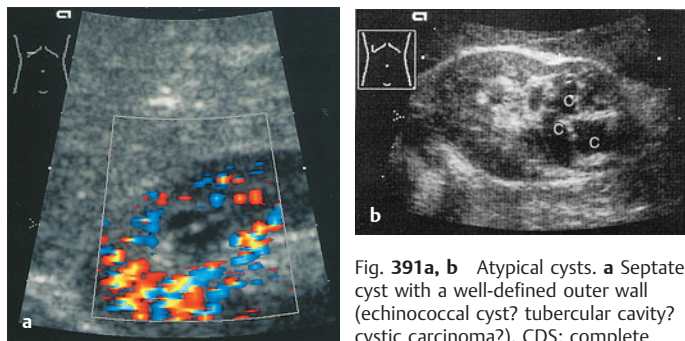


Fig. 391a, b Atypical cysts. **a** Septated cyst with a well-defined outer wall (echinococcal cyst? tubercular cavity? cystic carcinoma?). CDS: complete absence of vascularity and a well-defined echogenic wall. **b** Atypical cysts (C) with septa-like internal structures and bulging contours (arrow) → requires

274 cytohistologic evaluation!

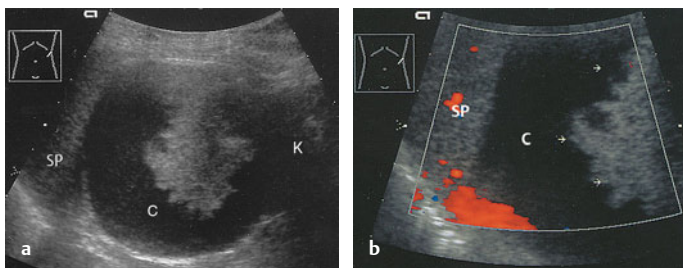


Fig. 392a, b Complicated cyst with internal hemorrhage. **a** Anechoic clotted blood (arrows in b) within the cyst (C), which is still identifiable. SP = spleen, K = kidney. **b** CDS: no detectable vascularity. This excludes a cystic tumor

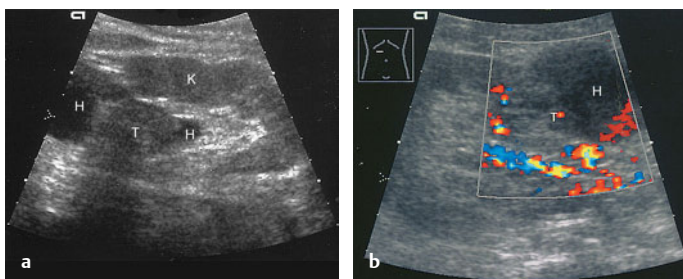


Fig. 393a, b Cystic renal cell carcinoma. **a** Renal cell carcinoma (T) with cystic regressive changes and areas of intralesional hemorrhage (H). K = kidney **b** Cystic renal cell carcinoma (T, H). CDS: predominantly cystic mass. Only the peripheral vascular rim marks the outlines of a solid tumor

- ▶ **Obstructive pyelocalyceal ectasia** (see Fig. 408, p. 285):
  - Multiple oval or triangular anechoic masses
  - Dilatation of the renal pelvis
  - Dilatation of the ureteropelvic junction
- ▶ **Multiple parapelvic cysts** (“benign cystic lymphangioma”): see Fig. 407, p. 284:
  - Hypoechoic
  - Complex internal echo pattern.
- ▶ **Lymphocele**:
  - Atypical round or angular anechoic mass
  - Frequently, past history of urologic surgery
- ▶ **Tuberculosis** (see Fig. 390b; Fig. 405c, p. 282):
  - Area of parenchymal cavitation
  - Cystic renal pelvic mass (dilated calyces, clean cavities)
  - Late changes include atrophy or calcification
- ▶ **Intracystic hemorrhage** (see Fig. 392):
  - Cystic shape can still be recognized
  - Echogenic or complex internal echo pattern
  - Possible moving echoes

- ▶ **Cystic renal cell carcinoma** (cystic RCC, Fig. 393):
  - *Clinical features:* cystic component > 50% (note: never oncocytoma)
  - *Histology:* carcinoma that has undergone small-cell or papillary pseudocystic transformation
  - *Differential diagnosis:* intratumoral hemorrhage, tumor liquefaction, cyst-associated carcinoma, and intracystic hemorrhage
  - *Sonographic criteria:*
    - Round or oval masses, anechoic or hypoechoic (intratumoral hemorrhage or necrosis)
    - Tumor can still be recognized in many cases
    - Tumor occurrence in cysts is controversial.
- ▶ **Hematoma** (Fig. 394):
  - Heterogeneous hyper- or hypoechoic mass with indistinct margins
  - Anechoic or complex perirenal mass
  - Hypoechoic parenchymal area with a normal organ contour, suggesting a contusion (= hypoperfused area)
  - *CDS:* absence of color flow signals

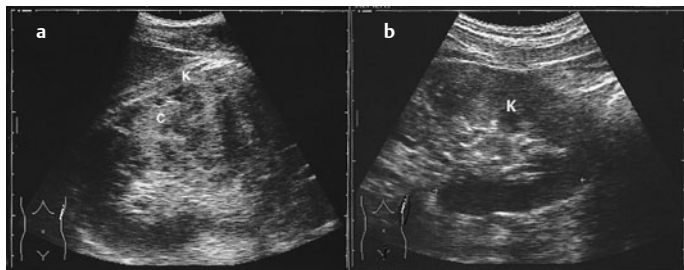
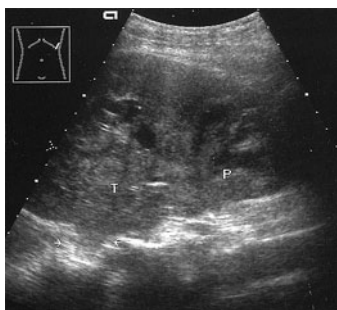


Fig. 394a, b Traumatic renal hematoma. **a** Mixed hypoechoic–hyperechoic echo pattern with a bulging contour (C) and a thin fluid rim surrounding the kidney (K). **b** Parenchymal contusion (hypoechoic to anechoic area of intraparenchymal hemorrhage, arrows). K = kidney. Patient had a history of ladder-related and riding injuries

### Hypoechoic or Isoechoic Renal Parenchymal Changes

- ▶ **Metastases** (see Fig. 416, p. 287): The primary tumor may be in the breast, bronchi, stomach, bowel, or kidney.
  - *Sonographic appearance:* Round or oval mass of low echogenicity
- ▶ **Malignant lymphoma** (Fig. 395):
  - Round or oval hypoechoic mass (low-grade lymphoma)
  - Large mass with a complex pattern of low-level internal echoes (high-grade lymphoma)

Fig. 395 High-grade non-Hodgkin lymphoma (T) of the kidney: extensive hypoechoic to complex mass with tumor nodules, also a branched anechoic pattern signifying pyelectasis (P)



► **Renal adenoma** (Fig. 396):

- Round, hypoechoic mass with smooth margins
- Complex internal echo pattern due to regressive changes
- Occasionally hyperechoic
- CDS: internal vascularity

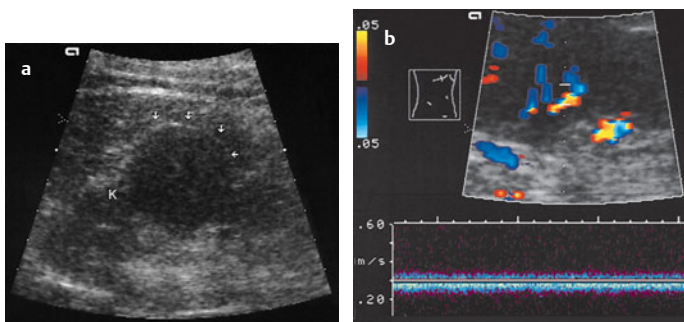


Fig. 396a, b Renal adenoma. **a** Intensely hypoechoic mass with smooth margins. The fine echogenic wall (arrows) closely resembles a hemorrhagic cyst. **b** CDS: subtle but constant vascularity excludes a cyst or abscess in favor of a solid mass

► **Abscess** (due to suppurative pyelonephritis); **carbuncle** (due to hematogenous spread of staphylococci):

- Nonhomogeneous hypoechoic mass
- Possible gas bubbles (empyematous pyelonephritis, Fig. 397)

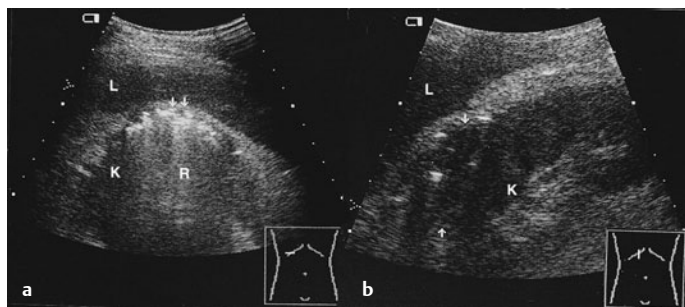


Fig. 397a, b Suppurative, empyematous pyelonephritis. **a** Extensive gas bubbles (arrows). The kidney (K) is partially obscured by reverberations (R). **b** Scan 2 weeks later shows a demarcated abscess (arrows), still accompanied by gas bubbles (young, poorly managed diabetic patient; changes resolved in response to intensive conservative therapy). L = liver

► **Oncocytoma** (adenoma): no reliable sonographic criteria

- Usually hypoechoic
- Smooth margins
- CDS: internal vascularity

### Isoechoic Changes in the Renal Parenchyma

► **Lateral bulge in the renal contour, fetal lobulation** (Fig. 398):

- Bulge in the lateral renal contour not associated with thinning of the parenchyma

► **Parenchymal bands** (parenchymatous extensions or hypertrophic renal columns): Fig. 399; see also Fig. 375a, p. 264:

- Tissue band passing from parenchyma to parenchyma through the central echo complex, often multiple
- Tumor-like parenchymal thickening (often creates a hypoechoic appearance)
- Signs of duplex kidney are common (surface notching, long narrow or enlarged kidney, duplicated renal pelvis)

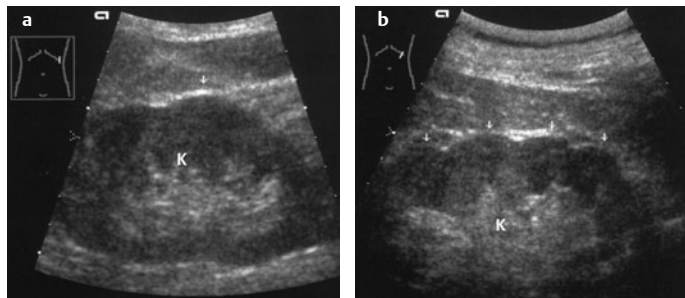


Fig. 398a, b Isoechoic bulges in the renal contour (arrows). **a** Lateral bulge, **b** Fetal lobulation. Note the concomitant thickening of the parenchymal border in the direction of the renal sinus. K = kidney

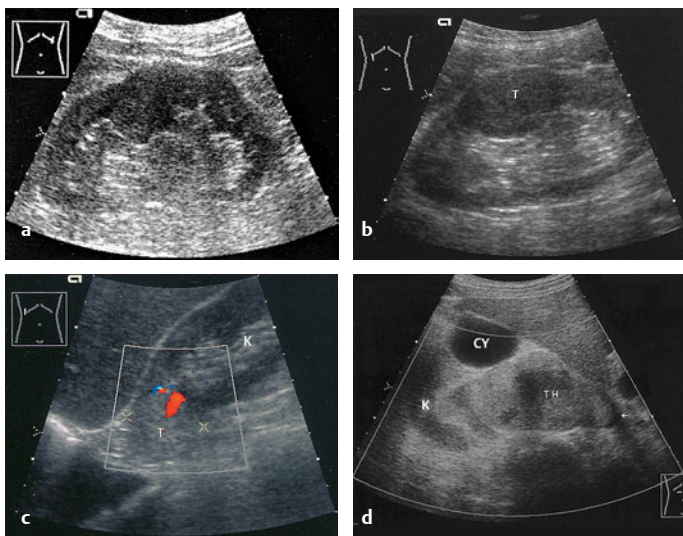


Fig. 399a–d Bulges in the renal contour. **a** In a duplex kidney. **b** Associated with renal cell carcinoma (T). The tumor appears as a largely isoechoic mass that creates a bulge in the normal parenchymal outline. **c** CDS: slight peripheral vascularity and a tumor-feeding vessel associated with an echogenic tumor (T) of the upper renal pole. **d** Advanced neoplasm, marked by a tumor thrombus (TH) in the renal vein and vena cava with minimal lateral residual flow in the vena cava (arrow). K = kidney, CY = renal cyst

- ▶ **Hematoma** (see Fig. 394a, p. 276): variable internal echo pattern ranging from hyperechoic (very fresh) to hypoechoic (clotted blood)
- ▶ **Renal cell carcinoma** (adenocarcinoma, hypernephroid carcinoma): Fig. 399a–d
  - Isoechoic, hypoechoic, or echogenic (small tumors)
  - Bulge in the renal contour
  - Occasional cystic liquefaction or calcification (20%)
  - Frequent invasion of the renal vein or vena cava
  - CDS: internal or peripheral vascularity

### Echogenic or Hyperechoic Changes in the Renal Parenchyma

- ▶ **Renal cell carcinoma (RCC; Fig. 399c)**:
  - Approximately 30% of hyperechoic tumors are RCCs
  - Echogenic tumors are usually small
  - CDS: internal or peripheral vascularity
- ▶ **Angiomyolipoma (Fig. 400)**: benign mesenchymal tumor composed of fat, muscle, and atypical vessels with thickened walls
  - Round mass with smooth margins
  - Intensely hyperechoic (“white tumor”)
  - Little or no bulge in the renal contour
  - Size: 1 cm to 3–5 cm. Rapid enlargement suggests liposarcoma

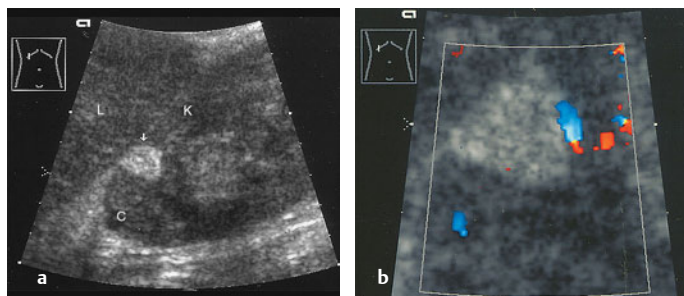


Fig. 400a, b Angiomyolipoma: echogenic tumor with smooth margins (arrow) causing an almost imperceptible bulge in the renal contour. **a** B-mode image. C = small anechoic cyst. **b** CDS: short segment of a peripheral vessel but no detectable internal vascularity

► **Note:** Tumors < 3 cm require differentiation from renal cell carcinoma.

- CDS: little if any vascularity; no more than one intratumoral vessel

► **Scars** (pyelonephritic, embolic, atherosclerotic, inflammatory; Figs. 401 and 402): often detected incidentally. The etiology of many renal scars cannot be determined.

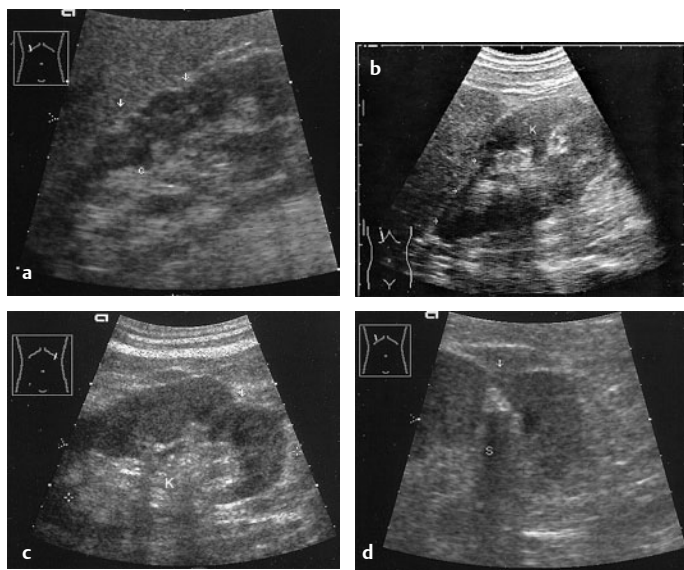


Fig. 401a–d Scar tissue in the renal parenchyma. **a** Pyelonephritic scars (arrows) with cystic calyceal ectasia (C). **b** Plaque-like scar (arrows) in the kidney (K) resulting from vascular embolism. The patient also presented clinically with cerebral infarction (both are often embolic and secondary to mitral stenosis, as in this case). **c** Atherosclerotic scar following a long history of hypertension.

280 **d** Parenchymal scar (arrow) with calcification and a distal acoustic shadow (S)

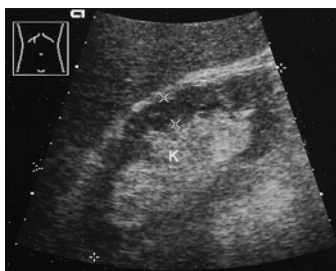

Fig. 402 Atherosclerotic surface indentations in the kidney, with areas of parenchymal thinning and rarefaction

- *Pyelonephritic*: irregular echogenic surface indentations, possible calcifications. The presence of calyceal cysts confirms the presumptive diagnosis.
- *Embolic*: frequently triangular in shape. Other lesions may appear as plaque-like indentations or an area of parenchymal thinning.
- *Atherosclerotic*: wavy surface with foci of parenchymal thinning between the “bulges” (normal tissue)
- *Mild form*: echogenic periphery of the medullary pyramids

► **Renal infarction** (Fig. 403):

- *Acute*: wedge-shaped area of increased echogenicity
- *CDS*: avascular segment
- *Chronic*: scar

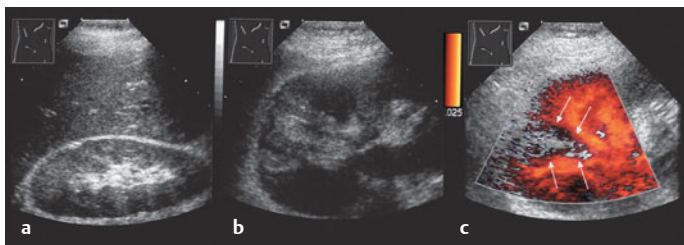


Fig. 403a–c Fresh renal infarction. **a** Scan shows increased echogenicity at the upper pole of the right kidney. **b** Magnified view. **c** CDS: the wedge-shaped avascular area (arrows) confirms the infarction

► **Medullary nephrocalcinosis** (Fig. 404): may be caused by hypercalcemia or tubular acidosis (i.e., an excess of calcium)

- *Medullary sponge kidney*: congenital malformation with patchy calcifications and cystic ectasia of the collecting ducts
  - *Radiograph*: bouquet or rosette pattern
- *Sonographic criteria*:
  - Calcification of renal parenchyma and medullary pyramids, possible kidney stones
  - Frequent secondary calcification
  - Conspicuous echogenic areas in place of the medullary pyramids
  - Possible pyelocalyceal ectasia and congestion (obstructing stone)

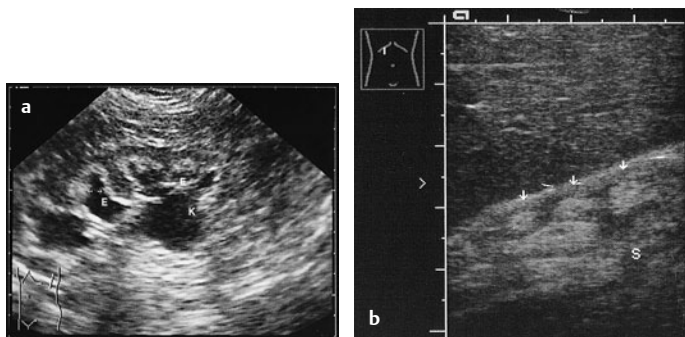


Fig. 404a, b Medullary nephrocalcinosis. **a** Cause is tubular acidosis: echogenic calcifying medullary pyramids (arrows) with obstructive pyelocalyceal ectasia (E) of the kidney (K) due to recurrent kidney stones. **b** Pronounced medullary nephrocalcinosis: small atrophic kidney with a band of residual parenchyma and hyperechoic areas, some with acoustic shadows (S) projected over the medullary pyramids (arrows)

► **Cortical nephrocalcinosis** (Fig. 405): parenchymal calcifications due to degenerative changes:

- *Small flecks of calcification*: e.g., vascular calcification in the setting of malignant hypertension or pseudoxanthoma elasticum
- *Disseminated renal calcification*: e.g., in hyperparathyroidism, tuberculosis, or renal atrophy requiring dialysis

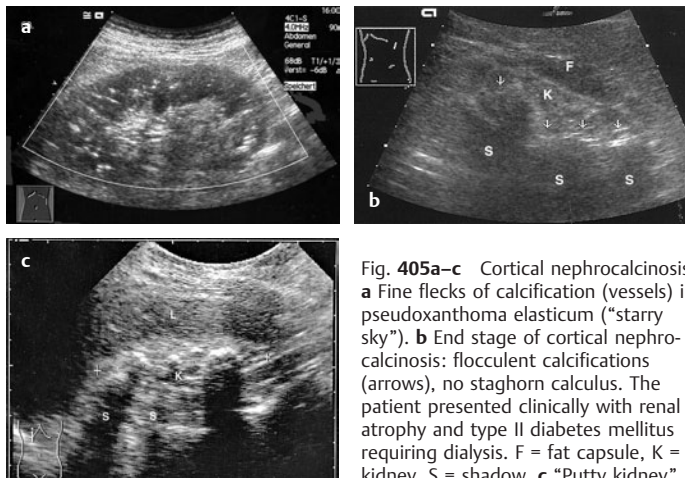


Fig. 405a–c Cortical nephrocalcinosis. **a** Fine flecks of calcification (vessels) in pseudoxanthoma elasticum (“starry sky”). **b** End stage of cortical nephrocalcinosis: flocculent calcifications (arrows), no staghorn calculus. The patient presented clinically with renal atrophy and type II diabetes mellitus requiring dialysis. F = fat capsule, K = kidney, S = shadow. **c** “Putty kidney” or “mortar kidney,” representing the end stage of renal tuberculosis: diffuse calcifications and acoustic shadows (S) (K; cursors). L = liver

- ▶ **Vascular calcification** (interlobar or arcuate arteries):
  - Echogenic tramlines
  - Absence of internal echoes
- ▶ **Parenchymal calcification** (Fig. 406; Fig. 390b, p. 274; Fig. 401d, p. 280): common; many cases have an indeterminate cause (e.g., calcified cyst or hematoma, postinflammatory, tuberculosis)

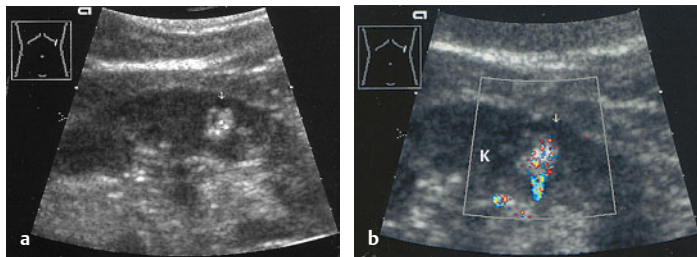


Fig. 406a, b Parenchymal calcification. **a** Hyperechoic mass in the renal parenchyma (arrow), suspicious for angiomyolipoma. **b** CDS with a high PRF: “twinkling” artifact indicates calcifications or kidney stones. K = kidney

## 10.4 Circumscribed Changes in the Renal Pelvis and Renal Sinus

### Overview (Table 49):

**Table 49** · Circumscribed changes in the renal pelvis or renal sinus

Anechoic or hypoechoic	Isoechoic or echogenic
Parapelvic cyst (solitary, multiple, p. 284)	Hemorrhagic cyst (p. 287)
Sinus lipomatosis (p. 284)	Pyelocalyceal stone (p. 288)
Parenchymal bands, hypertrophic renal columns (p. 284)	Foreign body (drainage tube, p. 288)
Infected obstruction (p. 286)	
Pyelitis (see p. 286)	
Abscess, pyonephrosis (p. 286)	
Inflammatory tumor, liquefying tumor (p. 287)	
Xanthogranulomatous pyelonephritis (p. 287)	
Carcinoma of the renal pelvis (p. 287)	
Renal cell carcinoma, metastasis (p. 287)	

### Anechoic or Hypoechoic Changes in the Renal Sinus or Renal Pelvis

- ▶ **Solitary parapelvic cysts** (see Fig. 388c, p. 273; Fig. 389a, p. 273):
  - *Clinical features:* may be tubular retention cysts (such as cortical and subcapsular cysts) or may have a lymphoid origin, arising from the lymphatic vessels of the renal sinus
  - *Sonographic criteria:* The standard criteria for cysts are reviewed on p. 272. A cyst with an inherently flat shape may show internal echogenicity or irregular margins due to physical artifacts such as noise. A flattened oval shape is particularly common with multiple cysts.
- ▶ **Multiple parapelvic cysts** (Fig. 407; Fig. 388d, p. 273): usually bilateral, taking the form of “benign cystic lymphangioma.”
  - Several or numerous round, oval, or finger-shaped anechoic masses oriented toward the hilum
  - Cyst boundaries are well defined by septations.
  - *CDS:* absence of vascularity inside the cysts, with normal-appearing blood vessels in the septa

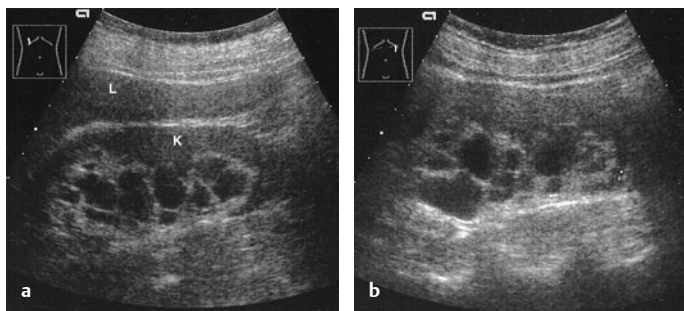


Fig. 407a, b Multiple bilateral parapelvic cysts (“benign cystic lymphangioma”): round or oval anechoic masses in the central echo complex, separated from one another by septa. L = liver, K = kidney

- ▶ **Atypical cyst** (Fig. 408; see Fig. 392, p. 275; Fig. 401a, p. 280): The differential diagnosis includes calyceal cyst, abscess, cavitating tumor, flat cyst, sectional view of a parenchymal band, and obstructive pyelocalyceal ectasia
  - Polygonal shape with intraluminal echoes due to noise
  - Trabeculations or septations
  - Extrarenal extension
- ▶ **Renal sinus lipomatosis** (Fig. 409): excessive fat in the renal sinus
  - Nonhomogeneous decrease of echogenicity in the central echo complex
  - Patchy, tumor-like figures (“bear claws”)
  - Widening of the renal sinus echo complex with thinning of the parenchyma (“fatty atrophy”). Parenchymal–pelvic ratio often < 1:1
- ▶ **Parenchymal bands, hypertrophic renal columns** (Fig. 410; see Fig. 399, p. 279):
  - Circumscribed, peg- or band-shaped iso- or hypoechoic area in the CEC
  - *CDS:* normal vascular architecture

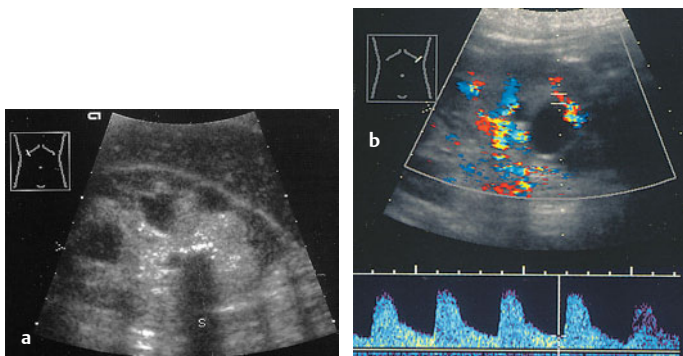


Fig. 408a, b Cystic calyceal ectasia. **a** Cystic anechoic and echogenic masses in the central echo complex. Obstructive calyceal ectasia? **b** Spectral analysis of the segmental and interlobar arteries shows a high RI of 0.76 (values  $> 0.70$  indicate an obstruction with 77–96% accuracy)

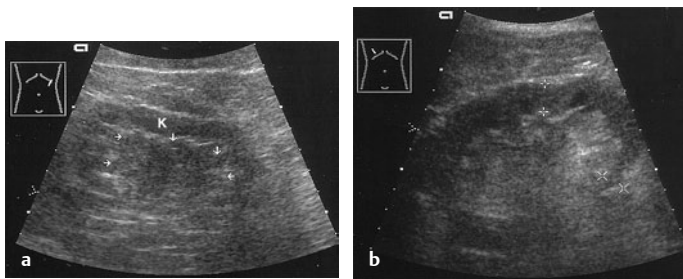


Fig. 409a, b Sinus lipomatosis. **a** Typical transformation of the central echo complex (arrows), which appears hypoechoic with irregular margins. K = kidney **b** “Fatty atrophy”: increased fat in the renal sinus with thinning of the parenchyma (cursors: parenchymal–pelvic ratio of 0.6)

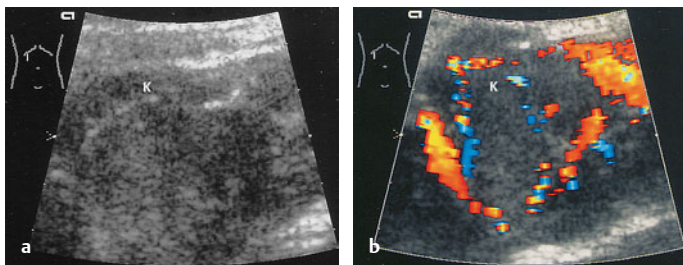


Fig. 410a, b Parenchymal bands. **a** Isoechoic mass completely occupies the renal section with slight ectopia and malrotation of the right kidney. **b** CDS: normal vascular architecture, no tumor vascularity. K = kidney

► **Infected obstruction (Fig. 411):**

▣ **Note:** The main priority is to clear the outflow obstruction as soon as possible.

- Hypoechoic dilatation of the pyelocalyceal system
- Involvement of the ureteropelvic junction

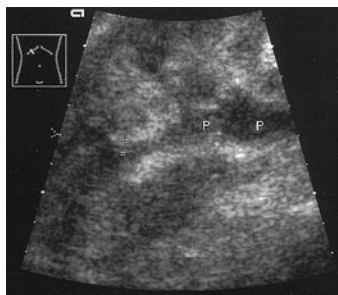

Fig. 411 Infected obstruction: very hypoechoic pyelectasis (P) with swelling of the renal pelvic wall (cursors)

► **Pyelitis (Fig. 412):**

- Inflammatory swelling of renal pelvic wall to  $> 2$  mm
- Anechoic or hypoechoic distention of the renal pelvis

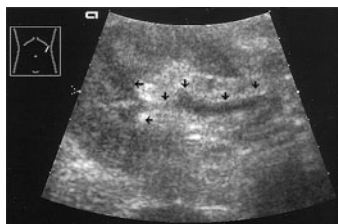


Fig. 412 Suppurative pyelitis (urosepsis): faint hypoechoic rim in the central echo complex with swelling of the renal pelvic wall (arrows)

► **Abscess or pyonephrosis (Fig. 413):** may require decompression by percutaneous needle aspiration or drainage

- Anechoic or hypoechoic mass, often multiple
- Ill-defined margins

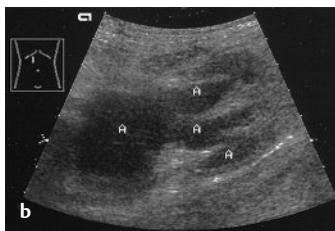
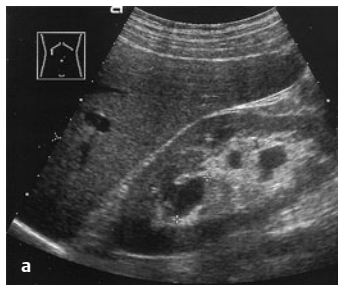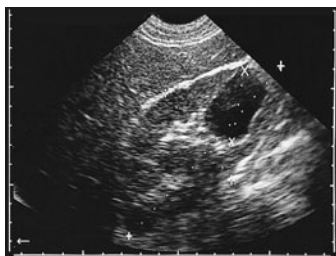


Fig. 413a, b Renal pelvic abscess and pyonephrosis. **a** Abscesses: anechoic “cystic” masses in the central echo complex. **b** Pyonephrosis: ill-defined confluent masses, some with a tapered outline

Fig. 414 Liquefaction (intratumoral hemorrhage) in a carcinoma of the renal pelvis (cursors indicate the longitudinal renal diameter and tumor diameter)



- Absence of vascularity
- Wall of renal pelvis thickened to  $> 2$  mm
- ▶ **Inflammatory mass, cavitating tumor or intratumoral hemorrhage** (Fig. 414): Other inflammatory masses may also occur, such as tumor-mimicking vasculitis.
- ▶ **Xanthogranulomatous pyelonephritis**: chronic inflammatory mass with fatty infiltration, also located in the parenchyma
  - Irregular, heterogeneous hypoechoic mass
- ▶ **Renal pelvic carcinoma** (urothelial carcinoma, Fig. 415):
  - Circumscribed hypoechoic mass, often exhibiting the same echo pattern as the renal pelvis and ureter
  - CDS: atypical vascularity (aberrant tumor vessels)
- ▶ **Renal cell carcinoma** (invading the renal pelvis and sinus), **metastasis** (Fig. 416):

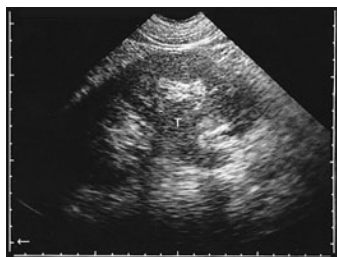

Fig. 415 Renal pelvic carcinoma (T): hypoechoic mass growing into the ureter (difficult to distinguish from an infected obstruction, see Fig. 411, p. 286)

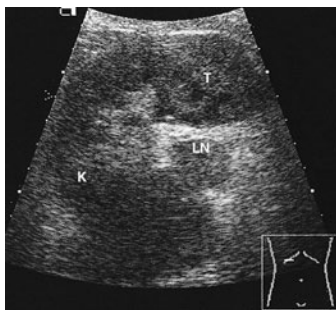

Fig. 416 Renal cell carcinoma (T) that metastasized to the lung. A metastatic lymph node (LN) is visible in the renal sinus echo complex of the same kidney (K)

### Round or oval area of decreased echogenicity in the CEC

- ▶ CDS: atypical vascularity (aberrant tumor vessels)

### Isoechoic or Echogenic Changes in the Renal Sinus or Renal Pelvis

- ▶ **Hemorrhagic cyst** (Fig. 417): mainly requires differentiation from a tumor
  - Smooth, round to oval hypoechoic area in the renal sinus echo complex
  - Fine, flocculent internal echoes

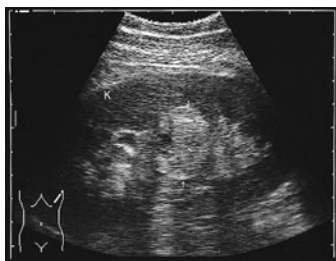

Fig. 417 Hemorrhagic parapelvic cyst (arrows) in the kidney, suspicious for metastasis from color carcinoma. FNAB: no tumor cells. CT: intracystic hemorrhage

- ▶ **Vascular calcification** (segmental branches of the renal artery, Fig. 418):
  - Echogenic streaks or bands in the renal sinus echo complex. It is common to see faint tramlines bordering a central, thread-like anechoic lumen.
  - Acoustic shadows may occur, depending on the degree of calcification.

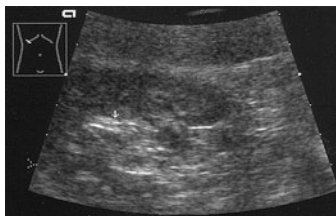

Fig. 418 Vascular calcification (arrow): echogenic "tramlines" with a central anechoic lumen

- ▶ **Renal calyceal or pelvic stone** (staghorn calculus, Fig. 419): The differential diagnosis includes vascular calcification, calcified papillary tips, and tumor-associated calcification.
  - Intense echo pattern with a distal acoustic shadow
  - Located in the calyx with hydrocalyx; in the ureteropelvic junction with an obstructed calyx or calyceal neck or with a renal pelvic obstruction
- ▶ **Drainage tube appearing as a foreign body** (see Fig. 576a), p. 388): typical double-walled linear structure with a central, anechoic fluid-filled channel.

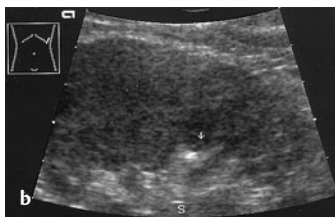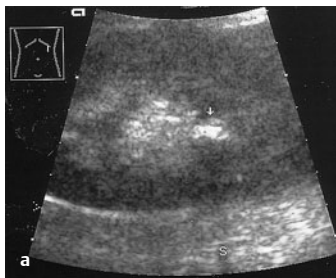


Fig. 419a, b Renal pelvic stone (nonobstructing): hyperechoic stone with a distal acoustic shadow (S; the "twinkling artifact" is helpful for confirming stones).

b Papillary tip calcification in diabetes: bright echo at the tip of the medullary

288 pyramid (arrow) with an incomplete acoustic shadow (S)

## 10.5 Evaluation and Further Testing

### Ultrasound Evaluation

- ▶ **Diffuse changes:** e.g., renal failure, undetermined renal disease. Ultrasound is usually the primary imaging modality for evaluating these cases. Generally the process can immediately be classified as interstitial, glomerular, or atrophic on the basis of sonographic findings.
- ▶ **Circumscribed changes:** These changes are often detected incidentally in routine examinations. Table 50 reviews the various changes that may be found and the confidence with which they can be identified with ultrasound.

**Table 50 · Circumscribed lesions that can be identified with ultrasound**

Can be positively identified	Can be classified, but further testing is recommended
Cysts	Lipomatosis
Kidney stone	Calcification
Renal cell carcinoma	Abscess
Angiomyolipoma	Tumor mass in the renal pelvis or renal sinus

### Further Testing

- ▶ **Indeterminate chronic renal disease:** Besides routine medical and serologic tests, special nephrologic procedures are used that include ultrasound-guided percutaneous renal biopsy.
  - The most common cause of renal failure in a general hospital setting is diabetic nephropathy.
  - ☑ **Caution:** Renal pelvic abscesses are often mistaken for cysts. This diagnosis should be considered in patients with unexplained fever and diabetes, and if necessary the lesions should be evacuated by fine-needle aspiration or retrograde drainage.
- ▶ **Indeterminate masses in the parenchyma or renal pelvis:**
  - **CDS:** Peripheral vascularity and multiple intratumoral vessels detected by contrast-enhanced duplex sonography are considered proof of a renal malignancy. The confirmation of RCC is an indication for surgery. CDS is a proven adjunct that can narrow the differential diagnosis in many other types of investigation (Fig. 420).
  - **Further tests:** FNAB or CT (for the differentiation of tumor, parenchymal band, sinus lipomatosis, and hemorrhagic cyst)

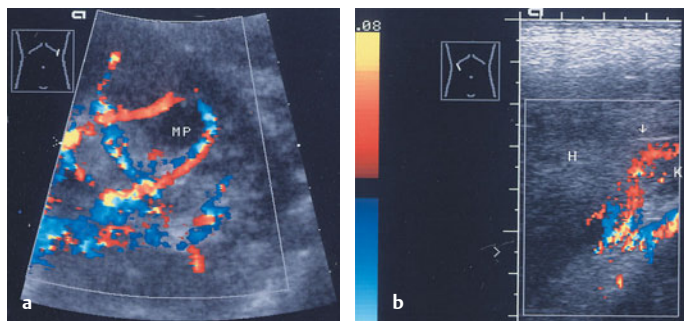


Fig. 420a, b CDS of the kidney. **a** Normal-appearing segmental and interlobar arteries alongside the medullary pyramids (MP). **b** CDS: avascular area caused by a traumatic hematoma (H), causing the displacement of other vascular structures

- ▶ **Parapelvic cysts, obstruction:** excretory urography. Peripheral vascularity and multiple intratumoral vessels detected by contrast-enhanced duplex scanning establish the diagnosis of a malignant renal tumor.
- ▶ **Suspected ectopic kidney or atrophic kidney:** excretory urography, isotope nephrography, or both
- ▶ **Small kidney and hypertension:** Suspicion of renal artery stenosis should be investigated by CDS with the determination of Doppler indices (see also Table 30, p. 193).
  - *Renal artery* (Fig. 421a, b): examine in the lateral decubitus position (more favorable angle). With stenosis:  $V_{\max} > 150$  cm/s, aliasing (see p. 8)
  - *Intrarenal parameters* (Fig. 421c, d): RI  $< 0.5$  is a significant decrease and indicates stenosis in  $> 75\%$  of cases with 95% sensitivity and 97% specificity. Accuracy is further increased by comparing the sides ( $\Delta$ RI pathologic if  $> 0.05$ ).

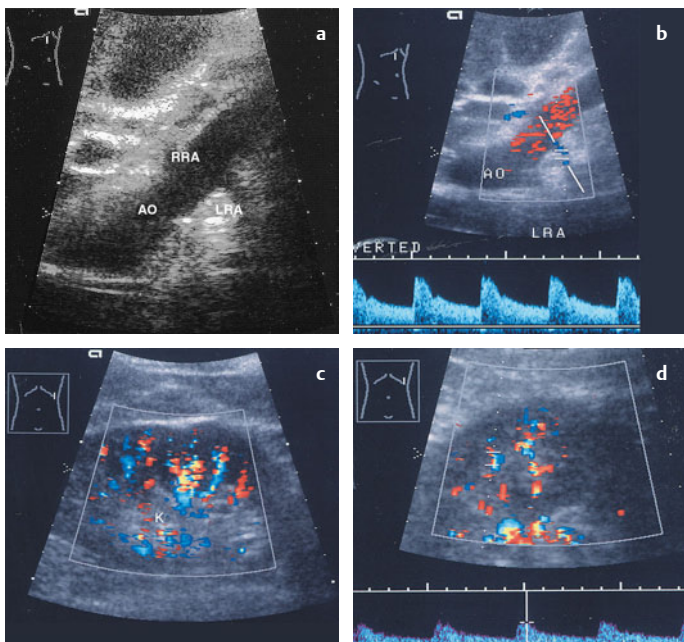


Fig. 421a–d Examination to confirm or exclude renal artery stenosis (CDS and spectral analysis). **a** Scan plane for defining the renal arteries (left oblique position, flank scan from right to left). The scan displays the right and left renal arteries (RRA, LRA) at a favorable angle for duplex sonography (“banana peel” view; AO = aorta). **b** Normal spectral analysis of the LRA. **c** Normal intrarenal vascular architecture. **d** RI determined from an interlobar artery = 0.63 (normal)

## 10.6 Perirenal Masses and Adrenal Tumors

### Perirenal Masses (Fig. 422a, b)

- ▶ **Perirenal abscess or hematoma:** complex mass. An abscess may contain gas bubbles.
- ▶ **Perirenal cyst** (Fig. 284, p. 209): anechoic mass
- ▶ **Adrenal tumors:** Hypoechoic mass:
  - Adrenal adenoma (“incidentaloma”)
  - Primary adrenal carcinoma
  - Pheochromocytoma (may also show a diffuse pattern)
  - Adrenal metastases.

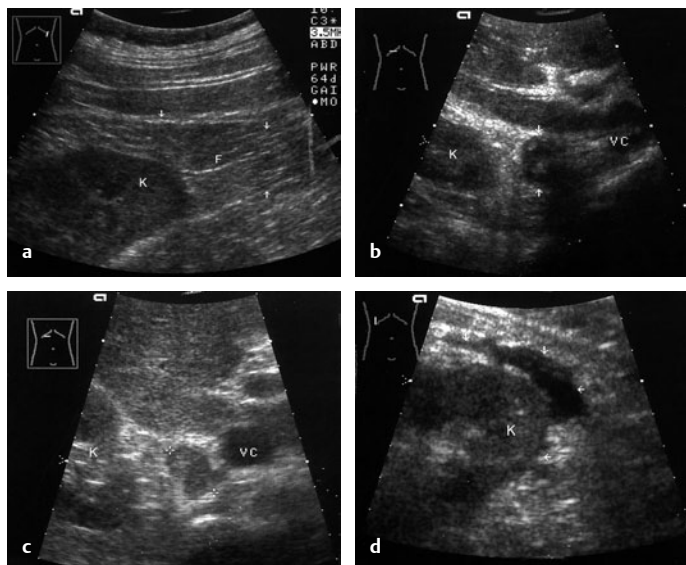


Fig. 422a–d Perirenal mass. **a** Perirenal fat (F). Arrows: Gerota fascia enclosing the perirenal fat capsule, K = kidney. **b** Incidentaloma of the right adrenal gland (arrows), detected incidentally as a complex mass. DD: pheochromocytoma, metastasis, primary carcinoma. Hormone tests were negative. **c** Adrenal metastasis from bronchial carcinoma (cursors), located between the upper pole of the kidney (K) and the vena cava (VC). **d** Perirenal fluid collection, showing a bar-shaped connection to the kidney at the pericapsular level. Differential diagnosis: abscess, hematoma, urinoma

## 11 Pancreas

### 11.1 Examination

#### Scan Planes

- ▶ Upper abdominal transverse scan (see p. 22).
- ▶ Upper abdominal longitudinal scan (see p. 29).

#### Sonographic Anatomy and Normal Findings

- ▶ **Sonographic anatomy** (Fig. 423): narrow, elongated, S-shaped organ that extends upward and to the left from the duodenal C loop to the hilum of the spleen.

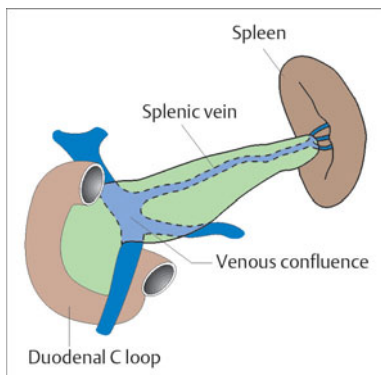


Fig. 423 Topographic anatomy of the pancreas

- ▶ **Normal findings** (Fig. 424): The normal pancreas has a homogeneous, finely granular internal echo texture. It may be isoechoic or slightly hyperechoic to the liver. The pancreas often shows increased echogenicity in elderly patients and diabetics (lipomatosis).

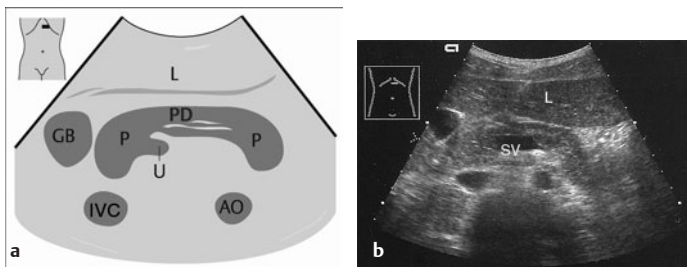


Fig. 424a, b Upper abdominal transverse scan displays the pancreas as a hypoechoic organ arching over the spinal column, aorta, and inferior vena cava and containing a double-walled echogenic duct. AO = aorta, GB = gallbladder, IVC = inferior vena cava, L = liver, P = pancreas, U = uncinate process, SV = splenic vein. PD = pancreatic duct

- ▶ **Normal dimensions:** head 25–30 mm, body < 18 mm, tail 25–30 mm, duct < 2 mm.

### Scanning Protocol

- ▶ The patient is scanned early in the morning in a fasting state.
- ▶ Upper abdominal transverse scan, placing the probe at the level of the xiphoid.
- ▶ Angle the probe to locate the celiac trunk. A key landmark is the splenic vein, which is located by angling the probe further and sliding it in the caudal direction.
- ▶ The scanning technique is adapted to the organ: The head of the pancreas is directed downward and to the right; the tail is directed upward and to the left (Fig. 425, see also Fig. 423).

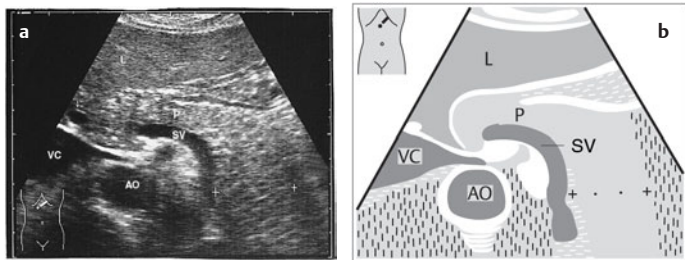


Fig. 425a, b Tail of the pancreas is demonstrated by placing the transducer obliquely and scanning upward to the left. P = pancreas, AO = aorta, SV = splenic vein (cursors mark the width of the pancreatic tail), VC = vena cava

- ▶ Transsplenic scanning is occasionally necessary to evaluate the tail region (Fig. 426).




Fig. 426a, b Transsplenic scan of the pancreatic tail. P = pancreas, S = spleen, SV = splenic vein

- ▶ The healthy pancreas is elastic and compliant, contrasting with its “en bloc” movement in chronic pancreatitis.
- ▶ **Scanning tips:**
  - Note any tenderness in response to digital or probe palpation.
  - If the pancreas is poorly visualized, the following measures may be helpful:
    - Scan during inspiration with the lower abdomen protruding (this moves the acoustic window of the liver downward and displaces bowel loops laterally downward).

- Fill the stomach with 500–1000 mL of water or tea (ingested through a straw).
- Scan at full expiration in athletic or heavy-set patients (stomach cranial to the pancreas).

## Overview and Classification of Findings

- **Note:** Pancreatic diseases appear sonographically as circumscribed or diffuse architectural changes in the organ. There may be associated focal changes in some cases.
- ▶ **Diffuse changes** (see Table 51, p. 295): Diffuse changes are seen mainly in fibrolipomatosis and in the various forms of pancreatitis (as defined in the Marseille classification of 1984):
- *Acute pancreatitis:* mild or severe course
  - *Chronic pancreatitis:* pancreatitis characterized by
    - focal necrosis,
    - segmental or diffuse fibrosis,
    - calcification or stones,
    - obstruction
- ▶ **Circumscribed changes** (see Table 52, p. 301): The findings of greatest significance are pancreatic pseudocysts and pancreatic carcinoma.

## 11.2 Diffuse Changes

### Definition and Overview

- ▶ **Definition:** Diffuse changes are characterized by a disturbance in the overall echo pattern (“echo texture”) of the organ, with associated changes in size and structure. There may also be changes in the duct system as well as circumscribed complications.
- ▶ **Overview:** See Table 51.

**Table 51 · Diffuse changes in the pancreas**

Hypoechoic	Hyperechoic	Small pancreas	Large pancreas
Acute pancreatitis (p. 295)	Lipomatosis (p. 297)	Age-related changes (p. 298)	Annular pancreas (p. 298)
Early chronic pancreatitis (p. 296)	Pancreatic fibrosis (p. 297)	Pancreatic atrophy (p. 298)	Acute pancreatitis (p. 298)
	Chronic pancreatitis (p. 297)		Tumor infiltration (p. 298)

### Hypoechoic Changes

- ▶ **Acute pancreatitis** (Fig. 427, see also Figs. 87–89, p. 66):
- Enlarged pancreas
  - Hazy, hypoechoic organ structure
  - Circumscribed anechoic (rarely hyperechoic) lesions representing necrotic or hemorrhagic areas

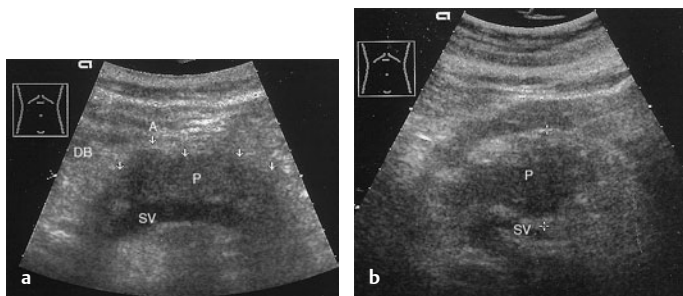


Fig. 427a, b Hypoechoic pancreas. **a** Mild, acute pancreatitis (P): slightly enlarged pancreas with a very hypoechoic structure. The slightly wavy structure is typical of the resolution phase. A = gastric antrum, DB = duodenal bulb, SV = splenic vein. **b** Normal pancreas of a 21-year-old woman (P, cursors show a normal size). Note that the pancreas is less echogenic than the liver. VC = vena cava, AO = aorta, GB = gallbladder, MS = mesenteric artery

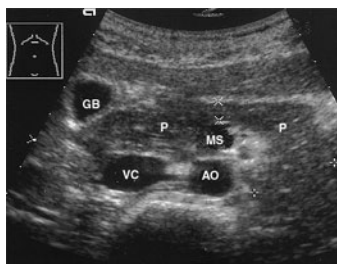


Fig. 428 Severe pancreatitis: pancreas also contains anechoic masses (necrotic and hemorrhagic areas). The antero-posterior diameter (cursors) is increased to 43 mm. S = anteriorly displaced stomach

- Possible ductal dilatation (biliary?)
- *Associated signs*: peripancreatic fluid, ascites, left-sided pleural effusion
- *Complications*: abscess formation along pathways of inflammatory spread (mesenteric, pararenal, subphrenic, see p. 72); pseudocysts (p. 302)

► **Early form of chronic pancreatitis** (Fig. 429):

- Decreased echogenicity in a normal-sized pancreas
- Irregular borders
- Possible undulation and dilatation of the pancreatic duct

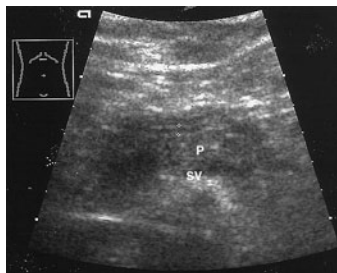


Fig. 429 Early form of chronic pancreatitis (P): hypoechoic structure with irregular borders. The pancreatic duct is wavy and slightly dilated at 3.2 mm (cursors). SV = splenic vein

## Hyperechoic Changes

- ▶ **Lipomatosis** (Fig. 430): occurs in older patients, especially elderly diabetics
  - Increased echogenicity
  - Usually normal size
  - No significant induration

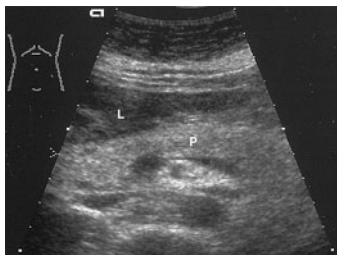


Fig. 430 Pancreatic lipomatosis. The pancreas (P) is more echogenic than the liver (L)

- ▶ **Pancreatic fibrosis** (Fig. 431): may occur in chronic pancreatitis, cystic fibrosis, and primary siderophilia (iron storage disease, “bronze diabetes”)
  - Increased echogenicity
  - Indurated organ
  - Usually normal size

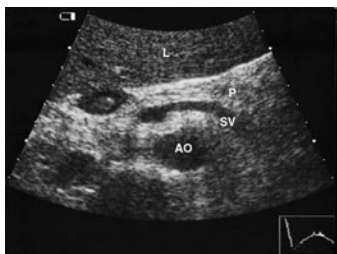

Fig. 431 Pancreatic fibrosis (P) in a patient with hemochromatosis (“bronze diabetes”): hyperechoic structure with incipient atrophy. L = liver, SV = splenic vein, AO = aorta

- ▶ **Chronic pancreatitis** (Fig. 432):
  - Irregular hyperechoic structure (fibrosis after acute inflammatory episodes)
  - Irregular borders

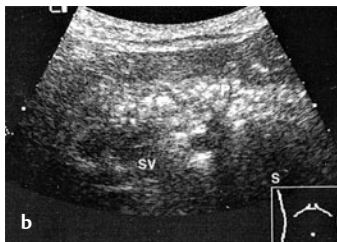
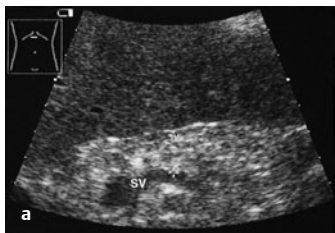


Fig. 432a, b Chronic pancreatitis. **a** Pancreatic fibrosis in a patient with chronic alcohol-related pancreatitis. The pancreas (cursors) is poorly delineated and shows a coarse echogenic structure. **b** The above changes plus calcifications with acoustic shadows (S) that obscure the deeper vascular landmarks. SV = splenic vein

- Usually normal size
- Possible micro- and macrocysts, calcifications (note acoustic shadows), ductectasia

### Small Pancreas

- ▶ **Age-related changes** (Fig. 433a): small pancreas that may show decreased, normal, or increased echogenicity
- ▶ **Pancreatic atrophy** (Fig. 433b)
- ▶ **Surgical resection or old pancreatic necrosis**

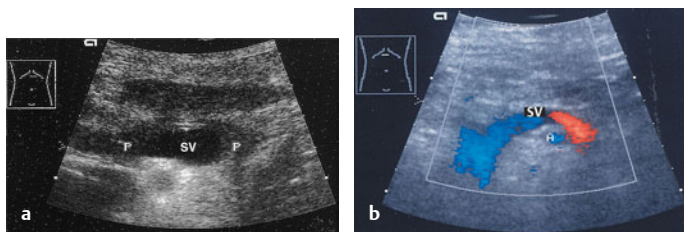


Fig. 433a, b Small pancreas, pancreatic atrophy. **a** Small, hypoechoic pancreas (P) in an elderly cachexic woman. The organ is barely detectable but contains a normal-sized duct (cursors). **b** Autoimmune chronic pancreatitis: complete atrophy with no discernible pancreas. The patient presented clinically with diabetes and maldigestion. SV = splenic vein. A = mesenteric artery

### Large Pancreas

- ▶ **Annular pancreas** (Fig. 434a): enlargement due to extension around the duodenum
- ▶ **Acute pancreatitis or an acute exacerbation of chronic pancreatitis** (Fig. 427 and p. 296)
- ▶ **Tumor infiltration** (Fig. 434b)

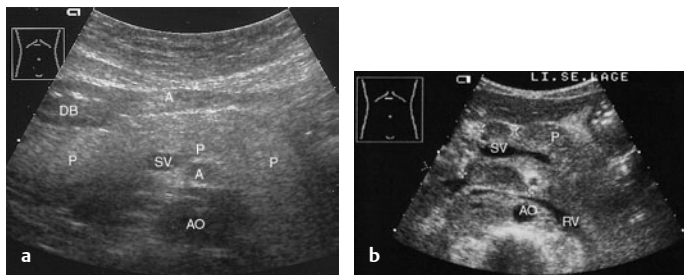


Fig. 434a, b Large pancreas. **a** Annular pancreas (P). A = antrum of stomach, AO = aorta, DB = duodenal bulb, SV = splenic vein. **b** Matted intra- and peripancreatic lymph nodes (cursors) causing enlargement of the pancreas (P) anterior and posterior to the splenic vein (SV). AO = aorta, RV = renal vein

## Possible Errors of Interpretation

- ▶ **Ductectasia** (Fig. 435a): A greatly enlarged pancreatic duct can mimic a hypoechoic pancreas.
- ▶ **Fluid-filled duodenum** (Fig. 435b): The horizontal part of the duodenum between the aorta and the superior mesenteric artery may be mistaken for a diffuse hypoechoic change in the pancreas.

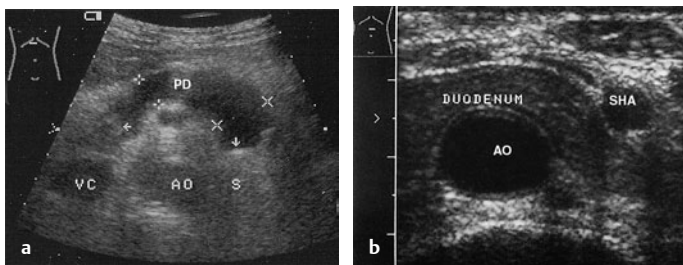


Fig. 435a, b Ductectasia mimicking a hypoechoic pancreas. **a** Massive dilatation of the pancreatic duct (PD, cursors), which is hypoechoic due to sedimentation. Arrows: duct stones, some with distal acoustic shadows (S). AO = aorta, VC = vena cava. **b** The horizontal limb of the duodenum passes between the aorta (AO) and superior mesenteric artery (SMA). In the lateral longitudinal scan, the duodenojejunal flexure is lateral to the pancreatic tail and anterior to the inferior mesenteric vein

### ▶ Differentiating fibrosis from lipomatosis:

- *Fibrosis*: coarser echo pattern with induration (digital palpation with indicate this)
- *Lipomatosis*: finer, homogeneous echo pattern with no significant induration

## Further Testing

### ▶ In acute pancreatitis:

- *Clinical findings*: acute, deep upper abdominal pain
- *Laboratory findings*: elevated amylase/lipase
- *CT*: routine initial study, may also be used for follow-up (better for differentiating edema, hemorrhage, and necrosis)
- *Early ERCP*: in cases with a suspected biliary etiology (sonographic investigation of the gallbladder and the prepapillary bile duct)

### ▶ In chronic pancreatitis:

- *Definition*: more than three episodes of acute inflammation
- *Sonographic and clinical findings*:
  - Ultrasound in early cases may demonstrate no abnormalities or at most may show irregular borders, duct irregularities, and “en bloc” movement of the pancreas. Induration (fibrosis) may be noted on digital palpation. Functionally, there are still no clinically overt deficits (ERP; see Fig. 436).
  - Advanced cases of chronic pancreatitis are usually marked by recurring bouts of upper abdominal pain (alcohol history?), secondary pancreatogenic diabetes mellitus, weight loss, and a fatty stool.

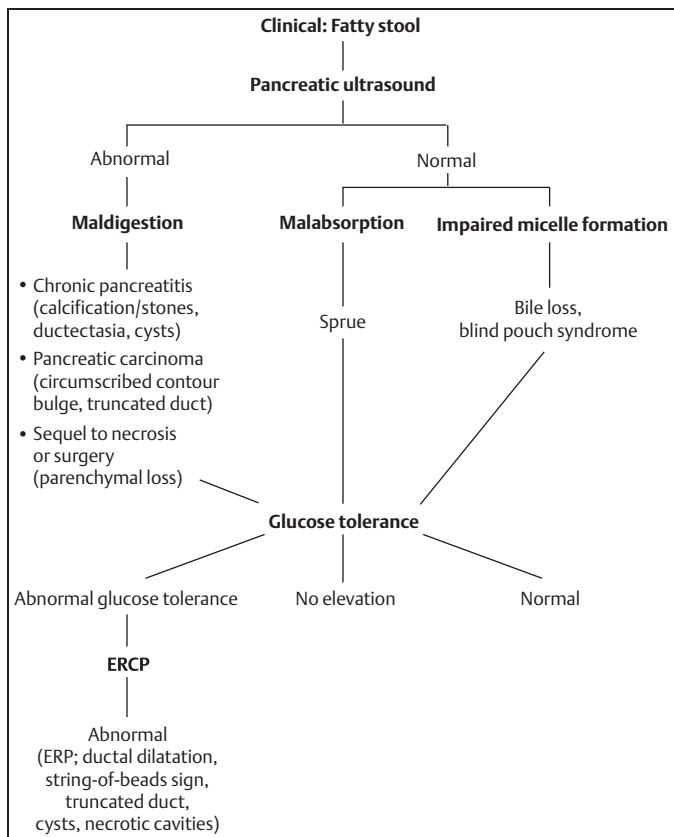


Fig. 436 Role of sonography in the workup of malassimilation (cardinal symptoms: weight loss and fatty stool)

- *24 hour test for stool fat*: well above 7 g of fat, stool weight > 150 g
- *Glucose tolerance test to differentiate from malabsorption in sprue*:
  - *Elevated 1 h and 2 h values*: favors pancreatogenic fatty stool. (The secretin-pancreozymin stimulation test is the most sensitive test but is too complicated for routine use; elastase in the stool is too imprecise, with a positive predictive value of only 50–60%.)
  - **Note**: Absence of blood glucose elevation is suggestive of malabsorption.
- *CT*: Sensitivity is poor in early forms. In more advanced forms, diagnostic accuracy is 100% based on the criteria of fibrosis, calcification, ductectasia, and cysts
- *ERCP*: duct irregularities.

## 11.3 Circumscribed Changes

### Overview (Table 52):

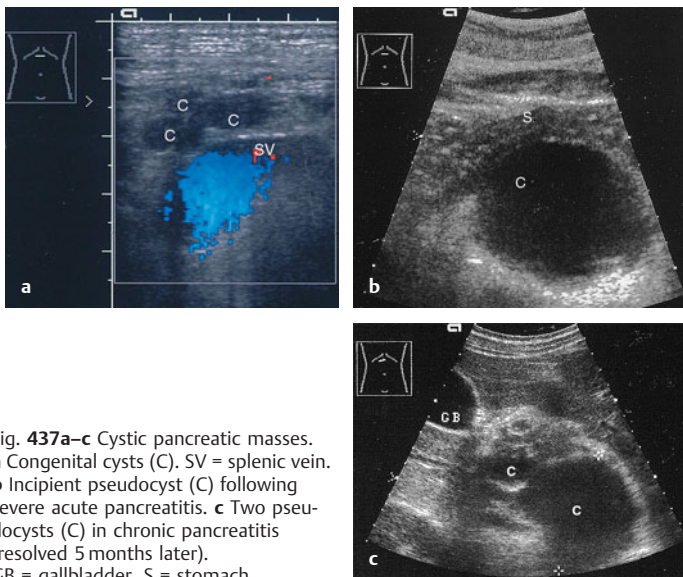
**Table 52** · Circumscribed changes in the pancreas

Anechoic	Hypo- or isoechoic	Hyperechoic
Cysts (congenital, pseudo-cysts, parasitic cysts)	Pancreas divisum (p. 303)	Duct stones, calcifications (p. 305)
Cystic neoplasia (p. 302)	Focal pancreatitis (p. 304)	Protein plug or foreign body (p. 306)
Pancreatitis of the head or tail (see p. 303)	Pancreatic carcinoma (p. 304)	Focal chronic pancreatitis (p. 306)
	Neuroendocrine tumor (p. 305)	Calcified or debris-filled pseudocyst (p. 307)
	Metastasis, lymphadenopathy (p. 305)	Hemangioma (p. 307)
		Vascular calcification (p. 307)

### Anechoic Changes

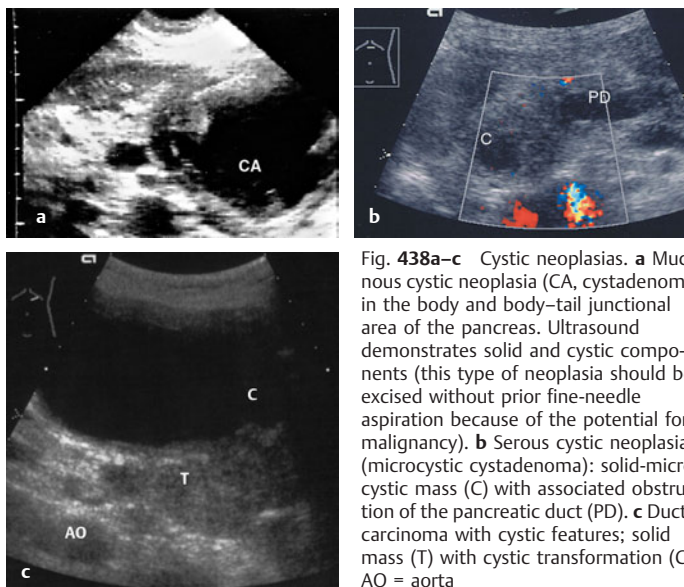
► **Congenital cysts** (Fig. 437a):

- Anechoic
- Smooth margins



**Fig. 437a–c** Cystic pancreatic masses. **a** Congenital cysts (C). SV = splenic vein. **b** Incipient pseudocyst (C) following severe acute pancreatitis. **c** Two pseudocysts (C) in chronic pancreatitis (resolved 5 months later). GB = gallbladder, S = stomach

- Frequently combined with renal and hepatic cysts
- No evidence of pancreatitis
- ▶ **Necrosis, pseudocyst, or parasitic cyst in acute pancreatitis** (Fig. 437b):
  - Irregular margins
  - Internal echo pattern is usually complex (necrosis, hemorrhage, infection)
  - Echogenic inflammatory wall (pseudocyst)
  - *Aspirate*: turbid, greenish, bloody, purulent
- ▶ **Cyst in chronic pancreatitis** (Fig. 437c):
  - Smooth margins
  - Anechoic
  - Size 2–4 (up to 17) cm
  - *Aspirate*: sterile, hypocellular, enzyme-rich
- ▶ **Parasitic cyst**: solitary lesion or rosette-like pattern, echogenic wall
- ▶ **Cystic neoplasias** (after Klöppel):
  - *Ductal adenocarcinoma with cystic features*: solid or cystic tumor mass
  - *Intraductal papillary mucinous neoplasia*: periductal cystic mass in the head of the pancreas
  - *Mucinous cystic neoplasia* (cystadenoma, see Fig. 438a): mixed solid-cystic mass in the body of the pancreas. Occurs predominantly in middle-aged women
  - *Serous cystic neoplasia* (microcystic cystadenoma, see Fig. 438b): solid-microcystic mass with prestenotic ductal dilatation. Benign neoplasia that occurs exclusively in elderly women
  - Solid pseudopapillary neoplasia
  - *Unusual cystic neoplasias*: cystic mass



**Fig. 438a–c** Cystic neoplasias. **a** Mucinous cystic neoplasia (CA, cystadenoma) in the body and body–tail junctional area of the pancreas. Ultrasound demonstrates solid and cystic components (this type of neoplasia should be excised without prior fine-needle aspiration because of the potential for malignancy). **b** Serous cystic neoplasia (microcystic cystadenoma): solid-microcystic mass (C) with associated obstruction of the pancreatic duct (PD). **c** Ductal carcinoma with cystic features; solid mass (T) with cystic transformation (C). AO = aorta

► **Pancreatitis of the head or tail of the pancreas:**

- *Mild pancreatitis:*
  - Hypochoic tumor-like swelling (tender to pressure)
  - Resolves after acute symptoms have subsided
- *Severe pancreatitis* (Fig. 439): swelling, plus
  - intrapancreatic fluid, necrosis, or hemorrhage
  - peripancreatic fluid (directly bordering the pancreas or in the splenic hilum)

⚠ **Caution:** Fokal pancreatitis in elderly patients may often caused by a ductal carcinoma!

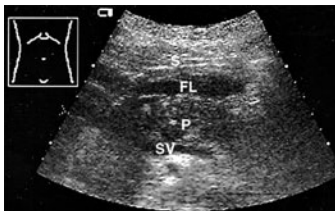


Fig. 439 Acute necrotizing pancreatitis: edematous swelling of the pancreas (P) with peripancreatic fluid (FL). S = stomach, SV = splenic vein

### Hypochoic and Isochoic Changes

► **Pancreas divisum** (Fig. 440):

- Isochoic enlargement of the pancreatic head
- Visualization of two duct systems (rudimentary pancreatic duct and accessory pancreatic duct)

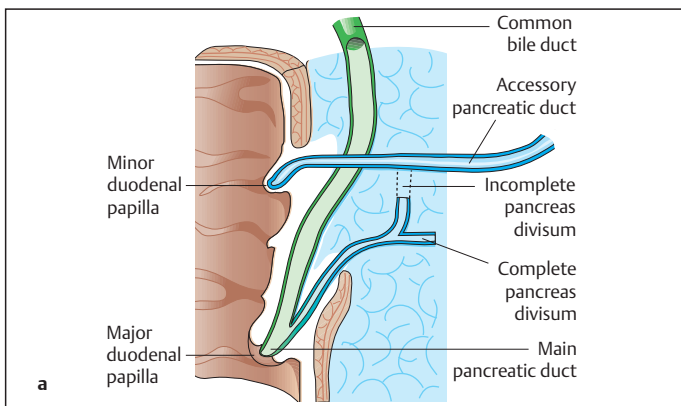
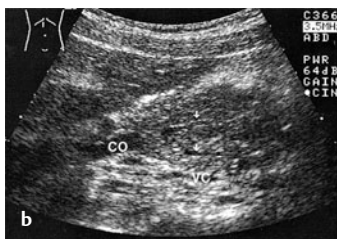

Fig. 440a, b Pancreas divisum.

**a** Schematic representation of a complete and incomplete pancreas divisum.  
**b** Pancreas divisum with typical enlargement of the pancreatic head and two definable ducts (arrows). CO = venous confluence, VC = vena cava



- ▶ **Focal pancreatitis** (Fig. 441): enlarged, circumscribed, hypoechoic to complex area of pancreatic change

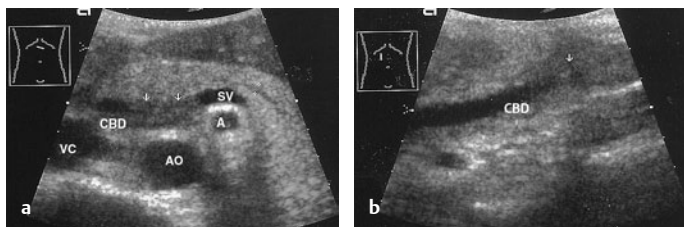


Fig. 441a, b “Groove pancreatitis”: acute focal pancreatitis of the pancreatic head (uncinate process, arrows) with stenosis of the bile duct. **a** Upper abdominal oblique scan. **b** Upper abdominal longitudinal scan. A = mesenteric artery, Arrow: duct stone, AO = aorta, CBD = common bile duct, surrounding hypoechoic inflammation (cholangitis), VC = vena cava, SV = splenic vein

- ▶ **Pancreatic carcinoma** (Figs. 442 and 443):
  - Scalloped margins, bulge in pancreatic contour
  - Uniformly isoechoic or hypoechoic lesion with fine peripheral extensions (spiculations)
  - Prestenotic enlargement of the pancreas
  - Signs of infiltration or displacement (splenic vein, celiac trunk)
  - CDS: no vascularity on unenhanced scans

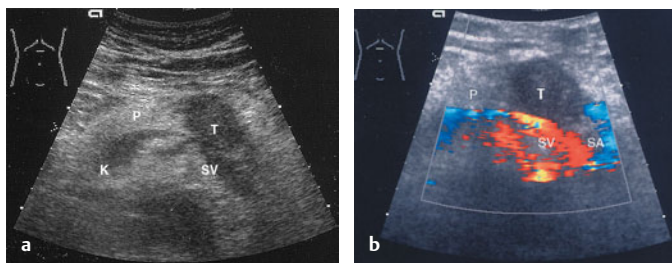


Fig. 442a, b Pancreatic carcinoma (deemed operable by ultrasound and CT, but found to be inoperable at surgery). **a** Hypoechoic tumor (T) in an echogenic lipomatotic pancreas (P). K = veinous confluence **b** CDS shows no tumor vascularity. SA = splenic artery, SV = splenic vein

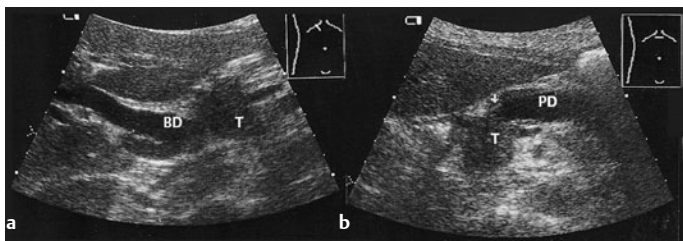


Fig. 443a, b Carcinoma of the pancreatic head (T): hypoechoic mass with fine extensions. **a** Compression and obstruction of the bile duct (BD). **b** Abrupt cutoff (arrow) of the pancreatic duct (PD) with prestenotic dilatation

► **Neuroendocrine tumor** (Fig. 444a):

► **Note:** Most insulinomas are detectable only by endosonography, intraoperative bimanual palpation, or intraoperative ultrasound.

- Circumscribed round or oval mass with smooth margins
- No duct obstruction
- CDS: vascularity

► **Metastasis, lymphadenopathy** (Fig. 444b)

- *Metastasis:* round hypoechoic mass with smooth margins
- *Lymphadenopathy:* bulky round or oval mass
- *Nodal metastasis:* hypoechoic or isoechoic

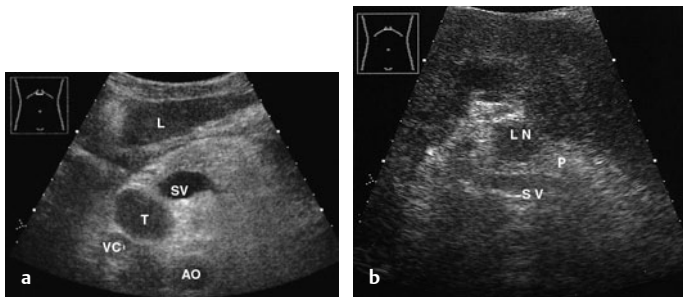


Fig. 444a, b Sharply circumscribed, hypoechoic pancreatic masses. **a** Metastatic neuroendocrine tumor of the pancreatic head (T). **b** Metastatic carcinoma (LN) in the pancreas (P). AO = aorta, L = liver, SV = splenic vein, VC = vena cava

## Hyperechoic Changes

► **Pancreatic duct stones, calcifications** (Fig. 445):

- Solitary or string-of-beads foci of very high echogenicity in the pancreatic duct, with associated acoustic shadows (and twinkling artifact)
- Possible ductal dilatation
- Isolated, intensely echogenic, circumscribed areas with or without definable acoustic shadows

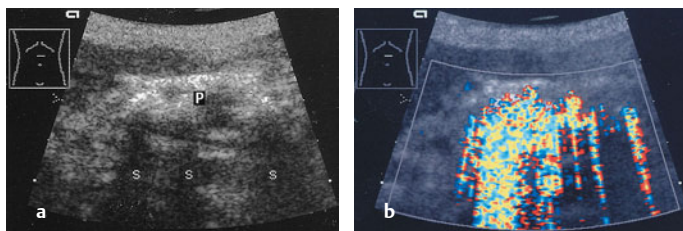


Fig. 445a, b Pancreatic duct stones and calcifications. **a** B-mode image: echogenic areas in the pancreas (P) with distal acoustic shadows (S) obscuring the usual landmarks. **b** CDS: twinkling and confetti artifacts caused by strong reflectors in the shadowed region

► **Protein plug, foreign body, air** (Figs. 446, 447):

- Hyperechoic, intensely echogenic structures in the expanded pancreatic duct
- Air in the pancreatic duct (after papillotomy) appears as mobile, echogenic gas bubbles

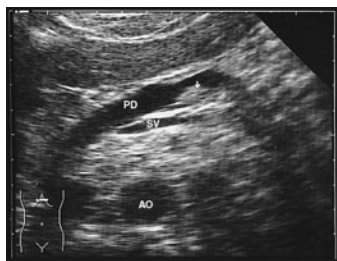

Fig. 446 Protein plug (arrow) in the dilated, unobstructed pancreatic duct (PD) in a setting of chronic autoimmune pancreatitis. SV = splenic vein, AO = aorta

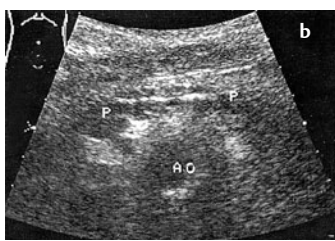
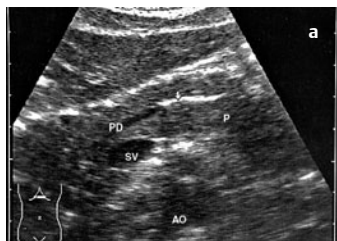
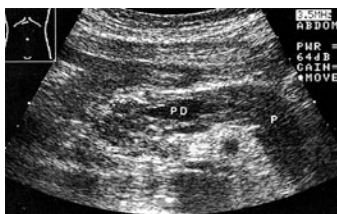Fig. 447a, b Echogenic structures in the pancreatic duct. **a** Stent (arrow) inserted for recurrent bouts of pancreatitis in a pancreas divisum. **b** Air in the pancreatic duct (arrow) secondary to a biliary-enteric fistula with a common duct orifice. AO = aorta, PD = pancreatic duct, SV = splenic vein, P = pancreas

► **Focal chronic pancreatitis** (Fig. 448):

- Circumscribed echogenic or heterogeneous area showing an altered or coarsened echo pattern
- Possible cysts and calcification

Fig. 448 Segmental chronic pancreatitis of the pancreatic head (cursors). P = normal-appearing tail, PD = segmental dilatation of the pancreatic duct



- ▶ **Calcified pseudocyst or a pseudocyst filled with pus or debris** (Fig. 449):
  - Round, oval or irregular mass with bizarre hypoechoic or hyperechoic components
  - Calcified wall appears echogenic and casts a distal acoustic shadow
- ▶ **Hemangioma**: round hyperechoic mass
- ▶ **Vascular calcification** (Fig 450; Fig. 471, p. 319): straight or curved linear echoes with acoustic shadows, distributed along the course of the splenic artery

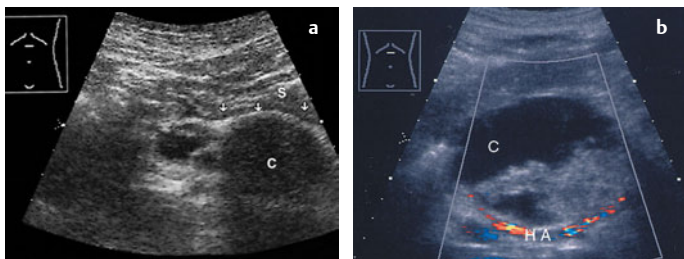
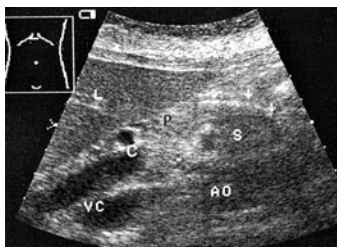


Fig. 449a–c Causes of heterogeneous increased echogenicity in the pancreas. **a** Peripheral calcification (arrows) of a pancreatic pseudocyst (C). Cystic structure appears hypoechoic (not anechoic) due to superimposed partial acoustic shadowing. S = indented stomach. **b** Pseudocyst (C) with a complex echo pattern, displacing the hepatic artery (HA). **c** Large debris-laden pseudocyst with a combination of anechoic and echogenic contents

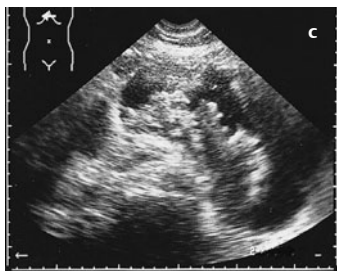

Fig. 450 Calcifications (arrows) with acoustic shadows (S) in the splenic artery. P = pancreatic head, AO = aorta, VC = vena cava, L = liver, C = venous confluence



## Pancreas Possible Errors of Interpretation

- ▶ **Mimics of a pseudocyst or necrosis** (Fig. 451):
  - Splenic artery that runs a tortuous course through the head and tail of the pancreas
  - Prepapillary common bile duct
- ▶ **Mimics of the splenic vein** (Fig. 446, p. 306):
  - Pancreatic duct that is dilated or distorted as a result of scarring
  - Irregular pseudocysts
- ▶ **Mimics of pancreatic carcinoma** (Figs. 452 and 453; see also Fig. 442, p. 304):
  - Atypical cyst (with intracystic hemorrhage, debris, or calcification; see Fig. 449, p. 307)
  - Malignant lymphoma or metastasis (Fig. 452b)
  - Cystadenoma, adenoma (see Fig. 438, p. 302)
  - Focal pancreatitis (Fig. 452a)
  - Fluid-filled duodenojejunal flexure (Fig. 453)

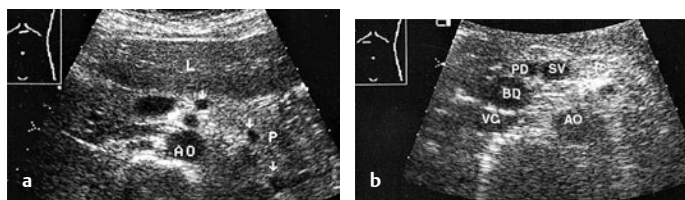


Fig. 451a, b Mimics of a pseudocyst or necrosis. **a** Multiple cross-sections through the splenic artery (arrows). **b** Dilatation of the pancreatic duct (PD) and common bile duct (BD) secondary to a small prepapillary carcinoma of the pancreatic duct. P = pancreas, L = liver, AO = aorta, VC = vena cava, SV = splenic vein

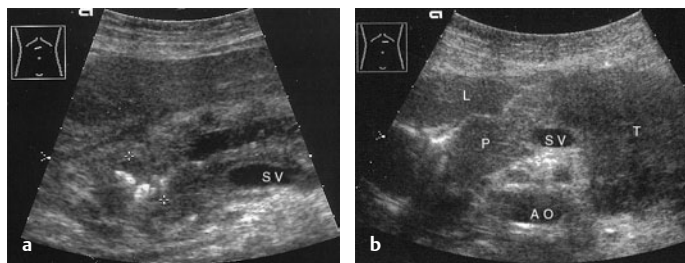


Fig. 452a, b Mimics of pancreatic carcinoma. **a** Hypoechoic swelling of the pancreatic head, calcifications (cursors), dilatation and cutoff of the pancreatic duct (carcinoma in chronic pancreatitis?): acute exacerbation of chronic pancreatitis. **b** Hypoechoic tumor (T) in the body and tail of the pancreas: high-grade non-Hodgkin lymphoma. AO = aorta, L = liver, P = pancreas, SV = splenic vein

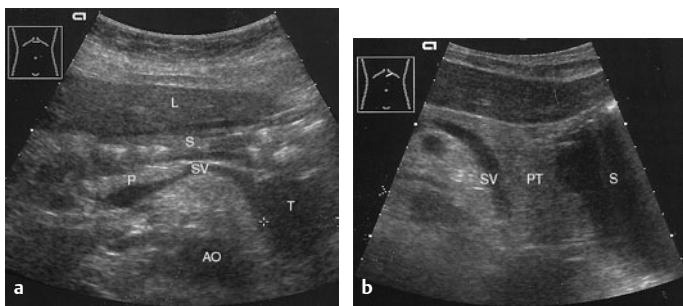


Fig. 453a, b Finding mimicking a tumor in the tail of the pancreas (T, cursor), CT diagnosis. **a** Initial ultrasound scan shows a hypoechoic mass. **b** Fluid filling and serial ultrasound: Intermittent normal appearance of the pancreatic tail (PT) excludes a tumor and identifies the finding as transient fluid filling of the duodenojejunal flexure. AO = aorta, L = liver, S = stomach, SV = splenic vein

### Differential Diagnosis of a Dilated Pancreatic Duct

- ▶ **Postprandial dilatation** (Fig. 454a)
- ▶ **Pancreas divisum** (Fig. 454b):
  - Cutoff or stenosis of the pancreatic duct with no visible obstruction
  - Detection of two ducts in the pancreatic head
  - Enlargement of the pancreatic head
- ▶ **Chronic pancreatitis** (Fig. 454c):
  - Undulating course of the duct
  - Calcifications, duct stones
  - Obstructive duct stone
- ▶ **Pancreatic tumor:**
  - Tumor mass with prestenotic ductectasia
  - No duct tortuosity
  - No duct stones
- ▶ **Autoimmune chronic pancreatitis:**
  - Circumscribed enlargement of the pancreas
  - Glandular atrophy
  - No evidence of an obstruction
- ▶ **Misinterpretation:** The hepatic artery may be misidentified as a dilated pancreatic duct (Fig. 454d).

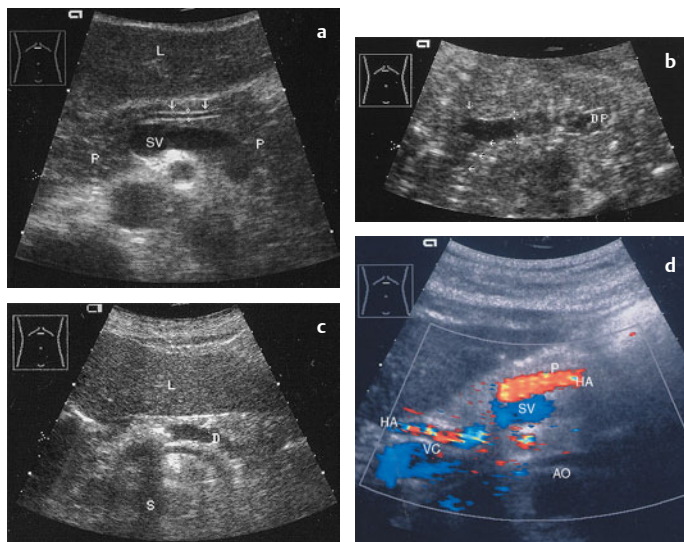


Fig. 454a–d Differential diagnosis of a dilated pancreatic duct. **a** Postprandial dilatation (arrows). **b** Pancreas divisum: cutoff of the duct (arrows) at its junction with a narrow accessory pancreatic duct. The main duct (arrow) is incompletely formed. **c** Chronic pancreatitis with an obstructing duct stone and distal acoustic shadow (S). **d** Splenic artery (SA), which can mimic a dilated duct in the B-mode image. L = liver, SV = splenic vein, HA = hepatic artery, P = pancreas, DP, D = pancreatic duct, VC = vena cava, AO = aorta

### Further Testing

#### ► In patients with suspected acute pancreatitis:

- **CT:** If findings are equivocal (calcified cyst; internal densities due to clotting, debris, or pus; suspected tumor), CT angiography should be used to differentiate between viable and nonviable tissue.
- **Fine-needle aspiration:** of necrosis or hemorrhage for cytology and bacteriology, for enzyme assays, and for the treatment of complicated cysts. In cases with intra- and peripancreatic fluids (the most severe form of pancreatitis), sites distant from the pancreas (omental bursa, hepatorenal and splenorenal recess, cul-de-sac, mesentery) should also be sampled.

#### ► In patients with suspected chronic pancreatitis: Chronic pancreatitis with duct stones or calcifications is difficult to diagnose with ultrasound, but it can be accurately diagnosed by a highly experienced sonographer. The only pitfall is coexisting carcinoma (in approximately 1–5% of cases). Cases with persistent pain should undergo operative treatment (a tumor in chronic pancreatitis often cannot be detected by ultrasound, CT, or even at operation).

- **CT:** indicated if ultrasound findings are equivocal (even with an experienced sonographer) or if a tumor is suspected
- **Fine-needle aspiration:** usually unrewarding as a method of tumor detection

- **Tumor marker:** elevated even in an acute inflammatory episode. Falling titers make carcinoma less likely.
- ▶ **In patients with suspected pancreatic carcinoma:** Ultrasound has an overall accuracy rate of 72% (comparable to CT), but considerably less with tumors < 3 cm
  - **Tumor marker:** Ca 19-9 is positive in approximately 80% of cases.
  - **FNAB:** only with an inoperable tumor (vascular infiltration, distant metastases; ultrasound staging has high sensitivity, see Fig. 73, p. 54). High accuracy rate (unless there is concomitant chronic pancreatitis). FNAB may be omitted in patients with a resectable tumor.
  - **CT or endosonography:** for evaluating tumor extent and operability. Endosonography has a 100% accuracy rate in tumor diagnosis.
  - **Operation:** After the exclusion of inoperable tumors (approximately 80%), the latest results at large centers suggest that 30–45% of tumors are resectable even when locoregional metastasis has occurred. Size is not a measure of operability. The 5 year survival rate after an R0 resection and lymph node dissection in patients with operable tumors is 10–35%.
- ▶ **In patients with a suspected pancreatic pseudocyst:**
  - Fine-needle aspiration of the cyst contents (bacteriology, amylase determination, cytology)
  - Further diagnostic criteria are given in Fig. 455.

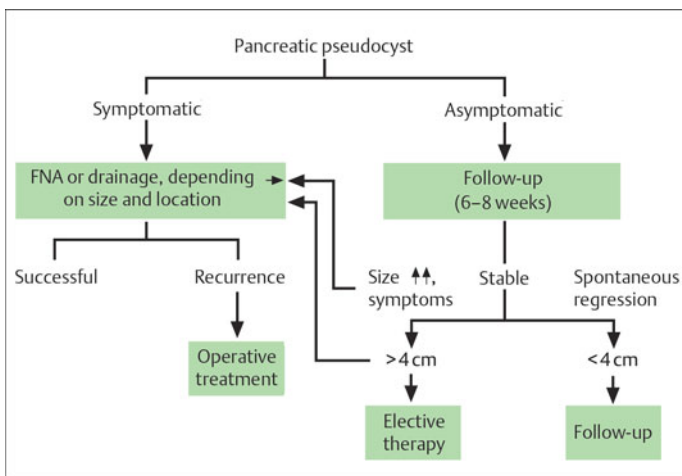


Fig. 455 Therapeutic algorithm for pancreatic pseudocysts (after Schwerk)

## 12 Spleen

### 12.1 Examination

#### Scan Planes

- ▶ Left subcostal oblique scan (see p. 27)
- ▶ High left-sided flank scan (see p. 26)

#### Sonographic Anatomy and Normal Findings

- ▶ **Sonographic anatomy** (Fig. 456):
  - The spleen is a subphrenic organ located in the left side of the abdomen. Its longitudinal axis is generally oriented parallel to the 10th rib.
  - The visceral surface of the spleen is closely related to the left kidney and adrenal gland and to the tail of the pancreas.
  - The spleen has smooth borders but is frequently notched at the hilum (crenate margin).

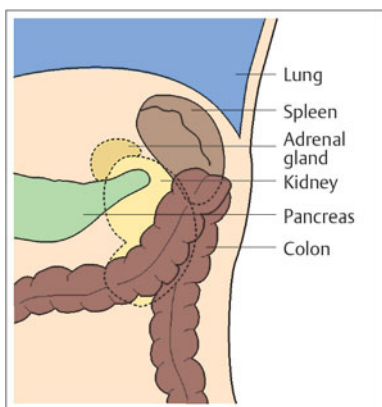


Fig. 456 Topographic anatomy of the spleen

- ▶ **Normal findings** (Fig. 457):
  - The normal spleen has a uniformly hypoechoic echo pattern.
  - The spleen is crescent- or wedge-shaped in longitudinal section and elliptical in cross section (left subcostal scan, visible only in a magnified view).
- ▶ **Normal dimensions:** length < 110 mm, thickness < 50 mm, width < 70 mm.

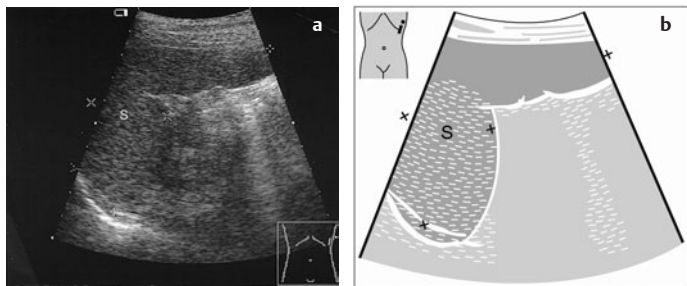


Fig. 457a, b Sonographic appearance of the spleen (S) in longitudinal section (high flank scan on the left side)

### Scanning Protocol

- ▶ Place the transducer in the left axillary line between the inferior costal margin and the iliac crest, parallel to the longitudinal course of the ribs.
- ▶ By angling the probe slightly cephalad with the breath held at inspiration, it is almost always possible to define the entire spleen.
- ▶ **Scanning tips:**
  - If the patient inhales too deeply, the upper pole of the spleen is often obscured by overlying air in the costophrenic angle.
  - If the organ is small or difficult to define, raising the patient's left arm in the supine or right lateral decubitus position and scanning at full inspiration will open up the intercostal spaces and aid in visualizing the spleen.

## 12.2 Sonographic Findings

### Basic Principles

- ▶ Scanning the spleen is a routine part of the upper abdominal ultrasound study. The spleen is often difficult to evaluate clinically because of its location, in which case ultrasound is the standard method for the assessment of splenic size. The interpretation of B-mode findings is strongly dependent on clinical data. Besides the detection of focal abnormalities, follow-up scans are often needed to make a definitive evaluation.
- ▶ **Classification:**
  - *Diffuse splenic changes* (see p. 314): Reflected mainly in splenic enlargement (splenomegaly). The following causes should be considered:
    - Infectious diseases
    - Systemic lymphatic diseases
    - Myeloproliferative diseases
    - Hemolytic anemias
    - Congestive splenomegaly (liver disease, venous congestion)
    - Storage diseases
  - *Focal splenic changes* (see p. 315): On ultrasound these lesions may appear predominantly anechoic, predominantly hypoechoic, or predominantly echogenic.
    - *Overview:* See Table 53.
    - *Interpretive criteria:* See Table 54.

**Table 53 · Focal splenic changes**

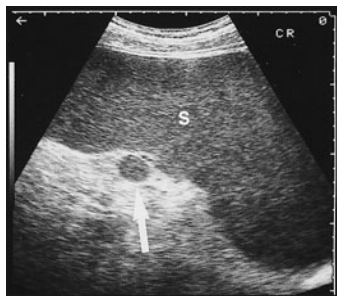Anechoic or hypoechoic	Echogenic
Splenic cyst (p. 315)	Hemangioma, splenoma (p. 318)
Splenic abscess (p. 316)	Splenic calcification (p. 319)
Splenic lymphoma (p. 316)	
Splenic infarction (p. 317)	
Splenic trauma (p. 317)	
Splenic metastases (p. 318)	

**Table 54 · Criteria for evaluating focal splenic lesions**

Criterion	Description
Echogenicity	Anechoic, hypoechoic (p. 315), echogenic (p. 318)
Size	Micronodular, macronodular (p. 316)
Margins	Smooth, irregular (p. 315, 316)
Shape	Round, oval, wedge-shaped, crescent-shaped (p. 317)
Internal echoes	Mobile internal echoes on real-time observation (p. 318)
CDS	Presence or absence of intrasplenic vascularity (p. 7)

### Diffuse Changes

- ▶ **Splenomegaly** (Figs. 458 and 459): spleen > 12 cm in length × 5 cm in width.
  - **Sonographic findings:**
    - Diffuse changes usually have a homogeneous echo pattern
    - Enlargement of the splenic poles
    - Accentuation of the splenic vessels
  - **Clinical findings:** Often the clinical findings will suggest the correct diagnosis. For example, infectious disease → inflammatory laboratory parameters and serologic findings; systemic lymphatic disease → generalized lymphadenopathy; myeloproliferative syndromes → abnormal blood count and bone marrow findings; hemolytic anemia → laboratory hemolytic parameters; congestive splenomegaly → liver disease, portal hypertension, portosystemic collaterals, etc.



**Fig. 458** Marked splenomegaly with a homogeneous echo pattern of the splenic parenchyma (S) in non-Hodgkin lymphoma. The arrow points to an accessory spleen. (NB: In this image and the ones shown later in this chapter, the transducer was rotated 180°)

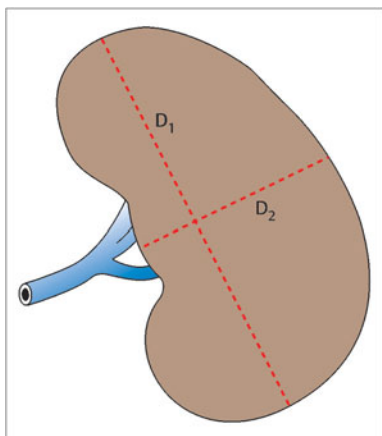


Fig. 459 The size of the spleen is determined by measuring its greatest length (D1) and greatest width (D2). (The third dimension, depth, cannot be seen here.)

- ▶ **Small spleen** (functional hypo- or asplenia): spleen < 7 cm in length × 3 cm in width
  - *Sonographic findings:*
    - A small spleen will usually have a nonhomogeneous internal echo pattern
    - Frequent nonvisualization of the splenic vessels
  - *Clinical findings:* differentiation from a physiologically small spleen due to aging. More common in ulcerative colitis, sickle cell anemia, throrastosis, immunologic diseases, and allogenic bone marrow transplantation

### Focal Changes: Anechoic or Hypoechoic

- ▶ **Splenic cyst** (Figs. 460 and 461):
  - *Sonographic criteria:*
    - Predominantly anechoic focus
    - Variable size
    - Smooth, round margins

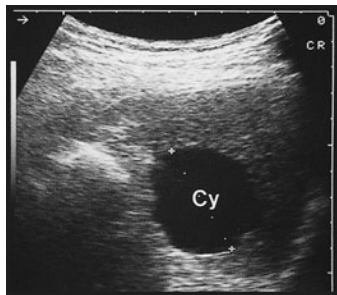


Fig. 460 Small, asymptomatic, anechoic splenic cyst (Cy)

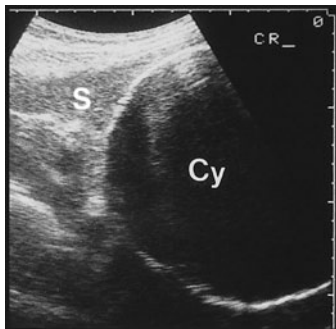


Fig. 461 Large anechoic cyst (Cy) with a markedly thick wall, occupying almost the entire spleen (S)

- Frequent peripheral calcification
- Occasional mobile internal echoes
- CDS: absence of vascularity
- *Clinical findings:* usually asymptomatic. Most primary cysts are congenital; secondary cysts may result from antecedent trauma, infarction, pancreatitis, or echinococcosis.

► **Splenic abscess:**

- *Sonographic criteria:*
  - Predominantly hypoechoic focus
  - Variable size
  - Irregular margins, variable shape
  - Occasional mixed echogenicity with air echoes and mobile internal echoes on real-time observation
  - CDS: absence of vascularity
- *Clinical findings:* Most patients are seriously ill, with pronounced signs of inflammation. Microabscesses (Fig. 462) most commonly result from hepatosplenic candidiasis.

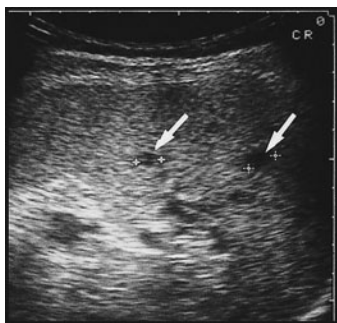

Fig. 462 Multiple small, almost anechoic microcysts (arrows) in hepatosplenic candidiasis

► **Splenic lymphoma (Fig. 463):**

- *Sonographic criteria:*
  - Predominantly hypoechoic focus
  - Variable size
  - Smooth margins, often rounded
  - Occasional diffuse nonhomogeneity

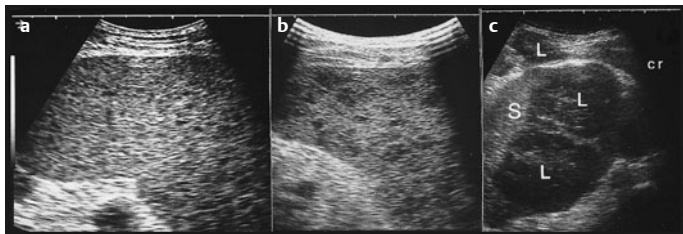


Fig. 463a-c Different patterns of splenic infiltration by malignant lymphoma. **a** The entire spleen is diffusely permeated by very small, hypoechoic foci. **b** Small hypoechoic foci, some with irregular margins. **c** Larger hypoechoic lymphoma masses (L) occupying almost the entire spleen (S)

- CDS: vascularity
- Frequent splenomegaly
- *Clinical findings:* Most patients have a known history of systematic lymphatic disease (non-Hodgkin lymphoma, Hodgkin disease). Systemic manifestations (fever, night sweats, weight loss), occasional LDH elevation
- ▶ **Splenic infarction** (Fig. 464):
  - *Sonographic criteria:*
    - Variable echogenicity, usually a hypoechoic focus
    - Variable size; irregular margins, occasionally wedge-shaped
    - Occasional free fluid in the abdomen
    - Possible subcapsular hematoma
    - CDS: absence of vascularity in the infarcted area
  - *Clinical findings:* Pain may be localized, diffuse, or absent. Splenic rub? Endocarditis? Sepsis? Myeloproliferative disease?
- ▶ **Splenic trauma** (Figs. 465 and 466):

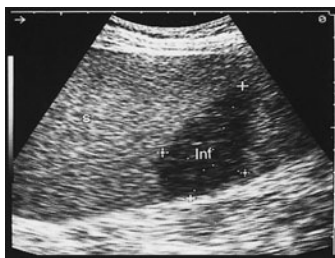

Fig. 464 Small, hypoechoic, wedge-shaped area of splenic infarction (Inf) in a setting of myeloproliferative disease

- *Sonographic criteria:*
  - Predominantly hypoechoic focus; echogenic in the acute stage
  - Variable size, irregular margins
  - Occasional crescent-shaped subcapsular hematoma
  - Occasional free fluid in the abdomen
  - Liquid areas may contain mobile internal echoes
  - CDS: absence of vascularity

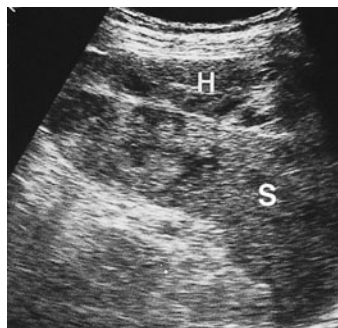


Fig. 465 Spontaneous subcapsular hematoma formation (H) in a patient with varicella sepsis. S = spleen

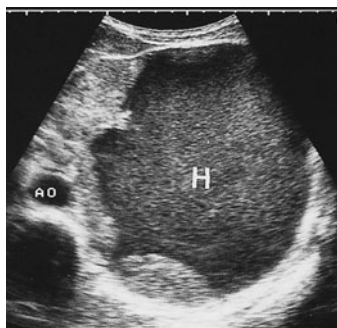

Fig. 466 Large posttraumatic intrasplenic hemorrhage (H), occupying almost the entire spleen. AO = aorta

- *Clinical findings:* history of trauma or underlying splenic disease (infection, hematologic disease, congestive splenomegaly, splenic infarction, splenic metastasis, etc.)

▶ **Splenic metastases** (Fig. 467):

- *Sonographic criteria:*
  - Predominantly hypoechoic focus, sometimes echogenic; occasional hypoechoic rim
  - Variable size and margins
  - Occasional central necrosis
  - *CDS:* vascularity
- *Clinical findings:* Splenic metastases are rare and are usually due to hematogenous spread from an advanced malignancy. Direct infiltration of the spleen (by gastric carcinoma, pancreatic carcinoma, etc., see Fig. 468) is also rare.

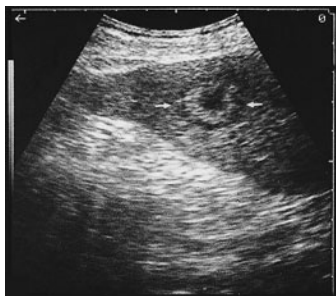

Fig. 467 Solitary echogenic splenic metastasis (arrows) with a peripheral halo and central liquefaction in a patient with colon carcinoma

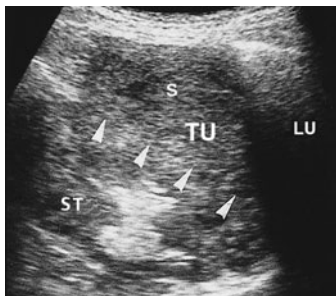

Fig. 468 Histologically confirmed gastric carcinoma. The tumor (TU) has invaded the spleen (S) by contiguous spread. ST = stomach, LU = lung

### Focal Changes: Echogenic

- ▶ **Hemangioma, splenoma** (Fig. 469): may resemble splenic metastases (Fig. 470), littoral cell angioma, fresh hematoma, storage diseases, and hemangiosarcoma

- *Sonographic criteria:*
  - Predominantly echogenic focus
  - Variable size

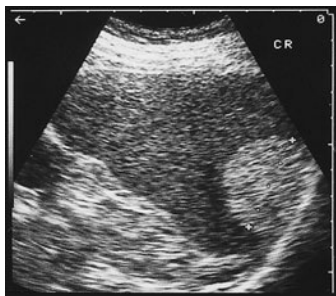

Fig. 469 Solitary echogenic mass, detected incidentally in an asymptomatic patient. The mass remained unchanged for 3 years, consistent with a benign splenoma or hemangioma

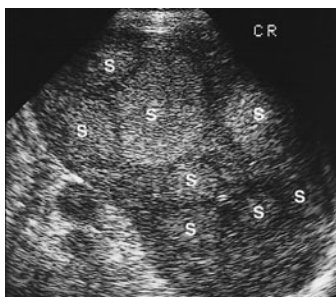


Fig. 470 Multiple rounded, echogenic splenic foci (S) due to diffuse metastasis from a carcinoid

- Usually round with smooth margins
- Occasional intralesional calcifications
- CDS: usually sparse vascularity
- *Clinical findings:* usually asymptomatic, often detected incidentally on ultrasound
- ▶ **Splenic calcification** (Fig. 471):
  - *Sonographic criteria:*
    - Predominantly echogenic focus
    - Variable size, smooth margins; variable shape
    - Posterior acoustic shadowing
    - CDS: absence of vascularity
  - *Clinical findings:* usually asymptomatic. May result from or accompany inflammations, abscesses, infarctions, cysts, and metabolic diseases (calcification of the splenic artery)

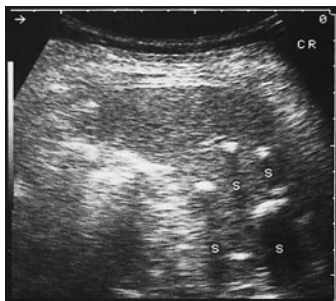

Fig. 471 Multiple intrasplenic calcifications in an asymptomatic patient. S = acoustic shadows

### Further Testing

- ▶ **Splenomegaly:** A complete workup may require laboratory tests, lymph node histology, bone marrow histology, and liver histology.
- ▶ **Small spleen:** laboratory parameters, Howell-Jolly bodies in stained blood,  $^{99m}\text{Tc}$  colloid scintigraphy
- ▶ **Splenic cyst:** see Fig. 472).
- ▶ **Splenic abscess:**
  - Diagnostic fine-needle aspiration (see p. 53), repetitive percutaneous drainage, catheter drainage (see p. 58), surgical options

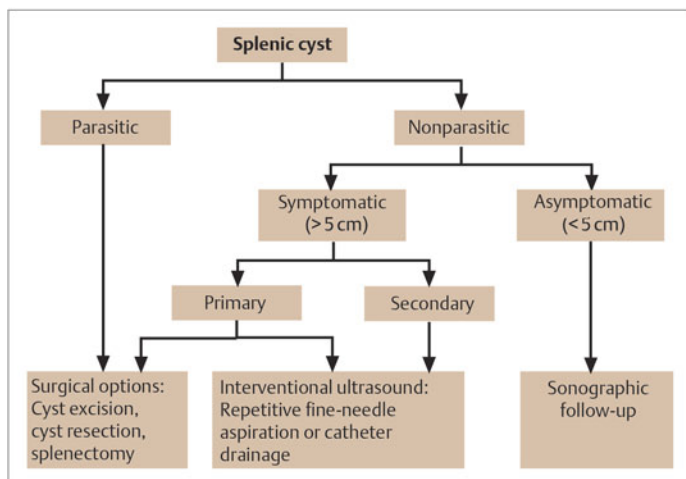


Fig. 472 Therapeutic algorithm for a splenic cyst

- With microabscesses (Fig. 462, p. 316): antimycotic therapy with sonographic follow-up
- ▶ **Splenic lymphoma:** sonographic follow-up. Isolated splenic lymphoma can be evaluated by percutaneous biopsy, but the sonographic course is usually enough to make a benign–malignant differentiation.
- ▶ **Splenic infarction:** requires sonographic follow-up. Most cases undergo complete resolution. Surgery may be necessary if complications arise (e.g., increasing liquefaction of the infarction, lack of regression, splenic rupture, infection) (Fig. 473).
- ▶ **Splenic trauma:**
  - CT is more reliable than ultrasound for grading the splenic injury.
  - Sonographic follow-up or surgery, depending on imaging findings and especially on clinical status
- 🚩 **Caution:** Look out for two-stage splenic rupture with subcapsular hemorrhage.
- ▶ **Splenic metastases:**
  - Sonographic follow-up is usually sufficient, because of the presence of an inoperable tumor or end-stage disease.
  - *With isolated splenic infiltration:* fine-needle aspiration (see p. 53) or surgical diagnosis
- ▶ **Hemangioma, splenoma:** CT may be required. Sonographic follow-ups or surgical diagnosis may be advised, depending on clinical findings. Often a definitive diagnosis is not made if the lesion remains unchanged over time.
- ▶ **Splenic calcification:** Sonographic follow-up may be advised. If ultrasound confirms the diagnosis, there is no need for additional tests.

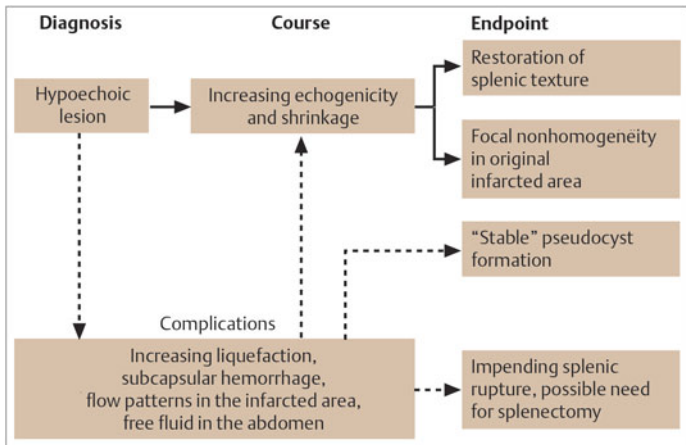


Fig. 473 Sonographic manifestations, course, and complications of splenic infarction (after Görg)

## 13 Bile Ducts

### 13.1 Examination

#### Scan Planes

- ▶ Intercostal scan, extended right intercostal scan, porta hepatis scan (see p. 33)
- ▶ Subcostal oblique scan on the right side (see p. 22).

#### Sonographic Anatomy and Normal Findings

- ▶ With careful scrutiny, the intrahepatic bile ducts can be identified as fine anechoic bands running anterior to the portal venous branches (except the left anterior segmental branch). The hepatic artery runs between or posterior to the intrahepatic ducts.
- ▶ The right and left hepatic ducts unite at the porta hepatis to form the common hepatic duct.
- ▶ The cystic duct is very difficult to visualize because of its tortuous course.
- ▶ In most cases the common bile duct and pancreatic duct empty into the duodenum by a common opening. (Since the termination of the cystic duct generally cannot be identified with ultrasound, the common hepatic duct and common bile duct are usually referred to collectively as "the bile duct," Figs 474 and 475.)
- ▶ *Normal dimensions:* The extrahepatic duct is < 7 mm in diameter, depending on age.

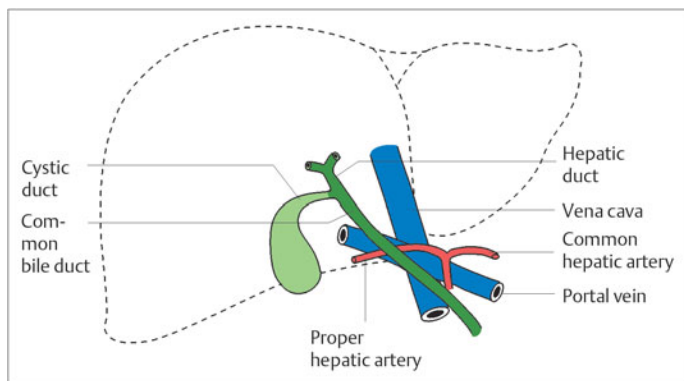


Fig. 474a Topographic anatomy of the gallbladder and biliary tract

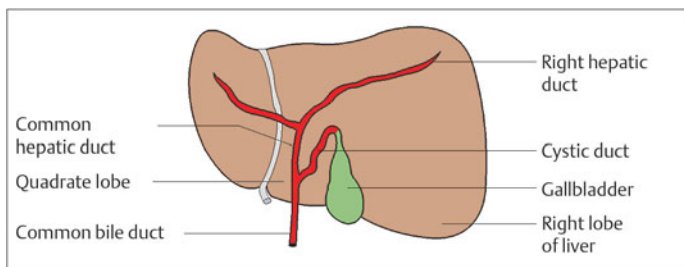


Fig. 474b Topographic anatomy of the gallbladder and biliary tract

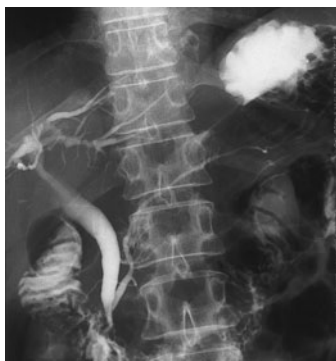

Fig. 475 ERCP demonstrates the descending, prepapillary (common) course of the bile duct and pancreatic duct in the head of the pancreas

### Scanning Protocol

- ▶ **Transducer:** 3.5–5.0 MHz.
- ▶ The patient is scanned early in the morning in a fasting state.
- ▶ Use the supine position for scanning the prepapillary bile duct; use left lateral decubitus and deep inspiration for scanning the upper two-thirds of the bile duct.
- ▶ A parasagittal upper abdominal longitudinal scan is best for evaluating the prepapillary segment of the bile duct (see Fig. 84, p. 64).
- ▶ A semiupright position is occasionally helpful in the detection of prepapillary stones.
- ▶ **Scanning tip:** Carefully controlled compression of the abdominal fat and bowel gas with a small-footprint transducer will generally permit good imaging of the distal bile duct and its termination in the duodenum (Fig. 476).

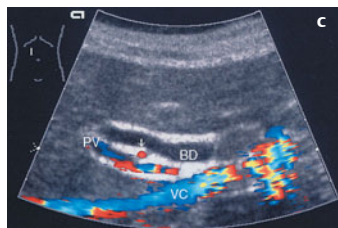
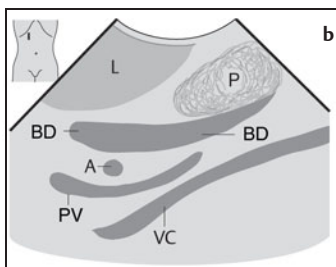
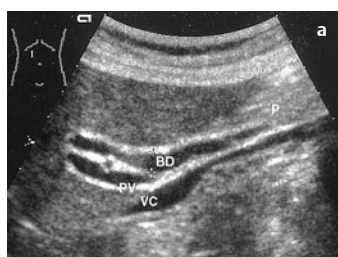


Fig. 476a–c Intra- and extrahepatic course of the bile duct (BD) anterior to the proper hepatic artery (A, arrow, cut transversely by the scan), the portal vein (PV, cut obliquely by the scan), and the inferior vena cava (VC, cut longitudinally by the scan). Paramedian upper abdominal longitudinal scan on the right side. **a** B-mode image. **b** Correlative diagram. **c** CDS. L = liver, P = pancreas

## Overview and Classification of Findings

- ▶ Incidental findings in the biliary tract are rare because clinical manifestations will usually prompt a specific ultrasound examination of that region. Thus, the sonograms in this chapter do not illustrate findings that correlate with a clinical presentation of “jaundice” or “cholestasis” (jaundice is reviewed on pp. 139–149).
- ▶ Most abnormal findings are characterized by circumscribed or diffuse biliary stasis. It is rare to encounter a nonobstructive biliary tract lesion.
- ▶ Echogenic structures projected into the liver or biliary tract may represent stones, calcifications, vascular calcification, abscesses, clots, or an echogenic ligamentum teres. Biliary sludge is apt to be mistaken for an intraluminal tumor.
- ▶ **Classification and overview:**
  - *Intrahepatic duct changes:* see Table 55, p. 325.
  - *Extrahepatic duct changes:* see Table 56, p. 330.
- ▶ **Typical duct changes in:**
  - *Biliary cysts, liver cysts:* Biliary cysts communicate with the biliary system. They contain biliary fluid and are therefore susceptible to stone formation (see Fig. 478a–c, p. 326). “Liver cysts” usually originate from the biliary tract but do not communicate with the bile ducts and therefore contain serous fluid rather than bile.
  - *Sclerosing cholangitis, biliary cirrhosis:* Despite cholestasis, primary biliary cirrhosis is not associated with bile duct changes (unlike primary sclerosing cholangitis, it affects only canaliculi and does not affect larger bile ducts).
  - *Duct stones:* Intraductal stones are not necessarily associated with cholestasis or ductal dilatation.

## 13.2 Intrahepatic Ductal Changes

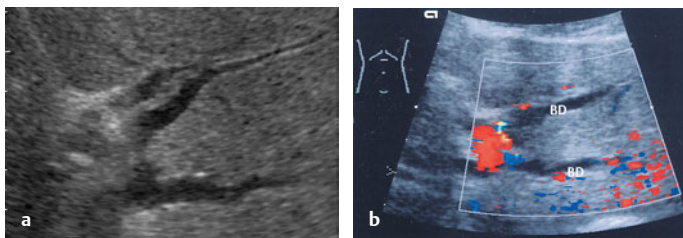
### Overview (Table 55):

**Table 55** · Intrahepatic duct changes

Anechoic or hypochoic	Echogenic or sonodense
Biliary cysts, Caroli syndrome (p. 326)	Duct stones (p. 330)
Sclerosing cholangitis (p. 327)	Pneumobilia (p. 330)
Parasites (p. 328)	
Papillomatosis, papillomatous carcinoma (p. 328)	
Intrahepatic bile duct carcinoma (p. 328)	
Compression or infiltration by metastases (p. 329)	

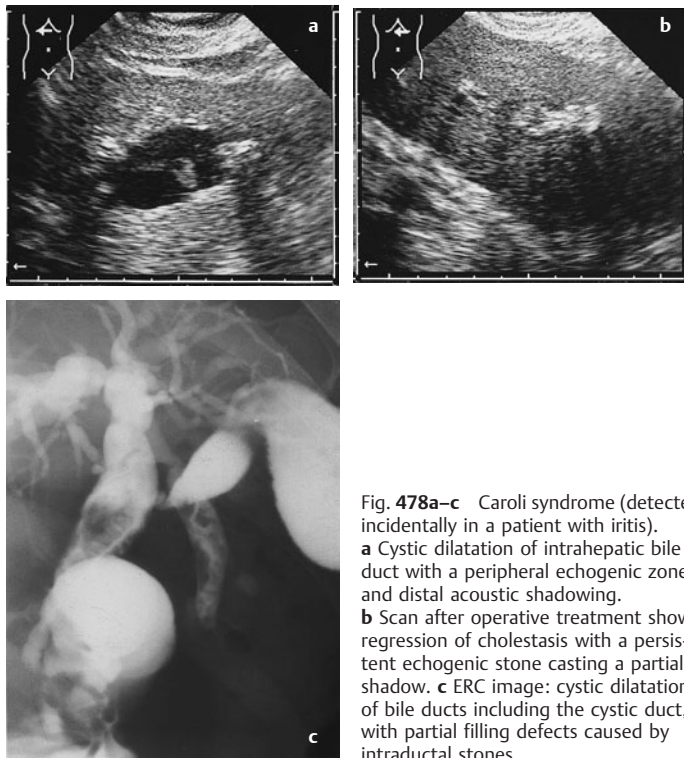
### Anechoic or Hypochoic Changes

- ▶ **Ductal dilatation:** The dilated duct and associated portal vein branch appear as anechoic tramlines. Generally the bile duct lies anterior and the portal vein branch is posterior.
  - **Exception:** With the anterior and posterior branches of the left main branch of the portal vein, the bile duct is posterior to the anterior branch and anterior to the posterior branch. Doubts can be resolved by CDS (Fig. 477).



**Fig. 477a, b** Intrahepatic bile duct dilatation secondary to a long-standing elevation of biliary pressure. **a** B-mode image: dilated intrahepatic duct branch in segment II and an accompanying anterior portal vessel, also an expanded bile duct branch in segment III. **b** CDS: The left main branch of the portal vein is encoded in red. CDS (with spectral analysis if necessary) can positively distinguish between a portal venous branch, an artery, and a bile duct (BD)

- ▶ **Biliary cysts** (Caroli syndrome, Fig. 478):
  - Circumscribed anechoic ductal dilatation
  - Possible hyperechoic stone with a distal acoustic shadow



**Fig. 478a–c** Caroli syndrome (detected incidentally in a patient with iritis).  
**a** Cystic dilatation of intrahepatic bile duct with a peripheral echogenic zone and distal acoustic shadowing.  
**b** Scan after operative treatment shows regression of cholestasis with a persistent echogenic stone casting a partial shadow.  
**c** ERC image: cystic dilatation of bile ducts including the cystic duct, with partial filling defects caused by intraductal stones

► **Sclerosing cholangitis** (Fig. 479):

- Irregularly dilated bile ducts with caliber variations
- Stenoses
- Broadened, fragmented portal tracts extending toward the periphery
- Accentuated arteries (between the portal branch and bile duct)

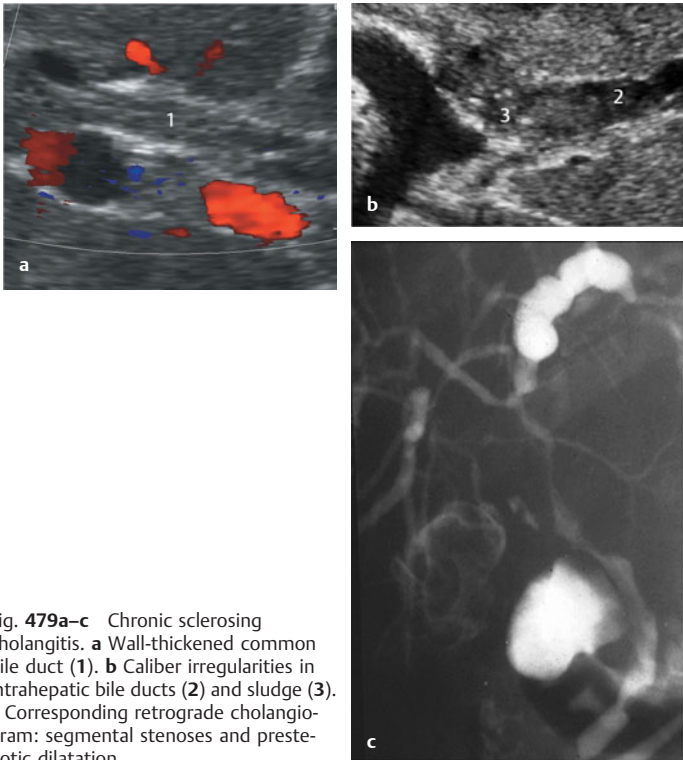


Fig. 479a–c Chronic sclerosing cholangitis. **a** Wall-thickened common bile duct (1). **b** Caliber irregularities in intrahepatic bile ducts (2) and sludge (3). **c** Corresponding retrograde cholangiogram: segmental stenoses and prestenotic dilatation

- ▶ **Parasites** (in order of frequency): ascarids, *Echinococcus alveolaris*, liver fluke
  - ▶ **Note:** The overall incidence of biliary parasites is very low.
- ▶ **Biliary papillomatosis, papillomatous carcinoma** (Fig. 480):
  - Lobular, polypoid intraluminal mass
  - Dilated intrahepatic (and extrahepatic) bile ducts
  - ▶ **Note:** Papillomatosis is rare. The prognosis is poor because of the high potential for recurrence and malignant change. Liver transplantation may be required.

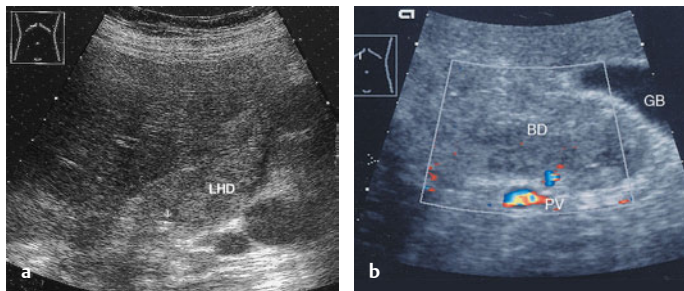


Fig. 480a, b Papillomatous bile duct carcinoma. **a** Tumor mass in the left hepatic duct (LHD), appearing isoechoic to liver parenchyma. Arrow: biliary drain. **b** CDS: tumor ingrowth into the bile duct (BD). There are practically no intratumoral vessels. PV = portal vein, GB = gallbladder

- ▶ **Intrahepatic bile duct carcinoma** (Fig. 481):
  - Circumscribed, anechoic area of ductal dilatation
  - Contour cutoff
  - Often a tumor is not directly visualized but is evidenced by the hypoechoic transformation of proximal liver segments
  - Pericanalicular tumor spread

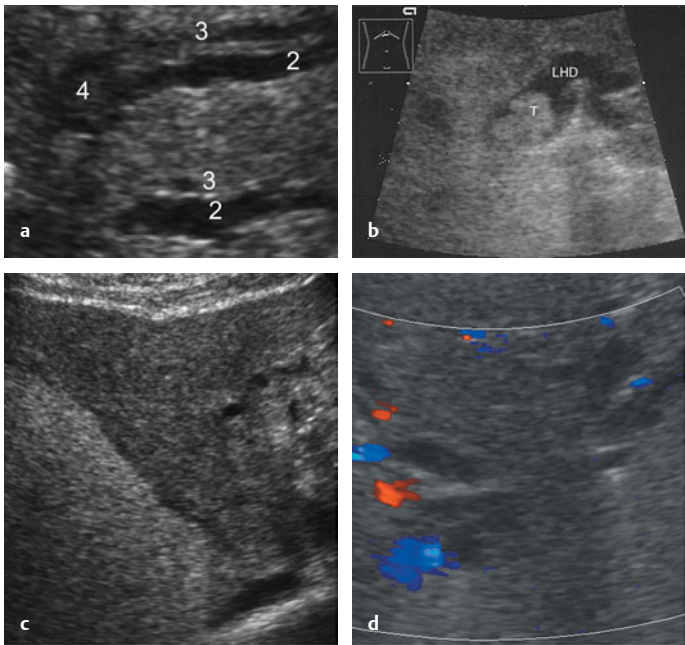


Fig. 481a–d Intrahepatic bile duct tumors with associated biliary stasis. **a** Cholangiocellular carcinoma (4) with peripheral obstruction of the bile ducts (2) and accompanying divisions of the portal vessels (3). **b** Cholangiocellular carcinoma (T) of the left hepatic duct (LHD). **c** Type 1 Klatskin tumor. Obstructed intrahepatic bile ducts are seen only in the less echogenic left hepatic lobe. **d** Type 3 Klatskin tumor: obstructed intrahepatic bile ducts and divisions of the portal vessels

► **Ductal dilatation due to compression or invasion by metastases:**

- Circumscribed dilatation of the bile duct
- Evidence of metastasis

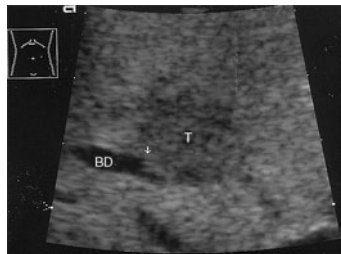


Fig. 482 Intrahepatic bile ducts (BD) obstructed by an infiltrating metastasis (T) from pancreatic carcinoma (Not detectable on CT)

## Echogenic or Sonodense Changes

### ► Intrahepatic duct stones:

- Solitary or multiple echogenic foci projected into the duct lumen
- Distal acoustic shadows or summation acoustic shadowing

### ► Pneumobilia: air in the biliary tract:

- Echogenic string-of-beads or band-like structures (mobile with position changes) in the portal tracts
- With a spontaneous biliary–enteric fistula caused by a perforating stone, the stone can be detected outside the biliary tract. With a surgical biliary–enteric anastomosis or papillotomy, any obstructing stone is generally cleared.

## 13.3 Extrahepatic Ductal Changes

### Overview (Table 56):

**Table 56** · Extrahepatic duct changes

Anechoic or hypoechoic	Echogenic or sonodense
Ductal dilatation due to obstructive cholestasis (p. 330)	Biliary stones (p. 332)
Papillomatosis (p. 331)	DD: vascular calcification (p. 332)
Ascariasis (p. 331)	Pneumobilia (p. 332)
Sludge or pus (p. 331)	

### Anechoic or Hypoechoic Changes

#### ► Anechoic ductal dilatation in obstructive cholestasis (Figs. 483 and 484):

- Diffuse, anechoic intraductal area > 7 mm
- Detectable obstructing lesion (tumor, stone)
- *With sclerosing cholangitis:* segmental ductal dilatation, string-of-beads luminal irregularities (Fig. 483b)

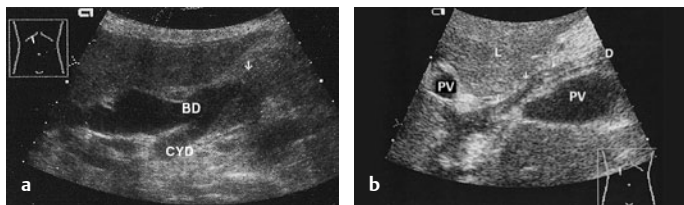
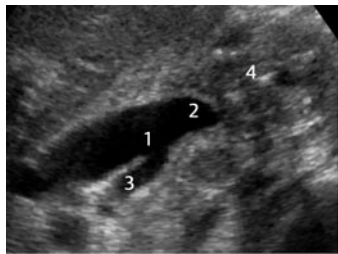

Fig. 483a, b Extrahepatic cholestasis. **a** Dilated bile duct, obstructed cystic duct (CYD) with cutoff (BD) due to bile duct carcinoma. Arrow: anechoic lumen with sludge. **b** Significant thickening of the duct wall (arrows) as far as the duodenum (D). The duct does not contain fluid. End stage of sclerosing cholangitic cirrhosis (L). PV = portal vein

Fig. 484 Complete obstruction of the bile duct in chronic pancreatitis. The orifice of the cystic duct (3) marks the junction of the hepatic duct (1) with the common bile duct (2). 4 = Head of the pancreas



- ▶ **Obstructing cystic duct stone:** dilated infundibulum continuous with a postero-superiorly expanded cystic duct, often with a definable obstructing stone
- ▶ **Biliary papillomatosis:** lobulated intra- and extrahepatic masses partially occupying the bile ducts
- ▶ ***Ascaris lumbricoides*** (Fig. 485): serpentine or band-like intraluminal structures

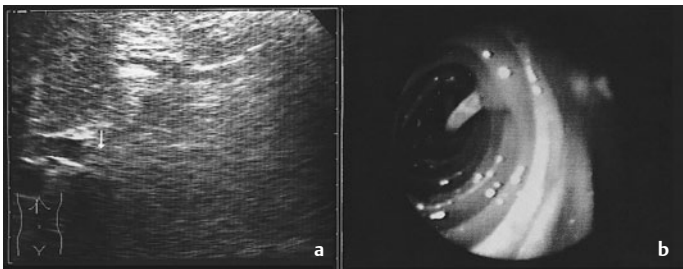


Fig. 485a, b *Ascaris lumbricoides* in the bile duct. **a** Ultrasound shows a hypoechoic intraluminal mass (arrow). **b** At endoscopy, an ascarid worm is visible in the papilla. The patient presented clinically with necrotizing pancreatitis

- ▶ **Biliary sludge or pus** (Fig. 486):
  - Hypoechoic intraluminal material, generally associated with an extrahepatic obstruction (stone or tumor, Fig. 483a)

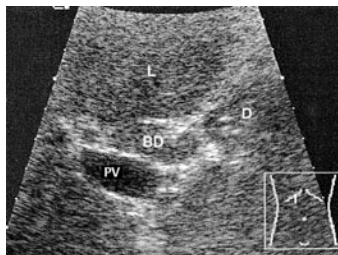

Fig. 486 Hypoechoic bile duct (BD) in suppurative cholangitis. PV = portal vein, L = liver, D = duodenum

### Echogenic or Sonodense Changes

- ▶ **Biliary stones** (Fig. 487):
  - Round or oval intraluminal foci of high echogenicity
  - Complete or incomplete acoustic shadow (may provide the only sonographic evidence of a nonobstructing stone)
- ▶ **Hepatic artery calcification:**
  - Typical location at the site where the hepatic artery passes beneath the common duct
  - Duct compression
  - Generally does not cast an acoustic shadow
- ▶ **Pneumobilia:** string-of-beads or band-like (mobile) echo structure (after papillectomy or fistula)

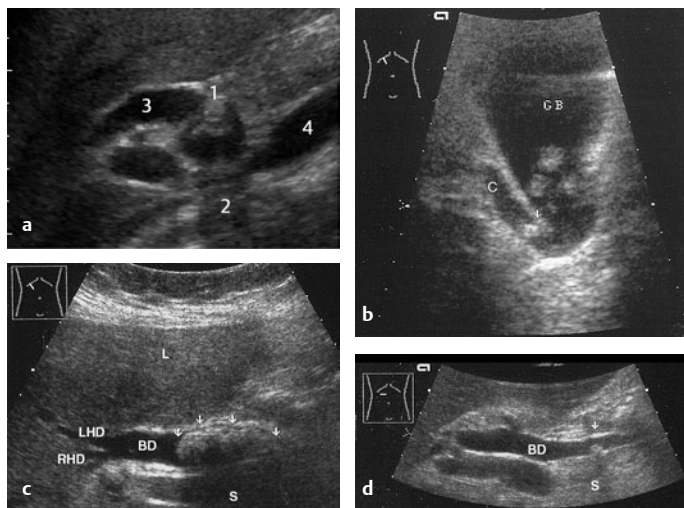


Fig. 487a–d Obstructing stones in the extrahepatic bile ducts. **a** Mirizzi stone (1) with an acoustic shadow (2), gallbladder lumen (4), and an obstructed hepatic duct (3). Typical location of the proper hepatic artery between the portal vein and hepatic duct. **b** Cystic duct stone (arrow, C). The stone oscillates within the duct, causing intermittent cystic duct obstruction. **c** Large oblong stone (arrows, 35 mm): acoustic shadow (S) in the bile duct (BD) with dilatation of the right and left hepatic ducts (RHD, LHD). L = liver **d** Small prepapillary stone (arrow) with an acoustic shadow (S)

## 13.4 Evaluation and Further Testing

### Sonography

---

- ▶ Changes in the intra- and extrahepatic bile ducts can be detected sonographically with very high confidence and can generally be identified.
- ▶ **Diagnostic accuracy:**
  - Obstructive cholestasis can be distinguished from nonobstructive forms in almost 100% of cases.
  - Intra- and extrahepatic stones > 15 mm can be correctly diagnosed in 100% of cases.
  - Intrahepatic tumors can be detected and identified indirectly based on circumscribed ductal dilatation, and extrahepatic tumors can be directly visualized.
  - Prepapillary stones are more difficult to detect (although this is examiner-dependent).
  - Sclerosing cholangitis can be correctly diagnosed in approximately 80% of cases.

### Further Testing

---

- ▶ **Primary biliary cirrhosis:** The clinical picture is that of cholestasis, but ultrasound does not show significant hepatic or biliary abnormalities. Can be diagnosed by the determination of antimitochondrial antibodies (positive in 96% of cases).
- ▶ **Sclerosing cholangitis:** Sonography shows echogenic wall thickening, string-of-beads irregularities due to mural fibrosis, and circumscribed foci of intrahepatic ductal dilatation. Liver histology and ERC confirm the diagnosis, with ERC showing duct irregularities (suppurative cholangitis secondary to biliary obstruction should be excluded). Ulcerative colitis is a common associated finding in many patients.
- ▶ **Suspicion of carcinoma:** ERC is the best modality for the further investigation of canalicular lesions, but it is not useful for evaluating the pericanalicular spread of a biliary tumor. Even CT is of limited value in this regard, and ultrasound is the imaging modality of choice.
- ▶ A detected tumor can be investigated further by FNAB with cytologic and histologic evaluation.
- ▶ Other indeterminate lesions of the extrahepatic bile ducts can be investigated by endosonography (biliary tumor or stone) or by biliary tract endoscopy.
- ▶ Metastases can be identified as the circumscribed cause of cholestasis by ultrasound and/or CT, or can be confirmed by FNAB.

## 14 Gallbladder

### 14.1 Examination

#### Scan Planes

- ▶ Right subcostal oblique scan (see p. 22)
- ▶ Intercostal scan, extended intercostal scan (see p. 23)

#### Sonographic Anatomy and Normal Findings

- ▶ The gallbladder nestles in the gallbladder fossa on the visceral surface of the liver, with only its fundus projecting past the inferior hepatic surface.
- ▶ The gallbladder is bounded on the right side by the right lobe of the liver, on the left side by the quadrate lobe, and posteriorly by the antrum or duodenal bulb (Fig. 474a, p. 323, and Fig. 474b, p. 323).
- ▶ Although many variants may be encountered (e.g., spherical, oblong, serpentine), the “textbook” gallbladder is pear-shaped and displays typical cystic features on ultrasound (anechoic interior, distal acoustic enhancement, smooth margins).
- ▶ **Normal dimensions:** longitudinal diameter < 100 mm, transverse diameter < 40 mm; volume < 100 mL, wall thickness < 3 mm (Fig. 488).

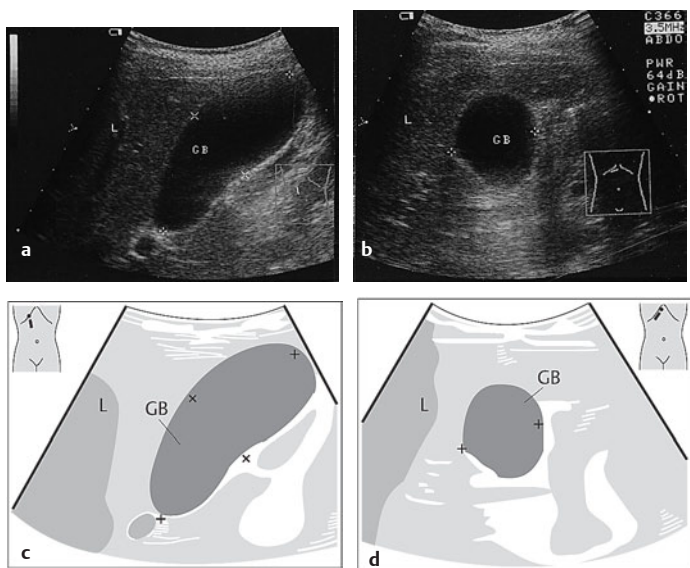


Fig. 488a–d Sonographic appearance of the gallbladder and its dimensions (cursors; length and depth in **a**, width in **b**). **a** Intercostal scan. **b** Right subcostal oblique scan. GB = gallbladder, L = liver

## Scanning Protocol

- ▶ **Transducer:** 3.5–5.0 MHz
- ▶ Patients are generally examined in a fasting state.
- ▶ The patient is usually positioned supine, or occasionally in left lateral decubitus or a standing position (“rolling stones,” polyps).
- ▶ The patient can be rapidly turned to mobilize crystal aggregates and microliths, causing them to swirl within the gallbladder lumen.
- ▶ The examination includes digital palpation (Murphy’s sign of acute cholecystitis = pain on gallbladder compression).
- ▶ Intercostal scans are helpful in patients with an elevated hemidiaphragm, in heavy-set patients, and after surgical operations.

## Overview and Classification of Findings

- ▶ **Classification:** Gallbladder abnormalities seen on ultrasound are classified as changes of size, shape, or location; intraluminal changes; and wall changes.
  - *Change in gallbladder size:* This may have a functional or organic cause.
  - *Intraluminal and wall changes:* It is important to distinguish between intraluminal and wall changes because of their different therapeutic implications. When wall changes are found, it is essential to make a detailed evaluation with magnified views and to document the findings in multiple planes (to determine whether operative treatment is indicated).
- ▶ **Overview:**
  - *Changes in size, shape, and location:* see Table 57, p. 335.
  - *Wall changes:* see Table 58, p. 339.
  - *Intraluminal changes:* see Table 59, p. 364.

## 14.2 Changes in Size, Shape, and Location

### Overview (Table 57):

**Table 57 · Changes in the size, shape, and location of the gallbladder**

Large gallbladder	Small gallbladder
Congested gallbladder, Courvoisier gallbladder (p. 336)	Contracted gallbladder (p. 336)
Hydrops (p. 336)	Empty gallbladder (p. 337)
Cystic duct obstruction (p. 332)	Hypoplasia (p. 340)
Gallbladder tumor (p. 341, 352)	Shrunken gallbladder (p. 340), perforated gallbladder (p. 337)
Change in gallbladder shape	Change in gallbladder location
Gallbladder diverticulum (p. 337)	Atypical location (p. 337)
Siphon gallbladder (p. 337)	
“Phrygian cap” (p. 337)	
Nonvisualization of the gallbladder (p. 337)	

## Changes in the Size of the Gallbladder

- ▶ **Congested gallbladder** (Fig. 489a): may result from hepatic cirrhosis or functional causes (acute abdomen, bowel obstruction, gastrointestinal diseases).
- ▶ **Courvoisier gallbladder** (Fig. 489b): may result from carcinoma of the pancreatic head
  - Enlarged gallbladder with dilatation of the cystic duct and common bile duct
  - Pre- or peripapillary duct cutoff sign
- ▶ **Contracted gallbladder** (Fig. 489c):
  - Increased gallbladder wall thickness with a normal three-layered wall structure
- ▶ **Hypoplasia:**
  - Small gallbladder with no detectable cause
- ▶ **Shrunken (stony) gallbladder** (Figs. 489d; Fig. 491c, p. 338):
  - Small gallbladder (in two planes)
  - Ultrasound almost always demonstrates stones or stone shadows.
  - The gallbladder wall is often echogenic (suggestive of chronic cholecystitis).

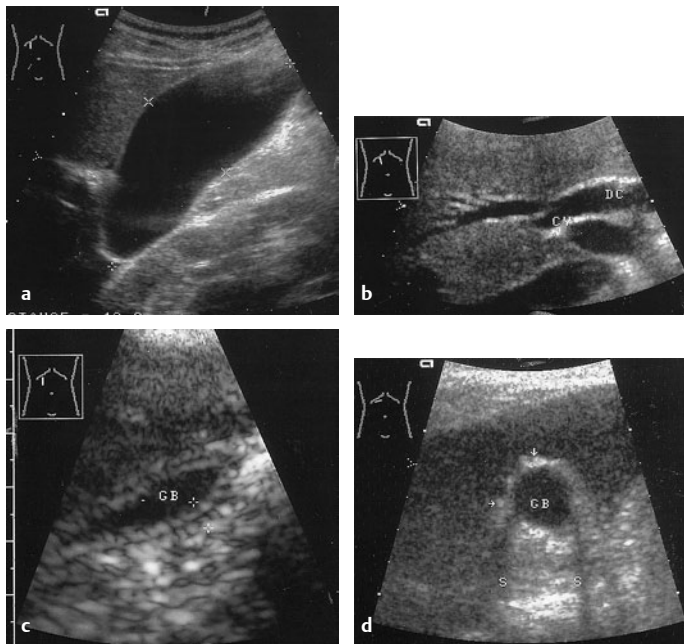


Fig. 489a–d Changes in gallbladder size. **a** Congested and enlarged gallbladder (cursors) in a patient with bowel obstruction. **b** Courvoisier gallbladder: requires differentiation from a congested gallbladder due to an obstructed cystic duct (CY) and common duct (DC). **c** Contracted gallbladder (GB): thickened wall with a normal layered structure (cursors). **d** Shrunken gallbladder: echogenic wall with irregular thickening (arrows). S = acoustic shadows

## Changes in the Shape and Location of the Gallbladder

- ▶ **Gallbladder diverticulum** (Fig. 490a): anechoic wall protrusion with a definable neck or stalk
- ▶ **Siphon gallbladder**: S-shaped tortuosity
- ▶ **“Phrygian cap”** (Fig. 490b): anatomical variant in which the gallbladder is kinked at the fundus
- ▶ **Atypical location**: intrahepatic or occupying an unusually low or lateral position

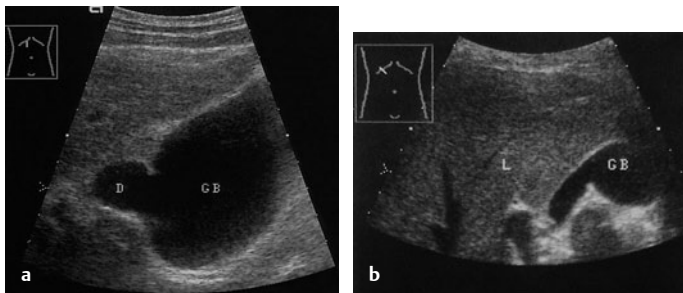


Fig. 490a, b Changes in gallbladder shape and location. **a** Gallbladder (GB) diverticulum (D). **b** Gallbladder (GB) kinked at the fundus. L = liver

## Nonvisualization of the Gallbladder

- ▶ **Scanning tip**: If you are having difficulty visualizing the gallbladder, look for it in the lesser pelvis, to the left or right of its typical location, or just beneath the abdominal wall (using the correct probe focus). Generally it can be located by moving the probe from a flank scan toward the midline while watching the inferior border of the liver, or by scanning subcostally along the interlobar fissure from the vena cava to the gallbladder bed.
- ▶ **Gallbladder agenesis**: often misinterpreted as a shrunken gallbladder; extremely rare
- ▶ **Contracted gallbladder** (see Fig. 489c, p. 336): History: “Have you recently eaten or smoked?”
- ▶ **Unusual location**: just beneath the abdominal wall in thin patients; in the midabdomen or lower abdomen in elderly cachexic patients. May be displaced laterally or medially in patients with hepatic cirrhosis
- ▶ **Empty gallbladder** (Fig. 491a): obstructing stone with a check-valve mechanism in the cystic duct or infundibulum
- ▶ **Echogenic gallbladder** (Fig. 491b): e.g., sludge, empyema, tumor
- ▶ **Stony gallbladder** (see Fig. 512, p. 349): stone-filled gallbladder that does not have an anechoic lumen
- ▶ **Shrunken gallbladder** (Fig. 491c): often identifiable only by distal shadowing
- ▶ **Perforated gallbladder** (Fig. 491d):
  - Bizarre hypoechoic formation
  - Free or confined fluid
- ▶ Postoperative gallbladder

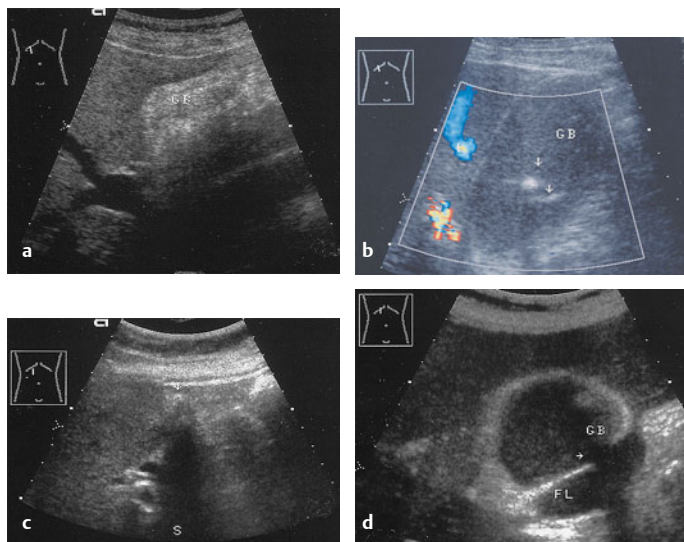


Fig. 491a–d Nonvisualization of the gallbladder.

**a** Empty gallbladder (GB) resulting from an infundibular and cystic duct stone with a check-valve mechanism.

**b** Echogenic gallbladder (GB) isoechoic to the liver. The impacted stones (arrow) and absence of tumor vessels (CDS) are consistent with empyema.

**c** Shrunken stony gallbladder. Only a distal acoustic shadow (S) marks the presence of the gallbladder (arrow).

**d** Perforated gallbladder. This gallbladder can still be identified owing to the confined fluid collection (FL) outside the perforation site. With a free perforation, the absence of the gallbladder and the presence of free intra-abdominal fluid (possible pneumobilia with a biliary–enteric fistula) raise suspicion of a perforation

## 14.3 Wall Changes

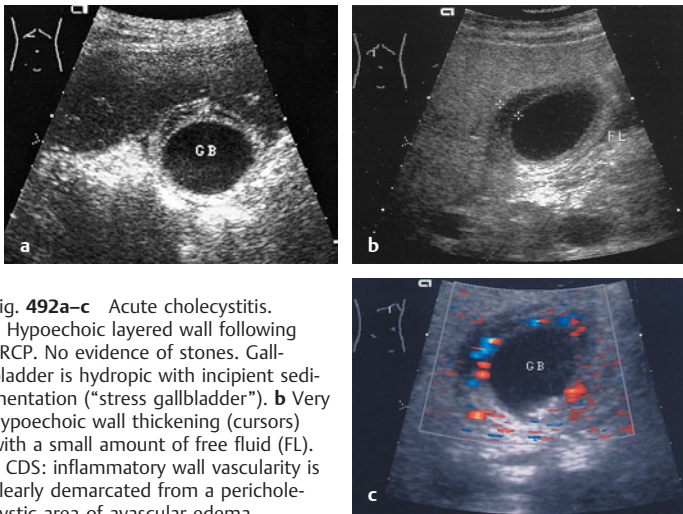
### Overview (Table 58):

**Table 58** · Changes in the gallbladder wall

Hypochoic or complex	Echogenic
Acute cholecystitis (p. 339)	Duplicated gallbladder (p. 342)
Wall thickening (hepatic or pancreatic disease, trauma, p. 340)	Flexion creases, true septa (p. 342)
Wall edema (ascites, right heart failure, p. 341)	Cholesterosis (p. 343)
Wall abscess (p. 341)	Adenomyomatosis (p. 343)
Wall infiltration by carcinoma (p. 341)	Xanthogranulomatous cholecystitis (p. 344)
Lymphoma, metastasis, abscess (p. 341)	Chronic cholecystitis (p. 344)
	Porcelain gallbladder (p. 344)
	Emphysematous cholecystitis (p. 345)

### Hypochoic or Complex Wall Changes

- ▶ **Acute cholecystitis** (Figs. 492 and 493): The differential diagnosis of acute cholecystitis includes chronic cholecystitis, wall thickening due to adenomyomatosis, scirrhous carcinoma, malignant lymphoma (= intrinsic factors), acute hepatitis and pancreatitis, liver cirrhosis with ascites
  - Hypochoic layered or stratified wall



**Fig. 492a–c** Acute cholecystitis. **a** Hypochoic layered wall following ERCP. No evidence of stones. Gallbladder is hydroptic with incipient sedimentation (“stress gallbladder”). **b** Very hypochoic wall thickening (cursors) with a small amount of free fluid (FL). **c** CDS: inflammatory wall vascularity is clearly demarcated from a pericholecystic area of avascular edema

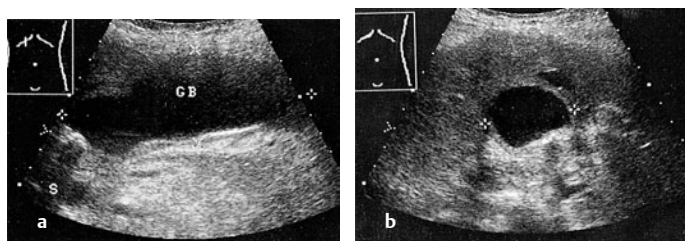


Fig. 493a, b Acute cholecystitis with hydrops (GB, cursors). Length > 8 cm, width and depth > 4 cm, rarefied wall structure. Local tenderness to compression (Murphy's sign), together with the obstructing stone in the infundibulum, confirm the presence of hydrops. S = acoustic shadows

- Stone detection (except in acalculous cholecystitis; causes: traumatic, weakened immune status due to chemotherapy, septic hematogenous, abscess formation)
- Possible associated features: hydrops, empyema, pericholecystic free fluid (Fig. 492c)
- ▶ **Wall thickening due to hepatic or pancreatic disease, AIDS, or trauma** (Fig. 494; Figs. 500–502, p. 344):
  - Thickened wall with a layered or complex structure
  - With portal hypertension: intramural vascularity (Fig. 494d)

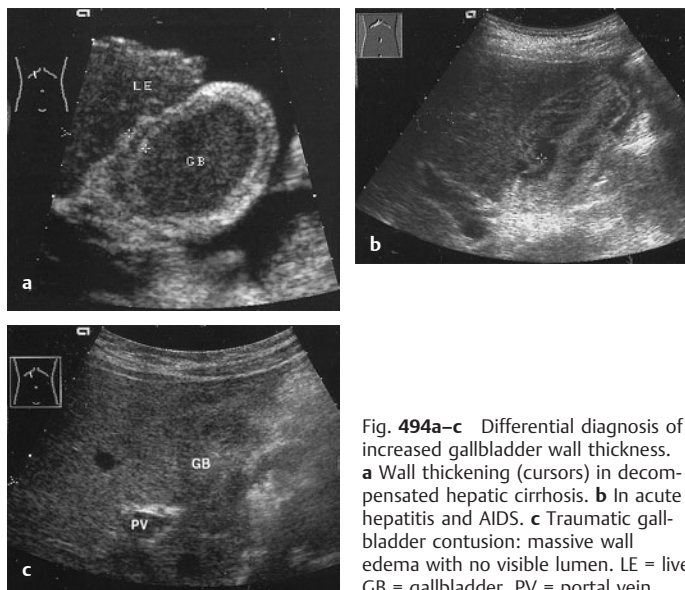

Fig. 494a–c Differential diagnosis of increased gallbladder wall thickness. **a** Wall thickening (cursors) in decompensated hepatic cirrhosis. **b** In acute hepatitis and AIDS. **c** Traumatic gallbladder contusion: massive wall edema with no visible lumen. LE = liver, GB = gallbladder, PV = portal vein

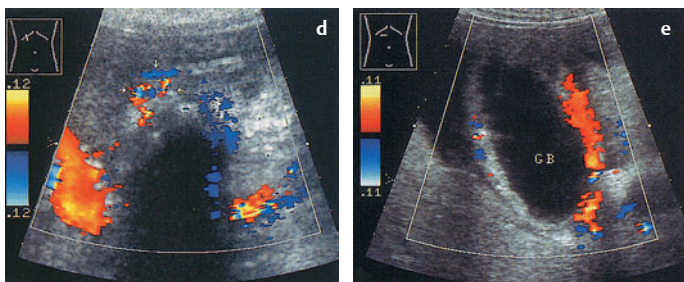


Fig. 494d, e Differential diagnosis of increased gallbladder wall thickness. **d** In portal hypertension. CDS: portosystemic collaterals in the gallbladder wall. **e** In cholecystolithiasis. CDS: stone shadow behind a wall thickened to 8 mm. Aberrant “spot-like” tumor vessels (arrows). Histology: carcinoma.

- ▶ **Wall edema** (Fig. 494a, p. 346): Possible causes are right heart failure, ascites in hepatic cirrhosis, and hypalbuminemia (= extrinsic factors). Does not occur with malignant ascites
  - Uniformly hypoechoic, layered wall
  - Frequent gallbladder congestion
- ▶ **Wall abscess** (Fig. 495):
  - Intramural hypoechoic or anechoic mass in a splayed wall
  - Signs of acute cholecystitis

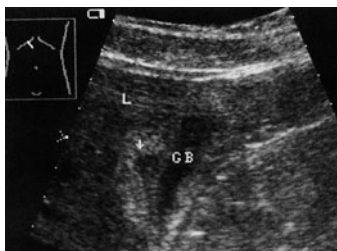

Fig. 495 Wall abscess (arrow) in acute cholecystitis. Scan shows markedly edematous segments of the gallbladder wall. GB = gallbladder, L = liver

- ▶ **Carcinoma infiltrating the gallbladder wall** (Fig. 496): stage I when confined to the gallbladder, stage II with extension past the gallbladder boundaries, stage III with infiltration outside the gallbladder
  - Hypoechoic, circumscribed intramural or polypoid area of wall thickening
  - Infiltration
- ▶ **Lymphoma, metastasis, abscess:**
  - Neoplastic wall thickening
  - Possible pericholecystic spread
  - Metastasis is indistinguishable from primary gallbladder carcinoma (Fig. 496).

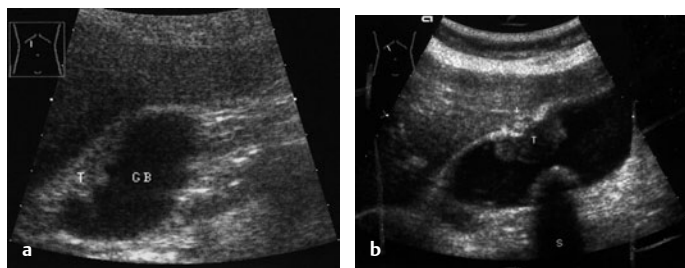


Fig. 496a, b Carcinoma of the gallbladder. **a** Early carcinoma appears as a broad-based, polypoid tumor mass (T) within the gallbladder (GB). **b** Stage II–III gallbladder carcinoma (T), already infiltrating the wall and starting to invade the liver (arrow). Stone with acoustic shadow (S)

### Echogenic Wall Changes

#### ► Duplicated gallbladder (Fig. 497):

- Echogenic, longitudinally oriented, septum-like compartmentalization
- This results in a second lumen with a wall and second cystic duct (definable by ERCP).

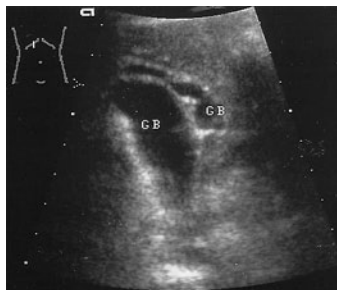

Fig. 497 Duplicated gallbladder (GB, GB). The smaller moiety of the duplicated gallbladder is bounded by a complete, echogenic wall extending to the second cystic duct (second duct not shown here)

#### ► Flexion creases, septa (Fig. 498):

- Surface indentation with a normal layered wall structure
- *With flexion creases:* kinked gallbladder
- *With true septa:* echogenic connective-tissue membranes (subdividing the lumen into two or more communicating spaces). Complete longitudinal septation can mimic a duplicated gallbladder. The differential diagnosis includes Heister valves in the gallbladder neck and cystic duct.

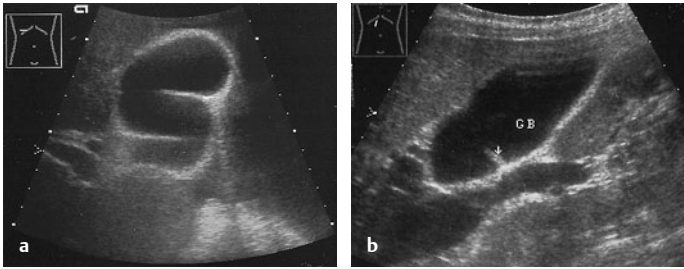


Fig. 498a, b Flexion creases vs. true septa. **a** Flexion creases impart an S shape to the gallbladder. A scan directed through the creases appears to show separate compartments. The creases may partially resolve when the patient is repositioned. **b** True septa (arrows) remain constant with position changes. Differential diagnosis: Heister valves

► **Cholesterosis** (cholesteatosis, Fig. 499):

- Multiple or occasionally solitary echogenic foci on the gallbladder wall (“stippled gallbladder”)
- No acoustic shadows, but reverberations are usually present

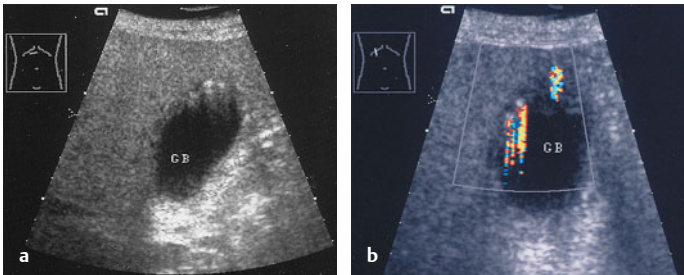


Fig. 499a, b Cholesterosis (cholesteatosis): segments of patchy echogenic wall change with reverberations. **a** B-mode image. **b** CDS: twinkling artifacts in the reverberations

► **Adenomyomatosis** (Fig. 500): hyperplasia of the mucosa, hypertrophy of the muscular layer, cholesterol deposits, and the formation of mural diverticula (Rokitansky–Aschoff sinuses)

- Segmental wall thickening (“hourglass gallbladder,” fundic myomatosis) or diffuse wall thickening
- Echogenic cholesterol specks with reverberations
- Small mural diverticula (Rokitansky–Aschoff sinuses)

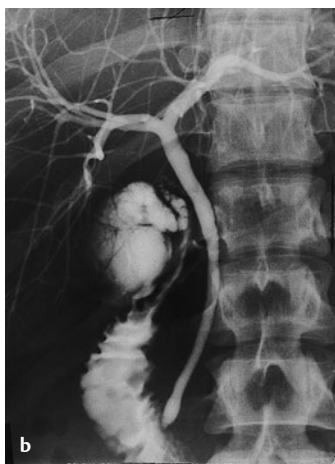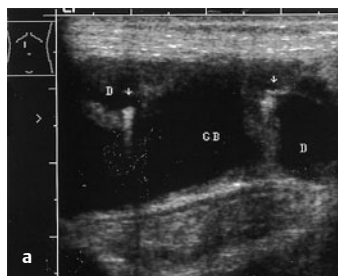


Fig. 500a, b Adenomyomatosis.  
**a** Segmental or diffuse wall thickening, diverticula (D), and echogenic cholesterol deposits (arrows).  
**b** ERC radiograph shows very fine diverticula with indistinct margins

- ▶ **Xanthogranulomatous cholecystitis** (Fig. 501): This entity, like cholesterosis and adenomyomatosis, belongs to the category of “cholecystoses.” Its sonographic features are nonspecific and similar to those of adenomyomatosis and cholesterosis. Patients present clinically with local tenderness and signs of inflammation.
  - Thickening of the gallbladder wall by an inflammatory mass (arising from small, inflamed mural diverticula?)
  - Possible echogenic cholesterol deposits, reverberations

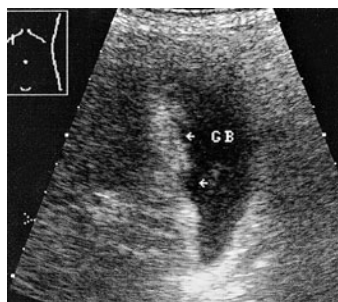

Fig. 501 Xanthogranulomatous cholecystitis: “circumscribed tumor-like thickening of the gallbladder wall (arrows). GB = gallbladder

- ▶ **Chronic cholecystitis** (Fig. 502):
  - Diffuse or circumscribed echogenic wall thickening
  - Detection of stones
  - Possible decrease in gallbladder size (shrunken gallbladder)
- ▶ **Thickened echogenic wall in ascites**: “Blooming effect” due to echo saturation, as in malignant ascites with acoustic enhancement along the gallbladder wall
- ▶ **Porcelain gallbladder** (Fig. 503): partial or complete calcification of the gallbladder wall, considered a premalignant lesion that requires operative treatment

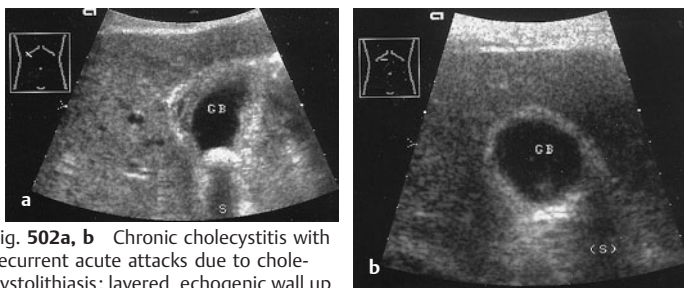


Fig. 502a, b Chronic cholecystitis with recurrent acute attacks due to cholelithiasis: layered, echogenic wall up to 9.8 mm in thickness (cursors). **a** Oblique longitudinal scan. **b** Transverse scan. (S) = incomplete acoustic shadow behind the hyperechoic wall

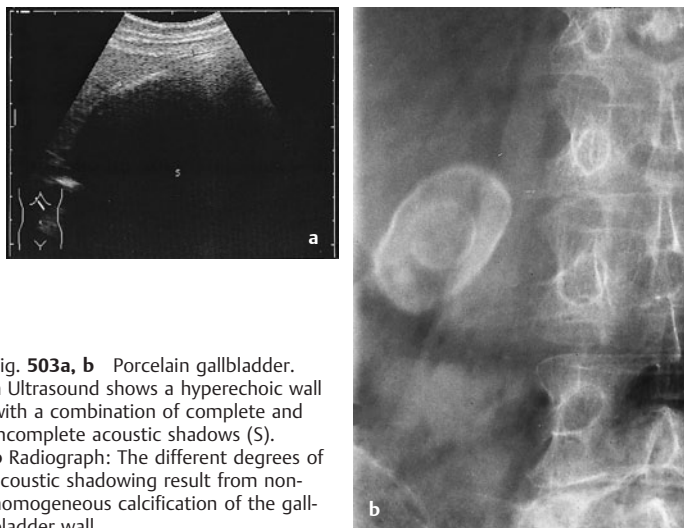


Fig. 503a, b Porcelain gallbladder. **a** Ultrasound shows a hyperechoic wall with a combination of complete and incomplete acoustic shadows (S). **b** Radiograph: The different degrees of acoustic shadowing result from non-homogeneous calcification of the gallbladder wall

- Wall intensely echogenic as a result of circumscribed or diffuse calcium encrustation
- Complete or incomplete distal acoustic shadowing
- ▶ **Emphysematous cholecystitis** (Fig. 504): common in diabetes, requires immediate operative treatment
  - Smooth wall with high-amplitude echoes caused by bacterial gas formation
  - Reverberations
  - Plus findings characteristic of a stony gallbladder. May be mistaken for pneumobilia or a porcelain gallbladder (Figs. 503, 504)

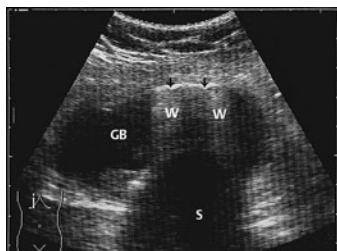

Fig. 504 Emphysematous cholecystitis: hydroptic gallbladder (GB) with stones and acoustic shadowing (S). Reverberations (W) arise from echogenic air bubbles on the anterior wall (arrows)

## 14.4 Intraluminal Changes

### Overview (Table 59):

Table 59 · Intraluminal changes in the gallbladder

Nonshadowing	Shadowing	Complex echo pattern
Sludge (p. 346)	Gravel (p. 348)	Gallbladder carcinoma with a stone (p. 349)
Empyema, hydrops (p. 347)	Stones (p. 348)	Empyema with a stone (p. 349)
Cholesterol polyp (p. 347)	Stony gallbladder (p. 349)	Phlegmon (p. 350)
Adenoma (p. 347)	Pneumobilia (p. 349)	
Carcinoma (p. 348)		

### Intraluminal Changes without Acoustic Shadowing

- ▶ **Sludge** (Fig. 505): formation of bilirubin and cholesterol crystals (floating, polypoid, or tumor-like, depending on specific gravity), common in patients on parenteral nutrition. It results in stone formation.
  - Rounded, fungoid or flat layer of sediment that shows sluggish movement with position changes

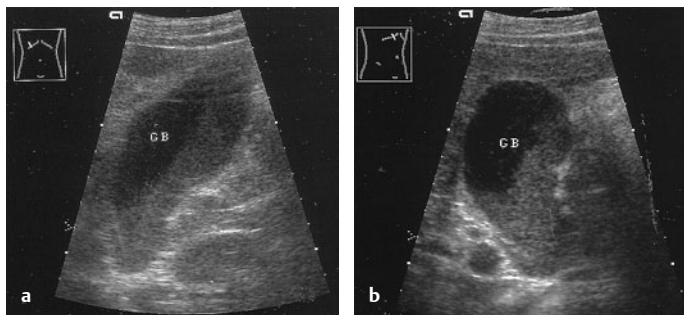


Fig. 505 a Sludge in the gallbladder (GB). b The echogenic sediment moves when the patient is repositioned

- *Individual crystal aggregates*: swirl on rapid rotation of the body
- *Sludge completely filling the lumen*: echogenic gallbladder
- ▶ **Empyema, hydrops** (see Fig. 493, p. 340, and Fig. 514, p. 350):
  - Enlarged gallbladder with slightly or markedly echogenic contents
  - Degree of enlargement: length > 80 mm, width > 40 mm
  - Local tenderness to palpation (Murphy's sign)
  - Gallstones usually present
- ▶ **Cholesterol polyp** (Fig. 506):
  - Round intraluminal mass adherent to the gallbladder wall
  - Size < 5 mm (size > 6 mm indicates a true neoplasm, and > 10 mm probably signifies the malignant transformation of gallbladder adenoma)
  - Usually echogenic with reverberations, sometimes hypoechoic

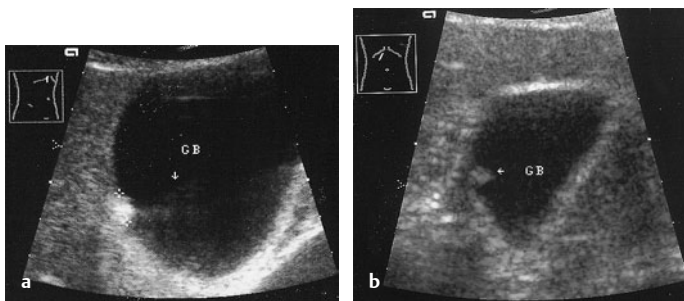


Fig. 506a, b Cholesterol pseudopolyps. **a** Echogenic, intraluminal protuberant mass on the gallbladder wall (cursors; arrow: side-lobe artifact). **b** Hypoechoic sessile polyp (arrow) on the gallbladder wall. Must be differentiated from adenoma

- ▶ **Gallbladder adenoma** (Fig. 507): tumor > 6 mm based on the gallbladder wall. Lesions  $\geq$  10 mm require close follow-up, and surgery may be considered. Lesions > 15 mm should always be extirpated as they often signify malignant change.

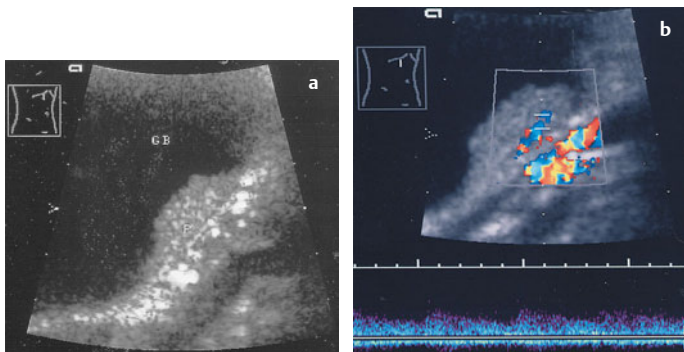
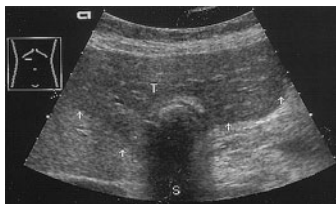

Fig. 507a, b Gallbladder adenoma. **a** Hyperechoic mass (P) in the gallbladder (GB). The tumor is broadly adherent to the gallbladder wall but does not infiltrate it. **b** CDS: Spectral analysis reveals an intratumoral vessel. Additional color flow signals: vena cava

- Round or lobulated, polypoid (papillomatous) tumor
- Adherent to the gallbladder wall, usually by a broad base
- Does not infiltrate the gallbladder wall
- Does not cast an acoustic shadow
- CDS: intratumoral vessels

► **Carcinoma** (Fig. 508):

- Polypoid mass occupying all or part of the gallbladder lumen (lesions > 33 mm are almost always invasive cancers)
- Mottled hypoechoic structure
- Often shows infiltrative growth (liver) with ill-defined margins
- Stones are usually present
- CDS: sparse vascularity

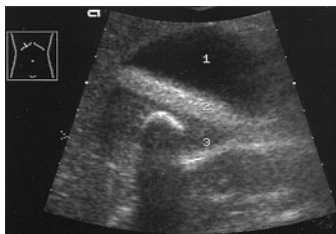

**Fig. 508** Gallbladder carcinoma (T, arrows): hypoechoic, nonhomogeneous mass that completely occupies the gallbladder lumen (stage II). Stone echo with a distal shadow (S)

### Intraluminal Changes with Acoustic Shadowing

► **Gravel** (Fig. 509):

- Collection of fine granular echoes with no definable stone echo
- Summation acoustic shadowing



**Fig. 509** Gallbladder contents: anechoic (1) = anechoic bile; hypoechoic (3) = sludge; high-amplitude granular echoes (2) = gravel (often with a faint zone of acoustic shadowing). Echogenic = stone echo with a distal shadow

► **Stones** (Figs. 509–511):

- Very echogenic focus with a distal acoustic shadow
- Movement in response to position changes (“rolling stones”)
- Intraluminal mass
- **Complications:**
  - **Cholecystitis:** inflammatory wall thickening, local tenderness (see Fig. 492, p. 339)
  - **Hydrops:** gallbladder enlarged to > 80 mm long and > 40 mm wide; tender, palpable mass (see Fig. 493, p. 340)
  - **Empyema** (see Fig. 514, p. 350)

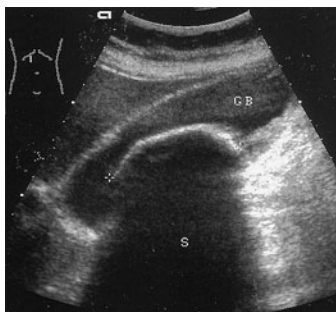


Fig. 510 Large, solitary, oblong stone (cursors, 62.5 mm) in the gallbladder (GB). The high-amplitude entry echo ("calcium stone," cursors) casts a dense acoustic shadow (S) that obscures the rest of the stone

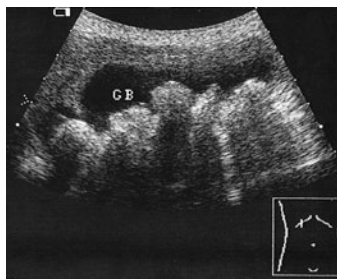
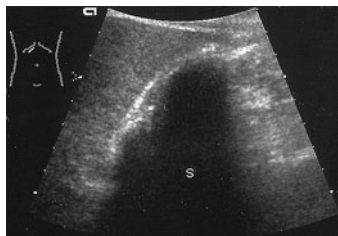

Fig. 511 Cholesterol gallstones: soft, rounded masses in the gallbladder (GB) that show some degree of through-transmission and cast incomplete distal acoustic shadows

► **Stony gallbladder** (Fig. 512):

- Stone-filled gallbladder
- Dense acoustic shadowing from the anterior surfaces of the stones
- Summation acoustic shadows obscure the rest of the gallbladder (differential diagnosis: large, solitary gallstone; porcelain gallbladder; emphysematous cholecystitis)
- *Differentiation from emphysematous cholecystitis* (see Fig. 504, p. 346): The gas bubbles in the inflamed gallbladder cause echoes with reverberations that distinguish emphysematous cholecystitis from pneumobilia (see below) and from wall-adherent stones.

Fig. 512 Stony gallbladder. Differential diagnosis: porcelain gallbladder and a large, solitary gallstone. There is no detectable fluid medium. Multiple echoes from the stone surfaces cast a summation acoustic shadow (S). Frequently, individual stone echoes can be identified in a zoomed image



- **Pneumobilia** (air bubbles following papillotomy): string-of-beads echoes located behind the anterior wall in the supine position, show movement with position changes

### Intraluminal Changes with a Complex Echo Pattern

- **Sludge with stones or gravel:** See Fig. 509, p. 348.
- **Gallbladder carcinoma with a stone:** See Fig. 513.
- **Empyema with a stone:** See Fig. 514.

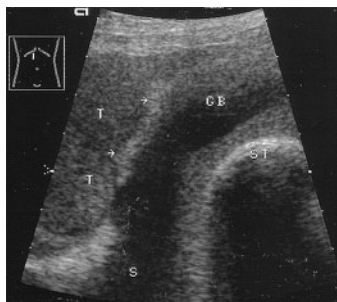


Fig. 513 Gallbladder (GB) carcinoma: complex structure in a partial porcelain gallbladder with a stone (ST) and sludge. The tumor has infiltrated the liver (T). ST = stone

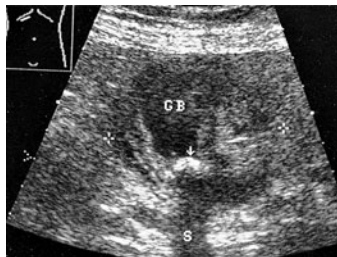

Fig. 514 Gallbladder empyema (GB): hydrops (cursors), phlegmonous wall structure, and a stone (arrow) with a distal acoustic shadow (S)

► **Phlegmons with wall thickening or detachment:**

- Features of empyema
- Bizarre outline of the thickened gallbladder wall
- Intramural abscesses
- Echogenic intraluminal bands (detached mucosa)

## 14.5 Evaluation and Further Testing

### Sonography

- **Diagnostic accuracy:** Because of the fluid medium in the gallbladder, ultrasound can detect intraluminal lesions as small as 1 mm with up to 100% accuracy.
- **Limitation:** Intercostal scanning is required (problematic in patients with bowel obstruction, postoperative patients, patients with a high or paralyzed diaphragm, postprandial examinations, overlying colon gas, or a shrunken gallbladder).
  - **Stone detection:** successful in virtually all cases where an echo, acoustic shadow, and mobility can be demonstrated. The diagnostic accuracy falls to 95% or considerably less in the case of smaller, nonshadowing stones. The accuracy rate is only about 65% for detecting stones in the infundibulum or fornix and detecting sediment in the gallbladder body.
  - **Identifying the type of stone:**
    - Very echogenic focus with a dense acoustic shadow → calcium stone
    - Less echogenic focus with through-transmission of sound and a partial acoustic shadow → cholesterol stone
    - Floating stone after radiographic contrast administration → cholesterol stone. Stone impacted in inspissated bile with internal echoes → empyema. A specific tissue diagnosis cannot be made.
  - Gallbladder carcinoma with locoregional metastasis and complications (cholestasis) can be correctly diagnosed in more than 90% of cases.
  - Polyps as small as 2 mm can be correctly identified when special scanning maneuvers are used. Some polyps are difficult to distinguish from small stones.

- *Acute cholecystitis*: When ultrasound findings are consistent with the history, clinical picture, and laboratory findings, no further preoperative tests are needed.

▶ **Errors of interpretation:**

- *Crystal aggregates, microliths*: oblong polygonal echoes, <1–2 mm, nonshadowing, with echogenic sediment. Swirling of the particles in response to rapid rotation is the only means of identification (see Fig. 505, p. 346).
- *Serous fluid collection*: A serous fluid collection after cholecystectomy is occasionally misinterpreted as the gallbladder, ascites, or cholecystitis.
- *Air in the stomach or colon*: can mimic stones and wall thickening. The distal gallbladder wall adjacent to the stomach or bowel should not be interpreted as thickened (Fig. 515).

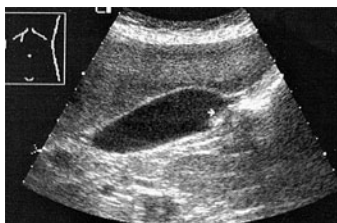

Fig. 515 Stones in the gallbladder fundus (arrow), poorly visualized due to surrounding colonic gas. Aids to visualization: slow or rapid position changes, repeating the examination

▶ **Differential diagnosis:**

- *Intraluminal changes*: Repositioning the patient aids in differentiating these changes as sludge, stones, or polyps.
- *Polyps*: unlike stones, these are adherent to the wall and have intramural vessels.
- *Stones*: distal acoustic shadows, mobility
- *Seroma, hematoma*: Hypoechoic or echogenic structures after cholecystectomy may be mistaken for the gallbladder (“pseudo-gallbladder”); debris and echogenic metal clips may be mistaken for gallstones (see Figs. 643 and 644, p. 431).

## Further Testing

- ▶ **Diagnosis of stones**: There are several situations in which ultrasound may be followed by CT scanning (accuracy rate of 70–80%) to establish the diagnosis:
  - Stones in the infundibulum
  - Echogenic stone sediment
  - Stones in the gallbladder fundus (look out for colonic air)
- ▶ **Empyema, abscess, sludge**: When extremely viscous, these lesions are often indistinguishable from a tumor. They can be investigated further by CT and MRI, but generally they can be positively identified only at operation.
- ▶ Chronic cholecystitis, especially in a porcelain gallbladder, is a premalignant condition requiring operative treatment.
- ▶ **Suspected tumor**: fine-needle aspiration cytology.

## 15 Gastrointestinal Tract

### 15.1 Examination

#### Scan Planes

- ▶ Upper abdominal transverse scan (see p. 22)
- ▶ Left subcostal oblique scan (see p. 27)
- ▶ Lower abdominal transverse scan (see p. 30)
- ▶ Upper abdominal longitudinal scan (see p. 29)
- ▶ Lower abdominal longitudinal scan (see p. 31)
- ▶ Scan planes tailored to specific findings (oblique lower abdominal scans)

#### Sonographic Anatomy and Normal Findings

- ▶ **Wall structure** (Table 60): All walls in the gastrointestinal tract are composed histologically of four layers. The serosa of the peritoneum provides a fifth layer investing the stomach and bowel.

**Table 60** · Layers comprising the walls of the gastrointestinal tract

Mucosa (with epithelial layer)

Muscularis mucosae (muscular layer of the mucosa)

Submucosa

Muscular coat

Serosa (with subserosa)

- ▶ **Esophagus:** Only two parts of the esophagus can be visualized as target patterns in upper abdominal longitudinal scans: the cervical part of the esophagus posteromedial to the left lobe of the thyroid gland and the cardiac part between the aorta and liver.
- ▶ **Stomach** (Table 61 and Fig. 516): Almost all parts of the stomach can be visualized with ultrasound.

**Table 61** · Positions for scanning specific parts of the fluid-filled stomach

Part of stomach	Scanning position
Fornix	Head lowered, left lateral decubitus
Body	Head raised, left lateral decubitus
Antrum	Head raised, supine
Greater curvature	Standing
Pylorus and duodenal bulb	Head raised, right lateral decubitus

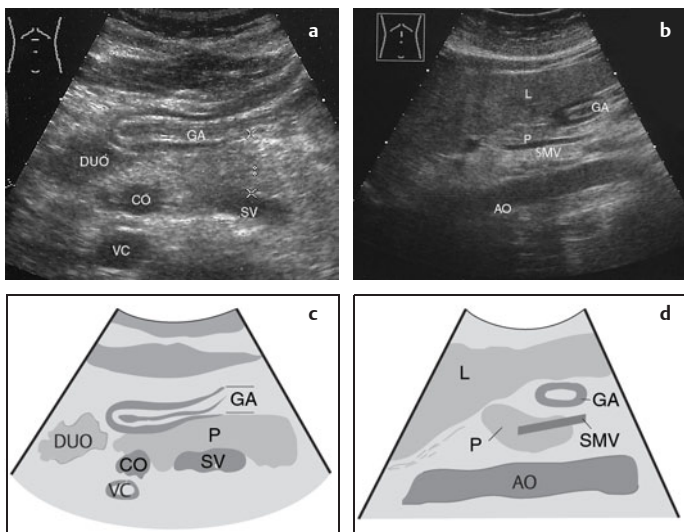


Fig. 516a–d Sonographic appearance of the stomach. **a, c** Upper abdominal transverse scan: gastric antrum (GA) with hypoechoic muscular coat, echogenic submucosa, and inner hypoechoic mucosa. Section of the fluid-filled duodenum (DUO). Posterior to the stomach are the pancreas and pancreatic duct (cursors). CO = venous confluence, P = body of pancreas, SV = splenic vein, VC = vena cava. **b, d** Upper abdominal longitudinal scan: gastric antrum (GA) appears as an elliptical figure. AO = aorta, L = liver, P = body of pancreas, SMV = superior mesenteric vein

- ▶ **Small intestine:** The wall of the small intestine is extremely difficult to define, and the bowel loops are often superimposed, making it impossible to analyze the walls of a healthy organ. (When the small intestine is distended because of partial or complete obstruction, it displays a typical “keyboard sign,” Fig. 517.) The terminal ileum is located by scanning left from the cecal pole (moves anterior to the psoas muscles with respiratory excursions) and looking anterior to the iliac vessels.

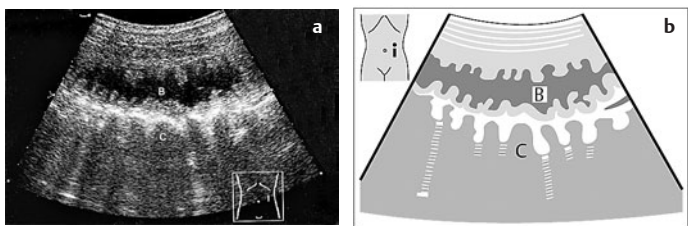


Fig. 517a, b Small-bowel obstruction with clearly delineated circular folds (“keyboard sign”). B = small bowel; C = colon, identified by its haustrations

- ▶ **Large intestine** (Fig. 517): The course of the large intestine can be traced upward from the cecum, across the transverse colon, and down to the sigmoid colon and rectum. Typical haustra and folds can be identified in most cases.

### Scanning Protocol

- ▶ **Transducer:** 5.0 MHz. A 3.5 MHz transducer is better for general views and especially for evaluating the far posterior wall and fundus of the stomach.
- ▶ Generally the patient is supine, but special positions are occasionally used (see Table 61).
- ▶ The stomach is filled with 500–1000 mL of tea or water (ingested through a straw) to enable a precise analysis of the wall layers. If necessary, 20 mg of butylscopolamine (hyoscine butylbromide) may also be administered by i.v. injection.
- ▶ Digital or probe compression is used to elicit tenderness that would indicate inflammatory change (diverticulitis, appendicitis).
- ▶ The terminal ileum can be imaged only with a high-frequency transducer and high-resolution system.
- ▶ To scan the appendix in patients with suspected appendicitis, first define the cecal pole and then, while applying gentle compression, look for a small target pattern (in transverse section) or a small hypoechoic band (in longitudinal section).

### Overview and Classification of Findings

- ▶ **Stomach:** The stomach is not an ideal object for ultrasound because of its acoustic properties. Nevertheless, it is possible not only to detect gross wall abnormalities such as tumors and severe inflammation but also to define the normal gastric wall and even the normal intestinal wall when a high-resolution scanner is used.
  - *Detectable with ultrasound:* functional disturbances and areas of wall thickening. Inflammatory gastrointestinal diseases lead to diffuse or long segmental masses and circumscribed foci of wall thickening. The location, extent, contours, and internal echo pattern supply information on the nature of the disease.
  - *Difficult to detect or undetectable with ultrasound:* inflammatory and ulcerative mucosal lesions, vascular changes such as angiodysplasia, hemorrhages, and small polyps (no acoustic impedance, “needle in a haystack”). Unlike endoscopy and radiography, sonography cannot give a continuous view of the gastric wall; it can define only localized segments.
- ▶ **Small intestine:** Functional disorders are most commonly diagnosed with ultrasound, followed by inflammatory bowel diseases (prototype: Crohn disease).
- ▶ **Large intestine:**
  - In ultrasound examinations of the large intestine, the main emphasis is placed upon the detection of intestinal tumors and colitis. Tumors generally appear as circumscribed lesions (“target sign”), whereas colitis (including appendicitis) appears as relatively long areas of segmental wall thickening.
  - The diagnosis of functional disorders (e.g., large-bowel obstruction) is usually prevented by pronounced gaseous distention of the intestine.
- ▶ **Classification and overview:**
  - *Stomach:* see Table 62, p. 355.
  - *Small intestine:* see Table 63, p. 360.
  - *Large intestine:* see Table 65, p. 366.

## 15.2 Stomach

### Overview (Table 62):

**Table 62** · Abnormal findings in the stomach (lesions difficult to detect with ultrasound are shown in parentheses)

Wall thickening		Luminal widening or narrowing
<b>Diffuse</b>	<b>Circumscribed</b>	
Wall edema (p. 355)	Pyloric stenosis (p. 357)	Impaired gastric emptying (p. 359)
Chronic type B gastritis (p. 356)	(Pyloric stenosis, p. 357)	Cicatricial stricture or inflammatory stenosis (p. 359)
Ménétrier disease (p. 356)	Varices (p. 357)	Tumor-related stenosis (p. 359)
Infiltrating carcinoma (p. 356)	Gastric ulcer, ulcerated carcinoma (p. 357)	
Malignant gastric lymphoma (p. 356)	(Benign tumors, p. 357)	
	Early-stage malignant tumor, metastases (p. 358)	
	Gastric carcinoma (p. 358)	
	Malignant gastric lymphoma (p. 359)	
	(Leiomyoma, neurinoma), gastrointestinal stromal tumor (GIST, p. 359)	

### Diffuse Wall Thickening

- ▶ **Edematous wall swelling** (Fig. 518): swelling of the antral mucosa secondary to acute pancreatitis. Similar hypoechoic wall swelling occurs in nephrotic syndrome, protein deficiency disorders, and congestive heart failure.
- ▶ **Smooth, hypoechoic, homogeneous wall thickening** (> 7 mm):
  - *Differential diagnosis:* wall thickening associated with a contraction wave

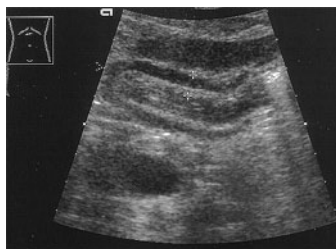
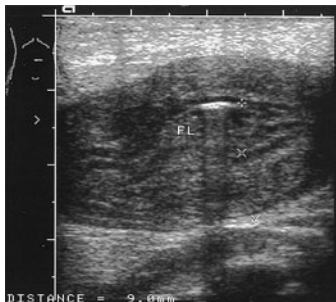
Fig. 518 Swelling of the gastric wall (7.2 mm, cursors) in acute pancreatitis

► **Inflammatory and hyperplastic wall swelling (Fig. 519):**

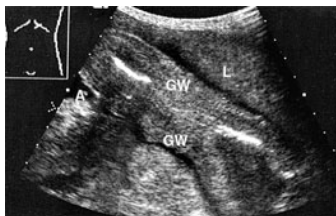
- *Chronic, severe Helicobacter pylori-positive type B gastritis:*
  - Mild to moderate thickening or hyperplasia of the rugal folds
  - Folds often up to 20 mm thick, with clear delineation of the crests and valleys
- *Ménétrier disease:* hyperplasia of the rugal folds (same as in severe type B gastritis)



**Fig. 519** Severe type B gastritis: markedly thickened gastric wall with a distinct layered structure (hypoechoic–hyperechoic–hypoechoic, cursors). The lumen is mostly obliterated except for a small, high-amplitude air echo and some fluid (FL)

► **Diffuse neoplastic wall swelling:**

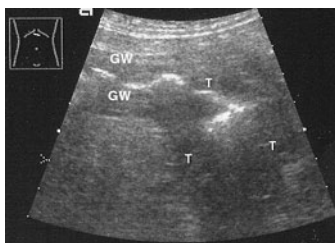
- *Diffusely infiltrating carcinoma (Fig. 520):*
  - Circumferential swelling of a long wall segment
  - Rigid, hypoechoic wall
  - Nondelineation of the normal wall layers
  - Absence of peristalsis
  - Possible locoregional or distant metastases
  - CDS: aberrant tumor vessels



**Fig. 520** Diffuse gastric carcinoma: long segmental wall thickening (GW) with high-grade luminal narrowing. The walls show indistinct boundaries with loss of normal stratification and peristalsis. A = ascites, L = left lobe of liver

- *Diffuse malignant gastric lymphoma (MALT-NHL, Fig. 521):* Tissue derived from mucosa-associated lymphatic tissue (MALT) as a result of type B gastritis
  - Very hypoechoic wall swelling due to tumor infiltration of the stomach wall
  - Nondelineation of the normal wall layers. In rare cases, rugal folds may still be definable (similar to severe gastritis).
  - Marked to severe luminal narrowing or obliteration

Fig. 521 Diffuse malignant gastric lymphoma (T, GW). Hypoechoic scalloped tumor mass greatly narrows the gastric lumen, which shows a loss of normal wall layers



### Circumscribed Wall Thickening

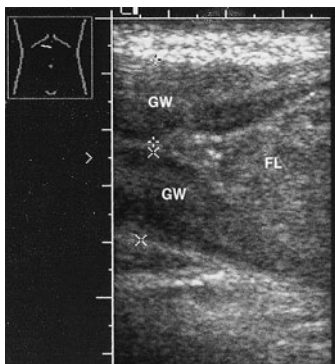
#### ► Congenital hypertrophic pyloric stenosis:

- Pyloric muscular hypertrophy in the upper abdominal transverse scan (“cervix sign” seen in a longitudinal section of the pylorus)
- Delayed gastric emptying visible on ultrasound
- Hyperperistalsis and reverse peristalsis

#### ► Acquired pyloric stenosis (Fig. 522): inflammatory, ulcerative (difficult to detect directly with ultrasound, usually noted indirectly from gastric atony), or neoplastic

- Rigid pyloric wall
- Increased fluid or food residues (anechoic interior, fine homogeneous echo pattern, or coarse internal echoes). Movements can be seen by prolonged observation, tilting the table, or repositioning the patient.

Fig. 522 Malignant pyloric stenosis (cursors) caused by signet-ring cell carcinoma. The lumen is obliterated by neoplastic thickening of the antral wall (GW, cursors). There is still slight evidence of a layered wall structure. Note the prestenotic dilatation with flocculent echogenic contents (FL)



#### ► Varices:

- Anechoic or cyst-like thickened areas on the outer gastric wall
- CDS: hepatofugal and portosystemic flow

#### ► Gastric ulcer, ulcerated carcinoma (Borrmann type III, Fig. 523):

- Crater-like depression in the luminal surface of the thickened wall

#### ► Benign tumors: Benign epithelial tumors (polypoid adenomas) are often undetectable with ultrasound because of their small size, or are detectable only in the fluid-distended stomach. Mesenchymal tumors (leiomyomas, neurinomas) may reach considerable size, growing large enough to be detected with ultrasound.

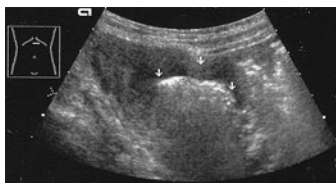

Fig. 523 Ulcerated gastric carcinoma (arrows). The broad ulcer base, clearly defined here by air echoes, appears as a convex echogenic band in the hypoechoic, tumor-involved gastric wall

- Rounded hypoechoic mass with smooth margins
- No metastases
- ▶ **Malignant tumors** (early stage): gastric metastases (e.g., from malignant melanoma):
  - Irregular rounded or lobulated wall thickening
- ▶ **Gastric carcinoma** (Figs. 524 and 525): Statistically, tumor thickness averages 16 mm
  - *Polypoid carcinoma*: lobulated mass
  - *Circumferential carcinoma*: typical round or oval figure with an echogenic center of air and mucus (target sign). Possible metastases
  - CDS: tumor angiogenesis

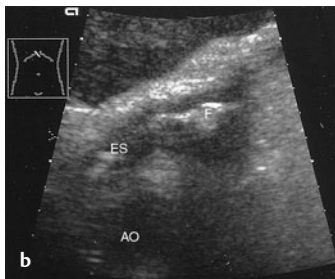
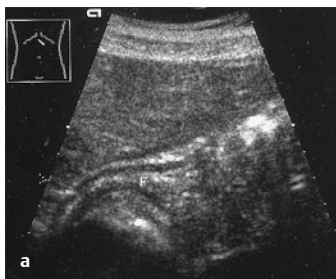
Fig. 524a, b Gastroesophageal junction (involving the cardia and gastric inlet). **a** Oblique longitudinal scan through the upper abdomen shows the normal hypoechoic wall (muscular coat) of the cardia and fornix. **b** Gastric cardia carcinoma: irregular, hypoechoic tumor mass extending from the cardiac part of the esophagus (ES) to the fornix (F). AO = aorta

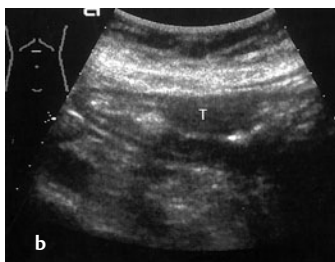
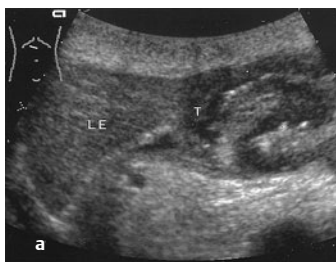

Fig. 525a, b **a** Gastric carcinoma: antral tumor (T) with a complex echo pattern. **b** Polypoid tumor (T), identified histologically as a carcinoid

- ▶ **Malignant gastric lymphoma:** has the same appearance as diffuse lymphoma (see above) or gastric carcinoma
- ▶ **Mesenchymal tumors:** leiomyoma, neurinoma, gastrointestinal stromal tumors (GIST)
  - **Benign:**
    - < 6 cm
    - No detectable vascularity
  - **Malignant (Fig. 526a, b):** Leiomyosarcoma, GIST
    - Usually > 6 cm
    - Tumor vascularity
    - Possible metastases

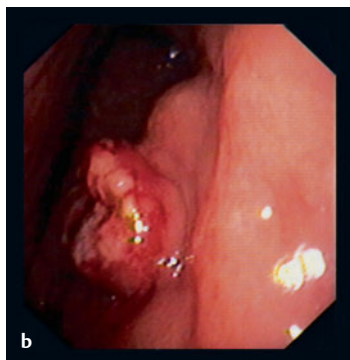
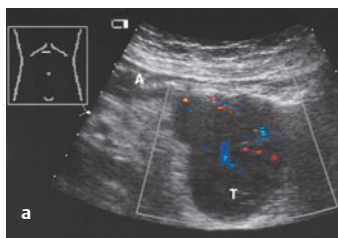


Fig. 526a, b **a** Flat, asymmetrical polypoid tumor (T) deeply invading and transgressing the gastric wall: gastrointestinal stromal tumor (GIST), in this case malignant and already metastasized. A = antrum. **b** Endoscopic appearance. Biopsies were negative

### Luminal Widening or Narrowing

- ▶ **Impaired gastric emptying due to bowel obstruction or diabetic gastroparesis:**
  - Distended, fluid-filled stomach with no wall changes
- ▶ **Mechanical outflow obstruction:**
  - *Cicatricial stricture or inflammatory stenosis:* no significant wall thickening
  - *Tumor-related stenosis:* significant concentric wall thickening (see Fig. 522, p. 357)

### Evaluation and Further Testing

- ▶ **Sonography:** If the ultrasound beam is tangential to the gastric wall and encounters a series of multiple rugal folds, this may create the erroneous appearance of a thickened wall (Fig. 527). On the other hand, massive wall swelling may be missed, even in a patient with clinical manifestations (anorexia, weight loss, bloating, aversion to roasted foods), if all portions of the stomach are not visualized (left subcostal oblique scan to evaluate the body of the stomach, high paramedian longitudinal scan over the aortic hiatus to demonstrate the cardia and gastric inlet; see Fig. 524).
- ▶ **Gastroscopy with biopsies** (may include loop biopsy) is indicated:
  - Whenever ultrasound detects wall thickening (e.g., in Ménétrier disease, chronic gastritis, carcinoma, lymphoma)

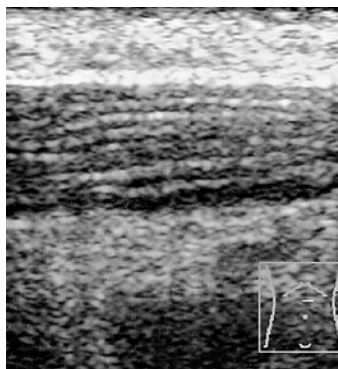


Fig. 527 Multiple rugal folds can mimic wall thickening when they are tangential to the ultrasound beam

- Even if findings suggest a benign tumor (smooth surface, marginal folds, folds lifted with a forceps for a submucosal lesion)
- ▶ **CT or endosonography:** used for tumor staging or to evaluate tumor extent in cases where ultrasound findings are equivocal. Locoregional metastases are generally detected at an early stage.

## 15.3 Small Intestine

### Overview (Table 63):

**Table 63** · Abnormal findings in the small intestine

Functional disorders	Thickening of the bowel wall	
	Long segmental thickening	Circumscribed thickening
(Gastro)enteritis	Crohn disease of the terminal ileum (p. 363)	Benign tumors of the small intestine (adenoma, leiomyoma, p. 365)
Sprue (p. 361)	Acute febrile enteritis (p. 364)	Malignant tumors of the small intestine (duodenal carcinoma, carcinoid, p. 365)
Autonomic diabetic neuropathy (p. 361)	Small bowel hematoma (p. 365)	
Partial or complete mechanical bowel obstruction (p. 361)	Mesenteric vascular occlusion (p. 365)	
Intussusception (p. 362)	Amyloidosis (p. 365)	
Partial or complete paralytic ileus (p. 362)		

## Functional Disorders

### ▶ (Gastro)enteritis (Fig. 528a):

- Secretory fluid collection
- Increased intraluminal bowel contents, may be anechoic to echogenic (depending on the contents)
- Dilated bowel loops
- Hyperperistalsis
- Accentuated wall

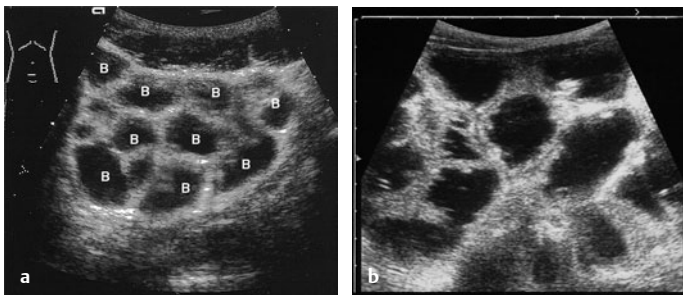


Fig. 528a, b Functional disorders of the small intestine. **a** Acute enteritis: fluid-filled bowel loops (B). **b** Sprue: the “washing machine” sign

### ▶ Sprue (Fig. 528b):

- Hypoechoic wall thickening (edema)
- Distention of the fluid-filled lumen
- *Real-time ultrasound*: “washing machine” sign

### ▶ Diabetic autonomic neuropathy (Fig. 529):

common in patients with a > 8 year history of diabetes, accompanied by other diabetic sequelae. Patients present clinically with refractory diarrhea and steatorrhea. Many cases show cardiopathy with tachycardia and peripheral neuropathies.

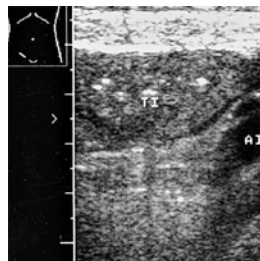
- Distended bowel loops
- Hypo- or hyperperistalsis

### ▶ Partial or complete mechanical bowel obstruction:

The bowel may be obstructed by adhesions, a gallstone or foreign body, etc. (Figs. 530 and 531; see also Figs. 110 and 111, p. 82, 83). The obstructed bowel may become strangulated as a result of intussusception or volvulus.

Fig. 529 Diabetic autonomic neuropathic enteropathy: dilated loops of terminal ileum (TI) with hyperperistalsis and no wall thickening. The patient had a long clinical history of type II diabetes mellitus with recurrent diarrhea.

AI = iliac artery



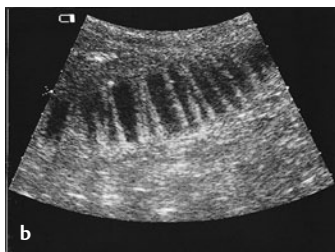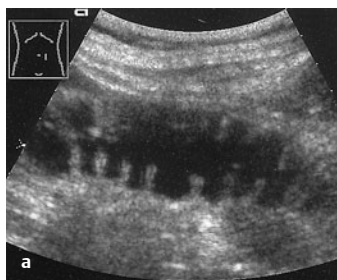


Fig. 530a, b Partial or complete bowel obstruction. a Fluid-filled bowel loops with a “keyboard sign.” b “Stepladder sign” of bowel obstruction

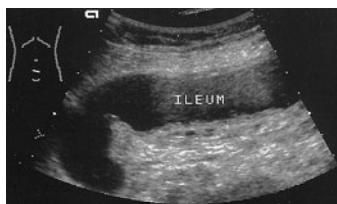

Fig. 531 Adhesive bowel obstruction: distended, fluid-filled terminal ileum. A keyboard or stepladder sign is not observed because of the absence of valvulae conniventes

- Dilated bowel loops
- Increased intraluminal fluid (anechoic to hyperechoic contents)
- As a rule, peristalsis is initially increased but later is diminished or absent (bidirectional peristalsis)
- “Keyboard sign” and “stepladder sign” (fluid-outlined valvulae conniventes in the jejunum). The bowel loops have a keyboard-like appearance when imaged in longitudinal section and a stepladder-like appearance when imaged tangentially (Fig. 530). Valvulae conniventes are absent in the ileum, where the dilated bowel loops present an essentially smooth inner surface (Fig. 531).
- Possible circumscribed free fluid
- *Obstruction by a gallstone or bezoar* (Fig. 112, p. 83): signs of obstruction proximal to the stenosis. The obstructing object can be identified as an intraluminal mass (stone: typical stone features with distal shadowing; bezoar: nonshadowing hypoechoic mass)
- *Obstruction due to intussusception*:
  - The telescoped bowel segments appear as concentric outer and inner hypoechoic rings with a hyperechoic middle ring (“target-in-a-target” pattern; common with polyps, tumors, and lymph nodes)
  - Slight wall thickening, possibly with a thin fluid rim
  - Absence of peristalsis in the intussusceptum
- ▶ **Partial or complete paralytic ileus** (see Fig. 114, p. 84):
  - ▣ **Caution:** Paralytic ileus is frequently associated with peritonitis.
    - Dilated, atonic bowel loops crowded close together
    - Echogenic contents
    - Peristalsis is usually absent
    - Bowel wall layers are delineated
    - Possible circumscribed free fluid

## Long Segmental Wall Thickening

### ► Crohn disease of the terminal ileum:

- *Clinical features:* diarrhea, pain in the right lower quadrant of the abdomen, elevated ESR; possible iron deficiency anemia, steatorrhea, vitamin B<sub>12</sub> deficiency, bile acid loss syndrome with chologenic diarrhea
- *Possible complications:*
  - Stenosis
  - *Fistula formation:* Fistulae may be enterocutaneous, enterovesical, enteromesenteric, or enterouterine
- **Caution:** Fistulae may also occur with intestinal tumors.
  - Hypochoic inflammatory mesenteric reaction
  - Abscess formation
  - Bowel obstruction
- *Sonographic findings* (Figs. 532–534):
  - Thickening of the terminal ileal wall to > 4 mm (for severity of inflammation, see Table 64)
  - Increased intraluminal fluid with wall thickening (fluid due to decreased absorption, unlike the secretory fluid collection in viral or bacterial enteritis)
  - Rigid bowel loop with absent or decreased peristalsis
  - Polypous inner wall with a “cobblestone” appearance

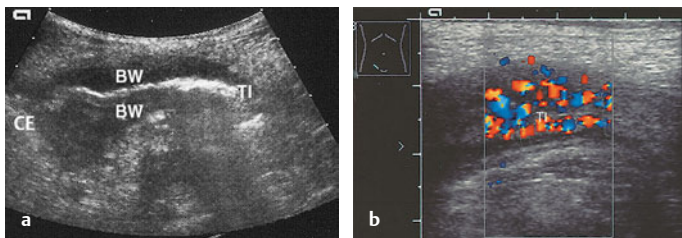


Fig. 532a, b Crohn disease of the terminal ileum (TI), highly active form with stenosis. **a** B-mode image: very hypochoic, swollen bowel walls (BW) with obliterated wall layers. CE = cecum. **b** CDS: marked inflammatory vascularity

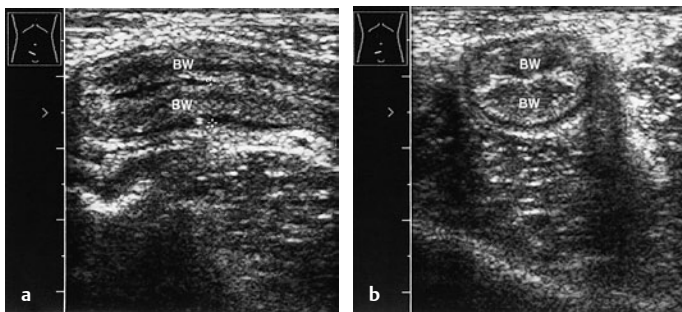


Fig. 533a, b Crohn disease: markedly thickened wall of the terminal ileum (cursors) with an echogenic middle layer (isoechoic to submucosa) and luminal narrowing. **a** Lower abdominal longitudinal scan, **b** transverse scan. BW = bowel wall

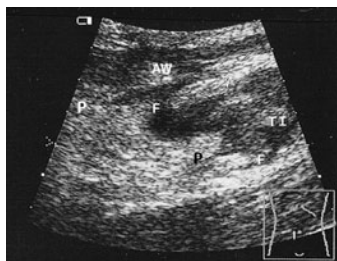

Fig. 534 Crohn disease of the terminal ileum: hypoechoic wall swelling (TI). Fistulous tracts (F), some terminating blindly, pass through the peritoneum (P) to the anterior abdominal wall (AW)

**Table 64 · Relationship of sonographic wall structure to the severity of inflammation in Crohn's disease**

Wall structure	Degree of inflammation
Accentuated	Mild inflammation
Echogenic layering with a broadened middle layer	Moderate inflammation
Hypoechoic wall with obliterated layers	Severe inflammation

- Frequent accompanying mesenteritis
- Signs of partial bowel obstruction
- Possible free fluid, lymphadenopathy
- CDS: color flow signals indicating inflammatory hyperperfusion (Fig. 532b)

► **Acute febrile enteritis (enterocolitis):**

- *Clinical features:* shows a predilection for the ileum but may also affect the jejunum. Acute right lower quadrant pain resembling appendicitis
- *Causative organisms:* viruses (especially rotaviruses), *Yersinia*, *Campylobacter*, staphylococci, salmonellae (invasive microbial pathogens such as *Shigella* in the colon)
- *Sonographic criteria* (Fig. 535; see also Fig. 544, p. 369):
  - Thickened wall with alternating hypoechoic, hyperechoic, and hypoechoic layers; often shows "gyration" and concomitant involvement of the cecal pole
  - Local tenderness to bowel compression
  - Local free fluid

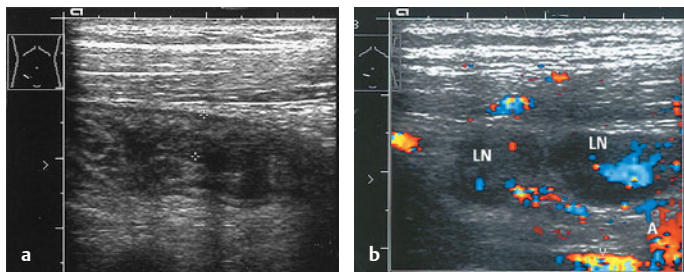


Fig. 535a, b Acute enteritis. **a** Swollen wall of the terminal ileum (cursors) with a distinct layered structure. **b** CDS: mesenteric lymph nodes (LN) anterior to the iliac artery and vein (A, V); mesenteric lymphadenitis

- Frequent enlargement of mesenteric lymph nodes (“mesenteric lymphadenitis”)
- CDS: inflammatory hypervascularity
- ▶ **Small-bowel hematoma** (Fig. 536): may result from anticoagulant medication or a hemorrhagic diathesis
  - Thickened bowel walls
  - Pronounced, very hypoechoic wall swelling with luminal narrowing (“garden hose” appearance)

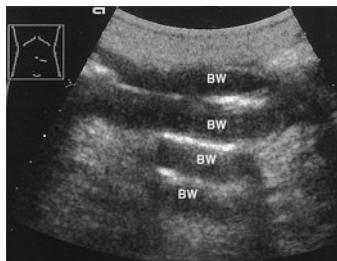


Fig. 536 Small-bowel hematoma in a patient on anticoagulant medication. Ultrasound shows intensely hypoechoic swelling of the bowel wall (BW)

- ▶ **Mesenteric vascular occlusion** (see also Fig. 115, p. 85):
  - Hypoechoic “standing” small-bowel loop of variable length (hemorrhagic intestinal necrosis, superinfection)
  - Loss of layered wall structure
  - Signs of partial or complete bowel obstruction (see p. 353)
  - Doppler evidence of mesenteric vascular stenosis or occlusion
- ▶ **Amyloidosis**: mild thickening involving a long segment of the bowel wall (intestinal amyloidosis may also occur without significant wall thickening)

### Circumscribed Wall Thickening

- ▶ **Benign tumors**: Examples are adenoma, leiomyoma, and neurofibroma. Occasionally the tumor can be directly visualized with ultrasound, based on the findings of contrast radiography.
  - Polypoid swelling of the bowel wall
- ▶ **Malignant tumors** (Figs. 537 and 538): Examples are duodenal carcinoma, small bowel carcinoma, carcinoid, malignant lymphoma, and metastases

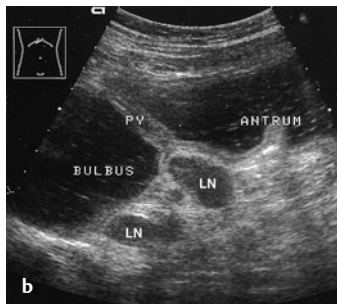
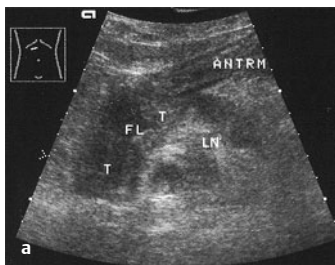


Fig. 537a, b Duodenal carcinoma. **a** Extensive tumor (T) with a prestenotic fluid collection. FL = fluid, LN = lymph node metastases. **b** Massive luminal widening of the duodenal bulb and antrum caused by the stenosis. PY = pylorus

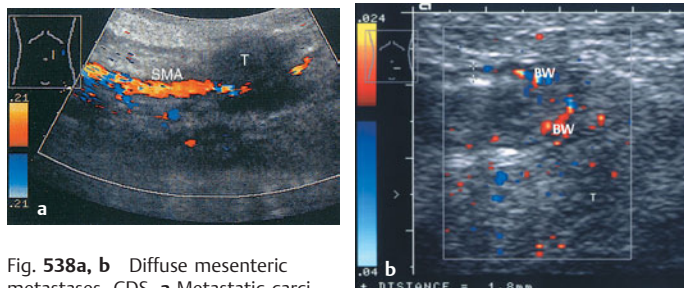


Fig. 538a, b Diffuse mesenteric metastases, CDS. **a** Metastatic carcinoid: The metastasis (T) is infiltrating and destroying the superior mesenteric artery (SMA). **b** Diffuse mesenteric metastasis (T) with small-bowel wall thickening (BW) in a patient with rectal carcinoma. Cursors: normal wall thickness

- Circumferential, infiltrative wall thickening with a target sign and clinical manifestations of stenosis
- Detectable metastases may be present (Fig. 538)

### Evaluation and Further Testing

- ▶ See p. 372.

## 15.4 Large Intestine

### Overview (Table 65):

**Table 65** · Abnormal findings in the large intestine

#### Long segmental wall thickening

Crohn disease  
 Ulcerative colitis (p. 367)  
 Ischemic colitis (p. 368)  
 Pseudomembranous (antibiotic-associated) colitis (p. 368)  
 Acute infectious colitis (p. 368)  
 Appendicitis (p. 369)  
 Diverticulitis (p. 369)  
 Carcinoma (diffuse infiltration, p. 370)  
 Lymphoma (diffuse spread, p. 370)

#### Circumscribed wall thickening

Diverticula, diverticulitis (p. 371)  
 Polyps (p. 371)  
 Incarcerated epiploic appendix (p. 371)  
 Colorectal carcinoma (p. 371)  
 Carcinoid (p. 372)  
 Malignant lymphoma (p. 372)

### Long Segmental Wall Thickening

- ▶ **Crohn disease** (Fig. 539): segmental involvement with a predilection for the cecum. Up to 50% of cases show colonic involvement. Only 25% of patients have disease limited to the large intestine.

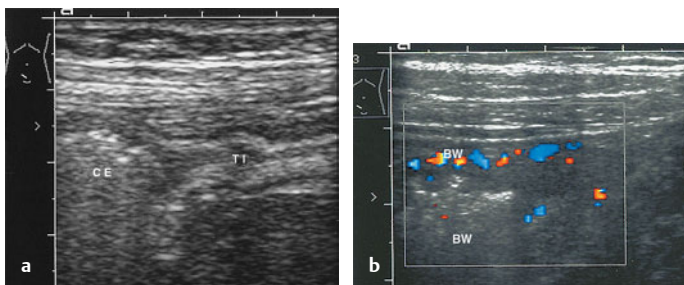


Fig. 539a, b Crohn disease. **a** Of the terminal ileum (TI), here with preservation of the wall layers. **b** Of the cecum. CDS: hypoechoic polypoid swelling of the bowel wall (BW). Histology demonstrated high activity. CE = cecum

- Sonographic findings are similar to those in Crohn disease of the terminal ileum (see p. 363).
  - Spread to the cecal pole is marked by a dilated, fluid-filled cecum. (Wall thickening can be detected and distinguished from fluid only by the sonographic observation of mobility and compression.)
  - Wall may show irregular swelling or polypoid changes, or it may be sharply delineated (accentuated).
- ▶ **Ulcerative colitis** (Figs. 540 and 541): diffuse involvement with a predilection for the rectum and the left half of the colon
- Uniform wall thickening

Fig. 540 Ulcerative colitis without inflammatory activity: accentuated wall (BW, cursors). CDS does not show increased vascularity

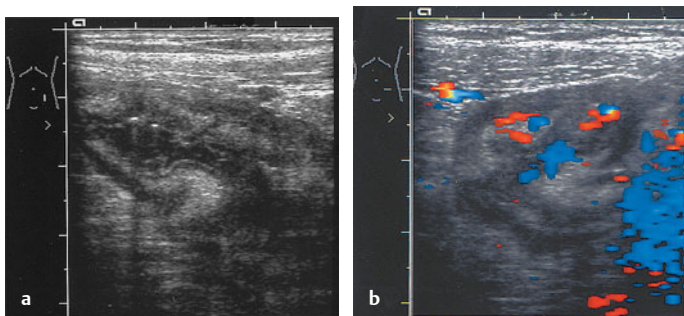
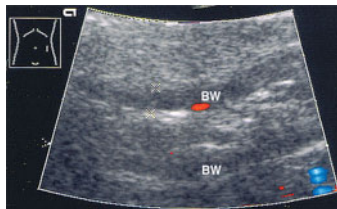


Fig. 541a, b Ulcerative colitis, high activity. **a** B-mode image: thickened, layered wall and intraluminal fluid causing high-grade luminal narrowing. **b** CDS: Transverse scan shows marked inflammatory vascularity

- Acute exacerbation is marked by intensive wall thickening with a distinct layered structure (echogenic middle layer) and possible circumscribed free fluid
- *Ulcerative colitis of low activity or in remission*: long segmental accentuation of the bowel wall

▶ **Ischemic colitis** (Fig. 542):

- Irregular hypoechoic wall thickening
- Segmental involvement, usually affecting the left transverse and descending colon
- Loss of anatomical wall layers (echogenicity of the layers may vary as a result of frequent bacterial superinfection)
- *CDS*: absence of color signals, or only peripheral vascularity

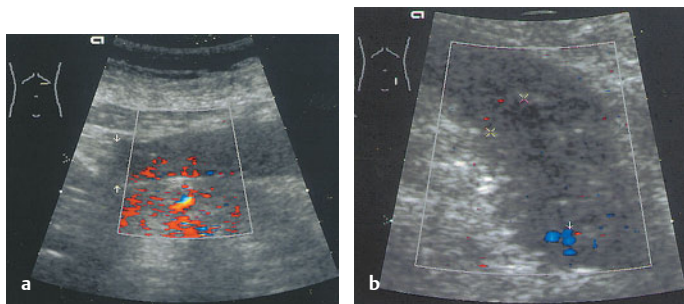


Fig. 542a, b Ischemic colitis (occlusion of the superior mesenteric artery, stenosis of the celiac trunk), *CDS*. **a** Sharply delineated starting point of the hypoechoic wall thickening (arrows). **b** Sharply delineated end point at the junction with the descending colon. Only peripheral vessels can be detected (arrow)

▶ **Pseudomembranous (antibiotic-associated) colitis** (Fig. 543):

- Extensive, occasionally grotesque wall thickening with luminal narrowing
- Hypoechoic to heterogeneous echo pattern

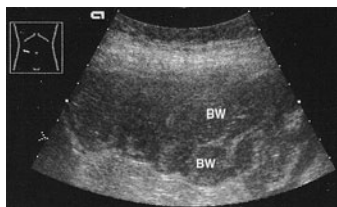

Fig. 543 Severe pseudomembranous antibiotic-associated colitis: massive polypoid swelling of the bowel wall (BW) with luminal obliteration. Clinical picture of toxic megacolon

▶ **Acute infectious colitis** (Fig. 544):

- Accentuated wall thickening (high activity is marked by layered wall thickening with luminal narrowing and local free fluid)
- Bowel dilatation due to increased fluid secretion

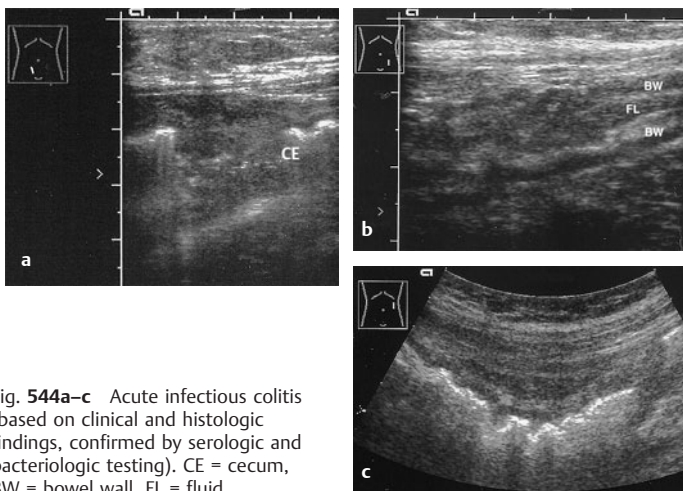


Fig. 544a–c Acute infectious colitis (based on clinical and histologic findings, confirmed by serologic and bacteriologic testing). CE = cecum, BW = bowel wall, FL = fluid

► **Appendicitis** (Fig. 545; see also Figs. 102 and 103, p. 76):

- Tubular (longitudinal) or target-shaped (transverse) fluid-filled hypoechoic structure in the right lower quadrant of the abdomen
- Diameter of the appendix > 6 mm
- Point tenderness over the appendix
- Echogenic fatty tissue reaction (echogenic “omental cap”)
- Aperistaltic, noncompressible appendix
- *Possible associated findings:* circumscribed free fluid, inflammatory lymphadenopathy, bacterial gas collection, fecalith

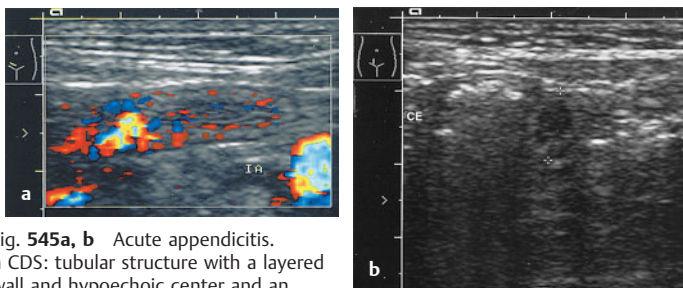


Fig. 545a, b Acute appendicitis. **a** CDS: tubular structure with a layered wall and hypoechoic center and an inflammatory vascular reaction. IA = iliac artery. **b** Longitudinal B-mode scan: cross-sectional view of the appendix with a typical target sign (cursors). CE = cecum

► **Diverticulitis** (Fig. 546; see also Fig. 104, p. 77):

- Inflammatory transformation of diverticula with hypoechoic peridiverticulitic wall thickening
- Segmental bowel wall thickening with absent or decreased peristalsis
- Echogenic omental cap (fatty tissue reaction)

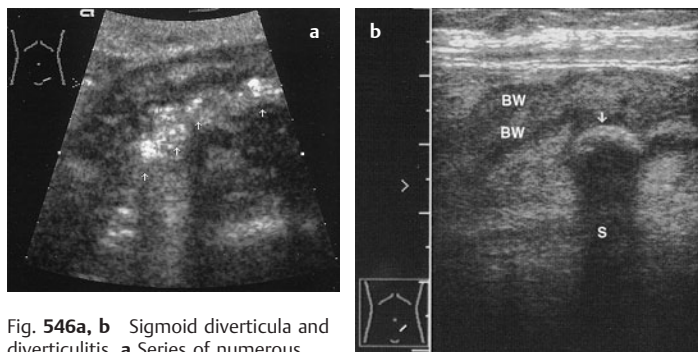


Fig. 546a, b Sigmoid diverticula and diverticulitis. **a** Series of numerous diverticula in the wall of the sigmoid colon (arrows). Hyperechoic air echoes, acoustic shadows, and increased thickness of the sigmoid wall. **b** “Peridiverticulitis”: curved zone of high-level echoes (arrow), acoustic shadow (S), hypoechoic perifocal inflammatory reaction, and the hypoechoic wall of the sigmoid colon (BW, with hypertrophy of the muscular coat)

- Localized tenderness over the diverticulitis
- CDS: inflammatory vascularity
- ▶ **Diffusely infiltrating carcinoma** (Fig. 547):
  - Irregular, bizarre, hypoechoic areas of wall thickening
  - Aberrant tumor vessels
  - Possible infiltration of surrounding organs, lymph node metastases

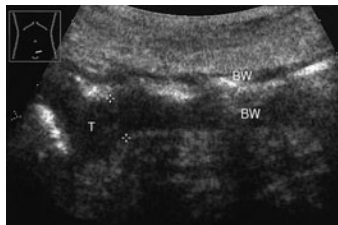

Fig. 547 Tumor infiltrating a long segment of the sigmoid colon (T, cursors). Harmonic imaging demonstrates infiltrative tumor growth in and along the bowel wall (BW)

- ▶ **Diffuse involvement by malignant lymphoma:**
  - Diffuse wall thickening of very low echogenicity
  - Wall layers often still defined

### Circumscribed Wall Thickening

- ▶ Sites of circumferential wall thickening often present as a “target sign” (after Lutz; Fig. 548). Other patterns may be seen, however, depending on the site of occurrence and the mode of tumor growth and spread. Several forms can be distinguished by ultrasound:
  - Ulcerated carcinoma with a crater-like defect (Fig. 548)
  - Carcinoma with an endophytic-polypoid type of growth (Fig. 549)
  - Diffusely infiltrating carcinoma involving a long segment of bowel (Fig. 550)

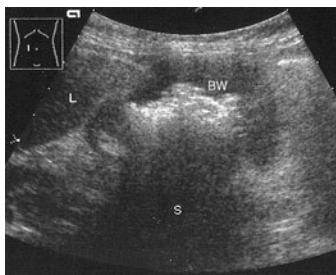


Fig. 548 Carcinoma of the ascending colon with a target sign: ulcerated form with a bright central echo (gas), distal acoustic shadow (S), and scalloped hypoechoic wall thickening (BW). L = liver

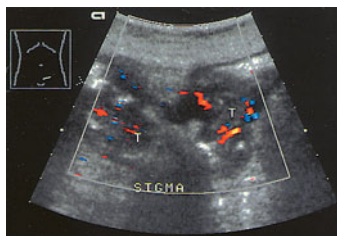


Fig. 549 Sigmoid carcinoma (T) showing an endophytic polypoid type of growth. CDS: prestenotic luminal widening and spot-like tumor vessels

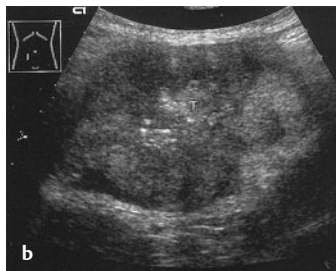
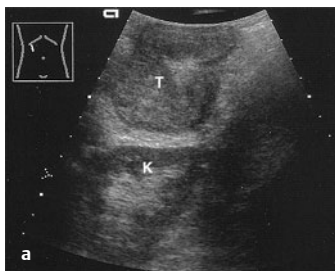


Fig. 550a, b Carcinoma of the ascending colon (T), diffusely infiltrating form. a Thickened colon wall with a hyperechoic center (lumen) = "pseudo-kidney sign." K = kidney b In a zoom view, the tumor-infiltrated bowel wall has a nonhomogeneous hypoechoic appearance. Tumor (T) has obliterated most of the bowel lumen

- ▶ **Diverticula and diverticulitis** (see p. 77 and Fig. 119, p. 90):
  - Small, rounded, echogenic (air-containing) structure with a distal acoustic shadow
  - Most lesions of diverticulitis (marked by typical left lower quadrant pain) are surrounded by a hypoechoic (inflammatory) halo
- ▶ **Polyp (adenoma, small polypoid carcinoma)**: appears as a rounded hypoechoic lesion adherent to the bowel wall. Can be defined sonographically only by using special techniques such as hydrocolonic ultrasound, and generally when the location of the lesion has already been determined by endoscopy.
  - **Incarcerated epiploic appendix**:
    - Sharply circumscribed hypoechoic mass on the outer wall of the intestine
    - Hypoechoic perifocal edema
    - Concomitant sectoral thickening of the bowel wall
- ▶ **Colorectal carcinoma** (see Figs. 548–550, p. 371): One-third of cases occur in the rectum and one-third in the sigmoid colon.
  - Target sign is present in typical cases
  - Sectoral thickening of the bowel wall

- Hypoechoic intraluminal tumor mass with associated luminal narrowing
- CDS: aberrant tumor vessels
- Possible associated findings:
  - Prestenotic gaseous distention (due to bowel obstruction)
  - Tumor infiltration
  - Locoregional or lymphatic metastases
  - Distant metastasis
- ▶ **Carcinoid:**
  - Primary tumor usually cannot be detected
  - Metastases: increased vascularity found by CDS
- ▶ **Malignant lymphoma (Fig. 551):** involves a long bowel segment but rarely affects the large intestine
  - Circumferential tumor mass
  - Marked wall thickening; anatomical wall layers frequently still defined

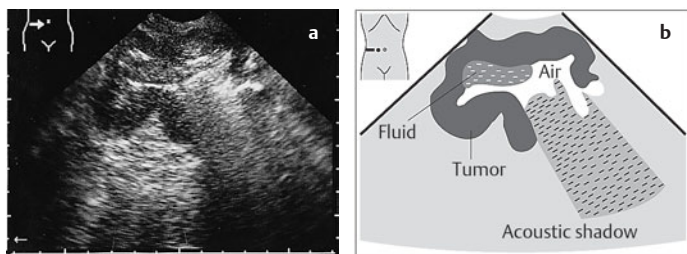


Fig. 551a, b Malignant lymphoma of the ascending colon. **a** Hypoechoic, scalloped area of tumor infiltration in the bowel wall. **b** Diagram corresponding to the ultrasound image

### Evaluation and Further Testing

- ▶ Intestinal ultrasound is a difficult study that requires a highly experienced sonographer and high-resolution technology (appendicitis can be diagnosed or the bowel wall evaluated with a 5 MHz transducer and occasionally with a 7.5 MHz transducer using magnified views). When wall thickening is present, it is often necessary to use a high-resolution magnifying scanner in order to differentiate the wall, lumen, and intraluminal fluid.
- ▶ **Sonographic diagnosis of inflammatory bowel disease:** The ultrasound classification of inflammatory bowel diseases is subject to misinterpretation. Highly acute ulcerative colitis and severe infectious colitis may demonstrate the same features as Crohn disease (see Figs. 539–541, p. 367 and Fig. 544, p. 369). Similar changes may also occur with swelling of the terminal ileum secondary to appendicitis with abscess formation. Accentuated walls may be found in all forms of inflammatory bowel disease. The diagnosis relies critically upon clinical manifestations, endoscopic findings, and histology.
  - Inflammatory mucosal lesions (ulcerative colitis), polyps, ulcers, and diverticula can be evaluated more accurately by endoscopy and radiography.
  - Sonography is as good as CT in evaluating lesions with transmural spread (Crohn disease, abscesses, fistulae).
- ▶ **Sonographic differential diagnosis:** The main sonographic patterns of wall swelling and their association with specific diseases are reviewed in Table 66.

**Table 66** · Clinical diagnoses suggested by different sonographic signs of wall swelling

Wall swelling	Spread	Clinical diagnosis
Accentuated wall with luminal distention		Crohn disease Ulcerative colitis (with mild inflammation) Perifocal reaction
Layered wall with luminal narrowing		Crohn's disease (with moderate inflammation) Ulcerative colitis (with severe inflammation)
	Inflammatory lymphadenopathy	Infectious enterocolitis Severe perifocal reaction (appendicitis, abscess formation)
Hypochoic wall with loss of layered structure	Perimural spread ("mesenteritis"), fistulae, abscesses	Crohn disease (high activity)
	Intraluminal spread (irregular wall thickness, luminal narrowing)	Pseudomembranous colitis
	Sharp segmental boundaries, predilection for the left side, avascular by CDS	Ischemic colitis
	"Garden hose" appearance	Intestinal hematoma
	Circumscribed, circumferential wall swelling, symmetrical or asymmetrical	Intestinal tumor

- **Crohn disease:** Ultrasound is the most important modality in the follow-up of this disease. Key criteria for interpreting sonographic findings are wall layering and periluminal changes. CDS can furnish additional criteria for evaluating the nature and extent of mural and mesenteric inflammation.
- **Ulcerative colitis:** Endoscopy is superior to ultrasound in the diagnosis of ulcerative colitis.
- **False-positive findings:** In extremely rare cases, endoscopy and histology may fail to detect a correlate for wall thickening noted on ultrasound. (In the few cases that we have seen to date, one involved a patient with a history of laxative abuse and hepatic cirrhosis, one was a clinically asymptomatic patient, and one was a patient with excretory pancreatic insufficiency and hepatic cirrhosis.)
- **Target sign:** Always requires endoscopic and histologic investigation. In exceptional cases (refusal of endoscopy, very elderly patient, no therapeutic implications), a tumor can be detected or excluded with reasonable confidence by sonographic inspection of the entire colon combined with a rectal examination and stool examination for occult blood. If necessary, these tests may be supplemented by ultrasound-guided FNAB or proctosigmoidoscopy.
- **Appendicitis:** Ultrasound provides a diagnostic accuracy of almost 100% (besides detecting lesions important in differential diagnosis such as kidney stones, ovarian cysts, adnexitis, and gallstones).

- **Rectal tumors:** Endorectal ultrasound is an accurate technique for investigating the spread of rectal tumors into the perirectal fat and their fistulation into urogenital organs.
- ▶ **Endosonography:** necessary and rewarding for all intramural, submucous lesions of the stomach and for staging gastric neoplasms
- ▶ **Endoscopy:** The procedure of first choice for examinations of the stomach and colon. Exceptions are the follow-up of Crohn disease and the diagnosis of appendicitis (see above).
  - *New technique:* wireless capsule endoscopy
- ▶ **Double-contrast radiography:** After endoscopy, double-contrast radiographs are the method of choice for examining the stomach and colon. They are used exclusively for examining the small intestine (small-bowel contrast using the Sellink technique).
- ▶ **CT:** should be used only to investigate abscesses and metastases (staging), especially in patients with rectal tumors and tumors of the lesser pelvis (conditions that limit the usefulness of ultrasound).

## 16 Urogenital Tract

### 16.1 Examination

#### Scan Planes

##### ► Ureter:

- A ureter affected by outflow obstruction can be imaged at the three levels shown in Fig. 552.

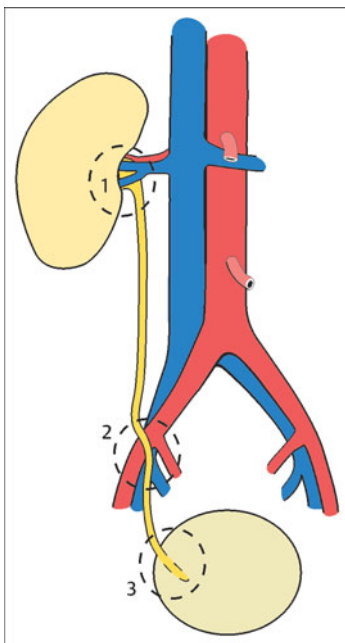


Fig. 552 Ultrasound examination of the ureter: 1 = ureteropelvic junction area, 2 = preiliac segment of the ureter, 3 = suprav vesical segment of the ureter

- The upper part of the ureter at the ureteropelvic junction can be identified in the posterior part of the flank scan and in the transverse renal scan. It lies posterior to the renal vein and artery and is directed anteriorly and medially (Fig. 553).
- **Urinary bladder:**
  - Lower abdominal transverse scan (see Fig. 39, p. 30)
  - Lower abdominal longitudinal scan (see Fig. 40, p. 31)
- **Genital organs:**
  - Lower abdominal transverse scan (see Fig. 39, p. 30)
  - Lower abdominal longitudinal scan (see Fig. 40, p. 31)
  - Special scan planes for the penis and testis

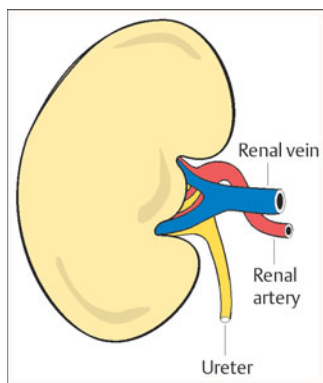


Fig. 553 Topographic anatomy of the renal artery, renal vein, and ureter

### Sonographic Anatomy and Normal Findings

- ▶ **Ureter:** The normal-sized ureter cannot be visualized with ultrasound.
- ▶ **Urinary bladder:**
  - The normal bladder has a round, oval, or approximately triangular or square shape.
  - The bladder tapers cephalad and anteriorly when viewed in longitudinal section (Fig. 554).
  - The bladder should be adequately distended with fluid for ultrasound scanning.
  - *Normal bladder volume:* 350–750 mL in men, 250–550 mL in women

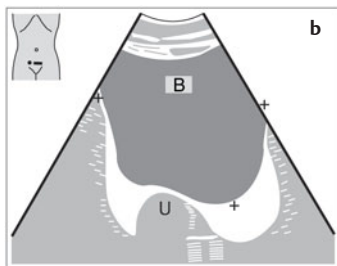
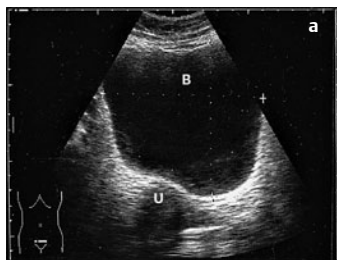


Fig. 554a, b Bladder (B) and uterus (U) in a lower abdominal transverse scan

#### ▶ Male genital organs:

- **Seminal vesicles** (Fig. 555): located between the bladder floor and prostate. They appear sonographically as two homogeneous, hypoechoic ovals that extend laterally upward from the bladder.
- **Prostate** (Fig. 556): an elliptical, chestnut-shaped gland with smooth margins and a homogeneous internal echo pattern
  - The volume of the prostate is calculated by using the formula for an ellipsoid (see Residual Urine Determination, p. 51).
  - *Normal dimensions:* width < 45 mm, depth < 35 mm, length < 35 mm, volume < 25 mL

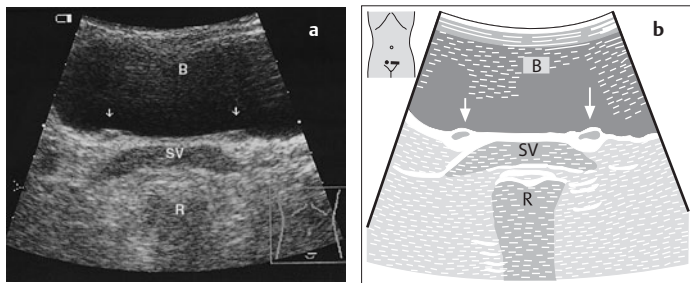


Fig. 555a, b Sonographic appearance of the seminal vesicles between the bladder floor (B) and rectum (R). SV = seminal vesicles, arrows: ureteral ridges

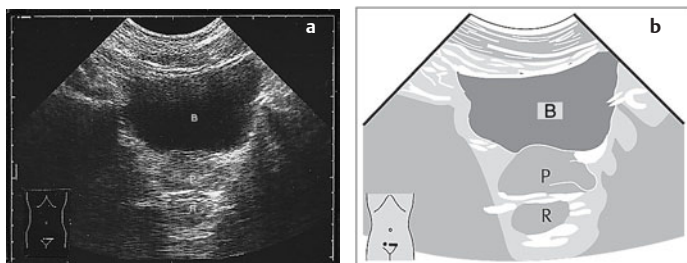


Fig. 556a, b Normal chestnut-shaped prostate (P) between the bladder (B) and rectum (R)

- **Penis:** The penis can be scanned posteroanteriorly from the perineum. The corpora cavernosa display a fine pattern of low-level internal echoes. The corpus spongiosum is hyperechoic, and the urethra appears as an echogenic band.
- **Testis** (Figs. 555, 557, 558): The anatomical location of the testis is shown in Fig. 557. It has a homogeneous, finely granular echo pattern.
- ▶ **Female genital organs** (Fig. 559): The most anterior structure in the female pelvis is the bladder. Behind it are the cul-de-sac and rectum.
  - **Uterus:** A transverse scan through the lower abdomen demonstrates the uterus as an elliptical hypoechoic organ situated between the bladder and rectum.
  - **Vagina:** The vagina appears sonographically as a delicate double-walled band with an echogenic streak-like lumen, located between the bladder and rectum.
  - **Ovary:** Normal ovaries are difficult to define with transabdominal ultrasound. They are hypoechoic and have a round-to-oval shape.

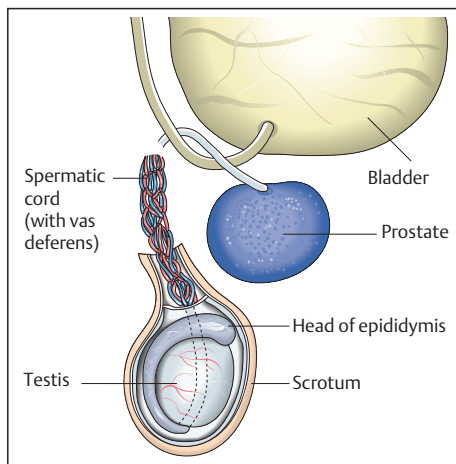


Fig. 557 Anatomical overview of the testis, epididymis, and vas deferens

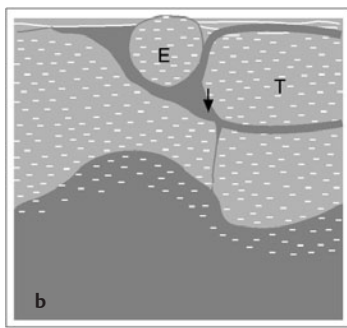
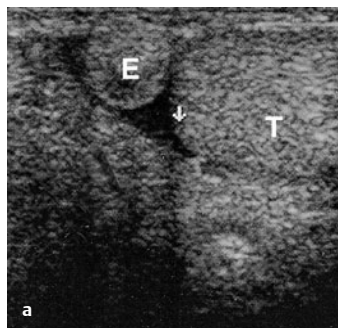


Fig. 558a, b Longitudinal scan of the testis (T) with the epididymis (E) and a small fluid collection (arrow, still within normal limits)

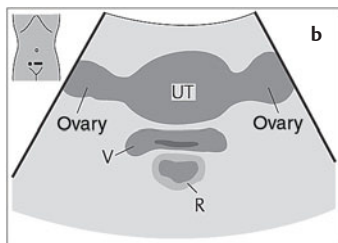
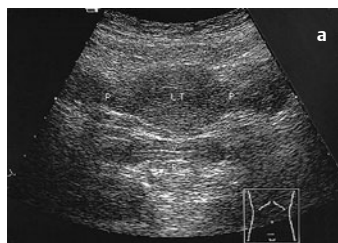

Fig. 559a, b Lower abdominal transverse scan of the female genitalia. UT = uterus, V = cervix and vagina, R = rectum, P = parametria

## Scanning Protocols

### ► Ureter:

- *Transducer:* 3.5–5 MHz
- The testicular vein (or ovarian vein) may occasionally be mistaken for the ureter at the site where the ureter crosses over the iliac vessels.
- **Scanning tip:** The visualization of an obstructed ureter can be aided by increased fluid intake, forced diuresis, or both.

### ► Bladder:

- The bladder is surveyed in longitudinal and transverse scans through the lower abdomen, occasionally with the transducer angled slightly cephalad.
- **Scanning tip:** Moving the patient to a lateral decubitus or knee–elbow position can be a helpful maneuver in differentiating wall thickening from clots and sediment.
- *Ultrasound cystometry:* see Function Studies, p. 52.

### ► Genital organs:

- *Transducer:* 3.5 or 5 MHz A 7.5–10 MHz transducer is occasionally used for the penis and testis.
- The uterus, ovaries, prostate, and seminal vesicle are scanned from a suprapubic site with a full (not overdistended) bladder. They are surveyed in longitudinal and transverse sections.
- For optimum visualization of the male genital organs, the beam should be angled caudad from the bladder floor. As for the female genital organs, the uterus is cranial to the bladder, the cervix and vagina are posterior, and the adnexa are posterolateral.

## Overview and Classification of Findings

- **Kidney, ureter, and bladder:** Section 16.2 deals with dilatations of the pyelocalyceal system (PCS) and ureter (urinary tract obstruction, UTO) and with wall changes and intraluminal changes in the bladder.
- **Genital organs:** Sections 16.3 and 16.4 deal with the genital organs only to the extent that they are involved in pathologic conditions encountered in routine medical ultrasound.
- **Classification and overview:**
  - *Renal pelvis, ureter, and bladder:* see Table 67, p. 380.
  - *Male genital organs:* see Table 68, p. 389.
  - *Female genital organs:* see Table 69, p. 395.

## 16.2 Renal Pelvis, Ureter, and Bladder

## Overview (Table 67):

Table 67 · Abnormal findings in the renal pelvis, ureter, and bladder

Renal pelvis and ureter	Bladder	
	Wall changes	Intraluminal findings
Pyelectasis (p. 380)	Diverticula, pseudo-diverticula (p. 384)	Ureterocele (p. 386)
Urinary stone colic (p. 380)	Bladder wall thickening (p. 384)	Sediment, pus, clotted blood (p. 386)
Obstructive pyelocalyceal ectasia, urinary tract obstruction (p. 382)	Bladder carcinoma (p. 384)	Stones (p. 387)
	Polypoid bladder tumors (p. 384)	Foreign bodies (p. 387)

## Dilatation of the Pyelocalyceal System

- ▶ **Pyelectasis** (Fig. 560): ampullary renal pelvis associated with increased urinary excretion
  - Triangular or cone-shaped hypoechoic mass in the renal sinus echo
  - Absence of calyceal ectasia
  - No ureteral dilatation
  - CDS: absence of vascularity
- ▶ **Note:** It is important to exclude an obstruction.

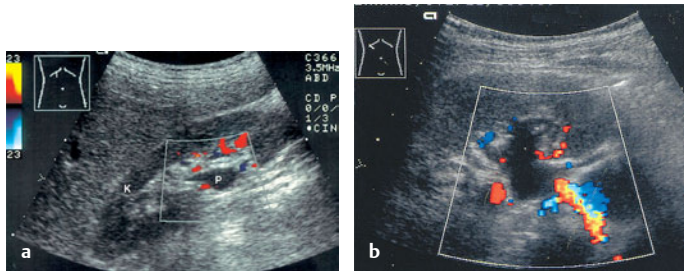


Fig. 560 Pyelectasis (P), CDS. **a** A large renal vein can be excluded from the differential diagnosis. K = right kidney. **b** Obstructive pyelocalyceal ectasia with acute urinary stone colic: anechoic separation of the central echo complex with mild dilatation of the ureteropelvic junction

- ▶ **Urinary stone colic** (Figs. 561–563; see also Fig. 86, p. 65):
  - **Clinical features:** acute, intense waves of abdominal pain caused by a kidney stone or, rarely, by blood clots. Perirenal fluid extravasation leads to urinoma formation.

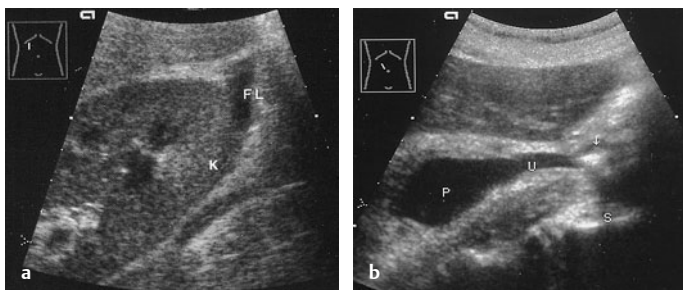


Fig. 561a, b Renal colic due to a ureteropelvic junction stone. **a** Hydronephrotic kidney (K) with a dilated, fluid-filled renal pelvis and extravasated fluid (urinoma, FL). **b** Ureteropelvic junction stone (arrow, U) and dilated renal pelvis (P). Oblique upper abdominal longitudinal scan over the course of the right ureter

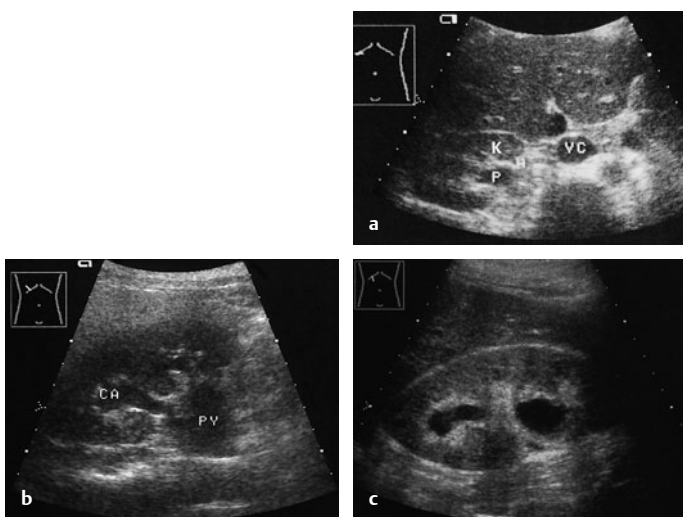


Fig. 562a–c **a** High transverse scan of the right kidney (K). Posterior to the artery is the ectatic renal pelvis (P) with no dilatation of the proximal ureter. VC = inferior vena cava. **b, c** Dilated pyelocaliceal system in a patient with flank pain. Suspicion of biliary colic. **b** Dilated calix (CA) communicating with the dilated and obstructed renal pelvis (PY). **c** A proximal ureteral stone causing obstructive caliceal ectasia. Scan shows two anechoic masses in the central echo complex. The upper mass represents an ectatic caliceal neck. The enlargement of a caliceal neck to more than 5 mm (here 11 mm) indicates obstruction. The lower mass is the dilated renal pelvis

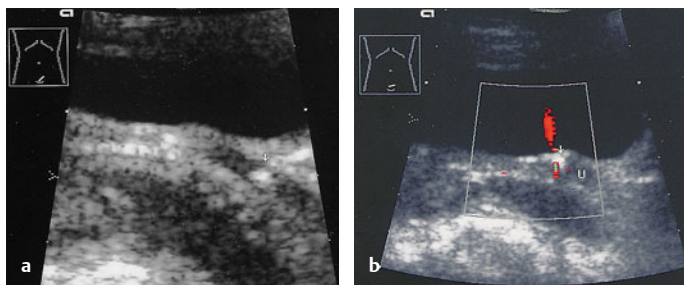


Fig. 563a, b Urinary stone colic with a detectable stone (arrow) in the prevesical ureter (U). **a** B-mode image: high-amplitude echo with a partial acoustic shadow. Oblique lower abdominal transverse scan. **b** CDS 4 days later: nonoccluding stone in the ureteral orifice; urine jet (red); faint “twinkling artifact” in the acoustic shadow of the stone

- **Sonographic criteria:** Ureteral obstruction can be detected sonographically at the classic sites of predilection. The level and nature of the obstruction can be accurately determined in over 80% of cases. If the neck of the calyx is enlarged more than 0.4 cm and the pelvis and ureter to more than 0.5 cm, urinary stasis is present.

► **Obstructive pyelocalyceal ectasia:** caused by UTO, Fig. 564). As the duration of the obstruction increases, the anechoic fluid exerts an increasing mass effect that leads to parenchymal thinning and obliteration of the central echo complex. This chronic process can be classified into several grades of severity (Figs. 565–568).

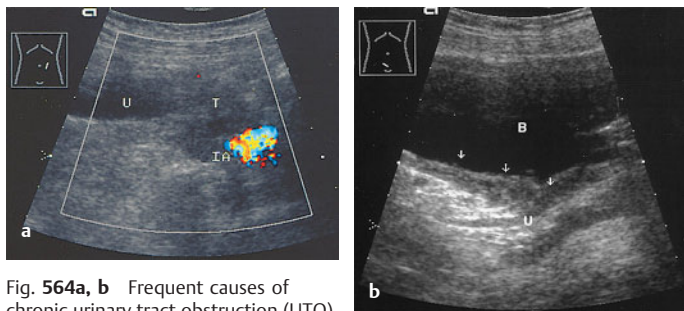
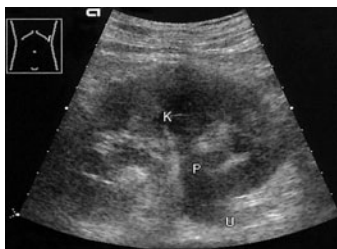

Fig. 564a, b Frequent causes of chronic urinary tract obstruction (UTO). **a** Metastasizing tumors in the lesser pelvis (ovary, uterus; here: rectal carcinoma). **b** Bladder carcinoma (urothelial carcinoma, arrows), often located near the ureteral orifice. The differential diagnosis includes metastasis from prostatic carcinoma. U = ureter, IA = iliac artery, B = bladder

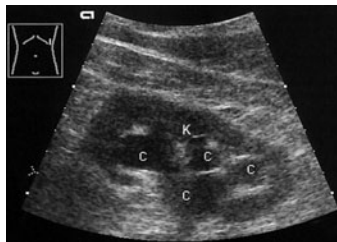
- **Mild urinary stasis** (grade I, Fig. 565):
  - Pyelocalyceal ectasia due to anechoic compartmentalization of the renal sinus echo complex
  - Possible anechoic dilatation of the ureteropelvic junction and ureter
  - Preservation of a prominent sinus echo
  - Normal thickness of the renal parenchyma

Fig. 565 Mild urinary stasis: anechoic splaying of the central echo band with preservation of the sinus echo and normal thickness (1.3–2 cm) renal parenchyma (K). P = renal pelvis, U = ureter



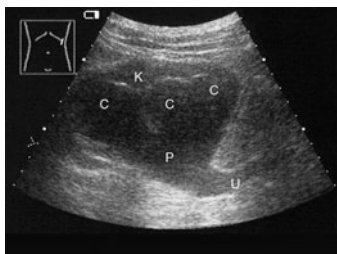
- **Moderate urinary stasis** (grade II, Fig. 566):
  - Marked calyceal dilatation to 5–10 mm, pyelectasis
  - Ureteral dilatation, incipient ureteral tortuosity
  - Renal parenchyma is normal or slightly thinned
  - Diminished renal sinus echo

Fig. 566 Moderate urinary stasis: marked anechoic pyelocalyceal ectasia (C) with a diminished sinus echo and incipient thinning of the renal parenchyma. K = kidney



- **Severe urinary stasis** (grade III, Fig. 567):
  - Massive calyceal dilatation, marked anechoic dilatation of the renal pelvis
  - Marked ureteral dilatation and tortuosity
  - Obliterated renal sinus echo
  - Thinning of the renal parenchyma

Fig. 567 Severe urinary stasis: pronounced anechoic pyelocalyceal ectasia (C, P) with an obliterated sinus echo, parenchymal thinning, and ureteral dilatation (U). K = kidney



- **Hydronephrotic sac** (grade IV, Fig. 568):
  - Anechoic cystic mass in the central echo complex caused by severe pyelocalyceal dilatation
  - Complete loss of the renal sinus echo
  - Complete or almost complete loss of the renal parenchyma

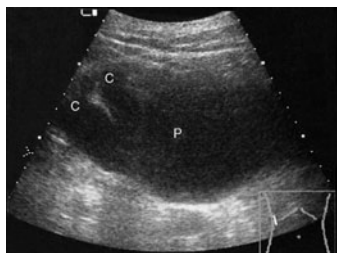

Fig. 568 Hydronephrotic sac. The calyces (C) and renal pelvis (P) have coalesced to form an anechoic hydronephrotic sac with loss of the renal parenchyma

### Bladder: Wall Changes

- ▶ **Bladder diverticula or pseudodiverticula** (Fig. 569): high incidence of diverticular carcinoma
  - *True diverticula*: anechoic, usually solitary outpouching of the bladder wall (prolapses between muscle bundles at a site of congenital weakness)
  - *Pseudodiverticula*: multiple protrusions due to thickening of the bladder wall (usually a result of obstructive or neurogenic bladder dysfunction)

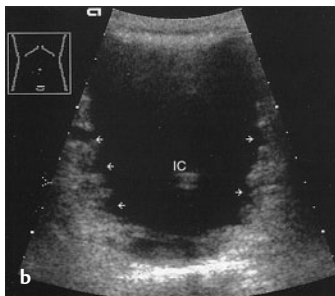
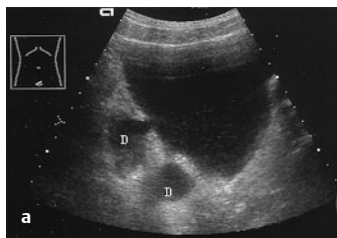


Fig. 569a, b Bladder diverticula (D). **a** True diverticulum (congenital anomaly): no wall thickening. **b** Pseudodiverticulum (arrows): significant wall thickening. The patient presented clinically with benign prostatic hyperplasia. IC = indwelling catheter

- ▶ **Bladder wall thickening** (Fig. 570a): mural hypertrophy, trabeculated bladder
  - Wall thickening > 8 mm in the full bladder
  - Usually results from an infravesical outflow obstruction
- ▶ **Plaque-like bladder carcinoma** (Fig. 570b; see also Fig. 564b, p. 382):
  - Relatively broad area of wall thickening
  - CDS: spot-like tumor vessels
- ▶ **Polypoid bladder tumors** (Fig. 571): polypoid or polypous tumors, “bladder papillomas,” mostly noninvasive carcinomas, staged according to the criteria in Fig. 572
  - Circumscribed wall thickening with intraluminal protrusion
  - Tumor surface is usually lobulated (and occasionally echogenic)
  - Nonhomogeneous internal echo pattern
  - CDS: spot-like tumor vessels

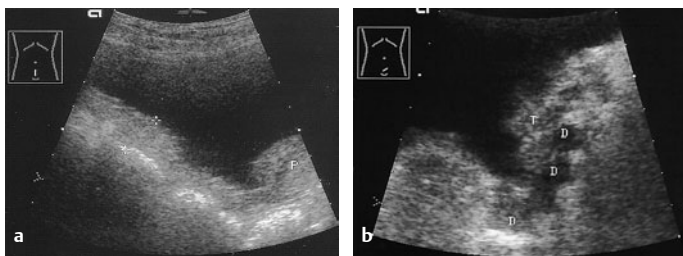


Fig. 570a, b Thickening of the bladder wall. **a** The bladder wall is thickened to 15.8 mm (cursors) as a result of prostatic enlargement (P). **b** Wall thickening due to a plaque-like bladder tumor (T; histology; papillary urothelial carcinoma, probably a diverticular tumor). D = diverticula

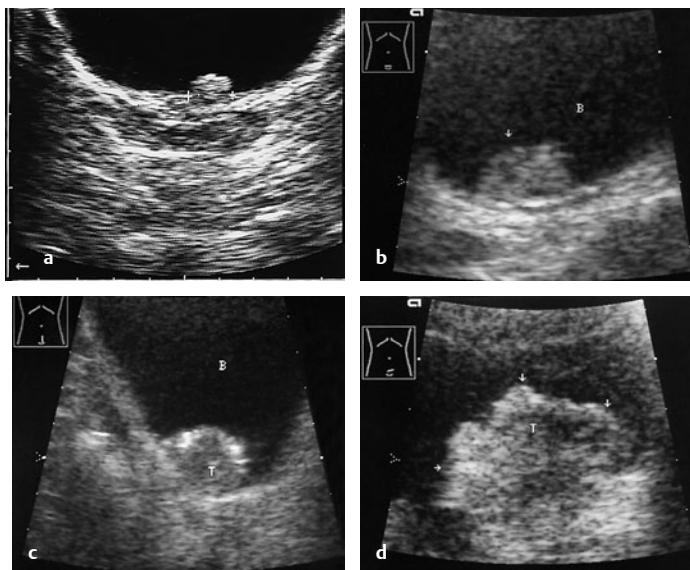


Fig. 571a–d Polypoid bladder tumors. **a** Benign “bladder papilloma” (cursors). **b** Lobulated hypoechoic mass (arrow) on the bladder floor (cystoscopy: papillary tumor; histology: urothelial carcinoma). **c** Echogenic tumor with an echogenic halo and no evidence of wall infiltration (histology: urothelial carcinoma). **d** Intravesical tumor with irregular margins (papillary urothelial carcinoma). The high surface echogenicity results from a “blooming” effect

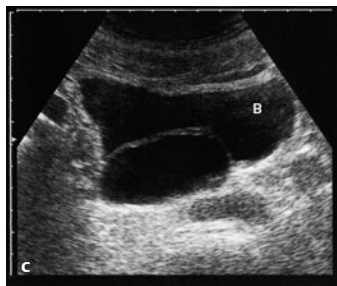
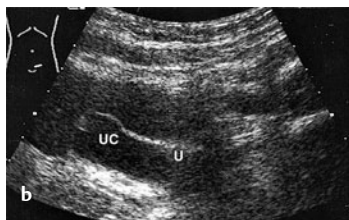
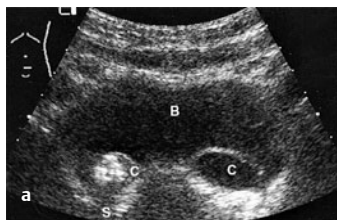
TNM	Tis	Ta	T1	T2	T3a	T3b	T4
Urothelial involvement							
L. propria							
Muscle							
Adventitia							
Invasion of extra-vesical organs							Prostate, uterus, vagina, pelvis wall, abdominal wall
New TNM stage (2002)	0	I	II	III	IV		

**Fig. 572** Staging of bladder carcinoma. Tis = carcinoma in situ, Ta = noninvasive papillary carcinoma, T1 = tumor invades subepithelial connective tissue, T2 = tumor invades muscle, T3 = tumor invades perivesical tissue, T3a = microscopically, T3a = macroscopically (extravesical mass), T4 = tumor invades adjacent organs

### Bladder: Intraluminal Findings

#### ► Ureterocele (Fig. 573):

- Echogenic band bulging into the bladder lumen (invaginated ureteral orifice)
- Ureteral obstruction



**Fig. 573a–c** Ureteroceles. **a, b** Bilateral ureteroceles (C, UC). The right ureterocele contains a stone (S = acoustic shadow), and the left ureterocele is associated with ureteral obstruction (U). B = bladder. **c** Large ureterocele on the right side: echogenic oval membrane within the bladder lumen (image courtesy of Dr. K. Ringewald)

#### ► Benign prostatic hyperplasia (BPH, Fig. 574):

- Spherical or nodular protuberance of the middle lobe of the prostate

#### ► Sediment, pus, blood clots (Fig. 575):

- *Sediment*: sharply margined echogenic layer that moves with position changes

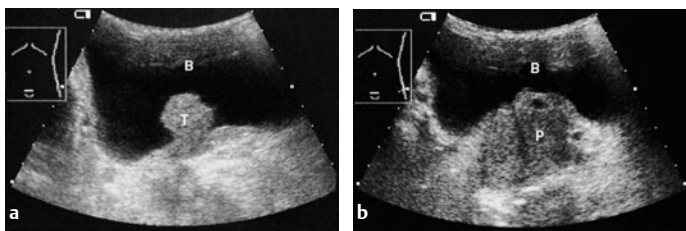


Fig. 574a, b Benign prostatic hypertrophy (BPH; adenoma of the middle lobe). **a** Polypoid tumor mass (T) in the bladder (B). **b** Angled scan demonstrates BPH, excluding a primary bladder tumor. P = prostate

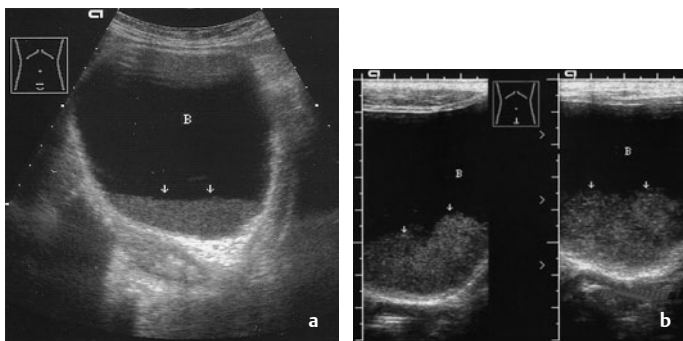


Fig. 575a, b Bladder sediment and clotted blood. **a** Purulent sediment: echogenic layer with a horizontal free margin (arrows). **b** Large polypoid clot (arrows): moves and changes shape with position changes, shows transient swirling of clot particles. B = bladder

- *Clots*: round or shaggy areas of increased echogenicity; distinguishable from polypoid tumors by noting movement or swirling in response to position changes or irrigation (bladder tamponade by clotted blood, see Fig. 177, p. 134)
- *Both*: absence of internal vessels found on CDS
- ▶ **Stone** (see Fig. 563, p. 382):
  - High-amplitude echo
  - Distal acoustic shadow
  - Mobility
- ▶ **Foreign body** (Fig. 576): e.g., ureteral stent, indwelling catheter
  - *Ureteral stent* (drain): echogenic double band in contact with the ureter (Fig. 576a)
  - *Catheter balloon*: typical round, echogenic balloon wall, fluid-filled lumen, echogenic center (tube, Fig. 576b), and double-walled tubing

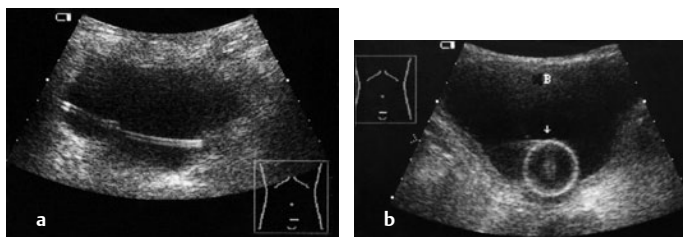


Fig. 576a, b Foreign bodies in the bladder: ureteral stent and indwelling catheter. **a** Echogenic ureteral stent inserted for urothelial carcinoma of the ureter. **b** Indwelling catheter balloon (arrow): echogenic balloon wall surrounding a bright central echo from the catheter tip

### Evaluation and Further Testing

#### ► Sonography:

- **Renal colic:** Sonography is the best and simplest diagnostic study in patients with suspected renal colic, with a diagnostic accuracy of almost 100%. An experienced examiner using all available aids can locate the stone with a high degree of confidence. Most cases do not require urography. Our practice:
  - The patient is referred for appropriate treatment based on the clinical presentation, laboratory results, and sonographic findings including the stone location. Daily ultrasound follow-ups are scheduled along with regular urinalysis (infection requires urologic intervention). If the stone is not passed in 1–2 weeks, the patient is referred for further urologic therapy.

■ **Note:** If complications arise such as urinoma, persistent/recurrent pain, or infection (bacteriuria, leukocyturia, fever and leukocytosis), immediate urologic stenting is indicated (see p. 286).

- **Bladder:** In a bladder well distended with fluid, transabdominal scanning can clearly demonstrate lesions as small as 5 mm (fasting without prior voiding or copious fluid intake 1 hour before the examination).
  - Ultrasound is an excellent modality for locating the cause of erythrocyturia (e.g., renal, ureteral or bladder stones, diverticula, tumors)
  - Tumors 5 mm or larger can be readily detected.
  - **Exceptions:** Tis tumors, tumors on the bladder roof, tumor staging (see Fig. 572, p. 386).

#### ► Further testing:

- **Ureteral stone:** If ultrasound cannot detect a stone in cases with minimal obstruction, the stone is either located at a poorly accessible site or is very small, in which case it generally cannot be detected even by excretory urography. Retrograde cystoscopy may be necessary.
- **Bladder:** Unexplained erythrocyturia and all indeterminate findings or masses should be investigated by cystoscopy or possibly endosonography.

## 16.3 Male Genital Tract

### Overview (Table 68):

**Table 68 · Abnormal findings in the male genital organs**

Vesiculitis (p. 389)
Acute prostatitis (p. 389)
Benign prostatic hyperplasia (BPH, p. 390)
Prostatic carcinoma (p. 390)
Chronic prostatitis, prostatic calcifications (p. 391)
Orchitis, abscess, hematoma (p. 392)
Testicular tumors (p. 393)
Hydrocele, varicocele (p. 393)
Spermatocele (p. 394)
Epididymitis (p. 394)
Testicular torsion (p. 394)
Urethral strictures (p. 394)

### Abnormal Findings

► **Changes in the seminal vesicles (Fig. 577):**

- *Focal echogenic areas:* calcifications (Fig. 577a)
- *Hypoechoic swelling:* purulent vesiculitis (Fig. 577b). Must be differentiated from invasion by prostatic carcinoma.

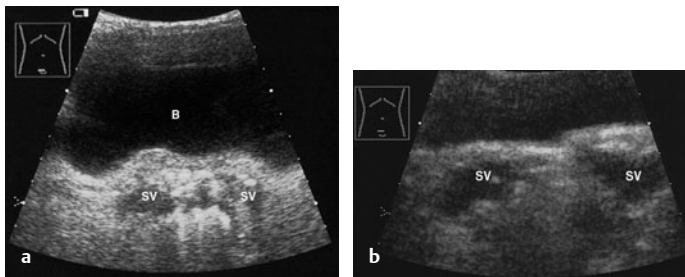
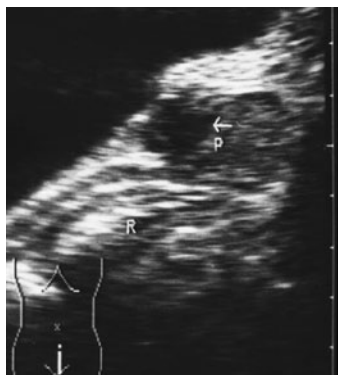

Fig. 577a, b Abnormalities of the seminal vesicles. **a** Calcifications of the seminal vesicles (SV). B = bladder. **b** Purulent vesiculitis: bulky hypoechoic to anechoic seminal vesicles with ill-defined margins. Harmonic imaging

► **Acute prostatitis (Fig. 578):**

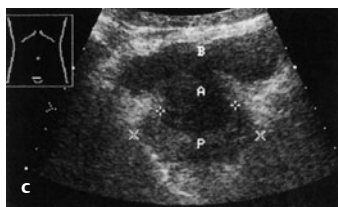
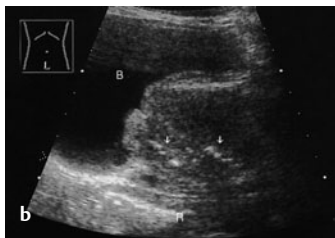
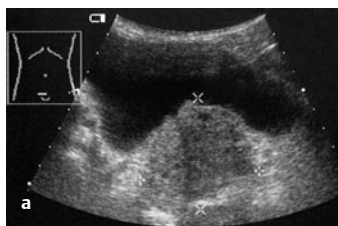
- Decreased echogenicity of the prostate
- Slight enlargement
- Smooth borders
- Frequent purulent liquefaction



**Fig. 578** Acute prostatitis: fluid collection (P, arrow) in the prostate. The echogenic area represents purulent liquefaction. R = rectum

► **Benign prostatic hyperplasia (BPH, Fig. 579; see also Fig. 574, p. 387):**

- Circumscribed or diffuse enlargement of the periurethral gland near the bladder floor (= enlarged middle lobe)
- Proliferation of the central paraurethral tissue may exert pressure on the other parts of the gland, inciting the formation of a “surgical capsule.”
- Smooth margins, intact capsule



**Fig. 579a–c** Benign prostatic hyperplasia (BPH). **a** Lower abdominal transverse scan: homogeneous echo pattern with fairly smooth borders. The bulging upper surface of the prostate has elevated the bladder floor. **b** Lower abdominal longitudinal scan: large prostate indenting the bladder floor (B). The echo pattern is nonhomogeneous due to numerous microcalcifications (amyloid bodies, arrows). R = rectum. **c** Benign nodular prostatic hyperplasia (P, cursors) with a hypoechoic benign prostatic hypertrophy, “middle lobe adenoma” (A, cursors) indenting the bladder floor (B)

► **Prostatic carcinoma (Figs. 580 and 581):**

- *Early signs:*
  - Nonhomogeneous echo pattern
  - Hypoechoic areas

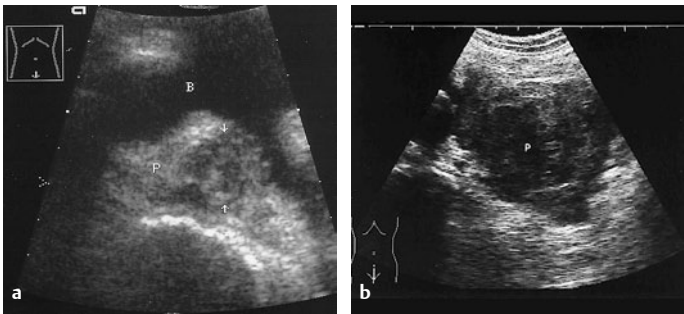


Fig. 580a, b Prostatic carcinoma. **a** Early prostatic carcinoma (stage pT2b): intraprostatic hypoechoic mass (arrows). **b** Advanced prostatic carcinoma: nonhomogeneous hypoechoic lesion with ill-defined margins and peripheral extensions. B = bladder, P = prostatic carcinoma

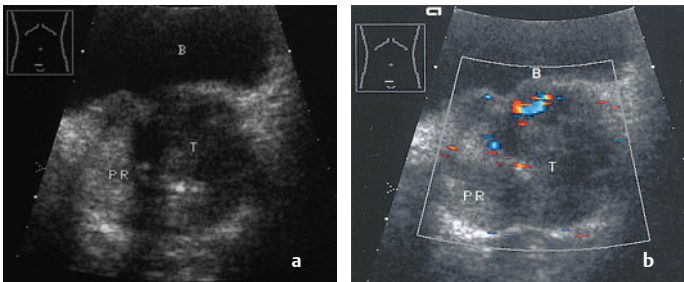


Fig. 581a, b **a** Hypoechoic mass in the left lobe of the prostate, infiltrating the right lobe (PR). Histologically confirmed prostatic carcinoma, stage IIIa. B = bladder. T = prostatic carcinoma. **b** CDS: nonhomogeneous, markedly hypoechoic mass with extracapsular extension. Sparse, aberrant spot-like vessels

- *Late signs:*
  - Irregular gland outline with discontinuities in the capsule
  - Infiltration of surrounding structures (bladder orifice, ureteral orifice, seminal vesicles, lymph nodes)
  - CDS: sparse tumor vessels

► **Chronic prostatitis, prostatic calcifications:**

- Small prostate
- Hyperechoic or heterogeneous internal echo pattern
- Echogenic = scar tissue
- Intensely echogenic calcifications with acoustic shadows (secondary to inspissated secretions or inflammation, Fig. 582)

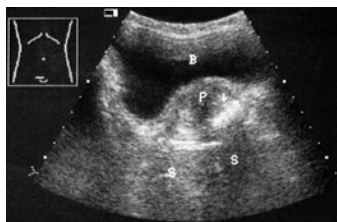


Fig. 582 Prostate stones (calculi, arrow) in a patient with presumed chronic prostatitis: very hyperechoic intraprostatic masses with distal acoustic shadows (S). B = bladder, P = prostate

► **Orchitis, abscess, hematoma** (Figs. 583, 584 and 413; see also Fig. 586a, p. 393):

- **Orchitis** (Fig. 583): e.g., viral orchitis, mumps
  - Homogeneous hypoechoic pattern
  - Enlarged testis
- **Abscess, hematoma** (see Fig. 413):
  - Circumscribed mass of very low echogenicity
  - CDS: absence of internal vessels

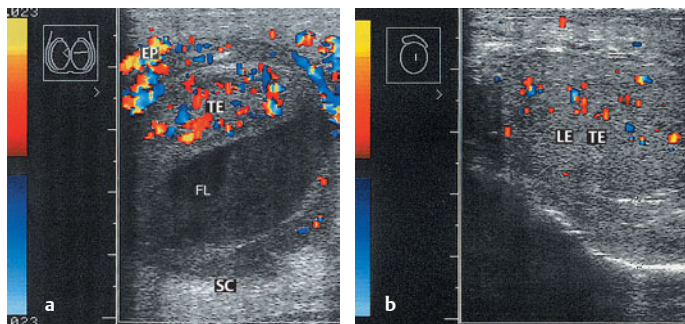


Fig. 583a, b Bacterial orchitis of the right testis with abscess formation (FL). **a** Slightly decreased echogenicity and inflammatory hypervascularity. Inflammatory edema of the scrotum (SC). EP = epididymis, TE = testis **b** Compare with the normal echogenicity and vascularity of the left testis

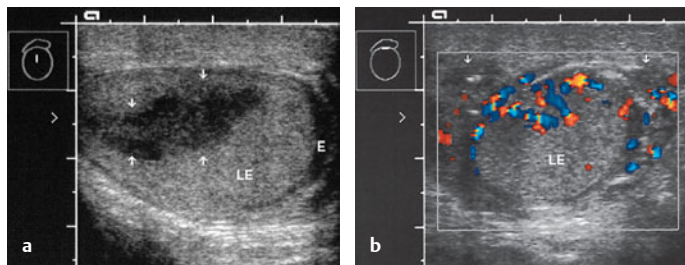


Fig. 584a, b Posttraumatic testicular hematoma. **a** B-mode image: anechoic mass. **b** CDS: absence of blood vessels in the hematoma. LE = left testis

► **Testicular tumors (Fig. 585):**

- Nonhomogeneous, predominantly hypoechoic mass
- Possible fine calcifications (“starry sky” appearance = testicular microlithiasis, may be caused by neoplasia, inflammation or chemotherapy)
- CDS: tumor vessels

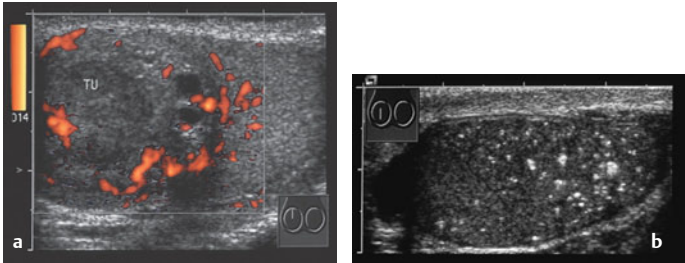


Fig. 585a, b Testicular tumors. **a** Testicular carcinoma (TU). CDS shows peripheral hypervascularity. **b** “Starry sky” appearance of right testicular calcifications following left orchietomy for a germ cell tumor

► **Hydrocele (Fig. 586a):**

- Anechoic fluid collection around the testis
- Frequently accompanied by epididymitis

► **Varicocele (Fig. 586b, c):**

- Visible and palpable dilatation of the pampiniform plexus
- Tortuous, anechoic tubular structures
- CDS: color signals in response to a Valsalva maneuver

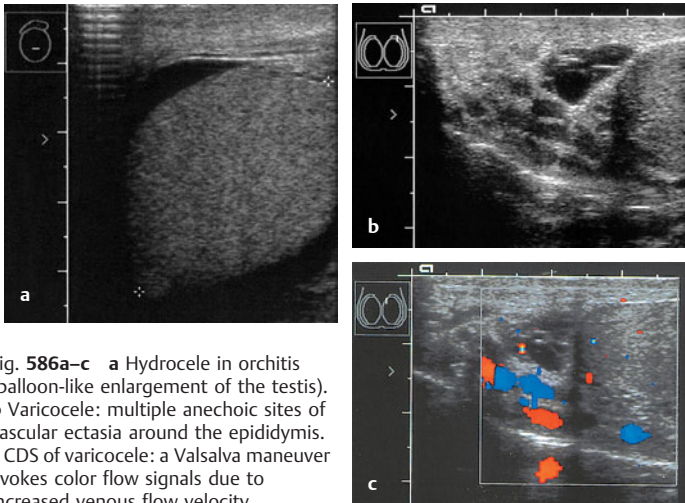


Fig. 586a–c **a** Hydrocele in orchitis (balloon-like enlargement of the testis). **b** Varicocele: multiple anechoic sites of vascular ectasia around the epididymis. **c** CDS of varicocele: a Valsalva maneuver evokes color flow signals due to increased venous flow velocity

- ▶ **Spermatocele** (Fig. 587a):
  - Anechoic mass in the region of the epididymis
  - Typical cystic criteria
  - Highly variable in size
- ▶ **Epididymitis** (Fig. 587b):
  - Enlargement of the epididymis (head, body, tail)
  - Variable echo pattern, predominantly hyperechoic to heterogeneous

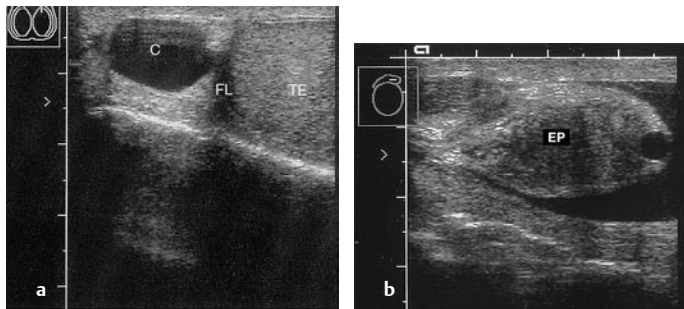


Fig. 587a, b **a** Left spermatocele: fluid collection (FL) with a cystic area (C) around the upper part of the testis. **b** Epididymitis: swollen, hypoechoic epididymis (EP) with an accompanying hydrocele. TE = testis

- ▶ **Testicular torsion** (see p. 80):
  - Testicular enlargement in the acute stage, no significant alteration of echo pattern
  - *Later*: hypoechoic or anechoic areas and a decrease in testicular size
  - *CDS*: decreased or absent blood flow
- ▶ **Urethral strictures**: The corpora cavernosa are easily distinguished by their fine echo texture from the corpus spongiosum and thus from the urethra. Urethral strictures due to scarring can be diagnosed with a high-resolution scanner after fluid instillation.

### Evaluation and Further Testing

- ▶ **Sonography**: Genital tract abnormalities are often detected incidentally on ultrasound examination, and frequently they are difficult to interpret. For this reason the essential findings should at least be classified as requiring follow-up and/or requiring further, specific investigation.

#### ▶ Further testing

**⚠ Caution:** Any indeterminate hypoechoic lesion of the prostate requires further investigation.

- Digital rectal examination (DRE), possible urological follow-up
- *Prostate-specific antigen test*: Normal PSA ranges are age-dependent, and today carcinoma is being detected even in younger men (positive family history is linked to increased risk). Combining PSA with DRE increases the positive predictive value to 49%.
- *Transrectal ultrasound (TRUS)*: Because of its low specificity and sensitivity as a screening modality, TRUS alone is generally relegated to a role in the diagnostic work-up of other abnormal screening tests like DRE and PSA and follow up after therapeutic modalities.

## 16.4 Female Genital Tract

### Overview (Table 69):

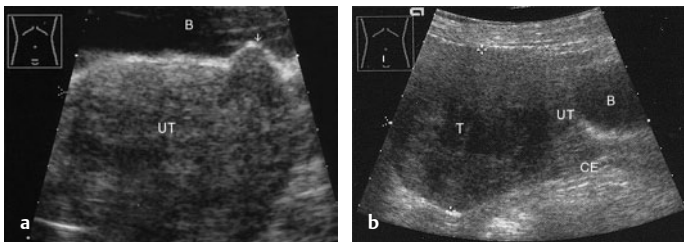
**Table 69 · Abnormal findings in the female genital organs**

Uterine myoma (p. 395)
Endometrial carcinoma (p. 395)
Cervical carcinoma (p. 396)
Foreign bodies (p. 396)
Ovarian or adnexal cysts (p. 396)
Serous cystadenoma (p. 397)
Mucinous cystoma (p. 397)
Cystadenocarcinoma (p. 397)
Meigs tumor (p. 398)
Endometriosis (p. 398)

### Abnormal Findings

#### ► Uterine myoma (Fig. 588):

- *Submucous*: polypoid mass projecting into the uterine cavity
- *Subserous*: bulge in the uterine contour
- *Intramural*: hypoechoic mass in the uterine wall
- *All*: frequent regressive changes (cystic areas, calcifications)



**Fig. 588a, b** Uterine myoma. **a** Subserous uterine myoma (arrow): isoechoic or slightly hypoechoic mass causing a bulge in the uterine contour. **b** Intramural uterine myoma (T) with an anechoic center due to regressive liquefaction. UT = uterus, CE = cervix, B = bladder. Lower abdominal longitudinal scan

#### ► Uterine carcinoma (Fig. 589):

- *Endometrial carcinoma* (Fig. 589a):
  - Endometrial thickness > 15 mm (or > 5–8 mm after menopause)
  - Nonhomogeneous echo pattern with micro- or macrocystic masses
  - Indistinct endometrial–myometrial boundary
  - Distention of the uterine cavity by exophytic tumor growth
  - Abnormal thickening of the endometrial echo with irregular boundaries

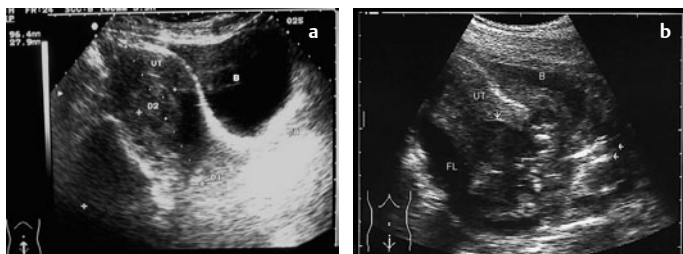


Fig. 589a, b Uterine carcinoma. **a** Endometrial carcinoma (D2), just distinguishable from the myometrium by its greater echogenicity (postmenopausal patient). UT = uterus. **b** Cervical carcinoma (arrows): heterogeneous mass with echogenic areas, located posterior to the uterus (UT) and infiltrating the bladder (B). FL = fluid

- **Cervical carcinoma** (Fig. 589b):
  - Cervix is thickened or shows barrel-shaped distention
  - Heterogeneous echo pattern
  - Anechoic to hyperechoic areas

► **Foreign bodies** (Fig. 590):

- **Coils** (Fig. 590a): intensely hyperechoic intrauterine echo (new plastic coils may be difficult to detect)
- **Tampon** (Fig. 590b): smooth, elongated echo (in longitudinal section) or a bean-shaped echo with a distal shadow in the vagina

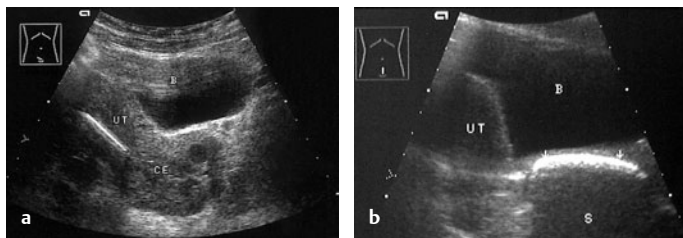


Fig. 590a, b Intrauterine foreign bodies. **a** IUD coil. Posterior to the bladder (B) is the distended cervix (CE) with hypoechoic foci consistent with microabscesses. The IUD is visible in the uterine cavity (UT). **b** Tampon: echogenic band in the vagina (arrows) with a distal acoustic shadow (S). B = bladder, UT = uterus

► **Ovarian and adnexal cysts:** simple cysts (Figs. 591 and 592):

- **Functional cysts** such as follicular and corpus luteum cysts (dependent on the menstrual cycle, Fig. 591)
- **Premenopausal cysts** < 3 cm (to 5 cm) = theca-lutein cysts (correspond to follicular cysts; multiple bilateral)
- **Paraovarian cysts:** intraligamentous, well delineated from the ovary (independent of the menstrual cycle)
- **Polycystic ovary** (Stein–Leventhal syndrome, Fig. 592): caused by unphysiological stimulation; enlarged ovaries with multiple cysts up to 5–10 cm in size and an echogenic center.

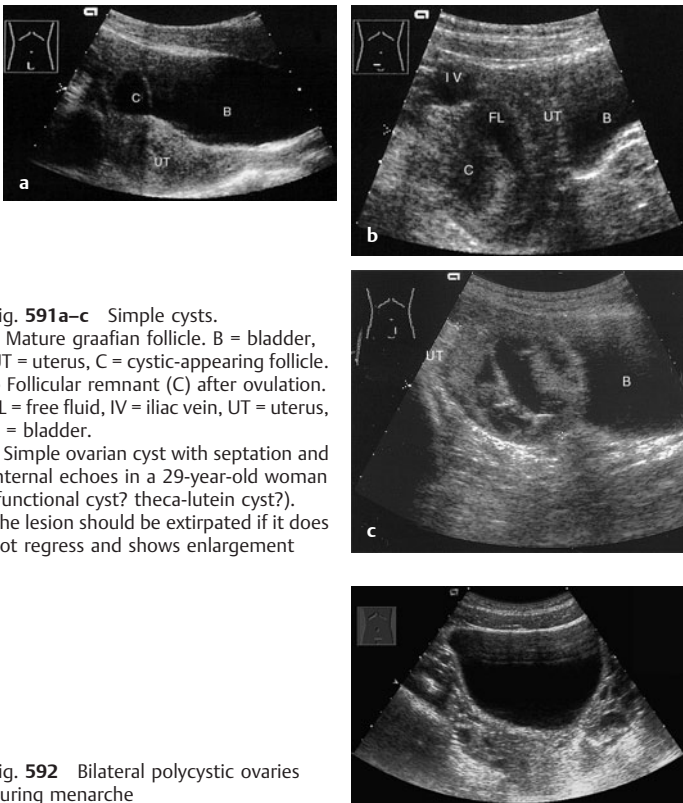


Fig. 591a–c Simple cysts.

**a** Mature graafian follicle. B = bladder, UT = uterus, C = cystic-appearing follicle.

**b** Follicular remnant (C) after ovulation. FL = free fluid, IV = iliac vein, UT = uterus, B = bladder.

**c** Simple ovarian cyst with septation and internal echoes in a 29-year-old woman (functional cyst? theca-lutein cyst?). The lesion should be extirpated if it does not regress and shows enlargement

Fig. 592 Bilateral polycystic ovaries during menarche

► **Cystic ovarian tumors** (Figs. 593 and 594):

- **Serous cystadenoma** (Fig. 593): benign
  - Unilocular
  - Sharply circumscribed, relatively small anechoic mass with echogenic (solid) components
- **Mucinous cystadenoma**: septated or loculated ovarian cyst, sometimes quite large
  - Usually unilateral
  - Large, bilateral lesions are more likely to be malignant (20% of cases).
- **Caution:** Percutaneous biopsy is contraindicated because of the risk of intra-abdominal spread.
- **Cystadenocarcinoma** (Fig. 594): A cystic mass with solid components is always suspicious for carcinoma. Ascites can often be detected because of peritoneal carcinomatosis.
  - Cyst walls show echogenic foci of tumor thickening
  - Polypoid structures projecting into the cyst

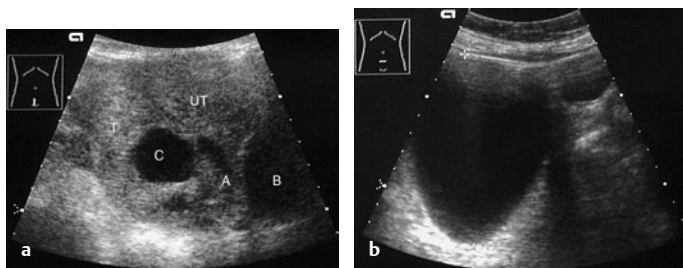


Fig. 593a, b Serous cystadenoma. **a** Hypoechoic mass (C) in the enlarged ovary (T). A = ascites, UT = uterus, B = bladder. **b** Ovarian cyst (approximately anechoic mass) in menopause, 10 cm in diameter (cysts greater than 5 cm in menopause are indications for operative treatment)

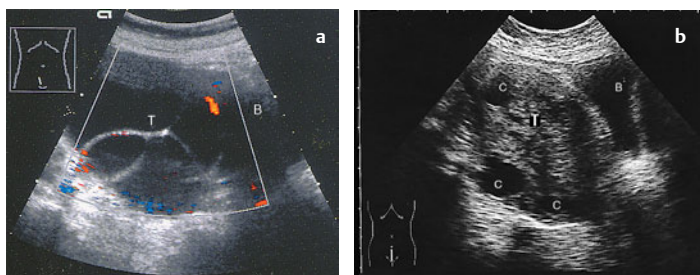


Fig. 594a, b Cystadenocarcinoma. **a** Cystic tumor (T) with fine septations and subtle tumor vessels by CDS. Serous cysts are a more common finding than mucinous cysts. B = bladder. **b** Solid (T) and cystic (C) tumor components (characteristic finding), detected incidentally at ultrasound. B = bladder

- ▶ **Ovarian tumor in Meigs syndrome:** benign ovarian fibroma with ascites and/or pleural effusion
  - Solid tumor mass projected over the ovary (see Fig. 210, p. 162)
- ▶ **Endometriosis (Fig. 595):**
  - *Endometriosis interna* (= intramyometrial adenomyosis of the uterus): ill-defined cystic mass located in the myometrium. Requires differentiation from true endometriosis

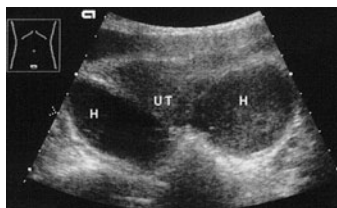


Fig. 595 Endometriosis externa with intralesional hemorrhage: hypoechoic mass, hematomas (H) due to bleeding endometriotic foci

- *Endometriosis externa* (endometriotic cysts of the ovary or fallopian tubes):
  - Nonhomogeneous anechoic/hyperechoic mass due to intralesional hemorrhage
  - CDS: absence of internal vessels

### Evaluation and Further Testing

---

- ▶ **Further testing:** Additional gynecologic studies:
  - ▣ **Note:** Every indeterminate cystic ovarian mass warrants further investigation.
  - Transvaginal sonography
  - Fine-needle aspiration or surgery, if needed

## 17 Thorax

### 17.1 Examination

#### Scan Planes

- ▶ Two main scanning techniques are used in thoracic ultrasound: subcostal and intercostal (Fig. 596).

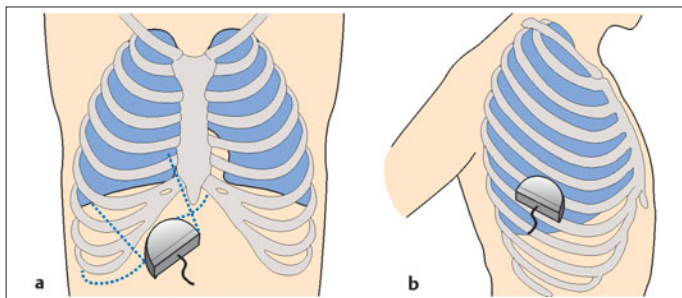


Fig. 596a, b **a** Subcostal scan: The liver serves as an acoustic window for the transducer. **b** Intercostal scan. The transducer is oriented parallel to the ribs

#### ▶ Specific scan planes:

- Transthoracic with intercostal transducer placement
- Right and left subcostal
- Supraclavicular and suprasternal
- Substernal
- High right and left flank scans

#### Sonographic Anatomy and Normal Findings

- ▶ Because ultrasound cannot penetrate aerated lung or the bony thorax, it can only demonstrate lesions that are in direct contact with the pleura or chest wall (see Figs. 605–608, p. 408, 409).
- ▶ **Interpretive criteria** (Table 70):

**Table 70** · Criteria for evaluating lesions of the chest wall, pleura, and lung parenchyma

<i>Chest wall</i>	Echogenicity (anechoic, hypoechoic, hyperechoic)
	Margins (smooth, irregular)
	Shape (round, oval, changing)
	Moving internal echoes on real-time observation
	Presence or absence of intralesional vascularity by CDS
<i>Pleura</i>	Extent of effusion
	Echogenicity (anechoic, hyperechoic)
	Septations, fibrin strands
	Pleural thickening, lung involvement
	Pleural tumors
	Moving internal echoes on real-time observation
<i>Lung parenchyma</i>	Echogenicity (hypoechoic, hyperechoic)
	Internal echo pattern, echo texture (homogeneous, nonhomogeneous)
	Margins (smooth, irregular)
	Shape (round, oval, wedge-shaped)
	Moving internal echoes on real-time observation
	Presence or absence of intralesional vascularity by CDS

### Scanning tips

- ▶ Examine the patient in the sitting position to supplement supine or semiupright scans.
- ▶ A 5.0 MHz transducer is generally best for defining chest wall lesions.
- ▶ Position the transducer parallel to the ribs to avoid interference from rib shadows.
- ▶ Use respiratory maneuvers to improve the visualization of peripheral areas.
- ▶ Raise the arms to obtain a clear projection of lesions located below the scapulae.

### Overview and Classification of Findings

- ▶ **Pleura:** The most common finding is pleural effusion. Sonography is the simplest and most effective method for the detection of pleural effusion. It also permits the further differentiation of epidiaphragmatic liquid masses.
- ▶ **Lung parenchyma:** The most important sonographic finding is the presence of nonaerated lung tissue.
- ▶ **Classification and overview:**
  - *Chest wall:* see Table 71.
  - *Pleura:* see Table 72, p. 403.
  - *Lung parenchyma:* see Table 74, p. 408.

## 17.2 Chest Wall

### Overview (Table 71):

**Table 71** · Abnormal findings in the chest wall

Hematoma (see below)
Abscess (see below)
Metastasis (see below)
Tumor infiltration (see below and p. 403)
Lipoma (see below)

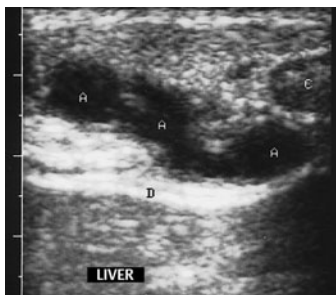### Abnormal Findings

#### ▶ Hematoma:

- Variable echogenicity
- Usually has smooth margins
- Variable shape
- May contain moving internal echoes
- CDS: absence of vascularity

#### ▶ Abscess (Fig. 597):

- Variable echogenicity, margins, and shape
- Moving internal echoes may be seen in response to compression
- CDS: absence of vascularity



**Fig. 597** Hypoechoic confluent foci (A) in the parasternal intercostal muscles. Identified cytologically as a tuberculous abscess. C = cartilaginous rib, D = diaphragm

#### ▶ Metastases:

- Usually hypoechoic
- Smooth margins
- Usually round
- CDS: vascularity

#### ▶ Tumor infiltration (Fig. 598):

- Usually hypoechoic
- Irregular margins
- Changes in shape
- Transgresses organ boundaries
- CDS: vascularity

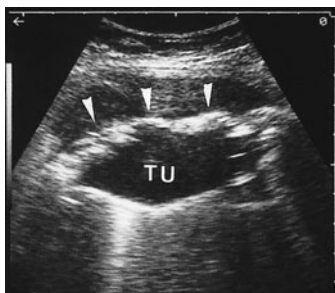


Fig. 598 Hypoechoic tumor mass (TU) with sites of rib destruction (arrows) and soft-tissue infiltration. Plasmacytoma

► **Lipoma:**

- Hyperechoic
- Smooth margins
- Usually oval
- CDS: sparse vascularity

### Evaluation and Further Testing

► **Clinical findings:** frequently suggest the correct diagnosis, e.g.:

- Hematoma → trauma
- Abscess → inflammatory signs
- Metastases → primary tumor
- Lipoma → often an asymptomatic incidental finding

► **Further testing:** Chest radiographs should always be obtained. Doubtful cases should be investigated by ultrasound-guided fine-needle aspiration histology and if necessary by CT.

- *With an abscess:* eradicate by repetitive percutaneous drainage (see also p. 53) and if necessary by catheter drainage
- *With hematomas and metastases:* ultrasound follow-ups

## 17.3 Pleura

### Overview (Table 72):

#### Table 72 · Abnormal findings in the pleura

Transsudative effusion (p. 403)

Benign exudative effusion (p. 404)

Malignant exudative effusion (p. 404)

Pleural tumors (p. 405)

### Abnormal Findings

► **Transsudative effusion (Fig. 599):**

- Anechoic
- Variable extent, usually small
- Fine pleural line

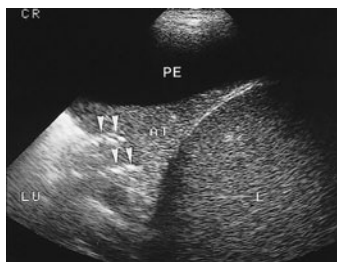

Fig. 599 Anechoic pleural effusion (PE) with associated compression atelectasis (AT) and visualization of air-filled bronchi (arrows) in a patient with heart failure. LU = lung, L = liver

► **Benign exudative effusion** (Figs. 600 and 601):

- Anechoic, echogenic, or with fibrin strands
- Frequent septations (Fig. 601)
- Possible pleural thickening and concomitant lung involvement
- Possible moving echoes

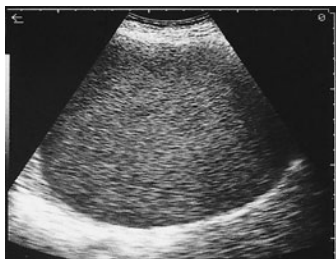

Fig. 600 Echogenic pleural effusion with moving echoes in the real-time examination. Thoracentesis yielded a hemorrhagic exudate

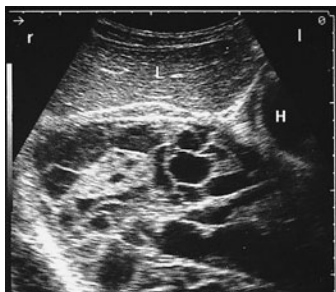

Fig. 601 Pleural effusion loculated by fibrin strands, creating a honeycomb-like appearance. Percutaneous needle aspiration is often unproductive with this type of effusion. H = heart, L = liver

► **Malignant exudative effusion** (Figs. 602 and 603):

- Like a benign exudative effusion (see above)
- Detectable pleural tumors

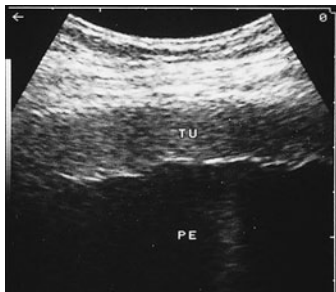

Fig. 602 Plaque-like tumor (TU) growing along the parietal pleura in a patient with bronchial carcinoma. PE = pleural effusion

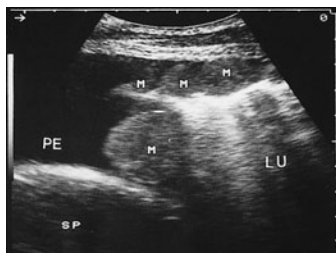

Fig. 603 Nodular tumor mass (M) abutting the visceral pleura in a patient with bronchial carcinoma. PE = pleural effusion, LU = lung, SP = spleen

► **Pleural tumors:**

- Variable shape (plaque-like, nodular)
- Usually hypoechoic
- Variable sites of occurrence (diaphragmatic, visceral, parietal)
- Tumors > 1 cm in size or thickness are most likely malignant.

### Evaluation and Further Testing

- **Clinical features of pleural effusion:** frequently suggest the correct diagnosis:
- *With a transsudative effusion:* symptoms (dyspnea) depend on the extent of the effusion
  - *With an inflammatory etiology:* signs of inflammation, pain with respiratory excursions (pleurisy)
  - *With a malignant etiology:* frequent copious effusion with significant dyspnea
- **Types of pleural effusion** (Table 73):

**Table 73 · Causes and types of pleural effusion**

Transsudate	Exudate	
	<i>Inflammatory effusion</i>	<i>Hemorrhagic effusion</i>
<i>Analysis of aspirate</i>		
Protein < 3 g/dl	Protein > 3 g/dl	Protein ≥ 3 g/dl
Hypocellular	Hypercellular aspirate	Bloody
LDH < 200 U/L	Cholesterol > 60 mg/dl	
<i>Causes (examples)</i>		
Heart failure	Pleuropneumonia	Hemothorax
Hepatic cirrhosis	Pulmonary infarction	Tumor hemorrhage
Hypoalbuminemia	Collagen disease	
<i>Characteristic sonographic findings</i>		
Anechoic	Anechoic or internal echoes	Hypoechoic with internal echoes
Fine pleural lines	Septations, fibrin strands	Possible sediment echoes (snowstorm pattern)
Frequent bilateral parenchymal lesions	Accentuated pleural lines	

**Table 73 · Causes and types of pleural effusion – continued****Exudate, continued**

<i>Chylous effusion</i>	<i>Purulent effusion</i>	<i>Malignant effusion</i>
<i>Analysis of aspirate</i>		
Protein > 3 g/dL	Protein > 3 g/dL	Protein > 3 g/dL
Milky, turbid	Debris	Possible tumor cells
Triglycerides > 110 mg/dL		
<i>Causes (examples)</i>		
Thoracic trauma	Pleural empyema	Peritoneal carcinomatosis
Malignant lymphoma	Pyothorax	Malignant mesothelioma
		Malignant lymphoma
<i>Characteristic sonographic findings</i>		
Hyperechoic with high-amplitude internal echoes (snowstorm pattern)	Variable, may be hyperechoic	Anechoic or internal echoes
	Absence of pleural movements	Septation, fibrin strands
	Pleural tumors	Parenchymal lesions

**► Further testing:**

- Chest radiographs should always be obtained.
- *Pleural effusion* (Fig. 604): ultrasound-guided diagnostic aspiration of the effusion. Diagnostic and therapeutic drainage, see p. 58
- *Suspected pleural tumor*: may be investigated by pleural biopsy, ultrasound-guided percutaneous biopsy of the lesion, or thoracoscopy

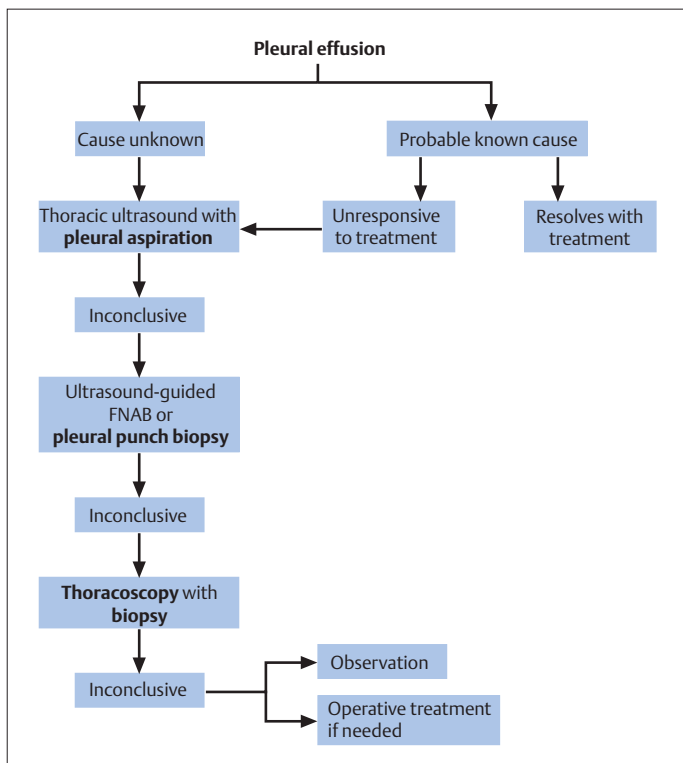


Fig. 604 Diagnostic algorithm for pleural effusion (after Schwerk and Görg)

## 17.4 Lung Parenchyma

### Overview (Table 74):

**Table 74 · Abnormal findings in the lung parenchyma**

Pulmonary tumors (p. 408)
Pulmonary metastases (p. 408)
Pulmonary abscess (p. 409)
Pneumonia (p. 409)
Compression atelectasis (p. 409)
Obstructive atelectasis (p. 410)
Pulmonary infarction (p. 410)

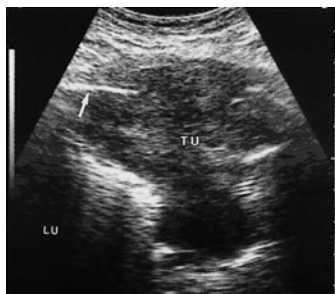### Abnormal Findings

#### ► Lung tumors (Fig. 605):

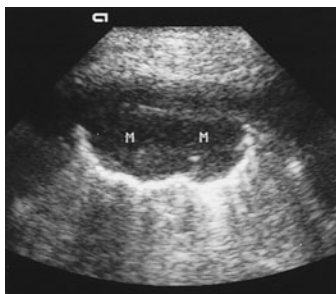
- Usually hypoechoic
- Variable echo pattern
- Variable shape and margins
- Frequently transgress organ boundaries
- CDS: vascularity

#### ► Pulmonary metastases (Fig. 606):

- Usually hypoechoic
- Homogeneous
- Round with smooth margins
- Not fixed to the chest wall on real-time observation
- CDS: vascularity



**Fig. 605** Peripheral hypoechoic bronchial carcinoma with irregular margins. The tumor (TU) has infiltrated the pleura (arrow) and chest wall. LU = lung



**Fig. 606** Hypoechoic peripheral pulmonary metastases (M), which move with respiratory excursions (patient had a malignant pulmonary blastoma)

► **Pulmonary abscess (Fig. 607):**

- Variable echogenicity
- Nonhomogeneous echo pattern
- Occasional air echoes
- Usually elliptical with smooth margins
- Moving internal echoes
- Accentuated walls
- *CDS*: absence of vascularity

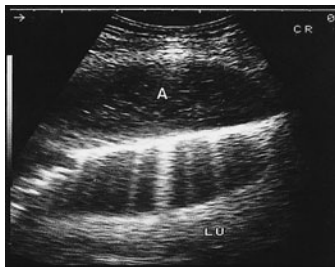


Fig. 607 Hypoechoic liquid mass in the pleural space (A), air-fluid level on the visceral pleura. Needle aspiration yielded purulent fluid consistent with an abscess. (LU = lung)

► **Pneumonia (Fig. 608):**

- Usually hypoechoic
- Very nonhomogeneous texture (air bronchogram), depending on the extent of consolidation
- Irregular margins
- Accentuated pleural walls
- Variable shape
- Occasionally accompanied by effusion
- *CDS*: frequent increase in vascularity

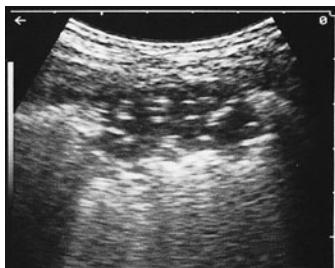

Fig. 608 Pleural-wall lesion with irregular margins, predominantly hypoechoic with multiple high-amplitude air echoes as in pneumonia

► **Compression atelectasis (Fig. 609):**

- Hypoechoic
- Homogeneous
- Variable margins
- Occasionally wedge-shaped
- Size varies with respiratory excursions on real-time observation
- Extent depends on the size of the pleural effusion
- *CDS*: increased vascularity may be noted with proper equipment and technique
- *After percutaneous drainage*: partial reinflation

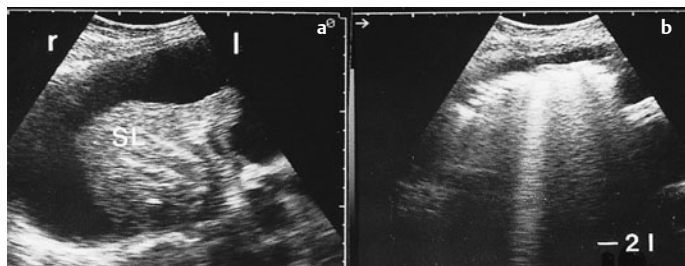


Fig. 609a, b **a** Scan demonstrating the right upper lobe (SL) with the echogenic (aerated) bronchial tree and a significant effusion. **b** Following the percutaneous aspiration of 2L of fluid, the upper lobe is re-inflated as in compression atelectasis

► **Obstructive atelectasis** (Figs. 610 and 611):

- Hypoechoic
- Homogeneous
- Smooth margins with lobar atelectasis
- Variable shape
- *With complete atelectasis:* homogeneous consolidation of the lung
- *CDS:* increased vascularity may be noted with proper equipment and technique
- *In cases with pleural effusion:* lung does not re-inflate after drainage
- Central mass is occasionally noted

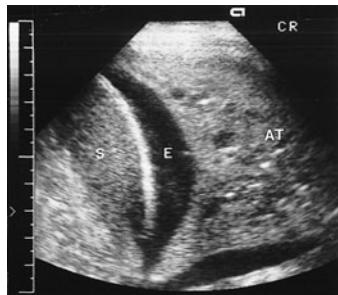


Fig. 610 Lateral intercostal scan shows complete atelectasis of the left lung (AT) with a centrally located bronchial carcinoma. S = spleen, E = pleural effusion

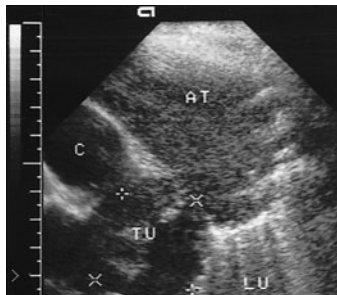


Fig. 611 Partial atelectasis of the left upper lobe (AT). The central tumor (TU) is visualized through the acoustic window of the atelectasis (AT). C = heart, LU = lung

► **Pulmonary infarction** (Fig. 612):

- Hypoechoic
- Nonhomogeneous texture depending on the extent of consolidation
- Irregular margins
- Frequently wedge-shaped
- Frequently multiple
- *CDS:* absence of vascularity
- Occasional small concomitant effusion

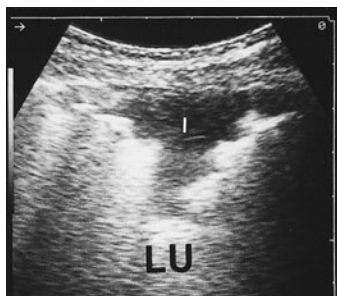

Fig. 612 Wedge-shaped hypoechoic lesion with irregular margins in the periphery of the lung. Scintigraphy confirmed the infarction due to pulmonary embolism. LU = lung, I = postinfarction pneumonia

### Evaluation and Further Testing

- ▶ **Clinical features:** frequently suggest the correct diagnosis, e.g.:
  - Pulmonary metastasis → primary tumor
  - Pulmonary abscess → fever
  - Pneumonia → coarse rales
  - Pulmonary infarction → deep lower-extremity venous thrombosis, etc.
- ▶ **Further testing:**
  - Chest radiographs should always be obtained
  - FNAB to establish the diagnosis (e.g., lung tumors, pulmonary metastases, pulmonary abscess, pneumonia)
  - CT is advised for obstructive atelectasis, pneumonia, etc.
  - Catheter drainage is indicated for pulmonary abscess
  - Ultrasound follow-ups are often recommended

## 18 Thyroid Gland

### 18.1 Examination

#### Scan Planes

- ▶ Transverse scan of the neck
- ▶ Oblique scan of the neck
- ▶ **Scanning tip:** When using CDS, always use a window setting that covers the entire thyroid lobe and use a consistent PRF setting such as 0.06 m/s.

#### Sonographic Anatomy and Normal Findings

- ▶ The thyroid gland is scanned from anterior to posterior in transverse section (contrasting with the “butterfly” shape seen in anatomical textbooks and isotope scans).
- ▶ **Sonographic anatomy** (Figs. 613 and 614): The trachea can be seen just posterior to the thyroid gland. The esophagus appears behind and to the left of the trachea and posterior to the left thyroid lobe. The principal blood vessels in the neck run posterolateral to the thyroid lobes.

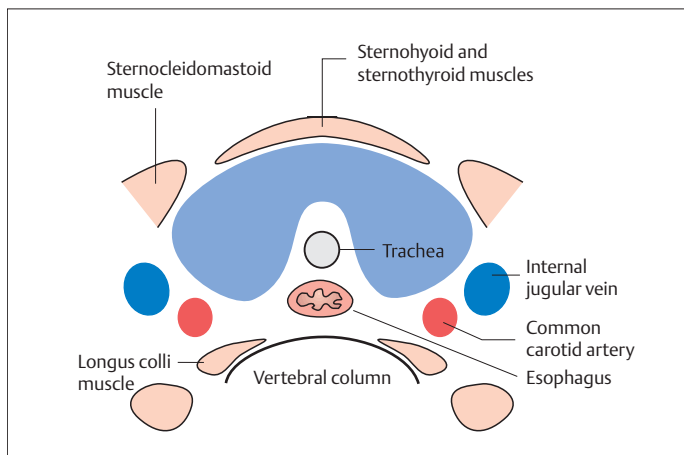


Fig. 613 Schematic cross-section of the neck at the level of the thyroid gland

- ▶ **Normal findings** (Fig. 615): The thyroid gland is covered by a capsule that clearly delineates it from surrounding tissues. It has a grainy, homogeneous echo texture and is hyperechoic to the surrounding muscles.
- ▶ **Normal dimensions:** length 40–70 mm, width 10–30 mm, depth 10–20 mm (per lobe). The isthmus is < 5 mm in width.
  - **Total volume:** < 25 mL in men, < 20 mL in women
  - **Volumetry:** length × width × depth × 0.5 for each thyroid lobe

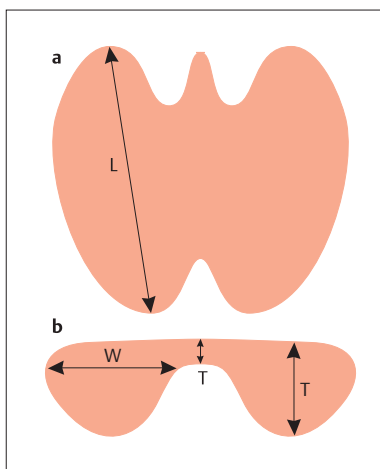


Fig. 614a, b Schematic representation of the thyroid gland. **a** Frontal view, **b** cross-sectional view. L = length of gland, W = width of gland, T = thickness of gland

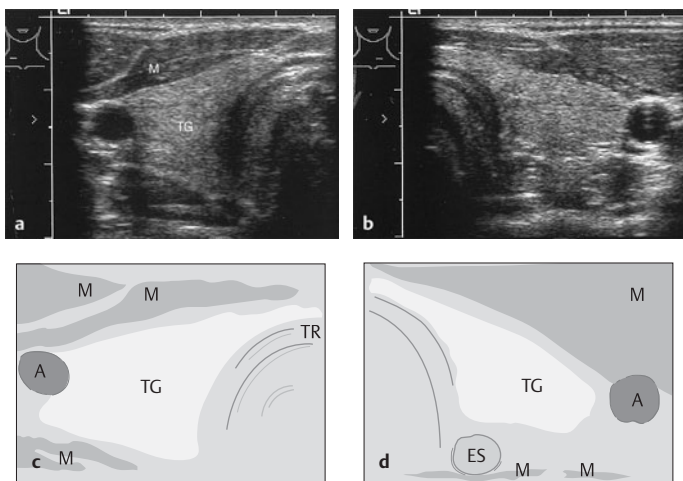


Fig. 615a–d Normal thyroid gland. Transverse scans of the right and left thyroid lobes show a normal echogenic structure. A = common carotid artery, TG = right and left lobes of thyroid gland, M = anterior and posterior neck muscles, ES = cervical esophagus, TR = trachea

## Aids to Examination

- ▶ **Transducer:** 5.0–7.5 MHz
- ▶ Longitudinal scan in each maximum dimension, serial transverse scans while moving the transducer over the skin (Fig. 614).
- ▶ Parathyroid glands can be defined by ultrasound only when they are enlarged (each is located posterior to the upper and lower poles of the thyroid gland).
- ▶ **Note:** Pain during examination may indicate thyroiditis.

## Overview and Classification of Findings

- ▶ The indication for ultrasonography of the thyroid gland may be a functional disorder (hyper- or hypothyroidism) or a goiter. In many cases the findings are surprising and difficult to interpret. Particular attention will be given to those findings in this chapter.
- ▶ The differential diagnosis and functional aspects of specific thyroid disorders are covered more fully in Section 6.14 (p. 179).
- ▶ An ultrasound examination of the thyroid gland should always include an assessment of the parathyroid glands. Sometimes they must be included in the differential diagnosis of thyroid nodules. Parathyroid adenomas and hyperplasia appear as hypoechoic nodules located posterosuperior or posteroinferior to the thyroid gland (see p. 423).
- ▶ **Classification and overview:** Thyroid changes that are observed on ultrasound may be classified as diffuse or circumscribed:
  - *Diffuse changes:* may relate to the size or echogenicity of the gland; see Table 75.
  - *Circumscribed changes:* range from anechoic (cyst) to intensely echogenic (calcification); see Table 76.

## 18.2 Diffuse Changes

### Overview (Table 75):

**Table 75 · Diffuse changes in the thyroid gland**

Hypoechoic or normal echogenicity	Hyperechoic
Acute or subacute thyroiditis (p. 415)	Diffuse colloid goiter (p. 416)
Hashimoto thyroiditis (p. 415)	Regressive fibrotic changes (p. 416)
Hyperthyroidism in Graves disease (p. 415)	
Riedel thyroiditis (p. 416)	
Malignant lymphoma (p. 416)	
Diffuse parenchymatous goiter (p. 416)	

### Hypoechoic Changes

- ▶ **Note:** The echogenicity of the thyroid gland is always evaluated in relation to that of the neck muscles. As a general rule, autoimmune thyroid disorders are all characterized by a diffuse decrease in echogenicity, although different entities can often be distinguished based on differences in their echo patterns.

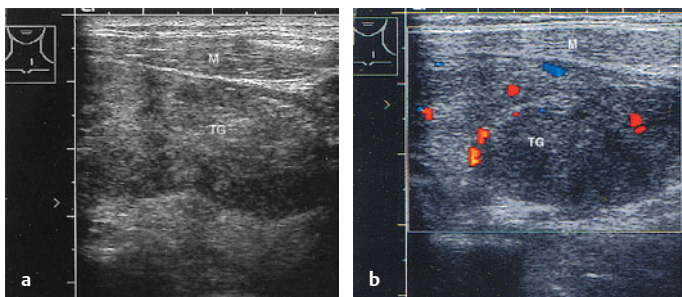


Fig. 616a, b Subacute de Quervain thyroiditis. **a** B-mode image: patchy hypoechoic thyroid gland (TG; compare with muscle, M). **b** CDS: individual color spots. The hypoechoic areas are largely devoid of vessels

- ▶ **Acute and subacute de Quervain thyroiditis** (Fig. 616): This disease presents clinically with acute malaise, local tenderness, inflammatory laboratory parameters, and frequent transient hyperthyroidism.
  - Large hypoechoic areas with ill-defined margins, interspersed among areas of normal echogenicity
  - Overall impression: patchy hypoechoic pattern
  - CDS: increased vascularity. Sclerotic areas are hyperechoic and hypovascular
- ▶ **Chronic lymphocytic Hashimoto thyroiditis** (Fig. 617): Patients present clinically with asymptomatic hypothyroidism of early onset and a shrunken, fibrotic gland. Other findings are an elevated ESR and high titers of thyroid peroxidase (TPO) antibodies and thyroglobulin (Tg) antibodies (see also Fig. 245, p. 183).
  - Stippled or diffuse hypoechoic pattern
  - End stage marked by small, hypoechoic thyroid remnants
  - Scarred areas appear hyperechoic
  - CDS: marked increase in vascularity
- ▶ **Hyperthyroidism in Graves disease** (Fig. 618; see also Figs. 243 and 244, p. 182): Patients present clinically with a goiter and classic signs of hyperthyroidism: weight loss, tachycardia, endocrine ophthalmopathy, and a thyroid bruit due to increased vascularity.

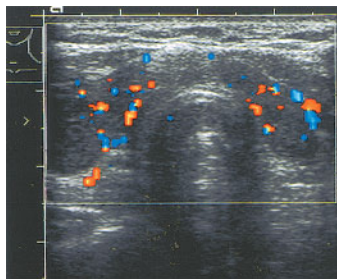


Fig. 617 Chronic Hashimoto thyroiditis: uniformly hypoechoic thyroid gland with a slight increase in vascularity

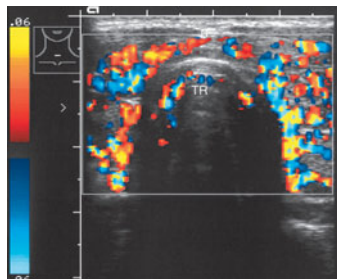


Fig. 618 Graves goiter. CDS: marked hypervascularity ("vascular inferno"). Median transverse scan of the neck. TR = trachea

- Marked swelling, especially of the isthmus
  - Stippled or diffuse pattern of decreased echogenicity
  - *CDS*: increased vascularity (“vascular inferno” after Ralls)
  - *Spectral analysis*: increased flow velocity in the inferior thyroid artery, up to 125 cm/s.
- ▶ **Riedel thyroiditis** (synonym: chronic sclerosing thyroiditis): rare; presents clinically as a “stony-hard” goiter
- Diffuse hypoechoic pattern caused by hyaline connective tissue
  - Smooth, distinct bulge in the contour of the gland
- ▶ **Malignant lymphoma**: invasive, confluent nodular mass of low echogenicity
- ▶ **Parenchymatous goiter**: diffuse enlargement of the thyroid gland
- Normal echo pattern (Fig. 619a)
  - Requires differentiation from lipoma (Fig. 619c)

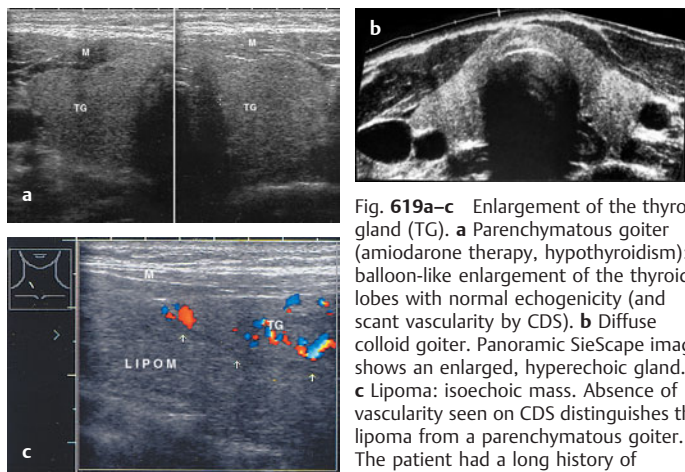


Fig. 619a–c Enlargement of the thyroid gland (TG). **a** Parenchymatous goiter (amiodarone therapy, hypothyroidism): balloon-like enlargement of the thyroid lobes with normal echogenicity (and scant vascularity by *CDS*). **b** Diffuse colloid goiter. Panoramic SieScape image shows an enlarged, hyperechoic gland. **c** Lipoma: isoechoic mass. Absence of vascularity seen on *CDS* distinguishes the lipoma from a parenchymatous goiter. The patient had a long history of hormone replacement therapy for a goiter. M = muscle

### Hyperchoic Changes

- ▶ **Diffuse colloid goiter** (Fig. 619b):
- *Clinical features*: Histologically, the goiter is comprised chiefly of colloid-containing macrofollicles. Like diffuse parenchymatous goiter, it is classified as a type of alimentary iodine-deficiency goiter. It is most prevalent in young people who live in iodine-deficient regions. Diffuse colloid goiter has a relatively coarse hyperechoic pattern (mostly macrofollicles), contrasting with the unchanged echo pattern of a parenchymatous goiter (mostly normal-sized follicles).
  - *Sonographic features*:
    - Enlargement of the thyroid gland
    - Coarse, hyperechoic pattern
- ▶ **Regressive fibrotic changes in the thyroid gland** (Fig. 620):
- *Clinical features*: may occur in a long-standing diffuse goiter or an irradiated goiter. Fine, isoechoic nodules can be differentiated by their hypoechoic halo.

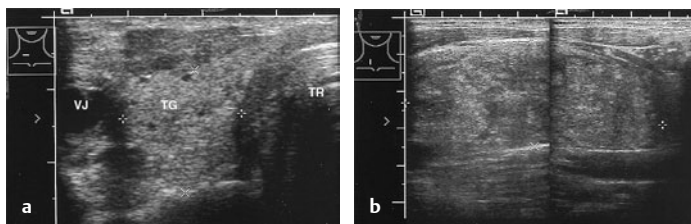


Fig. 620a, b Regressive changes in the thyroid gland. **a** Hyperechoic fibrotic changes in the thyroid gland (TG) following irradiation (primary tumor: palatal carcinoma). TR = trachea, JV = jugular vein. **b** Predominantly hyperechoic thyroid gland with a nodular goiter and regressive fibrotic changes

Regressive changes marked by the formation of collagenous (i.e., echogenic) connective tissue have a similar appearance to diffuse colloid goiter (usually distinguishable by CDS, which demonstrates perinodal vessels).

- *Sonographic features:*
  - Hyperechoic goiter, frequently asymmetrical
  - Nonhomogeneous internal echo pattern
  - Long history of a goiter (or recurrent goiter) or previous radiotherapy to the thyroid gland

## 18.3 Circumscribed Changes

### Overview (Table 76):

**Table 76** · Circumscribed changes in the thyroid gland

Anechoic	Hypoechoic or isoechoic	Hyperechoic
True cysts (p. 417)	Adenomatous hyperplasia (nodular goiter, p. 417)	Hyperechoic adenomatous nodules (p. 422)
Cystic transformation (pseudocysts, p. 418)	Adenoma (p. 419)	Hyperechoic adenoma (p. 422)
	Colloid nodule (p. 419)	Regressive changes in a nodular goiter (p. 422)
	Hyaline connective tissue (p. 419)	Calcifications (p. 422)
	Abscess (p. 419)	
	Oncocytoma (p. 420)	
	Malignant tumor, metastasis (p. 420)	

### Anechoic Changes

- ▶ **True (epithelium-lined) cysts:** rare
  - Round and anechoic with smooth margins
  - Distal acoustic enhancement

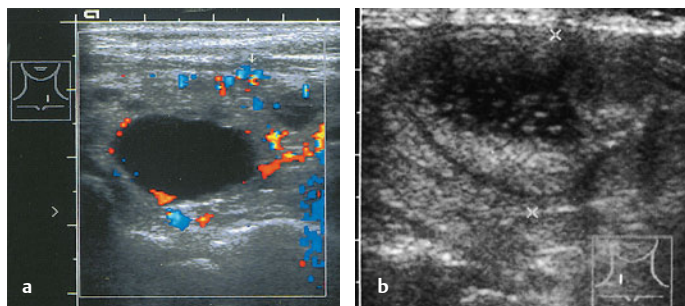


Fig. 621a, b Cystic transformation. **a** Cystic regression in a nodular goiter. CDS: avascular nodular area. **b** Cystic transformation with coarse, floating echos correlating with a fresh intranodular hemorrhage (cursors)

- ▶ **Cystic transformation** (“pseudocysts,” Figs. 621 and 624): regressive changes in goiters, adenomas or other tumors. Usually result from intralesional hemorrhage. Percutaneous aspirate from a fresh lesion is bloody, later becoming brown (“chocolate cysts”) and finally yellowish (“yellow cyst”). The differential diagnosis includes lymph cysts and small colloid cysts.
  - Classic cystic features as above, but more likely to have a noncircular shape
  - **Hyperechoic internal structures (clots, septa):**
    - *Fresh:* flocculent internal echo pattern
    - *Old:* completely anechoic

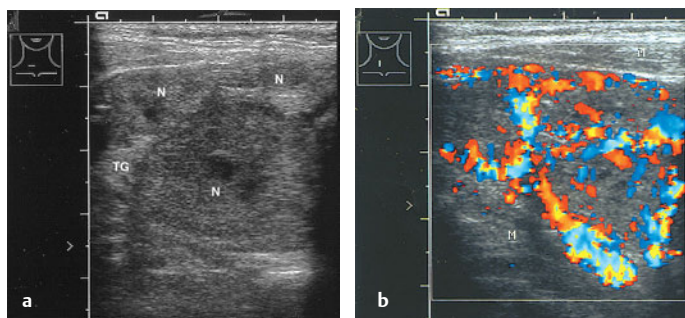


Fig. 622a, b Adenomatous nodules (nodular goiter). **a** Transverse B-mode image: hypoechoic nodule (N). TG = thyroid gland. **b** CDS in longitudinal section: The nodules are surrounded by intense peripheral vascularity. M = anterior and posterior neck muscles

### Hypoechoic and Isoechoic Changes

- ▶ **Adenomatous hyperplasia** (adenomatous nodule, Fig. 622): nodular transformation of a long-standing goiter. With multiple nodules: nodular goiter. Histologic examination shows a close-packed arrangement of small and large follicles.

- Adenomatous hyperplasia is usually isoechoic (or hyperechoic) and less commonly hypoechoic. (The hypoechoic pattern usually signifies multifocal autonomy.)
- Several (rarely solitary) or multiple nodules in one goiter
- Hypoechoic halo due to vascular displacement. (This halo sign does not suggest malignancy as it does in hepatic metastases.)
- Frequent regressive changes (pseudocystic transformation, connective tissue, calcification), often producing a very heterogeneous echo pattern
- CDS: peripheral blood vessels; increased vascularity in hypoechoic nodules
- ▶ **Adenomas** (Fig. 623; see also Fig. 242, p. 181, and Fig. 630, p. 422):
  - *Clinical features*: true benign neoplasms (“follicular adenomas”) with their own vascular supply. They are not involved by immune-mediated inflammation.
  - Adenomas may be composed of microfollicles, normal follicles, or macrofollicles. Macrofollicular adenomas are hyperechoic owing to their thick walls.
  - Most adenomas occurs as solitary lesions in a normal thyroid gland (unlike adenomatous nodules, which are usually multiple and develop in a goiter).
  - *Sonographic features*: The echogenicity of adenomas ranges from hypoechoic to hyperechoic:
    - *Hypoechoic*: microfollicular type; often appear scintigraphically as “hot” nodules, contrasting with hyperechoic adenomas
    - *Hyperechoic*: macrofollicular type, usually appear as “cold” nodules on scintiscans
    - Hypoechoic halo

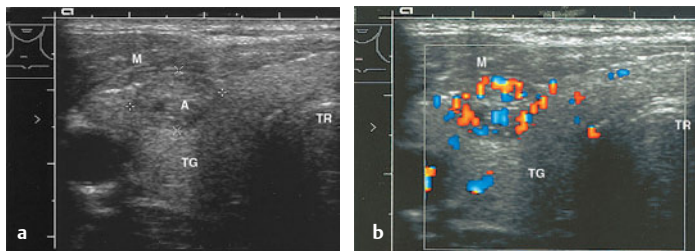


Fig. 623a, b Adenoma (A) of the thyroid gland (TG). **a** B-mode image: hypoechoic mass. **b** CDS: hypoechoic vascular rim plus internal vascularity. TR = trachea, M = anterior neck muscle

- ▶ **Colloid nodules** (Fig. 624):
  - Predominantly hypoechoic or isoechoic nodules
  - *Fine-needle aspiration*: colloid
- ▶ **Hyaline connective tissue**: regressive change consisting of hypoechoic hyaline connective tissue, indistinguishable from malignant tumors (see Fig. 628, p. 421; Riedel goiter)
  - Very hypoechoic (no echogenic interfaces)
  - Usually occurs in adenomas
  - Frequent calcifications
  - CDS: absence of vascularity
- ▶ **Abscess** (acute bacterial thyroiditis, Fig. 625): presents clinically with fever, a tender neck mass, and laboratory signs of inflammation
  - Nonhomogeneous hypoechoic mass

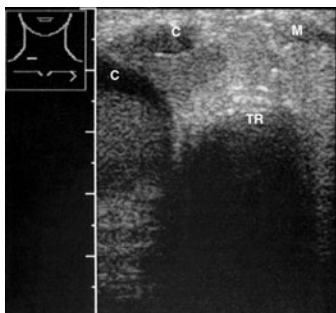


Fig. 624 Colloid nodules. Two cystic areas (C), one with internal echoes. FNA yielded a creamy colloidal fluid. M = muscle, TR = trachea

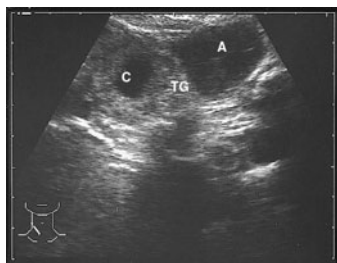

Fig. 625 Thyroid abscess (A) in acute bacterial thyroiditis. C = thyroid pseudocyst in an adenoma, TG = rest of normal-appearing thyroid gland

- Irregular margins
- CDS: absence of vascularity

► **Oncocytoma** (follicular neoplasia, Fig. 626):

- Hypoechoic mass
- Frequently lacks a halo
- CDS: scant vascularity

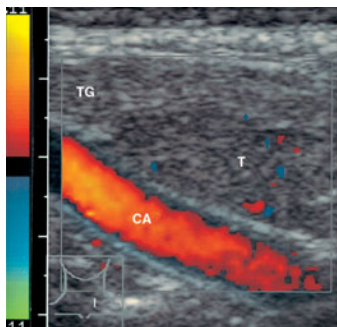


Fig. 626 Oncocytoma (T): benign hypoechoic tumor in a normal thyroid gland (TG). CA = carotid artery

► **Malignant tumor** (Figs. 627–629): metastases; lymphomas; follicular, papillary or medullary thyroid carcinoma.

- *Clinical aspects:* Early lesions are asymptomatic and are detected fortuitously. Suspicion is raised by the de novo appearance of a firm thyroid nodule, a rapidly enlarging goiter, dyspnea, cervical lymphadenopathy, and distant metastases.
- Hypoechoic mass
- May contain slight nonhomogeneities or microcalcifications (anaplastic carcinoma: complex echo pattern, Fig. 628b)
- CDS: incomplete (vascular) rim and internal vascularity, indistinguishable from adenoma
- Infiltrative growth confirms the malignancy.

Fig. 627 B-cell lymphoma involving the thyroid gland. CDS: very hypoechoic mass with no detectable vascularity

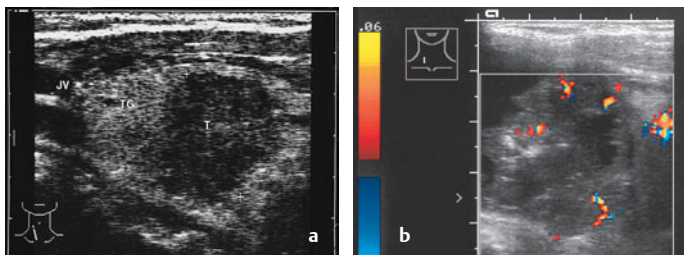


Fig. 628a, b Malignant tumors. **a** Infiltrative tracheal carcinoma (T, cursors). The patient presented clinically with severe stridor. TG = thyroid gland, JV = jugular vein **b** Undifferentiated anaplastic carcinoma: heterogeneous tumor with a hypoechoic basic structure, internal vascularity, anechoic areas of central liquefaction, and echogenic microcalcifications

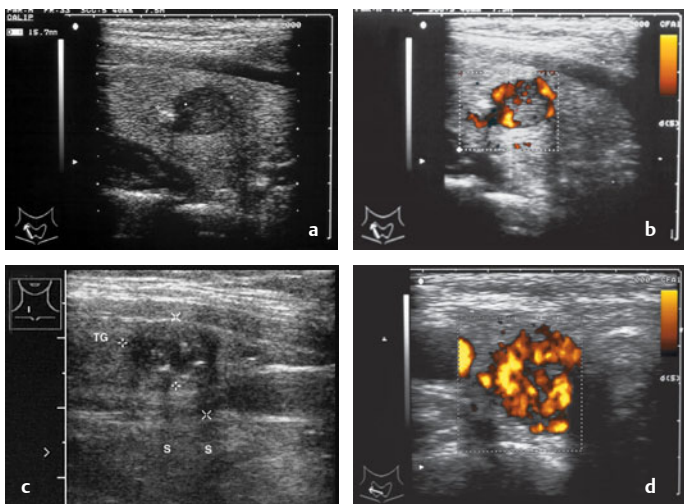


Fig. 629a–d Thyroid tumors. **a** C-cell carcinoma: hypoechoic mass (cursors) with a small, shadowing calcification and an echogenic halo. **b** B-cell carcinoma. CDS shows intense peripheral vascularity around a portion of the tumor plus internal vascularity. **c** Squamous cell carcinoma: hypoechoic mass (cursors) with microcalcifications. TG = thyroid gland, S = shadow. **d** Metastasis from a malignant melanoma. CDS shows pronounced internal vascularity

## Hyperechoic Changes

- ▶ **Hyperechoic adenomatous nodules:**
  - Solitary or multiple nodules in a goiter
  - Hypoechoic halo
- ▶ **Hyperechoic adenoma (Fig. 630):**
  - Hyperechoic nodule in a normal thyroid gland
  - CDS: peripheral vascularity with little or no intralesional vascularity

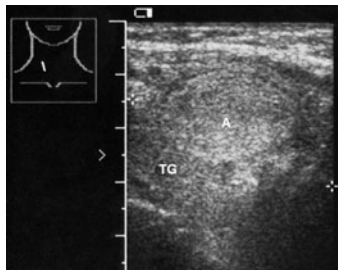


Fig. 630 Hyperechoic adenoma (A) in a normal thyroid gland (TG, cursors), delineated by its peripheral vascularity

- ▶ **Regressive changes in a nodular goiter (collagenous connective tissue, Fig. 631):**
  - Coarse, irregular hyperechoic pattern
  - Irregular margins

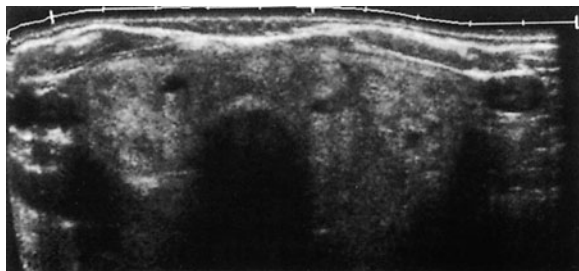
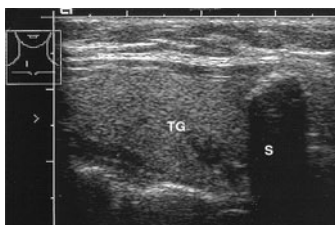

Fig. 631 Nodular goiter with regressive changes (cysts, connective tissue): mottled, very nonhomogeneous internal echo pattern (SieScape)

- ▶ **Calcifications (Fig. 632):** in nodules or tumors
  - ▶ **Note:** Paratracheal echoes may be mistaken for the trachea itself, so identify the trachea first before looking for possible calcifications.
    - High-amplitude echoes with distal acoustic shadows
    - Focal, patchy, or eggshell configuration

Fig. 632 Thyroid calcification: hyperechoic eggshell calcification with a distal acoustic shadow (S). TG = thyroid gland



### Evaluation and Further Testing

#### ► Sonography:

- **Differentiation from nodules:** The differential diagnosis should include parathyroid hyperplasia and adenomas, which appear as hypoechoic nodules located posteroinferior or posterosuperior to the thyroid gland. They may also extend into the thyroid gland itself (Fig. 633).

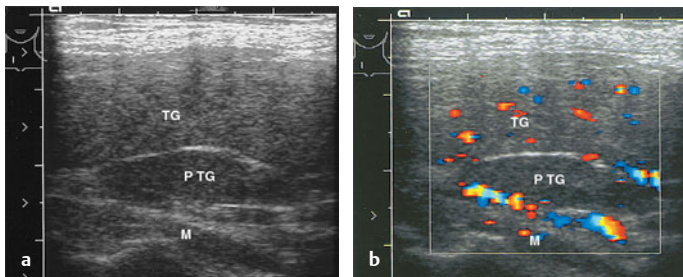


Fig. 633a, b Parathyroid adenoma. **a** B-mode image: hypoechoic retrothyroid mass (M). **b** CDS: no intratumoral vessels. TG = thyroid gland, PTG = parathyroid gland

- Cold nodules detected by scintigraphy are easily differentiated by ultrasound: cysts and hypoechoic tumors contrast sharply with calcifications and hyperechoic nodules.
- Diagnostic and therapeutic procedures can be done under sonographic guidance (see *Interventional Ultrasound*, p. 53):
  - Ultrasound-guided FNAB
  - Ultrasound-guided evacuation of cysts
  - Alcohol instillation (1–4 mL of 96% alcohol) into hot nodules detected by scintigraphy (generally hypoechoic by ultrasound)

#### ► Further testing:

- **Normal structured thyroid gland or diffuse goiter of normal echogenicity** (see p. 416): With a normal basal TSH, there is no need for additional tests (withhold scintigraphy, especially in younger patients). Iodine prophylaxis or iodine administration may be appropriate in some cases.

- *Nodular goiter:*
    - *Normal basal TSH:* hormone replacement therapy
    - *Suppressed basal TSH:* hyperthyroid workup and scintigraphy (see p. 180; also Fig. 240, p. 180)
    - *Elevated basal TSH:* hypothyroid workup (false-positive value; faulty test? recurrent nodular goiter after strumectomy?)
  - *Hypoechoic nodules* (solitary or multiple separate nodules):
    - *Nodules > 10 mm:* scintigraphy
    - *Nodules > 10 mm with an incomplete peripheral rim and internal vascularity:* FNAB (see p. 53)
    - *Normal TSH but suspicion of autonomy:* suppression scintigraphy
    - *Nodule hypoechoic by ultrasound and cold by scintigraphy:* Always investigate by FNAB or surgery; also do a calcitonin assay, when a medullary C-cell carcinoma is supposed
  - *Hypoechoic thyroid gland:*
    - *Normal basal TSH:* further tests to evaluate for thyroiditis or immunogenic goiter
    - *Suppressed basal TSH:* Hyperthyroidism in Graves disease? Chronic autoimmune thyroiditis with transient hyperthyroidism? Postpartum hyperthyroidism? De Quervain thyroiditis?
    - *Elevated basal TSH:* Hashimoto thyroiditis
- ▣ **Note:** In patients with an abnormal basal TSH, ultrasound and scintigraphy effectively supplement one other in the investigation of hyperthyroidism.

## 19 Major Salivary Glands

### 19.1 Examination

#### Scan Planes

- ▶ Longitudinal and transverse planes

#### Sonographic Anatomy and Normal Findings

- ▶ **Sonographic anatomy** (Fig. 634): The largest of the major salivary glands, the parotid gland is located anteroinferior to the ear and posterolateral to the ramus of the mandible. Its excretory duct leaves the gland anterosuperior to the buccal mucosa. Generally the duct cannot be defined with ultrasound unless it is enlarged as a result of obstruction.

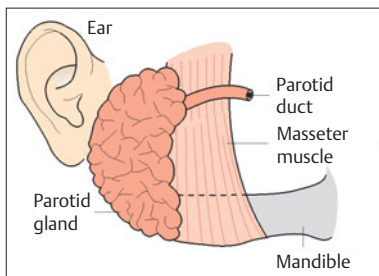


Fig. 634 Topographic anatomy of the parotid gland

- ▶ **Normal findings** (Fig. 635): All of the major salivary glands have smooth, sharp borders and a uniformly hyperechoic texture (similar to the thyroid gland).

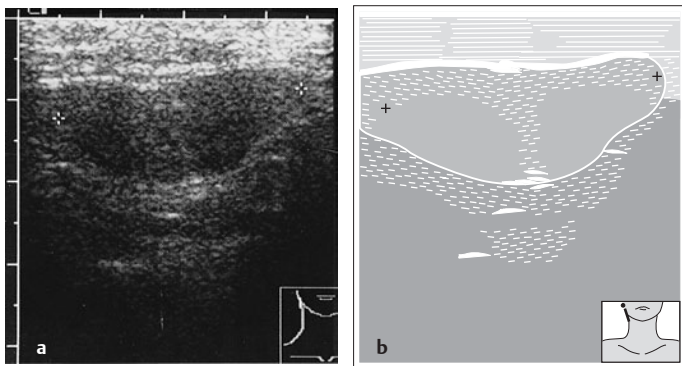


Fig. 635a, b Oblique scan through the right parotid gland

## Scanning Protocol

- ▶ **Transducer:** 7.5 MHz
- ▶ The patient is positioned supine, and a wedge may be placed beneath the shoulder. The neck is hyperextended and turned to the side.
- ▶ **Parotid gland:** surveyed in longitudinal and transverse scans (except for the retro-mandibular part of the gland)
- ▶ **Submandibular gland:** The transducer is positioned lateral to the oral floor on each side.
- ▶ **Sublingual gland:** The transducer is positioned lateral to the oral floor on each side.

## Overview and Classification of Findings

- ▶ **Indication for sonography:** As a rule, ultrasound is used specifically to distinguish between swelling and a tumor (see Peripheral Lymph Nodes, p. 110).
- ▶ **Pathology:**
  - **Sialoliths:** 80% of salivary stones occur in the submandibular gland and 20% in the parotid gland. The gland may undergo secondary enlargement with a change of internal echo pattern.
  - **Sialadenitis:** bacterial or viral (mumps)
  - Sialadenosis
  - Ductectasia. Stricture?
  - **Tumors:** 78% are benign, 13% malignant, 5% metastatic
    - **Adenomas:** pleomorphic adenoma (parotid mixed tumor, 85%), oncocytoma, Whartin tumor
    - Nonepithelial tumors
    - Secondary tumors (metastases, 5%)
- ▶ **Classification and overview:** See Table 77.

**Table 77 · Abnormal findings in the salivary glands**

Anechoic	Isoechoic or enlarged	Hypoechoic	Hyperechoic
Cysts (p. 427)	Viral sialadenitis (p. 427)	Acute bacterial sialadenitis (p. 428)	Sialadenosis (p. 430)
Abscess (p. 427)	Chronic sialadenitis (p. 428)	Parotid mixed tumor (p. 428)	Lipoma, hemangioma, lymphangioma (p. 430)
	Sialadenosis (p. 428)	Pleomorphic adenoma (p. 429)	Sialolithiasis (p. 430)
	Immunogenic sialadenitis (p. 428)	Cystadenolymphoma (p. 429)	
	Sarcoidosis (p. 428)	Oncocytoma (p. 429)	
		Mucoepidermoid carcinoma (p. 429)	
		Adenoid cystic carcinoma (p. 429)	
		Metastases, malignant lymphoma (p. 429)	

## 19.2 Abnormal Findings

### Anechoic Changes

#### ► Cysts:

- *Clinical features:* salivary duct cysts, dysontogenetic duct anomalies, secondary cysts
- *Causes:* inflammation, trauma, sialectasia
- *Sonographic features:*
  - Cystic lesion with smooth or irregular margins
  - Cysts always develop at the anterior border of the sternocleidomastoid muscle

#### ► Abscess:

- Ill-defined margins
- Internal echo pattern ranges from anechoic to complex
- Local tenderness

### Isoechoic Changes and Enlargement

#### ► Viral sialadenitis (Figs. 636 and 637): e.g., mumps

- Enlargement of the parotid gland
- Normal internal echo pattern

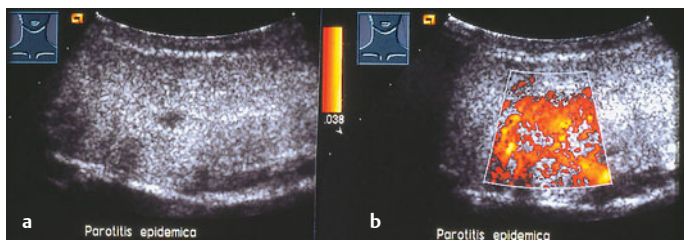


Fig. 636a, b Epidemic parotitis. **a** B-mode image: enlargement of the gland. **b** CDS: inflammatory hypervascularity

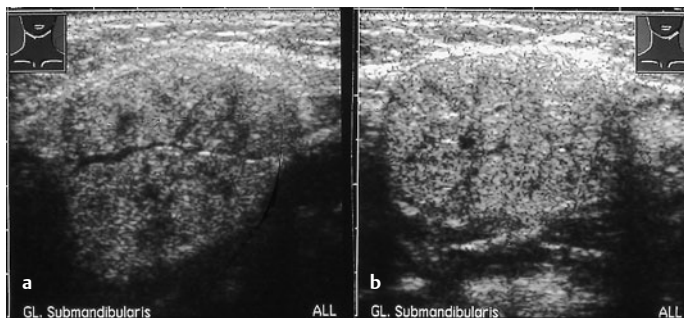


Fig. 637a, b Inflammation of the submandibular gland: hypoechoic swelling with anechoic streaks (edema)

- ▶ **Chronic sialadenitis:**
  - Recurrent swelling of the gland
  - Essentially normal echo pattern
- ▶ **Sialadenosis** (Fig. 638): “Hamster cheeks,” nonneoplastic. Common in alcoholics, seen occasionally in diabetics (neurogenic?)
  - Painless enlargement of the parotid gland
  - Nonspecific internal echo pattern
  - May be slightly hyperechoic. Fine cysts may be seen
- ▶ **Immunogen sialadenitis:**
  - Slight enlargement; nonspecific structure
  - Facultative slight hyperechoic; fine cysts
- ▶ **Sarcoidosis:** nonspecific echo pattern, may show decreased echogenicity

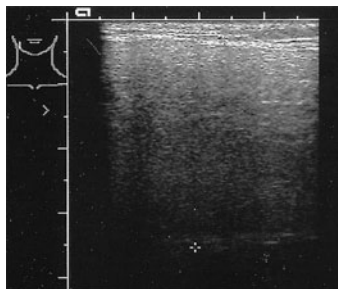


Fig. 638 Sialadenosis. Longitudinal scan shows significant thickening of the parotid gland (cursors)

### Hypoechoic Changes

- ▶ **Acute (or chronic recurrent) bacterial sialadenitis** (Fig. 639): occurs predominantly in elderly patients with a weakened immune system
  - Enlargement
  - Nonhomogeneous hypoechoic pattern
  - *Possible findings:* liquid foci of abscessation, echogenic structures with acoustic shadows (sialoliths). Possible anechoic ductal dilatation

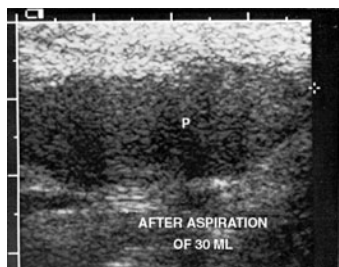


Fig. 639 Acute bacterial parotitis associated with an infected neck cyst. Oblique scan shows nonhomogeneous hypoechoic swelling of the parotid gland (P)

- ▶ **Parotid mixed tumor** (sialadenoma, Fig. 640a): most common parotid tumor; strong propensity for recurrence, may undergo malignant transformation
  - Round, oval
  - Hypoechoic (when large: heterogeneous, cystic/hyperechoic pattern)
  - Smooth margins

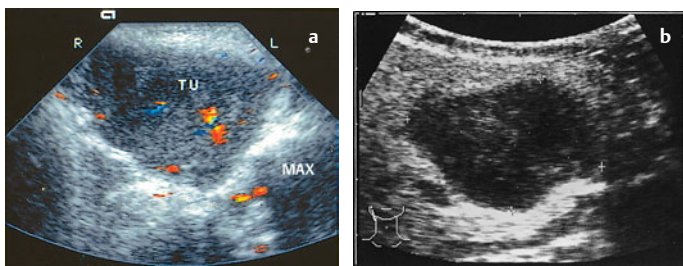
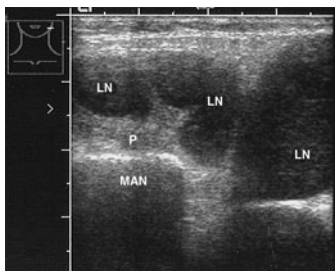


Fig. 640a, b a Parotid mixed tumor (TU). MAX = maxilla b Cystadenolymphoma (Whartin tumor, cursors). Diagnosed by FNAB

- ▶ **Pleomorphic adenoma:** may undergo malignant transformation
  - Smooth margins
  - Homogeneous
- ▶ **Cystadenolymphoma** (Whartin tumor, Fig. 640b): more common entity; like oncocytoma, is classified as a sialoma
  - Markedly hypoechoic, nonhomogeneous echo pattern
  - Smooth margins
  - Small cysts, may contain fine septations
- ▶ **Oncocytoma:** rare
  - Uniformly hypoechoic
  - Smooth margins
- ▶ **Mucoepidermoid carcinoma:** low-grade malignancy, the most common malignant tumor in adults (approximately 50% of malignant salivary gland tumors)
  - Very hypoechoic
  - Smooth margins
  - May contain cystic areas
- ▶ **Adenoid cystic carcinoma** (older term: cylindroma): high-grade malignancy marked by early infiltration of the facial nerve
  - Usually hypoechoic. Some lesions are heterogeneous or anechoic
  - Ill-defined margins
- ▶ **Metastases, malignant lymphoma** (Fig. 641):
  - Hypoechoic round or scalloped mass

Fig. 641 Lymph node metastases (LN) from bronchial carcinoma: very hypoechoic mass in the parotid gland (P). MAN = mandibular echo with acoustic shadow



## Hyperechoic Changes

### ▶ Sialadenosis:

- Frequently hyperechoic (due to diffuse fatty infiltration)
- Bilateral symmetry
- Painless enlargement

### ▶ Lipoma, hemangioma, lymphangioma:

- Hyperechoic
- Lipoma with a feathery pattern; lymphangioma may have a cystic appearance

### ▶ Sialolithiasis (salivary stone, Fig. 642): presents clinically with swelling and acute pain

- Round or oval hyperechoic mass with an acoustic shadow, projected over the duct
- Duct obstruction; anechoic duct structure at least 1 mm wide
- Rarely intraglandular, usually extraglandular with anteromedial extension into the buccal mucosa

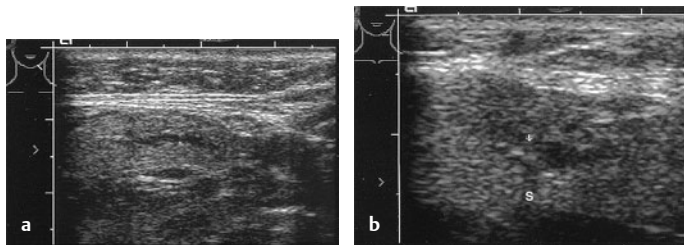


Fig. 642a, b Sialolithiasis. **a** Abnormal anechoic duct structure. **b** Magnified view with the scan plane positioned for greatest clarity: microliths (arrow) with a distal acoustic shadow (S)

## Evaluation and Further Testing

### ▶ Sonography: Diffuse and circumscribed salivary gland lesions can be clearly visualized with a high-resolution transducer. Most lesions (benign tumors) occur in the parotid gland.

- *Isoechoic diffuse swelling*: usually viral parotitis
- *Hypoechoic swelling*: usually bacterial sialadenitis
- *Circumscribed hypoechoic tumors*: Ultrasound is of limited value for benign-malignant differentiation

### ▶ Further testing:

- *Circumscribed hypoechoic masses*: fine-needle aspiration cytology and histology
- *Adenoid cystic carcinoma and carcinomas in adenomas*: These malignancies often present clinically with rapid growth and facial nerve palsy
  - *Critical*: FNAB, surgical diagnosis
  - Infiltrative growth is clearly demonstrated by CT.
  - MRI cannot differentiate between benign and malignant lesions (but is useful in the diagnosis of pleomorphic adenoma).

## 20 Postoperative Ultrasound

### 20.1 Normal Postoperative Changes

- ▶ The prior history (*anamnesis*) and follow-up history (*catamnesis*) can account for almost all postoperative findings.
- ▶ Therefore, always ask about previous operations, especially involving the abdomen (it is easy to overlook scars in the darkened ultrasound room).
- ▶ The absence of organs should be noted and documented (e.g., previous cholecystectomy, Figs. 643 and 644). It is also easy to miss an aortic prosthesis and other implant materials (Fig. 645).

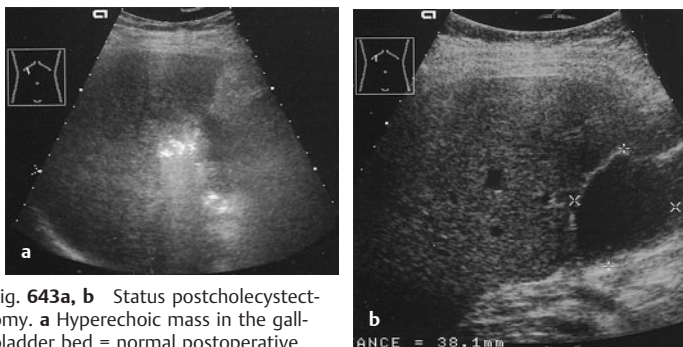


Fig. 643a, b Status postcholecystectomy. **a** Hyperechoic mass in the gallbladder bed = normal postoperative finding. **b** Anechoic mass (cursors) = postoperative seroma

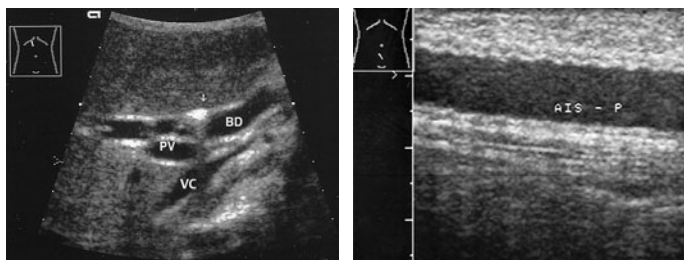


Fig. 644 Metal clip following a cholecystectomy: high-amplitude echo (arrow) with reverberations. Posterior to the clip is the bile duct (BD). PV = portal vein, VC = vena cava

Fig. 645 Prosthesis in the iliac artery (AIS-P)

### Examples of Postoperative Anatomical Changes

- ▶ **Scars and scar-tissue bands** (Fig. 646): Surgical procedures on the liver, kidney, and other organs leave scars. Scar tissue following ablative tumor surgery is particularly easy to recognize in a large parenchymatous organ like the liver. A scar-tissue band that is present for years or decades may cause significant local ana-

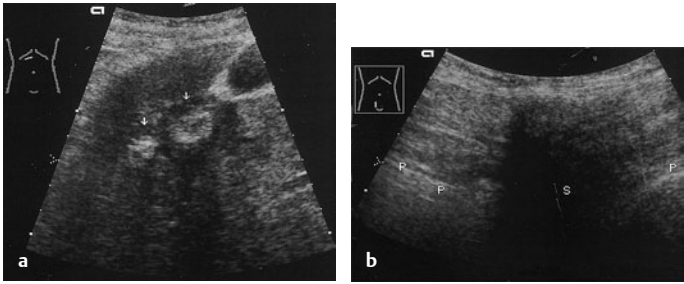


Fig. 646a, b Postoperative scars. **a** Scars following laser-induced tumor ablation (LIT) of the liver: echogenic mass (arrows) with a hypoechoic halo and acoustic shadow. **b** Scar-tissue band with an acoustic shadow (S) following a herniotomy. P = peritoneal echo

tomic changes. An example is the displacement of the upper abdominal visceral “packet” toward the left side that typically occurs after a partial gastrectomy or other extensive upper abdominal surgery (nonvisualization of the displaced gallbladder or of the pancreas because of adhesions with overlying bowel).

- ▶ **Thoracic surgical procedures:** Thoracic operations may also produce changes in upper abdominal anatomy. Examples are upward displacement of the liver due to right-sided phrenic nerve palsy and the impairment of respiratory organ mobility (e.g., by basal pleural adhesions). Generally in these cases the liver and pancreas cannot be visualized by ultrasound.
  - ▶ **Scanning tips:**
    - Define the liver and gallbladder in a high intercostal scan on the right side.
    - Define the pancreas after filling the stomach with fluid.
  - ▶ **Organ transplants:** typical pelvic location of the renal allograft with a denervated and ectatic pyelocalyceal system (Fig. 647.).
- 🚫 **Caution:** Do not misinterpret as urinary obstruction.

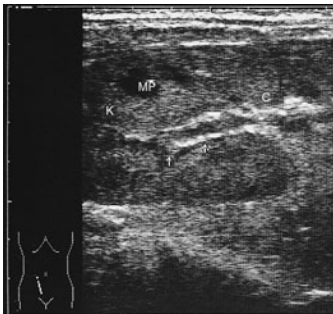


Fig. 647 Renal allograft (K) in the right lower abdomen. Arrows: ectatic fluid-filled pyelocalyceal system. C = renal columns, MP = hypoechoic medullary pyramids

- ▶ **Pneumobilia** (Fig. 648): Air in the bile ducts is consistently present after the surgical creation of a biliary–enteric anastomosis and is frequently present after endoscopic papillotomy (complete sphincterotomy). It is considered a normal finding in these settings.

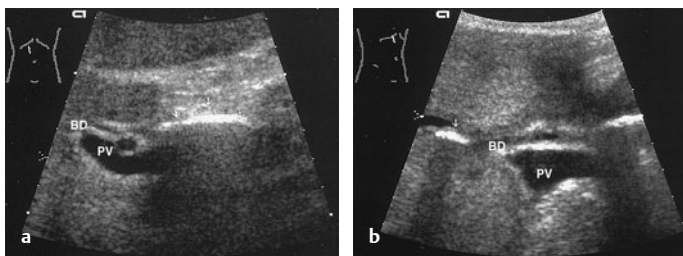


Fig. 648a, b Pneumobilia. **a** Supine position: A hyperechoic air echo (arrows) is visible in the most anterior portion of the bile duct (BD). **b** When the patient is moved to left lateral decubitus, the air echo moves into the liver (arrow). PV = portal vein

- ▶ **Cholangiectasis** (asymptomatic dilatation confined to the extrahepatic bile ducts, Fig. 649): May result from cholecystectomy but is more commonly an age-related finding.

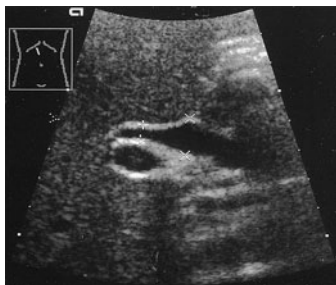

Fig. 649 Cholangiectasis: local variations in the caliber of the bile duct (cursors, 12.2 and 4.8 mm), common after cholecystectomy or with aging. This pattern is not consistent with an obstructive dilatation

- ▶ **Intestinal anastomoses and resections** (Fig. 650): Accessible to ultrasound evaluation only in selected cases, e.g., the restenosis of ileocolic anastomoses in Crohn disease, hepato(choledocho)jejunostomy for carcinoma

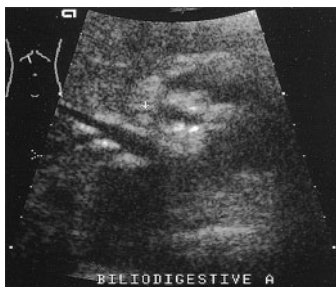

Fig. 650 Hepaticojejunostomy. Notable postoperative findings: cutoff of the anechoic hepatic duct (arrow) at the site of the biliary-enteric anastomosis. Chyme and bowel gas in the jejunal loop produce a complex echo pattern

## 20.2 Postoperative Complications

### Abnormal Accumulations of Fluid (Fig. 651)

- ▶ The most effective role of ultrasound in the follow-up of abdominal operations is for the detection or exclusion of abnormal accumulations of fluid.
- ▶ Peripheral accumulations of fluid around parenchymatous organs, mesenteric collections, and fluid in the cul-de-sac are considered normal findings. Larger accumulations associated with clinical manifestations arouse suspicions of ascites, intraperitoneal hemorrhage, pus, or leaks (bile, gastrointestinal, pancreas).
- ⚠ **Caution:** Avoid mistaking a harmless hematoma or seroma for an abscess.

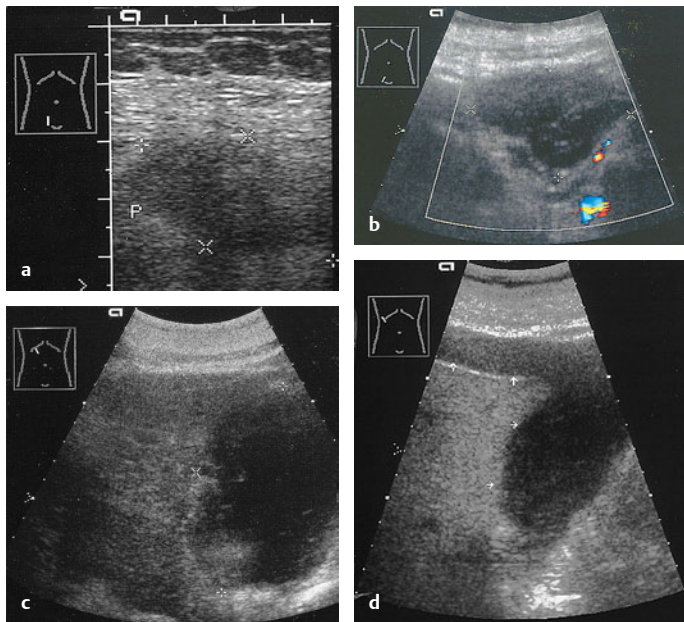


Fig. 651a–c Postoperative hematoma and hemorrhage. **a, b** Extraperitoneal and intraperitoneal hematomas (cursors). The boundary line of the peritoneum (P) aids in assessing their location. **c, d** Hematoma/hemorrhage following cholecystectomy: mass with low-level peripheral echoes (cursors) and a peripancreatic mass (arrows)

### Obstructed Tubular Systems

- ▶ The sonographic features of postoperative obstructions are the same as those of other types. When a detailed history is taken (and with meticulous scanning technique), the cause of the obstruction can usually be identified. Some cases may require investigation by ultrasound-guided percutaneous biopsy.

- ▶ **Biliary tract obstruction:** presenting clinically with jaundice. Despite unfavorable postoperative conditions, the course of the obstructed bile duct can usually be traced with ultrasound. Scanning tip: intercostal scans are helpful.
  - *Possible causes:*
    - Postoperative pancreatitis
    - Iatrogenic bile duct ligation
    - Residual duct stone
  - *Differentiation:* can be differentiated from obstructive drug-induced jaundice or toxic-septic jaundice by noting the presence or absence of obstructed intrahepatic bile ducts.
  - *Signs suggestive of postoperative obstructive cholestasis:*
    - Double-walled, anechoic intrahepatic duct systems (bile ducts, portal venous branches)
    - Extrahepatic bile duct dilated to  $> 7$  mm
    - Detection of the obstructing lesion
- ▶ **Ureteral obstruction** (Fig. 652): most commonly results from urinary stasis (often unilateral). May occur after tumor operations in the lower abdomen, or may be secondary to retroperitoneal lymphadenopathy. In most cases the cause cannot be established by ultrasound and the patient should be referred for CT scans. Therapeutic options include stenting and drainage.

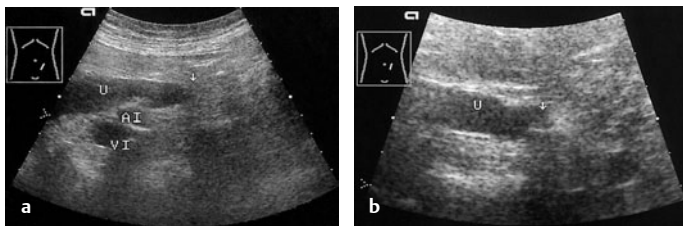


Fig. 652a, b Postoperative ureteral stricture (U, arrow). **a** Loss of ureteral delineation in an area of echogenic scar tissue. AI = iliac artery, VI = iliac vein. **b** Ureteral occlusion by an echogenic band (clip and suture material from previous intestinal tumor surgery)

- ▶ **Bowel obstruction (partial or complete):** Ultrasound is the simplest and best modality for the early postoperative diagnosis of bowel obstruction. Generally the cause is determined intraoperatively.

### Abscess Formation (Circumscribed, Diffuse, Loculated, Fig. 653)

- ▶ The most common problem in postoperative patients is to determine the presence or absence of a postoperative abscess. It is easy to make a sonographic diagnosis in cases that present with local swelling, redness, pain, and a circumscribed liquid mass. A more difficult problem is to detect or exclude an intra-abdominal abscess.
- ▶ A diffuse or uncircumscribed abscess is difficult to distinguish from ascites or leakage. Many of these cases can be evaluated by ultrasound-guided needle aspiration or drainage (see Fig. 73, p. 54).

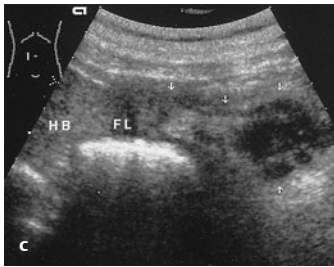
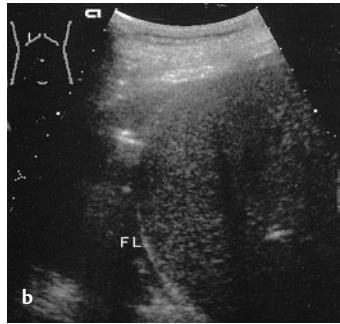
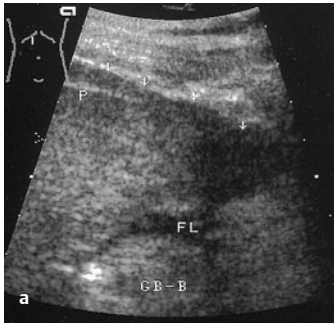


Fig. 653a–c Postoperative suppuration and abscess formation. **a** After cholecystectomy: echogenic mass in the gallbladder bed (GB-B) and hypoechoic purulent fluid tracking around the pancreas (FL, arrows). P = visceral peritoneum. **b** Concomitant seepage pleuropneumonia (same patient as in **a**). **c** After appendectomy: complex mass (arrows, FL). HB = hepatic border

### Arterial and Venous Perfusion Disorders

- ▶ These conditions are difficult to assess with ultrasound, but CDS is rewarding in some cases. The best modality is conventional angiography.

### Foreign Bodies (Figs. 654 and 655)

- ▶ These include “forgotten” foreign objects, devices that have been implanted for functional maintenance (e.g., drains), and endogenous bodies that are lost during an operation and have to be located with ultrasound.

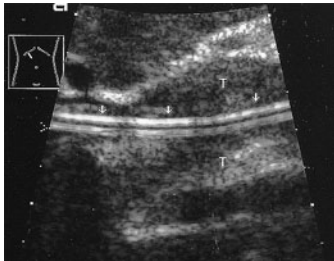


Fig. 654 Obstruction of the bile duct by a tumor (T). Biliary drain (arrows): typical pattern of echogenic double walls with an anechoic lumen

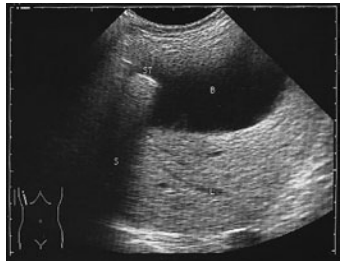


Fig. 655 Gallstone lost at operation (cholesterol stone, ST) and located by ultrasound (lodged between the liver and diaphragm). Treatment: endoscopic cholecystectomy. B = bilioma, L = liver, S = shadow

## 21 Search for Occult Tumors

### 21.1 Principal Signs and Symptoms

#### Overview (Table 78):

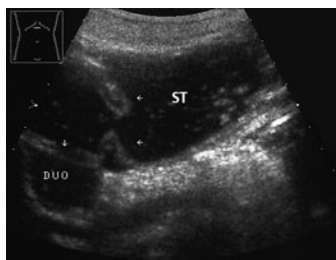
**Table 78 · Clinical manifestations of tumors**

Weight loss
Pain
Fever, night sweats
Acute abdomen, bowel obstruction
Ascites, pleural effusion
Diarrhea, constipation
Thrombosis
Abnormal laboratory values (anemia, lymphocytosis, thrombocytosis, hemoblastosis, hypercalcemia, elevated ESR)

#### Weight Loss

- ▶ **Definition:** unexplained loss of 10% of the body weight in 6 months, often caused by complex processes associated with a previously unknown neoplasm (metabolism, mass effects, obstructive stenosis, malnutrition, tumor metabolic products)
- ▶ **Occurrence:**
  - *Esophageal, gastric and duodenal tumors:* weight loss due to eating difficulties or impaired alimentary transit (Fig. 656; see also Fig. 537, p. 365)

Fig. 656 Massive prestenotic dilatation of the duodenal bulb and stomach. Malignancy is evidenced by lymph node metastases and small bowel wall thickening (see Fig. 538b, p. 366). The patient presented clinically with vomiting and weight loss. Horizontal arrows: peristaltic wave, vertical arrow: pylorus



- *Bowel tumors:* weight loss usually due to advanced (hepatic) metastases
- *Gallbladder tumors:* locally advanced tumor growth
- *Pancreatic carcinoma* (Fig. 657): due to displacement, compression, or other mass effects in the upper abdomen and maldigestion (ductal carcinoma with duct obstruction in > 90% of cases; see Fig. 443, p. 305)
- *High-grade non-Hodgkin lymphoma:* disseminated disease (Fig. 658)

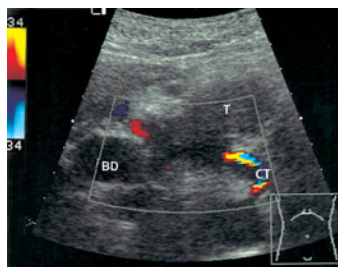


Fig. 657 Malignant tumor (carcinoma, T) of the pancreas infiltrating the hepatic artery. CT = celiac trunk, BD = obstructed common bile duct

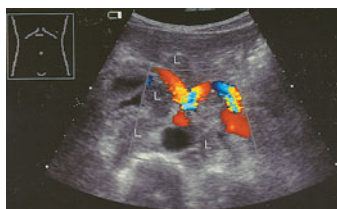

Fig. 658 High-grade non-Hodgkin lymphoma. Lymph node metastases (L) are scattered throughout the upper abdomen, compressing (but not infiltrating) the celiac vessels. The patient presented clinically with severe weight loss, cachexia

- *Hodgkin lymphoma, sarcoma*: advanced tumor stage (Ann Arbor stage IIIB [subphrenic involvement or Stage IVB [disseminated disease]])
- *Neuroendocrine tumors*: advanced tumor stage
- Metastatizing urologic or gynecologic tumors

## Pain

- ▶ **Definition:** Tumors are most likely to cause visceral pain, which is dull, poorly localized, and associated with autonomic effects (vasospasms, stretching of the organ capsule, displacement and pressure via a viscerocutaneous or viscerovisceral reflex arc).
- ▶ **Occurrence:**
  - Pancreatic carcinoma (Fig. 658)
  - Hepatic metastases
  - High-grade lymphoma (stage IE or IVB)
  - Retroperitoneal tumor (sarcoma)

## Fever and Night Sweats

- ▶ **Definition:** Fever is a rise in body temperature above the normal range ( $> 37.5^{\circ}\text{C}$ , or rectal temperature  $> 38.3^{\circ}\text{C}$  in children) lasting at least 3 weeks. Tumors are associated with an undulating febrile pattern (see Unexplained Fever, p. 92).
- ▶ **Occurrence:**
  - Abdominal or retroperitoneal tumors
  - Metastases
  - Malignant lymphoma, Hodgkin disease (see Fig. 658, p. 438; Fig. 132, p. 101)

## Acute Abdomen, Bowel Obstruction

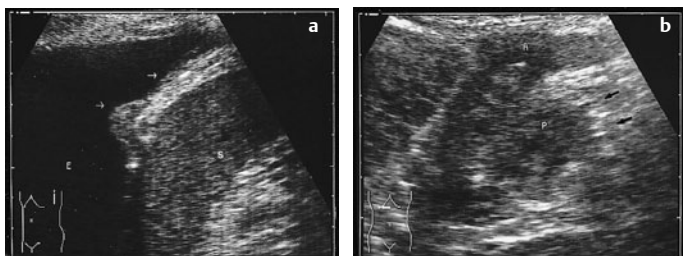
- ▶ **Definition:** Symptom complex that includes abdominal pain, muscular guarding, and altered intestinal peristalsis
- ▶ **Occurrence:**
  - Obstruction of the small or large intestine
  - Tumor hemorrhage
  - Peritoneal carcinomatosis
  - Acute portal vein thrombosis (neoplastic or paraneoplastic, see Fig. 116, p. 85)

## Ascites, Pleural Effusion

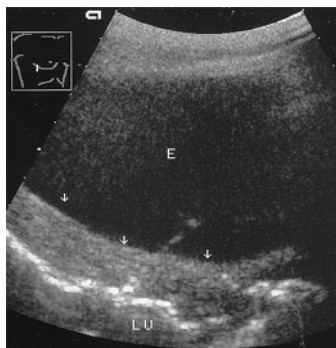
- ▶ **Definition:** collection of serous fluid in the capillary space between the visceral and parietal layers of the peritoneum or in the pleural space (exudate or transudate). For the differentiation of benign and malignant ascites, see p. 155.
- ▶ **Occurrence:**
  - *Peritoneal carcinomatosis*: see Table 79.
  - Pleural metastases, pleural carcinomatosis (Figs. 659 and 660)
  - *Mesothelioma* (Fig. 661): benign or malignant pleural or peritoneal tumor

**Table 79 · Signs of peritoneal carcinomatosis (after Rioux)**

Omental thickening (in 97%)
Peritoneal mass (in 19%)
Peritoneal discontinuity (in 16%)
Mesenteric adhesions (in 16%)
Hepatic metastases (in 38%)
Lymph node metastases (in 24%)
Ascites (in 49%)



**Fig. 659a, b** Pleural effusion. **a** Neoplastic pleural thickening (arrows) as a direct cause of effusion (E). S = spleen. **b** Result of ultrasound search for a primary tumor: malignant pancreatic tumor (P) infiltrating the antrum (A) and duodenum. Arrows: tumor extensions (same patient as in a)



**Fig. 660** Malignant pleural effusion (E) in peritoneal carcinomatosis: thickening of the parietal pleura (arrows). The echogenic line behind the parietal pleura is an entry echo from the aerated lung (LU)

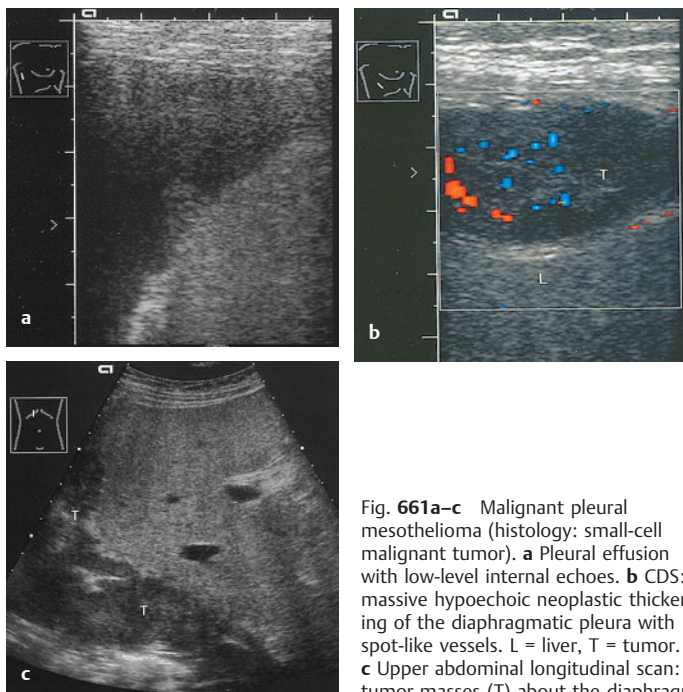


Fig. 661a–c Malignant pleural mesothelioma (histology: small-cell malignant tumor). **a** Pleural effusion with low-level internal echoes. **b** CDS: massive hypoechoic neoplastic thickening of the diaphragmatic pleura with spot-like vessels. L = liver, T = tumor. **c** Upper abdominal longitudinal scan: tumor masses (T) about the diaphragm

- *Meigs tumor* (see Fig. 210, p. 162): benign ovarian tumor with ascites or unilateral pleural effusion

### Diarrhea, Constipation

#### ► Occurrence:

- *Hormone-producing gastrointestinal tumors:*
  - *Carcinoid* (Fig. 662): diarrhea in 70–90%

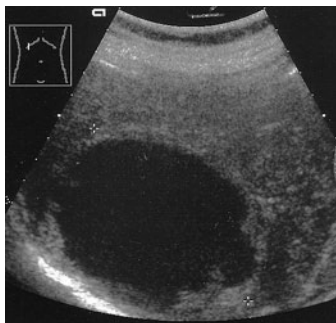


Fig. 662 Metastatic carcinoid in the liver (cursors): almost completely anechoic mass with a small, echogenic tumor margin—typical appearance of metastatic carcinoid

- *Gastrinoma* (pancreatic tumor with Zollinger–Ellison syndrome)
- *Vipoma* (pancreatic tumor with Verner–Morrison syndrome, very rare): “pancreatic cholera.”
- ▶ *Rectal carcinoma*: episodes of diarrhea (with bright red blood), constipation
- ▶ *Colon carcinoma* (see Fig. 663b, p. 441): constipation or bowel obstruction

## Thrombosis

- ▶ **Definition:** intravital and intravascular coagulation with thrombus formation (Fig. 663) or a tumor thrombus (Fig. 664) in the setting of a paraneoplastic syndrome (caused by ectopically produced hormones or hormonally active peptides and polypeptides, also tumor markers).
- ▶ **Occurrence:**
  - Superficial and deep (lower-extremity) venous thrombosis (Figs. 663 and 664)
  - Portal vein thrombosis (see Fig. 370, p. 261)
  - Vena cava or renal vein thrombosis (see Fig. 101, p. 74)

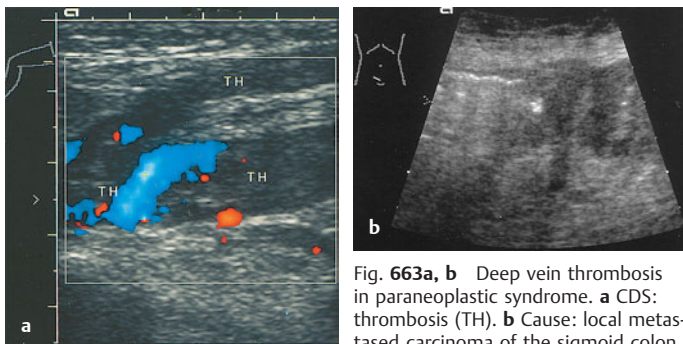
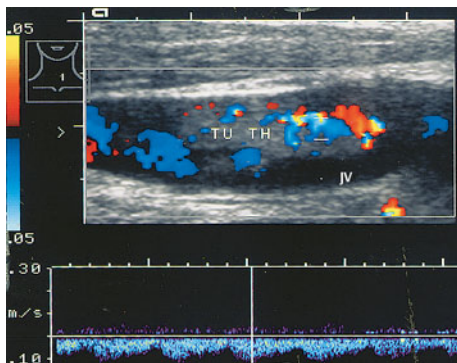


Fig. 663a, b Deep vein thrombosis in paraneoplastic syndrome. **a** CDS: thrombosis (TH). **b** Cause: local metastasized carcinoma of the sigmoid colon.

The patient had a 3-week history of recurrent pneumonia and fever, initially diagnosed as postinfarction pneumonia. The tumor was not diagnosed until deep venous thrombosis developed, prompting an ultrasound tumor search

Fig. 664 Tumor thrombosis of the internal jugular vein (JV): high-level intraluminal echoes (TU, TH) with internal vascularity. CDS with spectral analysis shows aberrant arterial vessels that confirm a malignant tumor thrombus. Primary tumor: renal cell carcinoma that metastasized to the thyroid gland



## Abnormal Laboratory Values

- ▶ Look for anemia, lymphocytosis, thrombocytosis, hemoblastosis, hypercalcemia, elevated ESR, etc.
- ▶ Occurrence in:
  - Acute leukemia, chronic lymphatic leukemia
  - Plasmacytoma
  - Gastrointestinal tumors
  - Metastasizing tumor

## 21.2 Sonographic Criteria for Malignancy

### Basic Principles

- ▶ **Sonographic definition of tumors:** Primary organ tumors and metastases appear as circumscribed lesions whose shape and echo pattern are characteristic of tumors. The normal architecture and echo pattern of the affected organ is altered or destroyed.
- ▶ **Sonographic appearance of tumors:**
  - Benign and malignant tumors may have different malignancy criteria in different organs (e.g., an echopenic halo suggests metastasis in the liver but suggests a benign nodule in the thyroid gland).
  - Calcification and liquefaction may occur in both malignant and benign tumors.
  - Many types of tumor lack reliable criteria for malignancy.
- ▶ **Sonographically detectable organ changes:** Some tumors are difficult to define directly with ultrasound but may still be detected indirectly by their effects on the host organ. The changes in the host organ relate mainly to organ contours and echo patterns but may also involve blood vessels and tubular structures.
- ▶ **Associated findings:** Tumors occasionally assume importance not by their primary site of occurrence or their host-organ effects but by their relationship to and effects on surrounding structures. They may produce clinical manifestations by the alteration of dynamic processes (e.g., intestinal peristalsis), the formation of abnormal fluids, the obstruction of blood flow or canalicular pathways, or by infiltrating adjacent organs.
- ▶ **Overview:** See Table 80.

**Table 80** · Sonographic criteria for malignancy

<i>Tumor appearance</i>	Shape Internal echo pattern Arrangement Regressive changes
<i>Vascularization pattern</i> (p. 445)	Spot-like pattern Wheel or basket pattern Branching pattern
<i>Organ changes</i> (p. 447)	Contours Echo pattern
<i>Associated findings</i> (p. 447)	Functional disorders Abnormal fluid collections Displacement, fixation, infiltration

## Appearance of Tumors

### ► Shape:

- Scalloped (pancreatic carcinoma; see Fig. 442, p. 304)
- Round (HCC; see Fig. 351, p. 249)
- Patchy (CCC; see Fig. 352, p. 250)
- Polygonal, band-shaped, or target-shaped (colorectal carcinoma; see Fig. 663b, p. 441)

### ► Echogenicity, arrangement:

- Metastases are generally round and hypoechoic, but multiple metastases have a tendency to coalesce (e.g., hepatic metastases; see Fig. 665).
- Colorectal metastases are usually hyperechoic, often have a hypoechoic halo, and are more likely to be multiple than solitary (Fig. 665a).
- Hemangiomas often have an identical appearance to metastases. A feeding vessel or intratumoral vessel can often be detected (but not in metastases; Fig. 665b).

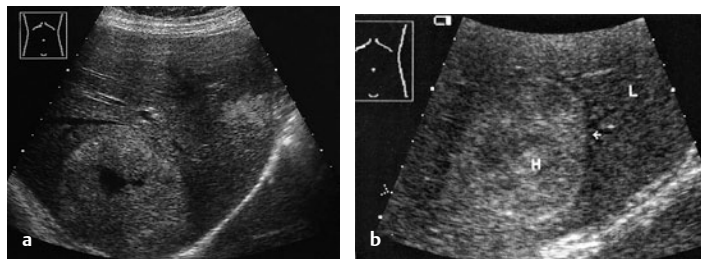


Fig. 665a, b Metastases. **a** Hyperechoic hepatic metastases from colon carcinoma, one with central liquefaction (anechoic regressive cystic transformation, incipient bull's-eye sign), no halo. **b** Hemangioma (H): cloudy hyperechoic pattern, peripheral halo (arrow). L = liver

### ► Regressive changes:

- *Liquefaction*: Foci of liquefaction may occur in benign and malignant tumors such as colorectal metastases (see Fig. 665a), atypical hemangiomas, and metastases from breast carcinoma. Carcinoid metastases can even be identified by their extensive central anechoic zones and hyperechoic rim (see Fig. 662, p. 440).
- *Calcifications*:
  - *Microcalcifications*: may form in older hepatic metastases (Fig. 666; see also Fig. 665a) and in testicular and prostatic carcinomas (see Fig. 581, p. 391, and Fig. 585, p. 393).
  - *Macrocalcification*: may form in colorectal metastases, renal carcinoma, primary hepatocellular carcinoma (Fig. 667), and hemangiomas.
  - *Regressive changes*: may produce a “target sign” (hypoechoic–hyperechoic–hypoechoic, Fig. 668), whereas *central liquefaction* produces a “bull’s eye sign” (Fig. 665a, p. 443); may also occur in large hemangiomas, hepatic adenomas, and renal carcinomas.

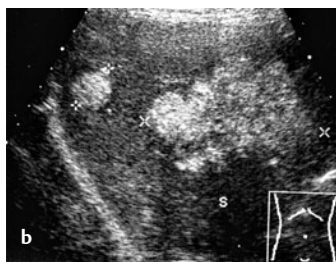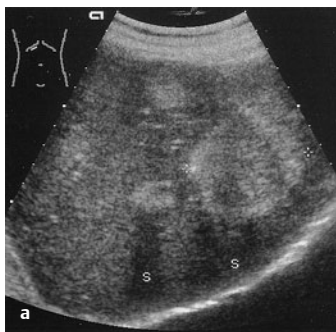


Fig. 666a, b Microcalcifications.  
**a** Hyperechoic hepatic metastases from rectal carcinoma. Microcalcifications are identified by their acoustic shadows (S). **b** Hemangioma (cursors): microcalcification casting a faint acoustic shadow

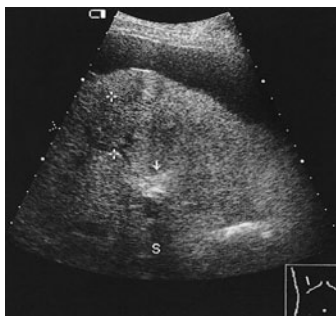

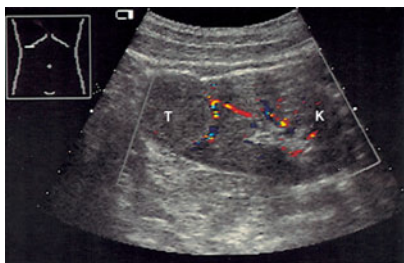
Fig. 667 Microcalcification (arrow) with an acoustic shadow (S) in a primary hepatocellular carcinoma plus another tumor (cursors)

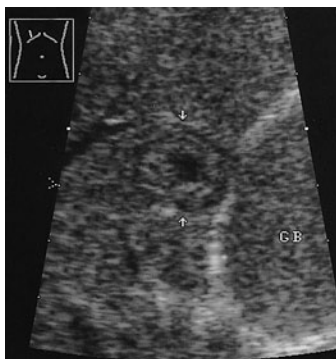

Fig. 668 Hepatic metastasis from a carcinoma of the small intestine (arrows): target sign. Associated finding: echogenic gallbladder (GB)

- **Differential diagnosis:**
  - Echogenic gas bubbles with acoustic shadows or reverberations (can mimic calcifications)
  - Echogenic abscess calcification with distal acoustic shadowing
- ▶ **Benign tumors with a halo** (see Figs. 348 and 349, p. 248, 249):
  - *Hepatic adenoma, focal nodular hyperplasia, hemangioma*: a pseudocapsule may be formed by tissue and vascular displacement; rare but possible
  - *Abscess*: hyperechoic pyogenic membrane. Rarely, abscesses may have a hypoechoic halo.
- ▶ **Malignant tumors with a halo:**
  - *Primary organ carcinoma*:
    - *Hepatocellular carcinoma*: A hypoechoic halo is somewhat unusual.
    - *Renal cell carcinoma* (Fig. 669): peripheral vascular rim, also internal vessels

Fig. 669 Renal cell carcinoma (T): delineated from the rest of the renal parenchyma (K) by a peripheral vascular rim. The combination of peripheral and internal vessels is suggestive of malignancy

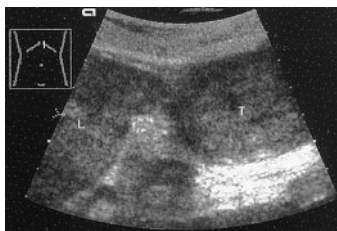


- **Metastasis:** A hypoechoic halo is consistently present (“halo sign”), representing a zone of intense tumor-cell proliferation (see Fig. 332, p. 240). Colorectal metastases may occasionally show a changeable halo sign; this is not useful for differentiating colorectal metastasis from hemangioma (see Fig. 665, p. 443).

### Vascularity

- ▶ There are still no definitive sonographic criteria for the reliable benign–malignant differentiation of tumors. This probably relates to varying patterns of tumor angiogenesis and changes in the original organ vascularity. Attempts have been made to define typical malignancy criteria for specific organ tumors. To date, it has been possible to establish definite malignancy criteria for only a few tumor types. Examples are renal tumors and lymph nodes (see below).
- ▶ **Vascularization patterns in benign tumors:**
  - **Hepatic adenoma:** hypervascular (see Fig. 349, p. 248)
  - **Focal nodular hyperplasia:** hypervascular with a typical spoked-wheel pattern (see Fig. 348, p. 248)
  - **Leiomyomas, GIST tumors:** no detectable intratumoral vessels (Fig. 670)

Fig. 670 Tumor of the gastric wall (T): benign? malignant? CDS shows no peripheral or intratumoral vessels. FNAB and histology: leiomyoma. L = liver



- ▶ **Vascularization patterns in malignant tumors:** depend on the tumor type and affected organ. There are no patterns of vascularity that are specific for a particular tumor (although hepatic tumors may show typical patterns in the various phases of contrast-enhanced sonography: early arterial, arterial, venous, and portal venous). Nevertheless, three vascularization patterns have been identified that are commonly associated with malignant tumors (after Tanaka):
  - **Branching pattern** (Figs. 671 and 672): observed in HCC and other tumors (e.g., lymph nodes, where the wheel pattern is also common)
  - **Basket or wheel pattern** (Fig. 672a): illustrated by hepatocellular carcinoma with peripheral vascularity

- *Spot-like pattern* (Fig. 673; see also Fig. 661b, p. 440): This is the most commonly seen pattern of angiogenesis and is strongly suggestive of a malignant process.
- Only arterial tumor vessels are indicative of malignancy.




Fig. 671a, b Well-differentiated primary hepatocellular carcinoma. **a** B-mode image: elliptical tumor (arrows). Harmonic imaging. **b** CDS: spot-like and branching patterns of increased vascularity. T = tumor

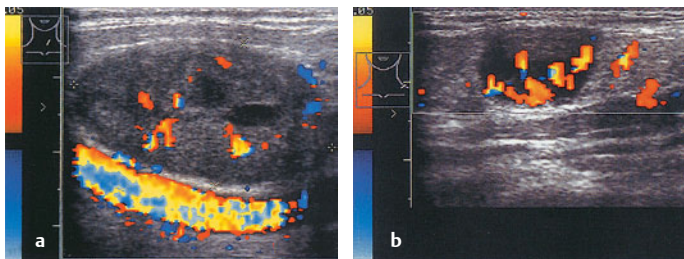


Fig. 672a, b Malignant lymphadenopathies. **a** Malignant cervical lymph node (endometrial carcinoma). CDS: elliptical tumor with multiple intratumoral vessels and avascular foci; subcapsular vessels (wheel pattern). **b** Malignant cervical lymph node (acute lymphatic leukemia). CDS: branching pattern (arterial vessels only)

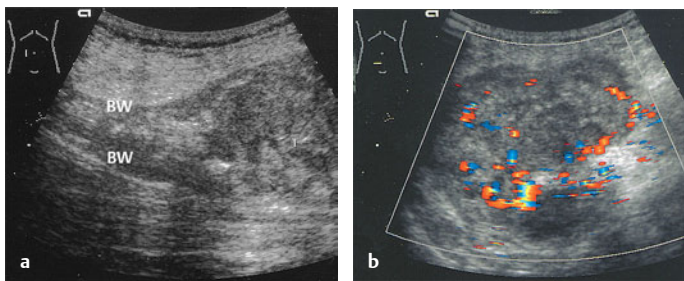


Fig. 673a, b Large bowel obstruction due to a tumor stricture (T). **a** B-mode image: nonhomogeneous mass filling the bowel lumen, with prestenotic dilatation and thickening of the bowel walls (BW). **b** CDS: spot-like pattern of aberrant tumor vessels

## Organ Changes

### ► Contour changes:

- Protuberances
- Irregularities

### ► Alteration of tubular structures:

- Tumor invasion, obstruction, or displacement (e.g., blood vessels, bile ducts)
- Prestenotic dilatation (e.g., bile duct dilatation)

### Deformation or infiltration of vessels (Fig. 674; see also Fig. 371, p. 261):

- Portal vein with portal hypertension
- Hepatic veins in Budd–Chiari syndrome

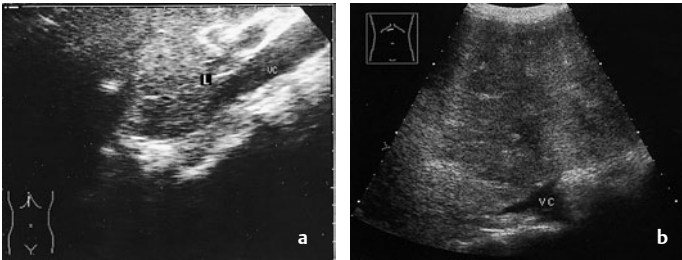


Fig. 674a, b Budd–Chiari syndrome. **a** Acute Budd–Chiari syndrome: lymph node metastases (L) from ovarian carcinoma, completely infiltrating the vena cava (VC) at the termination of the hepatic veins. **b** Chronic secondary Budd–Chiari syndrome: diffuse hepatic metastasis from bronchial carcinoma. The hepatic veins are obliterated as far as the vena cava (VC), which is still patent

## Associated Findings

### ► Functional impairment (see Fig. 656, p. 437, and Fig. 673, p. 446):

- Biliary tract obstruction (biliary tumor, pancreatic tumor, gastric tumor)
- Urinary tract obstruction (gynecologic tumors, intestinal tumors, urothelial carcinoma)
- Obstruction of the vena cava
- Obstruction of the pancreatic duct (pancreatic carcinoma, benign microcystic cystadenoma)
- Partial or complete bowel obstruction (urogenital tumors, gastrointestinal tumors, pancreatic involvement by intra-abdominal metastasis, infiltration or peritoneal carcinomatosis)
- Locoregional metastasis

### ► Abnormal accumulations of fluid:

- *Pleural effusion* (pleural metastases, see Fig. 659, p. 439)
- *Ascites*:
  - *Generalized*: with peritoneal carcinomatosis, hepatic metastases
  - *Circumscribed*: with advanced gallbladder tumors, urogenital tumors, or intestinal tumors
- *Differentiation of benign and malignant ascites*: see Figs. 675 and 676, Table 81

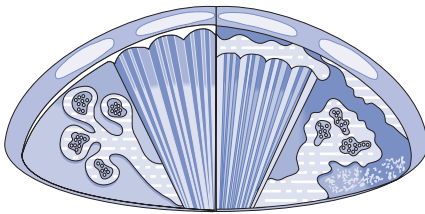


Fig. 675 Characteristic features of benign (left) and malignant (right) ascites (after Meckler)

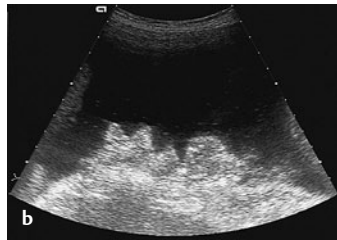
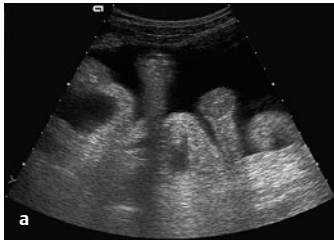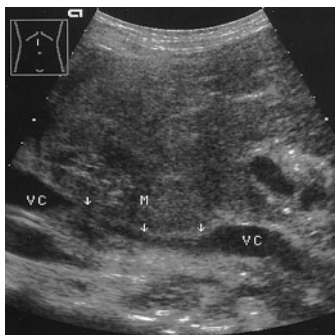


Fig. 676a, b Benign and malignant ascites. **a** Benign ascites: smooth peritoneum and free-floating small bowel loops ("sea anemone sign") in a patient with decompensated hepatic cirrhosis. **b** Malignant ascites: internal echoes and marked mesenteric retraction consistent with malignant ascites

**Table 81** · Sonographic features of benign and malignant ascites

Benign ascites	Malignant ascites
Anechoic (internal echoes, septa)	(Anechoic), internal echoes, septa
Free-flowing	Confined (loculated, encapsulated)
Smooth, regular peritoneum	Irregular peritoneum, mass
Thin greater omentum	Thick, rigid greater omentum
Unconstrained mesentery	Retracted mesentery
"Sea anemone" pattern (Fig. 676)	Matted loops of small bowel
Thin, mobile bowel wall	Thickened, rigid bowel wall
	Adhesions between the bowel and abdominal wall
	Nodal and hepatic metastases
<b>Occurrence</b>	
Hepatic cirrhosis, pancreatitis, right heart failure	Metastases and tumors of the bowel, pancreas, uterus, and ovaries

Fig. 677 Compression and infiltration (arrows) of the vena cava (VC) by hepatic metastases (M, here in the caudate lobe), leading to inferior vena cava syndrome. Primary tumor: breast carcinoma



► **Displacement, fixation, and infiltration** (Fig. 677; see also Fig. 656, p. 437, and Fig. 664, p. 441):

- **Displacement:**
  - Of organs (kidney, spleen, or stomach by hepatic, intestinal, and pancreatic tumors)
  - Of vessels and tubular structures (vena cava with superior or inferior vena cava syndrome)
- **Fixation:**
  - Of stomach and bowel
  - Of serous membranes (peritoneum, pleura)
- **Infiltration:**
  - Of adjacent organs (biliary tract, spleen, kidney, stomach)
  - Of serous membranes (peritoneum, pleura)
  - Of vessels (vena cava by hepatic metastases, bronchial carcinoma, renal tumors; portal vein, splenic vein and celiac trunk by pancreatic carcinoma)
  - Of hollow viscera (urinary bladder, gallbladder) by gastrointestinal or urogenital tumors

## 21.3 Evaluation and Further Testing

### Sonographic Evaluation of Malignancy

- Of all the abdominal tumors that are detectable by ultrasound, only two can be confidently diagnosed as malignant without additional testing: renal cell carcinoma and renal angiomyolipoma. Hemangioma and focal nodular hyperplasia need additional contrast-enhanced sonography. All other tumors can be classified as benign or malignant only when they display typical features or by the detection or exclusion of other signs of malignancy. Two rules should be kept in mind:
  - Only the cytologic or histologic diagnosis is conclusive.
  - Benign cytology or histology does not, however, exclude a malignant tumor.
- **Suggestive criteria:** Some tumors display a fairly characteristic vascular pattern on CDS or show characteristic blood flow kinetics in contrast-enhanced sonography. These patterns may be useful in terms of benign–malignant differentiation.

- ▶ **Uncertain criteria:** These are criteria relating to tumor appearance, organ changes, and associated findings:
  - Changes in shape and echo pattern, including a hypoechoic halo, calcification, liquefaction, and organ deformation and displacement are found in association with both benign and malignant tumors.
  - **Conclusion:**
    - These sonographic signs are not specific.
    - Nevertheless, the examiner should still look for displacement, halo signs, and microcalcifications as they are important suggestive signs for diagnosis. CDS can also aid in differentiation.
- ▶ **Definite criteria:** Infiltrative growth, locoregional metastasis, and distant metastases are indisputable criteria of malignancy. A specific search should be made for these changes, which can often be detected by ultrasound.

### Further Investigation of Suspected Tumors

- ▶ **Suspected hepatic tumor or metastases:**
  - **Sonography, CDS, CEVS:** CDS is an important tool in the investigation of focal hepatic changes and is frequently combined with contrast-enhanced sonography. As a rule, different types of hepatic tumor display typical patterns of vascularity. Contrast enhanced US (CEUS) permits clear improvements in the characterization and detection of focal liver lesions when compared to unenhanced US.
    - **Hemangiomas:** Ordinary CDS shows little if any internal vascularity in these tumors, except in the case of small “high-flow” hemangiomas (capillary hemangiomas). A definitive diagnosis can be made with contrast-enhanced sonography because it demonstrates the same characteristic progressive peripheral nodular centripetal enhancement that can be seen on CT or MR images.
    - **Adenomas:** detectable vascularity; in CEUS hyperenhancing in the arterial phase, but do not show characteristic vascularity
    - **Focal nodular hyperplasia:** typical spoked-wheel vascular pattern. In CDS, more intensive in CEUS, hyperenhancing, early spoke wheel arteries, centrifugal filling artery.
    - Primary liver tumors (HCC) are vascularized. In CEUS hyperenhancing with “chaotic” vessels. According to Tanaka, they often show a combination of the “basket” and “branching” patterns of angiogenesis (see p. 446).
    - **Metastases:** Most metastatic tumors do not have demonstrable blood vessels neither in CDS nor in CEUS (Fig. 678a–d). Exceptions are metastases from endocrine tumors and renal carcinoma, some of which show conspicuous vascularity.
    - Focal fatty infiltration may be confused with hepatic metastases, but CDS is helpful in differentiating benign and malignant masses: hepatic veins and portal venous branches are observed to pass through the apparent mass unchanged.
  - **CT:** The diagnostic accuracy of ultrasound in the detection of malignant hepatic tumors and metastases is somewhat less than that of CT (accuracy rate of 80–95 %, and 95 % with CT angiography). The sensitivity of contrast-enhanced sonography in the detection of hepatic tumors is equal or even superior to that of CT angiography.

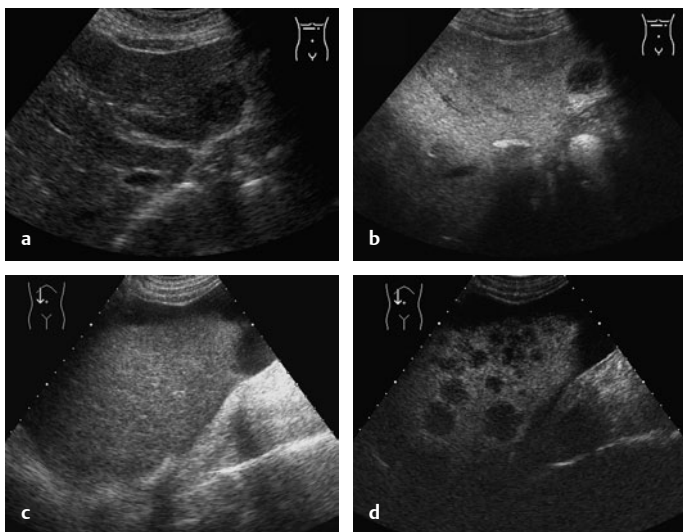


Fig. 678a–d **a** Native image of a weakly visible liver metastasis in the left lobe of a pancreas carcinoma. **b** CEUS; sharply limited hypovascular metastasis. **c** Native image of an inhomogeneous left lobe, ascites. **d** CEUS; multiple lesions (metastasis) without enhancement in CEUS

- **MRI:** This modality is reasonably accurate in differentiating hemangiomas and cysts from metastases. It is difficult, however, to distinguish hepatic adenoma and hepatocellular carcinoma from metastases with MRI, and it is difficult to distinguish focal nodular hyperplasia from hepatic adenoma and hepatocellular carcinoma.

► **Suspected biliary or gallbladder carcinoma:**

- **Sonography:**
  - The hepatic duct and common bile duct can be traced sonographically to the site of the obstructive lesion, which can then be evaluated in magnified views.
  - Gallbladder carcinoma is easily detected with ultrasound, but usually it is no longer operable because of early lymphogenous metastasis and local spread.
  - Stones are difficult to detect in cases where tumor has completely permeated the lumen.
- **ERC; FNAB** (if required)
- **CT:** generally unrewarding with small bile-duct tumors but very accurate in the detection of gallbladder tumors. Infiltration of the liver by isoechoic tumor is difficult to detect by ultrasound, and CT may be helpful in these cases.

► **Suspected pancreatic tumor:**

- **Sonography:** reliable sonographic evaluation with a sensitivity of 72% (only about 32% for tumors  $\leq 2$  cm, comparable to CT)
- **Endosonography:** Maximum accuracy, 100%
- **ERP:** diagnostic accuracy of approximately 70%, because pancreatic tumors almost always arise from the ductal epithelium.

- *Fine-needle aspiration cytology and histology*: high accuracy rate, > 90%. FNAB is not indicated for operable tumors, however, because of possible false-negative findings and the risk of seeding malignant cells along the needle track.
- *Surgery and histology*: Small hormonal tumors (insulinomas) cannot be detected by nonoperative methods, including endosonography, and surgical diagnosis is required.
- *Tumor marker Ca 19-9*: A positive test is not a criterion for malignancy, as elevated markers are also found in association with benign tumors and pancreaticitis. Follow-up is helpful in these cases.
- ▶ **Suspected renal tumor**: Sonographic malignancy criteria:
  - *Frauscher classification*: Peripheral vascularity and the presence of intratumoral “spot-like” vessels are considered definite criteria for malignancy. Frauscher grades 3 and 4 are suggestive of renal cell carcinoma; grade 2 is characteristic of angiomyolipoma and other tumor types (noncontrast sonography)
    - Grade 0:  
No halo and no tumor vascularity
    - Grade 1:  
Peripheral vascularity
    - Grade 2:  
Peripheral vascularity and one intratumoral vessel
    - Grade 3:  
Peripheral vascularity and 2–4 intratumoral vessels
    - Grade 4:  
Peripheral vascularity and more than 5 intratumoral vessels
  - *Muster classification*: The detection of a tumor-feeding vessel is added to peripheral perfusion. In this scheme the combination of peripheral vascularity and a tumor-feeding vessel has a 96% sensitivity in the detection of a malignant tumor.
- ▶ **Suspected thyroid malignancy**: There are no definite sonographic criteria for distinguishing between adenomas and carcinomas in the thyroid gland. Both exhibit a complete or incomplete vascular halo and intratumoral vessels (although the halo tends to be complete with adenomas and fragmentary with carcinomas). With metastases and lymph nodes, however, duplex scans may demonstrate “blinking” vessels with a high RI (see p. 193) that are suggestive of malignancy.
- ▶ **Suspected gastrointestinal tumors**:
  - *Sonography*: particularly useful in searching for an occult tumor in elderly, bed-ridden patients. Ultrasound is a very effective tool for screening the entire colon (identified by its folds and haustra), and symptomatic tumors are easily detected. CDS can demonstrate aberrant (“spot-like”) tumor vessels that suggest malignancy.
  - *Endoscopy*: Small tumors and polyps are the domain of endoscopy.
  - *Tumor markers* (CEA): particularly useful preoperatively and for follow-up.
- ▶ **Suspected malignant pleural effusion or malignant ascites**:
  - *Sonography*: Using high transducer frequencies and magnified views, the sonographer can look for irregularities in the pleura and peritoneum that would indicate carcinomatosis. This technique has a surprisingly high accuracy rate.
  - *The diagnosis can be confirmed* by FNAB, pleuroscopy, pleural biopsy, or laparoscopy. (CT is unrewarding for pleural and peritoneal carcinomatosis.)

- ▶ **Suspected lymph node metastasis.** Sonographic signs of malignancy are as follows:
- *Periperal lymph nodes:* Longitudinal/transverse axis ratio  $< 2:1$  (see Fig. 144, p. 109)
  - *Pathologic tumor vessels:* The predictive factor for nodal malignancy is 94% when all four criteria are present (see below). Reactive lymph nodes, by contrast, are more likely to show a hilar, longitudinal, peripheral, or punctate pattern of vascularity (Tschammler).
  - *Patterns suspicious for malignancy:*
    - Multiple vessels
    - Displacement and aberrant course of intranodal vessels
    - Focal avascular areas
    - Detectable subcapsular vessels

## Subject Index

## Notes

Abbreviations used: CDS - color Duplex sonography

Page numbers in *italics* refer to figures.

vs. indicates a comparison or differential diagnosis.

## A

- abdominal hernia, 105, 105
  - palpable masses vs., 99
- abdominal lymph nodes, 108
- abdominal pain
  - diffuse *see* diffuse abdominal pain
  - lower *see* lower abdominal pain
  - upper *see* upper abdominal pain
- abdominal sonography, 16-31
  - scan planes, 16, 17, 19
    - - longitudinal scan, 16, 17
    - - sequence of, 18
    - - transverse scan, 16, 17
  - - *see also* topography
- abdominal tumor
  - ascites, 155, 159, 159
  - differential diagnosis, 88
  - obstructive lesion, 89
- abdominal vessels, 28, 188-190, 191
  - *see also specific blood vessels*
- abscesses, 94-95, 95
  - aorta, 206
  - chest wall, 402, 402
  - fever vs., 92
  - gallbladder, 341, 341, 351
  - kidney, 277, 278, 286, 286
  - liver *see* liver
  - male genital organs, 392
  - perirenal masses, 292
  - postoperative ultrasound, 435, 436
  - salivary glands, 427
  - spleen, 316, 319, 320
  - therapeutic aspiration/drainage, 56, 59, 60, 61
  - thyroid gland, 419-420, 420
- absorption, 3
- Achilles tendon, 44, 178
  - bursitis, 178
  - distance values, 45
- acoustic enhancement, 11, 12
- acoustic shadowing, 11, 11
  - gallbladder, 348-349
  - gallstones, 11
- acquired pyloric stenosis, 357, 357
- acromioclavicular arthritis, 170, 170-171
- active infective colitis, 368, 369
- acute abdomen, 438
- acute cholecystitis, 63, 63-64
  - further testing, 351
  - gallbladder, 339, 339-340, 340
  - gallbladder hydrops, 63, 64
  - upper abdominal pain vs., 62
- acute febrile enterocolitis, 364, 364-365
- acute glomerulonephritis, 135, 269, 269
  - differential diagnosis, 117, 125
  - edema, 117, 119
- acute hepatitis, 235
- acute nonsuppurative thyroiditis
  - differential diagnosis, 179
  - goiter, 184
- acute pancreatitis, 65-67, 66, 295, 295-296
  - computed tomography, 310
  - fine-needle aspiration, 310
  - further testing, 299, 310
  - necrosis, 66, 301, 302
  - parasitic cysts, 301, 302
  - pseudocyst, 301, 302
  - upper abdominal pain vs., 62
- acute prostatitis, 389, 390
- acute renal failure (ARF), 124-138, 268, 269
- acute suppurative cholangitis, 145
- acute suppurative thyroiditis
  - differential diagnosis, 179
  - goiter, 184
- adenoid cystic carcinoma, salivary glands *see* salivary glands
- adenoma
  - gallbladder, 347, 347-348
  - liver, 248, 248
  - pleomorphic, salivary glands, 429
  - thyroid gland, 181, 181, 419, 419, 422, 422
    - - differential diagnosis, 179
- adenomatous hyperplasia, thyroid gland, 418, 418-419
- adenomatous nodules, thyroid gland, 422
- adenomyomatosis, gallbladder, 343, 344
- adhesive bands, 82, 82
- adjustment errors, equipment settings, 6
- adnexitis, 78-79, 79
  - lower abdominal pain vs., 75
- adrenal glands, 262-293
  - documentation, 47
  - examination, 264-266, 265
  - fine-needle aspiration biopsy (FNAB), 56
  - normal, 265, 265
  - tumors, 292
- adrenal tumors, 96, 96-97
  - fever vs., 93
- agenesis, gallbladder, 337
- AIDS, gallbladder, 340, 340
- alcoholic cirrhosis, 238, 239, 239
- alcohol instillation, therapeutic aspiration and drainage, 60
- aliasing, CDS, 8
- alimentary fatty liver, 234, 234
- A-mode ultrasound, 3, 4
- amyloidosis
  - differential diagnosis, 179
  - goiter, 179, 186-187
  - small intestine wall thickening, 365
- analgesic nephropathy, 133-134, 271, 271
  - differential diagnosis, 125
- anastomoses, postoperative ultrasound, 433, 433
- anechoic changes, 48
  - liver, 241, 242-244
  - salivary glands, 427-428
  - thyroid gland, 417-418
- aneurysms, 198, 198-199, 199
  - classification, 206
  - hepatic artery, 243
  - renal artery, 200
- angiography, 207
- angiomyolipoma, kidney, 279-280, 280
- ankle
  - arthritis, 176, 176-177
  - distance values, 45
- ankylosing spondylitis, 169
- Ann Arbor staging, 113
- annular pancreas, 298, 298

- anterior humeroradial scan, elbow, 40
  - anterior humeroulnar scan, elbow, 40
  - anterior longitudinal scan
    - hip, 41
    - knee, 42
    - malleolar region, 44
    - shoulder, 36, 36
  - anterior transverse scan
    - knee, 42
    - malleolar region, 44
    - shoulder, 32, 37, 37
  - antiglomerular basement membrane disease, 129
    - differential diagnosis, 125
  - aorta, 28, 188, 188, 189, 192, 194-207
    - abscesses, 206
    - anomalies, 194
    - atherosclerotic changes, 192, 198
    - Doppler indices, 193, 193
    - ectasia, 197, 197
    - elongation, 197, 197
    - hemodynamic changes, 192
    - right midabdominal transverse scan, 25
    - sclerosis, 197, 197
    - tortuosity, 197
    - upper abdominal longitudinal scan, 22, 29
  - aortic aneurysms, 204, 204, 207
    - differential diagnosis, 205
  - aortic valve insufficiency, 209
  - appendicitis, 75-76, 76
    - differential diagnosis, 75, 373
    - large intestine wall thickening, 369, 369
  - arterial perfusion disorders, 436
  - arterial prosthesis, 195, 229
  - arteries, 188-213, 194-207
    - aneurysms, 198, 198-199, 199
    - anomalies, 194
    - arterial prosthesis, 195, 229
    - arteriovenous fistula, 195, 196
    - atherosclerosis, 202, 202
    - classification by location, 201
    - displacement/compression/infiltration, 200, 200
    - Doppler indices, 193
    - echogenic luminal changes, 205, 205
    - echogenic wall changes, 201, 202-203
    - wall thickening, 202, 202
    - elongation, 197
    - false aneurysm, 195, 196
    - flow velocities, 193
    - further testing, 206-207
    - hypochoic luminal changes, 203-204
    - hypochoic wall changes, 201, 202
    - interpretation, 206-207
    - lymphadenopathy, 205
    - metastases, 205
    - paravascular changes, 205, 205-206, 206
    - postoperative lesions, 195-196
    - prosthesis infection, 206, 206
    - retroperitoneal fibrosis, 205
    - sclerosis, 197
    - traumatic lesions, 195-196
    - see also specific arteries
  - arteriovenous fistula, 195, 196
  - arthritis
    - acromioclavicular, 170, 170-171
    - ankle, 176, 176-177
    - cubital, 171, 171
    - hip, 173-174, 174
    - knee see knee
    - osteoarthritis vs., 163
    - shoulder see shoulder
    - sternoclavicular, 170-171, 171
    - synovitis, 35
  - arthrosonography, 31-45
    - abnormal findings, 33
    - capabilities, 31
    - clinical importance, 31
    - distance values, 45
    - guidelines, 36
    - limitations, 31-32
    - normal findings, 32
    - synovial membrane, 32
  - articular synovitis
    - fingers, 172, 172-173, 173
    - toes, 172-173
  - ascariasis
    - bile ducts, 331, 331
    - biliary obstruction, 142
  - ascending thoracic artery, 216
  - ascites, 155-163
    - differential diagnosis, 155-156
    - gallbladder, 344
    - tumors, 439, 447, 448, 448
    - see also specific diseases/disorders
  - atheromatous plaques, 201
    - protuberant intraluminal, 201, 201
  - atherosclerosis, 197-199, 198
    - aorta, 192, 198
    - arteries, 202, 202
    - cervical vessels see cervical vessels
    - plaque classification, 203
  - atrial myxoma, 98
    - fever vs., 93
  - atrophic kidney, 134, 264, 290
    - differential diagnosis, 125
  - attenuation, 3
  - atypical cysts, kidney, 284, 285
  - atypical hemangioma, liver, 249, 249
  - atypical lobulation, liver, 251, 251
  - autoimmune chronic pancreatitis, 309
  - axial resolution (of ultrasound), 2
  - axillary longitudinal scan, shoulder, 39
- B**
- .....
  - bacterial sialadenitis, 428, 428
  - Baker cysts, 175, 176
  - basic equipment settings, 6
  - basilar artery, 216
  - basket pattern, tumor vascularity, 445, 446
  - B-cell carcinoma, thyroid gland, 421
  - B-cell lymphoma, thyroid gland, 421
  - beam angle, CDS, 8
  - beam shape, 2
  - benign exudative effusion, pleura, 404, 404
  - benign prostatic hyperplasia (BPH), 386, 387, 390, 390
  - benign tumors see tumors
  - bezoar, 82, 83, 362
  - bicipital tenosynovitis, 167-168
    - polyarthritides, 168
  - bile ducts, 322-333
    - anatomy, 322, 322, 323
    - atresia
      - ascites, 156, 163
      - differential diagnosis, 140
      - carcinoma, 333
      - cirrhosis, 324
      - secondary, 140, 147
      - compression, 143, 143-144
      - differential diagnosis, 140
      - duodenal diverticulum, 144
      - inflamed lymph nodes, 144
      - stent treatment, 144
      - tumor, 144
      - cysts, 242, 324, 326, 326
      - ductal dilatation, 325, 325
      - metastases, 329
      - echogenic changes, 330

**biliary colic**

- extended right intercostal scan, 23
  - extrahepatic duct changes, 330-332
  - - anechoic changes, 330-331
  - - echogenic changes, 332
  - - hypoechoic changes, 330-331
  - further testing, 333
  - hepatic artery calcification, 332
  - intrahepatic bile duct carcinoma, 328, 329
  - intrahepatic changes, 324-330
  - - anechoic changes, 324-329
  - - hypoechoic changes, 324-329
  - jaundice, 139
  - normal findings, 322, 324
  - obstruction, 142, 142
  - - differential diagnosis, 139
  - - duct stones, 331
  - papillomatosis, 142, 328, 328, 331
  - papillomatous carcinoma, 328, 328
  - parasagittal upper abdominal longitudinal scan, 323
  - parasites, 328
  - - ascariasis, 331, 331
  - - pneumobilia, 330, 332
  - sclerosing cholangitis, 324, 327, 327
  - sludge, 331, 331, 346, 346-347, 349
  - - further testing, 351
  - - stones, 324, 332, 332
  - - intrahepatic, 330
  - - obstructing cystic duct, 331
  - topography, 21, 21
  - see also gallbladder biliary colic, 64, 64-65
  - upper abdominal pain vs., 62
  - biliary tract
  - carcinoma, 451
  - postoperative obstruction, 435
  - bladder see urinary bladder
  - blood clots, urinary bladder, 386-387, 387
  - blood vessels see *specific blood vessels*
  - B-mode ultrasound, 3, 4
  - cervical vessels, 214, 214
  - common carotid artery, 214
  - shoulder arthritis, 169
  - splenic infarction, 74
  - bone, arthrosonography, 32
  - bone erosion, abnormal findings, 33
  - bowel see gastrointestinal tract
  - brachiocephalic trunk, 216
  - branching pattern, tumor vascularity, 445, 446
  - breast cancer, 97, 97
  - fever, 93
  - palpable masses, 100
  - Budd-Chiari syndrome, 147, 447
  - ascites, 155, 162-163
  - CDS, 152
  - differential diagnosis, 140
  - hepatosplenomegaly, 148, 152, 152
  - bursitis, Achilles tendon, 178
- C**
- .....
  - calcifications
  - liver, 254
  - spleen, 319, 319, 320
  - thyroid gland, 422, 423
  - tumors, 443
  - carcinoid tumors
  - gastrointestinal tract, 440, 440
  - large intestine wall thickening, 372
  - carcinoma
  - gallbladder, 341, 342, 348, 348, 349
  - mucoepidermoid, salivary glands, 429
  - prostate gland, 391, 391
  - stomach wall swelling, 356, 356
  - uterus, 395-396
  - cardiac inflow stasis, hepatosplenomegaly, 148
  - Caroli syndrome
  - bile duct compression, 143
  - cholelithiasis, 141, 142
  - differential diagnosis, 140
  - liver cysts, 242
  - carotid artery
  - stenosis, 221
  - stent implantation, 223, 223, 224
  - carpal joints, 41
  - cartilage, arthrosonography, 32
  - caudate lobe, liver see liver
  - cavitating tumor, kidney, 287, 287
  - C-cell carcinoma, thyroid gland, 421
  - celiac trunk, 28, 188, 189
  - Doppler indices, 193, 193
  - infiltration, pancreatic carcinoma, 200
  - upper abdominal longitudinal scan, 29, 189
  - variations, 195
  - cervical carcinoma, 396, 396
  - cervical vessels, 214-230
  - abnormal findings, 221-230
  - - see also *specific diseases/disorders*
  - anatomy, 216
  - atherosclerotic plaques, 221, 221, 221-222, 222, 222
  - B-mode ultrasound, 214, 214
  - CDS see color duplex sonography (CDS)
  - duplex sonography, 214-216, 215
  - ECA stenosis, 225, 225
  - ICA occlusion, 226, 227, 228, 229
  - ICA stenosis, 225, 226
  - interpretation, 220
  - pulsed Doppler ultrasound see pulsed Doppler ultrasound
  - scanning protocol, 219-221
  - stenosis, 222, 222-223, 223
  - thrombosis, 229, 229-230, 230
  - transverse scans, 220
  - cervix, lower abdominal scan, 378
  - chest wall, 402-403
  - abnormal findings, 402
  - - see also *specific diseases/disorders*
  - abscesses, 402, 402
  - lesion evaluation, 401
  - tumor infiltration, 402, 403
  - cholangiectasis, postoperative ultrasound, 433, 433
  - cholangiocellular carcinoma, 249, 250
  - cholangitis, 145-146
  - chronic, 145, 146
  - differential diagnosis, 139
  - - upper abdominal pain, 63
  - cholecystitis, 147
  - acute see acute cholecystitis
  - differential diagnosis, 140
  - cholelithiasis, 141, 141-142
  - differential diagnosis, 139
  - see also gallstones
  - cholesterol polyps, gallbladder, 347, 347
  - cholesterosis, gallbladder, 343, 343
  - chronic cholangitis, 145, 146
  - chronic cholecystitis, 344, 345

- chronic glomerulonephritis, 128–129, 270, 270
  - differential diagnosis, 125
  - chronic gouty arthropathy, elbow nodules, 172
  - chronic hepatitis, 238, 238
  - chronic myeloid leukemia, liver metastases, 240
  - chronic pancreatitis, 89–90, 296, 296, 297, 297–298
  - computed tomography, 300, 310
  - cysts, 301, 302
  - differential diagnosis, 88
  - duct dilation, 309, 309
  - fine-needle aspiration, 310
  - focal, 306, 306
  - further testing, 299–300, 310
  - glucose tolerance test, 300
  - chronic prostatitis, 391, 392
  - chronic pyelonephritis, 130–131, 271, 271
  - differential diagnosis, 125
  - chronic renal disease, indeterminate, 287
  - chronic sialadenitis, 428
  - chronic toxic liver disease, 238, 238
  - chronic venous insufficiency, 209, 209
  - chronic viral hepatitis, 235, 235
  - chylous effusion, pleura, 406
  - circle of Willis, 216
  - cirrhosis, 239
  - collateral vessels, portal venous system, 258, 259, 259
  - colloid nodules, thyroid gland, 419, 420
  - colon, documentation, 47
  - colon carcinoma
    - gastrointestinal tract, 441
    - liver metastases, 254
  - color artifacts, CDS, 8
  - color duplex sonography (CDS), 7–8
  - aneurysms, 199
  - bicipital tenosynovitis, 167
  - Budd–Chiari syndrome, hepatosplenomegaly, 152
  - cervical vessels, 214–215
  - – anomalous course, 215, 215
  - common femoral vein thrombosis, 121
  - dissecting aortic aneurysm, 71
  - goitrous nodule, 103
  - hepatorenal syndrome, 135
  - iliac artery stenosis, 198
  - left heart failure, 119
  - liver abscesses, 247
  - lymph node metastases, 113, 113
  - lymphoma, 114
  - mitral valve endocarditis, 98
  - Mönckeberg sclerosis, 203
  - neck cysts, 104
  - nodular varix, 106, 106
  - phlegmasia cerulea dolens, 123
  - portal hypertension, 158
  - renal vein thrombosis, 74
  - serpentine aneurysm, 199
  - shoulder arthritis, 169
  - colorectal carcinoma, 370, 371, 371–372
  - common carotid artery, 216, 217
  - B-mode ultrasound, 214
  - common duct stone disease, cholelithiasis, 141
  - common femoral artery, Doppler indices, 193, 193
  - common femoral vein thrombosis, 121
  - common hepatic artery, 189
  - common iliac artery, 188
  - complicated atherosclerotic plaques, 202, 202
  - complicated cysts, kidney, 274, 274
  - compression
    - arteries, 200, 200
    - veins, 211
  - compression atelectasis, lung parenchyma, 409, 410
  - computed tomography (CT)
    - acute pancreatitis, 310
    - biliary tract carcinoma, 451
    - chronic pancreatitis, 300, 310
    - hepatic tumor, 450
    - large intestine, 374
    - liver, 256
    - pancreatic carcinoma, 311
    - stomach, 360
    - veins, 213
  - computed tomography angiography, liver, 256
  - confetti artifact, CDS, 8
  - congenital cysts, pancreas, 301, 301–302
  - congenital hypertrophic pyloric stenosis, 357
  - congestion, veins, 208, 208
  - vena cava, 208
  - congestive cirrhosis, 236, 236, 239
  - conglutination thrombi, 204
  - constipation, 87–91
  - definition, 87
  - differential diagnosis, 88
  - tumors, 440–441
  - constructive pericarditis, hepatosplenomegaly, 148, 152–153
  - continuous-wave (CW) Doppler ultrasound, 4
  - contracted gallbladder, 336, 336, 337
  - contrast-enhanced sonography, 6
  - contrast harmonic imaging (CHI), 5
  - convex scanner, transducers, 5
  - coprostatitis, diffuse abdominal pain vs., 81
  - cortical nephrocalcinosis, 282, 282
  - Courvoisier gallbladder, 336, 336
  - Crohn disease, 87–89
  - differential diagnosis, 88, 373
  - large intestine wall thickening, 366–367, 367
  - peritonitis, 84
  - small intestine wall thickening, 363, 363–364, 364, 364
  - cubital arthritis, 171, 171
  - cutaneous changes, Graves disease, 182
  - cystadenocarcinoma, ovaries, 397, 398
  - cystadenolymphoma (Warthin tumor), salivary glands, 429, 429
  - cystic liver, hepatosplenomegaly, 148, 151
  - cystic neoplasias, pancreas, 302
  - cystic renal cell carcinoma, 275, 276
  - cystic transformation (pseudocysts), thyroid gland, 418, 418
  - cystic tumors, ovaries, 397, 398
  - cysts
    - bile ducts, 324, 326
    - edge shadowing, 15
    - kidney *see* kidney
    - liver *see* liver
    - ovaries, 396, 397
    - pancreas *see* pancreas
    - paraovarian, 396
    - salivary glands, 427
    - spleen, 315, 315–316, 319
- D**
- .....
  - deep vein thrombosis, paraneoplastic syndrome, 441

## degenerative lesions

- degenerative lesions, rotator cuff, 165, 165, 166
  - de Quervain thyroiditis, 415, 415
  - goiter, 184
  - descending thoracic artery, 216
  - diabetic autonomic neuropathy, small intestine, 361, 361
  - diabetic fatty liver, 234, 234
  - diabetic nephropathy, 269, 269, 270, 271
  - diaphragm, right flank scan, 25
  - diaphragmatic crura, liver, 251, 252
  - diarrhea, 87-91
    - definition, 87
    - differential diagnosis, 88
    - tumors, 440-441
  - diffuse abdominal pain, 81-86
    - differential diagnosis, 81
    - see also *specific diseases/disorders*
  - diffuse colloid goiter, 416, 416
  - diffuse goiter, 180
    - differential diagnosis, 179
  - diffuse lesions, kidney, 287
  - diffusely infiltrating carcinoma, large intestine, 370, 370
  - diffuse malignant gastric lymphoma, stomach, 356, 357
  - digital image processing, 5-6
  - digital rectal examination, 394
  - dilated bile ducts, jaundice, 139
  - displacement
    - arteries, 200, 200
    - tumors, 449
  - dissecting aortic aneurysm, 71, 71, 199
    - CDS, 71
    - diffuse abdominal pain vs., 81
    - transesophageal echocardiography (TEE), 199
  - distance values, elbow, 45
  - diuresis urography, 52, 52
  - diverticula
    - large intestine wall thickening, 371
    - urinary bladder, 384, 384
  - diverticulitis, 76, 76-77, 90, 90
    - differential diagnosis, 88
    - lower abdominal pain, 75
    - large intestine wall thickening, 369-370, 370, 371
  - documentation, 46-48
    - guidelines, 46-47
    - image, 46
    - written, 46
  - Doppler effect, 1
  - Doppler frequency, CDS, 7
  - Doppler indices
    - aorta, 193, 193
    - cervical vessels, 215
  - Doppler spectrum, synovitis, 35
  - Doppler ultrasound, 4
    - mesenteric vascular occlusion, 85, 85
  - double-contrast radiography, large intestine, 374
  - ductal dilatation
    - bile ducts see bile ducts
    - pancreas, 309, 309
    - pancreas divisum, 309, 309
    - pancreatic tumor, 309
  - ductectasia, pancreas, 299, 299
  - duct stones
    - bile ducts, 324
    - liver, 254
    - pancreas, 305, 305
  - duodenal diverticulum, bile duct compression, 144
  - Duplex sonography, 4
    - cervical vessels see cervical vessels
  - duplicated gallbladder, 342, 342
  - duplication, vena cava, 211, 212
- E**
- ECA stenosis, cervical vessels, 225, 225
  - echinococcal cysts
    - hepatosplenomegaly, 148, 153
    - liver, 244, 244
  - echocardiography, left heart failure, 120
  - echogenicity, 48
    - imaging artifacts, 9
    - liver, 241, 251-254
    - tumors, 443, 443
  - echogenic ligamentum teres, liver, 252, 252-253
  - echogenic luminal changes, arteries, 205, 205
  - echogenic portal tracts, liver, 253, 253
  - echogenic wall changes, arteries see arteries
  - echo patterns, 48, 48
  - ectasia
    - aorta, 197, 197
    - portal vein, 243
  - ectopic kidney, 264, 264, 290
  - edema, 116-123
    - differential diagnosis, 116-117
    - gallbladder, 341, 341
    - see also *specific diseases/disorders*
  - edge shadowing, 15, 15
  - elbow, 40-41
    - anterior humeroradial scan, 40
    - anterior humeroulnar scan, 40
    - distance values, 45
    - nodules, 171-172, 172
    - chronic gouty arthropathy, 172
    - rheumatoid arthritis, 172
    - posterior longitudinal scan, 41
  - elongation
    - aorta, 197, 197
    - arteries, 197
  - emboli, 203, 203-204
  - emphysematous cholecystitis, 345, 346
  - empyema
    - gallbladder, 347, 347, 349, 351
    - therapeutic aspiration/drainage, 60, 61
  - endocarditis, 98-99
    - fever vs., 93
  - endometrial carcinoma, 395, 396
  - endometriosis, 398, 398-399
  - endometriosis externa, 399
  - endoscopy
    - goitrous nodule, 102
    - large intestine, 374
  - endosonography
    - large intestine, 374
    - pancreatic tumor, 311, 451
  - enterocolitis, 364, 364-365
    - acute febrile, 364, 364-365
  - epididymitis, 394, 394
  - epiploic appendicitis, 77, 77
    - lower abdominal pain vs., 75
  - equipment settings, 6
  - erosive psoriatic arthritis, 34
  - esophagus, 352
  - examination, 16-45
  - extended intercostal scan, 19
  - extended right intercostal scan, 23, 24
  - external carotid artery, 218, 218
    - transverse scans, 220
  - external iliac artery, 188
  - external iliac vein, 28
  - extrahepatic cholelithiasis, 141, 142
  - exudation, knee arthritis, 174, 174
  - exudative coxitis, joint effusion, 33

- F**  
 .....  
 fallopian tubes, 30  
 false aneurysm, arteries, 195, 196  
 fatty liver, 146–147  
 – differential diagnosis, 140  
 – focal sparing, 245, 245, 246  
 – hepatosplenomegaly, 148, 149, 149–150  
 febrile enterocolitis, acute, 364, 364–365  
 female genital organs, 29, 395–399  
 – abnormal findings, 395  
 – – *see also specific diseases/disorders*  
 – anatomy, 377  
 – lower abdominal scan, 378  
 female urinary bladder, 29  
 femoral hernia, 105  
 – palpable masses vs., 99  
 femoral vein thrombosis, 210  
 fetal lobulation, kidney, 278, 278  
 fever, 92–99  
 – differential diagnosis, 92–93  
 – lymph node enlargement, 92  
 – primary tumors, 92  
 – tumors, 438  
 fibroma, 107  
 – palpable masses vs., 100  
 fibrosis  
 – liver, 235, 235–236  
 – pancreas *see pancreas*  
 fine-needle aspiration biopsy (FNAB), 53–57  
 – contraindications, 57  
 – general risks, 57  
 – indications, 56–57  
 – interpretation, 57  
 – liver, 256  
 – materials, 53, 53  
 – organs, 56–57  
 – pancreatic carcinoma, 310  
 – pancreatic insufficiency, 90  
 – pancreatic tumor, 451  
 – pancreatitis, 310  
 – technique, 53, 54, 55, 56  
 fingers, 41  
 – articular synovitis, 172, 172–173, 173  
 fixation, tumors, 449  
 flexion creases, gallbladder, 342, 343  
 flow changes, portal venous system, 258, 259, 259  
 fluid accumulations  
 – fine-needle aspiration biopsy (FNAB), 57  
 – postoperative ultrasound, 434, 434  
 fluid deficit, 126  
 – differential diagnosis, 125  
 focal chronic pancreatitis, 306, 306  
 focal fatty infiltration, liver, 252, 252  
 focal nodular hyperplasia, 248, 248  
 – further testing, 450  
 – vascularity, 445  
 focal pancreatitis, 303, 304  
 focal sparing, fatty liver, 245, 245, 246  
 focusing, resolution (of ultrasound), 2  
 foreign bodies  
 – postoperative ultrasound, 436, 436  
 – urinary bladder, 387, 388  
 – uterus, 396, 396  
 Frauscher classification, renal tumors, 452  
 frequency, 1–2  
 functional impairment, tumors, 447  
 function studies, 49–52  
 – diuresis urography, 52, 52  
 – gallbladder contractions, 49, 49  
 – gastric emptying, 50, 50  
 – residual urine determination, 51, 51  
 – carcinoma, 348, 348, 349  
 – cholesterol polyps, 347, 347  
 – complex echo pattern, 349–350  
 – empyema, 347, 347, 349  
 – gravel, 348, 348  
 – hydrops, 347  
 – phlegmons, 349  
 – pneumobilia, 349  
 – sludge, 346, 346–347, 349  
 – stones, 348, 349  
 – stony gallbladder, 349, 349  
 – location changes, 337, 337  
 – nonvisualization, 337–338  
 – normal findings, 334, 334  
 – perforated *see perforated gallbladder*  
 – “Phrygian cap,” 337, 337  
 – positional changes, 335  
 – scan planes, 334  
 – extended right intercostal scan, 24  
 – right longitudinal paramedian scan, 24  
 – right midabdominal transverse scan, 25  
 – shape changes, 335, 337, 337  
 – shrunken (stony), 336, 336, 337, 338  
 – side-lobe artifact, 10  
 – siphon, 337  
 – size changes, 335, 335, 336–338  
 – sludge, 351  
 – stones *see cholelithiasis; gallstones*  
 – stony, 337  
 – topography, 20, 20  
 – tumors, weight loss, 437  
 – upper abdominal longitudinal scan, 22  
 – wall changes, 335, 339–345  
 – abscesses, 341, 341  
 – adenomyomatosis, 343, 344  
 – AIDS, 340, 340  
 – ascites, 344  
 – carcinoma, 341, 342  
 – cholesterosis, 343, 343  
 – chronic cholecystitis, 344, 345  
 – complex, 339–341  
 – differential diagnosis, 341  
 – echogenic, 342–345  
 – edema, 341, 341  
 – emphysematous cholecystitis, 345, 346  
 – flexion creases, 342, 343  
 – hypoechoic, 339–341  
 – liver disease, 340, 340  
 – lymphoma, 341

**G**

- .....  
 gallbladder, 334–351  
 – abscesses, 351  
 – acoustic enhancement, 12  
 – acute cholecystitis, 339, 339–340, 340  
 – agenesis, 337  
 – anatomy, 334, 334  
 – congestion, 336, 336  
 – contracted, 49, 49, 336, 336, 337  
 – Courvoisier, 336, 336  
 – differential diagnosis, 351  
 – documentation, 46  
 – duplicated, 342, 342  
 – echogenic, 337, 338  
 – empty, 337, 338  
 – empyema, 351  
 – further testing, 351–352  
 – hypoplasia, 336  
 – interpretation errors, 351  
 – intraluminal changes, 335, 346–350  
 – acoustic shadowing, 348–349  
 – adenoma, 347, 347–348

## gallbladder diverticulum

- - metastases, 341
  - - pancreatic disease, 340, 340
  - - porcelain gallbladder, 344, 344–345
  - - trauma, 340
  - - xanthogranulomatous cholecystitis, 344, 344
  - see also bile ducts
  - gallbladder diverticulum, 337, 337
  - gallbladder hydrops, acute cholecystitis, 63, 64
  - gallstones, 348, 349, 350, 351
    - acoustic shadowing, 11
    - further testing, 351
    - mechanical bowel obstruction, 82, 83
    - small intestine, 362
    - see also cholelithiasis
  - gastric carcinoma, stomach wall thickening, 358, 358
  - gastric emptying, 50, 50
  - gastric ulcer, stomach wall thickening, 357
  - gastrinoma, gastrointestinal tract, 441
  - gastroenteritis
    - diffuse abdominal pain vs., 81
    - small intestine, 361, 361
  - gastroenterology, contrast-enhanced sonography, 6
  - gastrointestinal tract, 352–375
    - anatomy, 352
    - carcinoid tumors, 440, 440
    - colon carcinoma, 441
    - documentation, 47
    - gastrinoma, 441
    - mechanical obstruction, 82, 82, 83
    - - small intestine, 361–362
    - normal findings, 352
    - obstruction
      - - ascites, 155, 161–162
      - - gastrointestinal tract tumors, 438
      - - mechanical see above
      - - postoperative, 435
      - - rectal carcinoma, 441
      - - scanning protocol, 354
      - - scan planes, 352
      - - tumors, 93, 93–94
      - - - bowel obstruction, 438
      - - - fever vs., 92
      - - - further investigation, 452
      - - - weight loss, 437
    - vipoma, 441
    - wall structure, 352
    - see also specific organs
  - gastroscopy, 359–360
  - genital organs, 379
    - documentation, 47
    - female see female genital organs
    - male see male genital organs
    - scanning protocols, 379
    - scan planes, 375
  - glomerulonephritis
    - acute see acute glomerulonephritis
    - chronic see chronic glomerulonephritis
    - classification, 124
    - occurrence, 124
  - glucose tolerance test, chronic pancreatitis, 300
  - goiter, 179–187
    - differential diagnosis, 179
    - diffuse see diffuse goiter
    - Graves disease, 182
    - Riedel thyroiditis, 184–185
  - goitrous nodule, 102, 102–103, 103
    - CDS, 103
    - endoscopy, 102
    - palpable masses vs., 99
  - gouty nephropathy, 136, 136, 269, 269
    - differential diagnosis, 126
  - gravel, gallbladder, 348, 348
  - Graves disease, 182, 182–183
    - differential diagnosis, 179
    - hyperthyroidism, 182, 415, 415–416
- ## H
- halos, tumors, 444–445
  - hard plaques, cervical vessels, 222, 222
  - Hashimoto thyroiditis, 183, 183, 415, 415
    - differential diagnosis, 179
  - heart failure
    - with low-output syndrome, 127, 127
    - renal insufficiency, 125
    - shock kidney, 136
  - helminthiasis, 140
  - hemangioma
    - liver, 253, 253–254
    - microcalcification, 444
    - pancreas, 306
    - salivary glands, 430
    - spleen, 318, 318, 320
  - hematoma
    - chest wall, 402
    - kidney, 276, 276, 279
    - liver, 244, 245, 253
    - male genital organs, 392, 392
    - perirenal masses, 292
  - hemodynamic changes, aorta, 192
  - hemorrhage, kidney
    - intracystic, 275, 275
    - intratumoral, 287, 287
  - hemorrhagic cysts
    - kidney, 287, 288
    - liver, 247, 247, 254, 254
  - hemorrhagic effusion, pleura, 405
  - hepatic artery
    - aneurysms, 243
    - calcification, 332
  - hepatic cirrhosis, 140, 140, 156, 156–157, 157, 236, 237, 239
    - differential diagnosis, 139
    - - ascites, 155
    - - hepatosplenomegaly, 148
  - hepatosplenomegaly, 149, 149
    - regenerative nodules, 246, 246
  - hepaticojejunostomy, 433
  - hepatic tumors, 145, 145
    - computed tomography, 450
    - differential diagnosis, 139
    - - ascites, 156
    - - hepatosplenomegaly, 148, 150, 150
    - further testing, 450
    - magnetic resonance imaging, 450
  - hepatic veins, 28
    - right subcostal oblique scan, 22
  - hepatocellular carcinoma, 249, 249
    - halo, 444
    - microcalcification, 444
  - hepatorenal syndrome, 135, 135
    - CDS, 135
    - differential diagnosis, 125
  - hepatosplenomegaly, 148–154
    - CDS, 152
    - differential diagnosis, 148
    - see also specific diseases/disorders
  - hernia, 77, 77–78, 91
    - abdominal see abdominal hernia
    - differential diagnosis, 88
    - - lower abdominal pain, 75
    - - palpable masses, 99
    - - upper abdominal pain, 62
  - high lateral intercostal scan (high left flank scan), 19, 26
  - hip, 41–42
    - anterior longitudinal scan, 41
    - arthritis, 173–174, 174
    - distance values, 45
    - posterior transverse scan, 42
    - synovitis, 174

- Hodgkins disease, 114
- hepatosplenomegaly vs., 148
  - weight loss, 438
- hyaline connective tissue, thyroid gland, 419
- hydrocele, testis, 393, 393
- hydronephrosis, 131
- differential diagnosis, 125
- hydronephrotic sac, 383, 384
- hydrops, gallbladder, 347
- hyperechoic pattern, 48
- salivary glands, 430
  - thyroid gland, 416-417, 418-421, 422-423
- hypernephroma, 95-96, 96
- fever vs., 93
- hypertension, 197-199
- hyperthyroidism, Graves disease, 182, 415, 415-416
- hypoechoic pattern, 48
- arteries, 203-204
  - artery wall changes, 201, 202
  - liver, 241, 245-251
  - salivary glands, 428-429
  - thyroid gland, 414-416
- hypoplasia, gallbladder, 336
- hypoplastic kidney, 269, 270
- I**.....
- ICA occlusion, cervical vessels, 226, 227, 228, 229
- ICA stenosis, cervical vessels, 225, 226
- iliac artery stenosis, 198
- CDS, 198
- image documentation, 46
- imaging artifacts, 8-15, 9
- acoustic enhancement, 11, 12
  - acoustic shadowing, 11, 11
  - echogenicity classification, 9
  - edge shadowing, 15, 15
  - mirror image artifact, 13, 13, 14
  - noise, 10, 10
  - principles, 8
  - reverberations, 14, 14-15
  - side-lobe artifact, 9, 9, 10
  - slice-thickness artifact, 12, 12-13, 13
  - *see also specific types*
- impaired gastric emptying, 70, 70
- upper abdominal pain vs., 62
- impedance mismatch, 3
- implant materials, postoperative ultrasound, 431, 431
- infarction, spleen, 317, 317, 320, 321
- inferior mesenteric artery, 28
- Doppler indices, 193, 193
- inferior vena cava, 28, 188-189, 191
- infiltrating carcinoma, large intestine, 370, 371
- infiltration
- arteries, 200, 200
  - tumors, 449
- inflammation
- effusion, pleura, 405
  - lymph nodes *see* lymph nodes, enlargement
- inflammatory mass, kidney, 287, 287
- inguinal hernia, 105
- palpable masses vs., 99
- infercostal scan, 19
- internal carotid artery, 217, 218
- looping, 215
  - stenosis, 215
  - transverse scans, 220
- internal iliac artery, 188
- internal iliac vein, 28
- interorgan bleeding, upper abdominal pain vs., 63
- interstitial nephritis, classification, 124
- interventional ultrasound, 52-61
- *see also specific techniques*
- intra-abdominal bleeding, 86, 86
- diffuse abdominal pain vs., 81
- intra-abdominal lymph nodes, documentation, 46
- intracranial Doppler sonography, 220
- intracystic hemorrhage, kidney, 275, 275
- intrahepatic bile duct carcinoma, 328, 329
- intrahepatic cholelithiasis, 141, 142
- bile ducts, 330
- intrahepatic thrombosis, portal vein, 247, 247
- intraluminal changes
- thrombosis, 210, 210
  - veins, 208, 210
- intraorgan bleeding, 72, 72-73
- intratumoral hemorrhage, kidney, 287, 287
- intussusception, 82, 83
- small intestine, 362
- ischemic colitis, 368, 368
- isoechoic changes
- liver, 241, 251
  - thyroid gland, 418-421
- J**.....
- jaundice, 139-147
- differential diagnosis, 139-140
  - dilated bile ducts, 139
  - liver size/configuration, 139
- joint effusion
- abnormal findings, 33
  - erosive psoriatic arthritis, 34
  - exudative coxitis, 33
- joint imaging
- see* arthrosonography
- joint pain/swelling, 163-178
- differential diagnosis, 164
  - *see also specific diseases/disorders*
- jugular vein thrombosis, 229, 229, 230
- tumor, 441
- K**.....
- kidney, 262-293
- abscesses, 277, 278, 286, 286
  - anatomy, 262
  - anechoic changes, 284-287
  - angiomyolipoma, 279-280, 280
  - atrophic, 264, 290
  - cavitating tumor, 287, 287
  - circumscribed lesions, 287, 287
  - circumscribed parenchyma changes, 272
  - - - anechoic changes, 272-276
  - - - hyperechoic, 279-283
  - - - hypoechoic, 276-278
  - - - isoechoic, 276-278, 278-279
  - circumscribed pelvis/sinus changes, 283-288
  - - - anechoic, 284-287
  - - - hypoechoic, 284-287
  - - - isoechoic, 287-288
  - cysts, 272-273, 273
  - - - atypical, 284, 285
  - - - complicated, 274, 274
  - - - hemorrhagic, 287, 288
  - - - multiple parapelvic, 275, 284, 284
  - - - parapelvic, 290
  - diffuse changes, 267-271
  - diffuse lesions, 287
  - documentation, 46
  - echogenicity, 266
  - ectopic, 264, 264, 290
  - evaluation, 287-291
  - examination, 292-264
  - fetal lobulation, 278, 278

- fine-needle aspiration biopsy (FNAB), 57
  - further testing, 287–291
  - hematoma, 276, 276, 279
  - hemorrhage
    - - intracystic, 275, 275
    - - intratumoral, 287, 287
  - hyperechoic changes, 268–269
    - - circumscribed parenchyma changes, 279–283
      - - large, 268–269
      - - parenchyma, 279–283
      - - small (hypoplasia), 270–271
  - hypoechoic changes, 267, 267, 267–268
    - - circumscribed pelvis/sinus, 284–287
      - - large, 267–268
    - - parenchyma, 276–278
  - hypoplastic, 269, 270
  - indeterminate mass, CDS, 289, 290
  - infected obstruction, 286, 286
  - inflammatory mass, 287, 287
  - isoechoic changes
    - - circumscribed pelvis/sinus, 287–288
    - - parenchyma, 278–289
    - - small (hypoplasia), 269–270
  - large, 264, 264
    - - hyperechoic, 268–269
    - - hypoechoic, 267–268
  - left flank scan, 26
  - left midabdominal transverse scan, 27
  - lymphocele, 275
  - lymphoma, 276, 277
  - metastases, 276
  - multiple parapelvic tumor, 284, 284
  - non-Hodgkins lymphoma, 277
  - normal, 263
  - obstructive pyelocalyceal ectasia, 275
  - oncocytoma, 278
  - parenchyma bands, 278, 279, 284, 285
  - parenchymal calcification, 283
  - pelvic stone, 288, 288
  - pyelitis, 286, 286
  - pyonephrosis, 286, 286
  - renal calyceal, 288, 288
  - right flank scan, 25
  - right intercostal scan, 23
  - right midabdominal transverse scan, 25
  - scar tissue, 280, 280–281, 281
  - secondary cysts, 274, 274
  - size changes, 266
  - small (hypoplasia), 263, 263, 264, 269–270
    - - hyperechoic, 270–271
    - - hypertension, 290
    - - isoechoic, 269–270
  - solitary parapelvic tumor, 284
  - tuberculosis, 275
  - tumors
    - - Frauscher classification, 451
    - - further investigation, 451
    - - Muster classification, 451
    - - vascular calcification, 283, 288, 288
    - - vascular occlusive disease, 270, 270
    - - *see also entries under renal Kimmelsteil–Wilson*
    - - glomerulosclerosis, 128
    - - differential diagnosis, 125
  - Klatskin tumor, biliary obstruction, 142
  - knee, 42–43
    - - anterior longitudinal scan, 42
    - - anterior transverse scan, 42
    - - arthritis, 35, 174–175
    - - exudation, 174, 174
    - - distance values, 45
    - - osteoarthritis, 174
    - - posterior longitudinal scan, 43
    - - posterior transverse scan, 42
    - - suprapatellar longitudinal scan, 43
    - - suprapatellar transverse scan, 43
- L**
- .....
  - laboratory tests, tumors, 442
  - laparoscopy, liver, 256
  - large intestine, 354, 366–374
    - - abnormal findings, 366
    - - *see also specific diseases/disorders*
    - - circumscribed wall thickening, 365–366, 370–371
      - - - carcinoid, 372
      - - - colorectal carcinoma, 370, 371, 371–372
      - - - diverticula, 371
      - - - diverticulitis, 371
      - - - infiltrating carcinoma, 370, 371
    - - lymphoma, 372, 372
    - - polyps, 371
    - - ulcerative carcinoma, 370, 371
  - evaluation, 372–374, 373
  - further testing, 372–374
  - long segmental wall thickening, 366–370
    - - active infective colitis, 368, 369
    - - appendicitis, 369, 369
    - - Crohn disease, 366–367, 367
    - - diffusely infiltrating carcinoma, 370, 370
    - - diverticulitis, 369–370, 370
    - - ischemic colitis, 368, 368
    - - lymphoma, 370
    - - pseudomembranous colitis, 368, 368
    - - ulcerative colitis, 367, 367–368
  - lateral longitudinal scan
    - - hip, 42
    - - malleolar region, 44
  - lateral resolution (of ultrasound), 2
  - left common carotid artery, 216
  - left flank scan, 19, 26
  - left heart failure
    - - CDS, 119
    - - echocardiography, 120
    - - edema, 119, 119–120, 120
    - - pleural sonography, 120
  - left midabdominal transverse scan, 19, 27
  - left subclavian artery, 216
  - left subcostal oblique scan, 19, 27
  - leiomyomas, vascularity, 445, 445
  - lesions, obstructive
    - - abdominal tumor, 89
    - - differential diagnosis, 88
  - linear scanner, transducers, 4–5
  - lipoma, 107, 107
    - - chest wall, 403
    - - palpable masses vs., 100
    - - salivary glands, 430
  - lipomatosis, pancreas
    - - *see pancreas*
  - liquefaction, tumors, 443
  - liver, 231–261
    - - abscesses, 95, 244, 247, 247
    - - - micronodular, 237, 237
    - - adenoma, 248, 248
    - - further testing, 450
    - - halo, 444
    - - vascularity, 445

- anatomical guidelines, 22
- anatomy, 231, 231–232
- atypical hemangioma, 249, 249
- atypical lobulation, 251, 251
- calcification, 254
- caudate lobe, 22
- echogenicity decrease, 246, 246
- circumscribed changes, 233, 241–257
  - anechoic changes, 241, 242–244
  - echogenic changes, 241, 251–254
  - hypoechoic changes, 241, 245–251
  - interpretation, 255–257
  - isoechoic changes, 241, 251
- cirrhosis *see* hepatic cirrhosis
- computed tomography, 256
- computed tomography angiography, 256
- contrast-enhanced sonography, 6
- cysts, 242, 242–244, 255
  - Caroli syndrome, 242
  - hemorrhagic, 247, 247
  - noise, 10
- diaphragmatic crura, 251, 252
- diffuse changes, 233, 234, 234–241
  - interpretation, 240–241
- documentation, 46
- duct stones, 254
- Echinosoccal cysts, 244, 244
- echogenic ligamentum teres, 252, 252–253
- echogenic portal tracts, 253, 253
- examination, 231–233
- fibrosis, 235, 235–236
- hepatosplenomegaly, 148, 153–154, 154
- fine-needle aspiration biopsy (FNAB), 56, 256
  - risks, 57
- focal fatty infiltration, 252, 252
- focal nodular hyperplasia, 248, 248
- fresh hematoma, 253
- hemangioma, 253, 253–254
- hematologic malignant systemic disease, 250, 250
- hematoma, 244, 245
- hemorrhagic cyst, 254, 254
- laparoscopy, 256
- magnetic resonance imaging, 256
- metastases, 237, 237, 239, 240, 244, 245, 250, 250, 255
  - chronic myeloid leukemia, 240
  - colon carcinoma, 254
  - further testing, 450
  - isoechoic, 251, 251
  - mirror image artifact, 14
  - pneumobilia, 254
  - protocol, 232
  - quadrate lobe, 22
  - sarcoidosis, 237, 237
  - scan planes, 231
  - left subcostal oblique scan, 27
    - paramedian upper abdominal longitudinal scans, 231
    - right flank scan, 25
    - right intercostal scan, 23, 231, 232, 232, 233
    - right longitudinal paramedian scan, 24
    - right midabdominal transverse scan, 25
    - right subcostal oblique scan, 22, 231
    - upper abdominal longitudinal scan, 22, 29, 189
    - upper abdominal transverse scan, 231, 232, 233
  - size/configuration, jaundice, 139
  - tumors *see* hepatic tumors
  - ultrasound-guided therapeutic intervention, 256
  - vascularity, 255
  - *see also entries under hepatic; specific diseases/ disorders*
- liver disease
  - edema, 118
  - differential diagnosis, 116
  - gallbladder wall changes, 340, 340
- longitudinal paramedian scan, 19
- longitudinal scan
  - abdominal sonography, 16, 17
  - tendovaginitis, 35
- looping, internal carotid artery, 215
- lower abdominal longitudinal scan, 19, 31
- lower abdominal pain, 75–81
  - differential diagnosis, 75
- *see also specific diseases/ disorders*
- lower abdominal scan, 378
- lower abdominal transverse scan, 19, 30
- lower-extremity thrombosis, 120–121, 121
  - differential diagnosis, 117
- lower extremity venous sonography, 67
- lumbar arteries, 188
- luminal changes, veins *see* veins
- lung parenchyma, 401, 408–411
  - abnormal findings, 408–410
  - *see also specific diseases/ disorders*
  - compression atelectasis, 409, 410
  - lesion evaluation, 401
  - lung tumors, 408, 408
  - metastases, 408, 408
  - obstructive atelectasis, 410, 410
  - pneumonia, 409, 409
  - pulmonary abscesses, 409, 409
  - pulmonary infarction, 410, 411
- lung tumors, lung parenchyma, 408, 408
- lymphadenopathy
  - arteries, 205
  - pancreas, 305, 305
- lymphangioma, salivary glands, 430
- lymphatic pathways, 99
- lymph nodes
  - abdominal, 108
  - fine-needle aspiration biopsy (FNAB), 56
  - metastases
    - CDS, 113, 113
    - further investigation, 452
    - peripheral, 109
- lymph nodes, enlargement, 107–116, 109, 116
  - bile duct compression, 144
  - causes, 110
  - differential diagnosis, 108
  - fever, 92
  - inflammation, 110–111, 111
    - differential diagnosis, 99, 108
  - interpretation errors, 115–116
  - lymphoma, 110
  - metastases, 106, 108, 112, 112, 113
  - differential diagnosis, 108

## lymphocele

- primary tumors, 92
  - principles, 107-110
  - lymphocele, kidney, 275
  - lymphogranulomatous Hodgkins disease, 99
  - lymphoma, 113-115, 114, 115
    - Ann Arbor staging, 113
    - CDS, 114
    - differential diagnosis, 108
    - - fever, 93
    - - hepatosplenomegaly, 148, 150-151, 151
    - - palpable masses, 99
  - enlarged lymph nodes, 110
  - gallbladder wall changes, 341
  - high-grade, 101, 101, 102
  - kidney, 276, 277
  - large intestine wall thickening, 370, 372, 372
  - metastases, salivary glands, 429, 429
  - spleen, 316, 316-317, 320
  - thyroid gland, 416
- M**.....
- macrocalcification, tumors, 443, 444
  - magnetic resonance angiography, 207
  - magnetic resonance imaging (MRI)
    - hepatic tumor, 450
    - liver, 256
  - malassimilation, 300
  - male bladder, 30
  - male genital organs, 30
    - abnormal findings, 389
    - - *see also specific diseases/disorders*
    - abscesses, 392
    - anatomy, 376-377
    - evaluation, 394
    - further testing, 394
    - hematoma, 392, 392
  - malignant effusion, pleura, 406
  - malignant exudative effusion, pleura, 404, 404, 405
  - malignant gastric lymphoma, stomach wall thickening, 359
  - malignant tumors *see* tumors
  - malleolar region, 44, 44
    - tenosynovitis, 177, 178
  - mechanical bowel obstruction *see* gastro-intestinal tract
  - mechanical ileus, diffuse abdominal pain vs., 81
  - medial longitudinal scan, malleolar region, 44
  - medullary nephrocalcinosis, 138, 281, 282
    - differential diagnosis, 126
  - medullary sponge kidney, 281
  - Meigs syndrome
    - ascites vs., 155, 162
    - ovaries, 398
    - pleural effusions, 162
  - Ménétier disease, 356
  - mesenchymal tumors, stomach wall, 359
  - mesenteric vascular occlusion, 84-85, 85
    - acute portal vein thrombosis, 85
    - diffuse abdominal pain vs., 81
    - Doppler sonography, 85, 85
    - small intestine wall thickening, 365
  - mesenteric vascular thrombosis, ascites vs., 155, 162
  - mesenteric vein, acute thrombosis, 260, 261
  - metacarpophalangeal joint, distance values, 45
  - metastases, 105-106, 106
    - arteries, 205
    - chest wall, 402
    - gallbladder wall changes, 341
    - halo, 445
    - kidney, 276
    - liver *see* liver
    - lung parenchyma, 408, 408
    - lymph nodes *see* lymph nodes, enlargement
    - palpable masses vs., 100
    - spleen, 318, 318, 320
    - thyroid gland, 421
  - metatarsophalangeal joint, distance values, 45
  - microcalcification, 443, 444
  - micronodular abscesses, liver, 237, 237
  - mild urinary stasis, 382, 383
  - Mirizzi syndrome, 143, 143
  - mirror image artifact
    - imaging artifacts, 13, 13, 14
    - liver, 14
  - mitral valve
    - endocarditis, 98, 98
    - insufficiency, 209
  - M-mode ultrasound, 3
  - moderate urinary stasis, 383, 383
  - Mönckeberg sclerosis, 203, 203
  - monitor, equipment settings, 6
  - motion artifacts, CDS, 8
  - mucinous cystadenoma, ovaries, 397
  - multiple parapelvic cysts, kidney, 275, 284, 284
  - mumps, 427, 427
  - muscle, arthrosonography, 32
  - Muster classification, renal tumors, 451
  - myocardial infarction, upper abdominal pain vs., 62
  - myoma, uterus, 395, 395
  - myxedema, 118, 118
    - differential diagnosis, 117
- N**.....
- neck cysts, 104, 104-105
    - CDS, 104
    - palpable masses vs., 100
  - necrotizing acute pancreatitis, 66, 301, 302
  - nephrostomy, therapeutic aspiration/drainage, 61
  - neuroendocrine tumors
    - pancreas, 305, 305
    - weight loss, 438
  - neurological ultrasound, contrast-enhanced sonography, 6
  - night sweats, tumors, 438
  - nodular goiter, 180, 180-181
    - differential diagnosis, 179
    - thyroid gland *see* thyroid gland
  - nodular varix, 106, 106
    - CDS, 106, 106
    - palpable masses vs., 100
  - nodules, thyroid gland *see* thyroid gland
  - noise, 10, 10
    - CDS, 8
    - hepatic cyst, 10
  - nomenclature, 47-48
  - non-alcoholic steatohepatitis (NASH), 146-147
    - differential diagnosis, 140
  - non-Hodgkins lymphoma, 114, 115, 438
    - kidney, 277
    - palpable masses vs., 99
    - splenic artery displacement, 200
    - weight loss, 437
- O**.....
- obstructed tubular systems, postoperative ultrasound, 434-435, 435
  - obstructing cystic duct stone, bile ducts, 331

- obstructive atelectasis, lung parenchyma, 410, 410
- obstructive cholestasis, ductal dilatation, 330, 330
- obstructive pyelocalyceal ectasia, 275, 382, 382
- oncocytoma
  - kidney, 278
  - salivary glands, 429
  - thyroid gland, 420, 420
- ophthalmic signs, Graves disease, 182
- orchitis, 392, 392
- organ absence, postoperative ultrasound, 431, 431
- organ changes, tumors, 447, 447
- organ transplants, postoperative ultrasound, 432, 432
- Ossler disease, 243
- osteoarthritis
  - arthritis vs., 163
  - knee, 174
  - rotator cuff, 170
- ovarian arteries, 188
- ovarian cyst torsion, 80, 80
  - lower abdominal pain vs., 75
  - transvaginal sonography, 80
- ovaries
  - anatomy, 377
  - cystadenocarcinoma, 397, 398
  - cystic tumors, 397, 398
  - cysts, 396, 397
  - Meigs syndrome tumors, 398
  - mucinous cystadenoma, 397
  - premenopausal cysts, 396
  - serous cystadenoma, 397, 398
- overall gain, signal processing, 5
- P**
  - .....
  - pain
    - abdomen *see* diffuse abdominal pain; lower abdominal pain; upper abdominal pain
    - tumors, 438
  - palpable masses, 99-107
    - differential diagnosis, 99-100
    - *see also specific diseases/disorders*
  - pancreas, 293-311
    - anatomy, 293, 293
    - annular, 298, 298
    - carcinoma *see* pancreatic carcinoma
      - circumscribed changes, 295, 301-311
      - - anechoic changes, 301-303
      - - hyperechoic changes, 305-307
      - - hypoechoic changes, 303-305
      - - interpretation errors, 307-308
      - - isoechoic changes, 303-305
      - congenital cysts, 301, 301-302
      - cystic neoplasias, 302
      - cysts
        - - chronic pancreatitis, 301, 302
        - - congenital, 301, 301-302
        - - diffuse changes, 295-300
        - - hyperechoic changes, 297-298
        - - hypoechoic changes, 295-296
        - documentation, 46
        - duct dilation, 309, 309
        - ductectasia, 299, 299
        - duct stone calcifications, 305, 305
        - examination, 293-295
        - fibrosis, 297, 297
        - - lipomatosis vs., 299
        - fine-needle aspiration biopsy (FNAB), 56
        - - risks, 57
        - hemangioma, 306
        - large, 298, 298
        - lipomatosis, 297, 297
        - - fibrosis vs., 299
        - lymphadenopathy, 305, 305
        - neuroendocrine tumor, 305, 305
        - normal, 293, 293, 294
        - protein plug, 306, 306
        - pseudocysts, 306, 307
        - - further testing, 310, 311
        - - mimics, 307, 308
        - - therapeutic aspiration/drainage, 61
        - scanning protocol, 294-295
        - small, 298, 298
        - topography, 21, 21
        - tumors, 94, 94
        - - carcinoma *see* pancreatic carcinoma
        - - duct dilation, 309
        - - endosonography, 451
        - - ERP, 451
        - - fever vs., 92
        - - fine needle aspiration, 451
        - - further testing, 451
        - - upper abdominal longitudinal scan, 22, 29
    - pancreas divisum, 303, 303
      - duct dilation, 309, 309
    - pancreatic carcinoma, 304, 304
      - celiac trunk infiltration, 200
      - computed tomography, 311
      - endosonography, 311
      - fine needle aspiration, 310
      - further testing, 310
      - mimics, 307, 308
      - weight loss, 437
    - pancreatic disease, gallbladder wall changes, 340, 340
    - pancreatic insufficiency, 89-90
      - differential diagnosis, 88
      - fine-needle aspiration biopsy (FNAB), 90
    - pancreatitis, 303, 303
      - acute *see* acute pancreatitis
      - ascites vs., 155, 159, 160
      - focal, 304, 304
      - stomach wall swelling, 355
    - pannus, 33
      - rheumatoid arthritis, 34
    - papillomatosis, differential diagnosis, 140
    - papillomatous carcinoma, bile ducts, 328, 328
    - paralytic ileus, 83, 84
      - differential diagnosis
      - - ascites, 155, 161, 161-162
      - - diffuse abdominal pain, 81
      - small intestine, 362
      - toxic megacolon, 83
    - paramedian upper abdominal longitudinal scans, 231
    - paraneoplastic syndrome, deep vein thrombosis, 441
    - paraovarian cysts, 396
    - parapelvic cysts, kidney, 290
    - parasagittal upper abdominal longitudinal scan, 323
    - parasitic cysts, acute pancreatitis, 301, 303
    - paravascular changes, arteries, 205, 205-206, 206
    - parenchyma bands, kidney, 278, 279, 284, 285
    - parenchymal calcification, kidney, 283
    - parenchymal goiter, thyroid gland, 416, 416
    - parotid gland, 425, 426
      - mixed tumor, 428, 428
    - parotitis, 103
    - pelvic stone, kidney, 288, 288
    - pelvic venous thrombosis, 120-121, 121
      - differential diagnosis, 117

- penis, anatomy, 377
- percutaneous nephrostomy, 60–61
- perforated duodenal ulcer, upper abdominal pain vs., 62
- perforated gallbladder, 69, 69–70, 337, 338
  - upper abdominal pain vs., 62
- perforated ulcer, 68, 68–69
  - upper abdominal pain vs., 62
- periarthritides, 177, 177
- pericardial effusion, ascites vs., 155, 161, 161
- peripheral lymph nodes, 109
- peripheral veins, 193
- peripheral vessels, 191
- perirenal cysts, 292, 292
- perirenal masses, 292
  - abscesses, 292
  - hematoma, 292
  - perirenal cyst, 292, 292
- peritoneal carcinomatosis, 157–158
  - ascites vs., 155
- peritonitis, 83–84, 84, 158
  - Crohn disease, 84
  - differential diagnosis
    - ascites, 155
    - diffuse abdominal pain, 81
- phlegmasia cerulea dolens, 123
  - CDS, 123
  - differential diagnosis, 117
- phlegmons, gallbladder, 349
- photopic ultrasound imaging, 5
- “Phrygian cap” gallbladder, 337, 337
- plaque-like carcinoma, urinary bladder, 384, 385
- pleomorphic adenoma, salivary glands, 429
- pleura, 401, 403–407
  - abnormal findings, 403
    - see also specific diseases/disorders
  - effusions, 405
    - benign exudative effusion, 404, 404
      - causes/types, 405–406
      - chylous effusion, 406
      - diagnostic algorithm, 407
      - further investigation, 452
      - hemorrhagic effusion, 405
      - inflammatory effusion, 405
        - malignant effusion, 406
        - malignant exudative effusion, 404, 404, 405
        - Meigs syndrome, 4340
        - purulent effusion, 406
          - transudative effusion, 403, 404
          - tumors, 439, 439, 447
      - see also specific types
      - fine-needle aspiration biopsy (FNAB), 57
      - lesion evaluation, 401
      - sonography, left heart failure, 120
      - tumors, 405
  - pneumobilia
    - bile ducts, 330, 332
    - gallbladder, 349
    - liver, 254
    - postoperative ultrasound, 432, 433
  - pneumonia, lung parenchyma, 409, 409
  - polyarthritides, bicipital tenosynovitis, 168
  - polycystic kidney, 137, 273, 273–274
    - differential diagnosis, 126
  - polycystic ovaries, 396, 397
  - polypoid bladder tumors, 384, 385
  - polyps, large intestine, 371
  - popliteal artery, Doppler indices, 193, 193
  - popliteal vein
    - duplication, 211, 212
    - thrombosis, 121, 210
  - porcelain gallbladder, 344, 344–345
  - porphyria, echogenic lesions, 253, 254
  - portal hypertension, 158, 158–159
    - ascites vs., 155
    - CDS, 158
  - portal vein, 189, 190
    - acute thrombosis
      - mesenteric vascular occlusion, 85
      - portal venous system, 260, 261
      - chronic thrombosis, 260, 261
      - ectasia, 243
      - extended right intercostal scan, 23
      - hepatosplenomegaly, 148, 151
      - intrahepatic thrombosis, 247, 247
    - portal venous system, 233, 257–261
      - flow changes/collaterals, 258, 259, 259
      - interpretation, 261
      - intraluminal changes, 260–261, 261
      - luminal dilatation, 257–259
      - indirect signs, 257, 258
      - tributary compression, 258, 258
      - tributary dilation, 258, 258
  - posterior longitudinal scan
    - elbow, 41
    - knee, 43
    - malleolar region, 44
    - shoulder, 37
  - posterior transverse scan
    - hip, 42
    - knee, 42
    - malleolar region, 44
    - shoulder, 38
  - postoperative lesions, arteries, 195–196
  - postoperative ultrasound, 431–436
    - abscesses, 435, 436
    - anastomoses, 433, 433
    - arterial perfusion disorders, 436
    - cholangiectasis, 433, 433
    - fluid accumulations, 434, 434
      - foreign bodies, 436, 436
      - implant materials, 431, 431
      - normal changes, 431–433
      - obstructed tubular systems, 434–435, 435
      - organ absence, 431, 431
      - organ transplants, 432, 432
      - pneumobilia, 432, 433
      - resections, 433, 433
      - scars, 431–432, 432
      - thoracic surgery, 432
      - venous perfusion disorders, 436
    - postprocessing, signal processing, 5
    - power Doppler ultrasound, 4
    - pregnancy, edema, 118
      - differential diagnosis, 116
    - premenopausal cysts, ovaries, 396
    - preprocessing, signal processing, 5
    - primary biliary sclerosis, further testing, 333
    - primary hepatic carcinoma, 249, 249, 254
    - primary sclerosing cholangitis, 145
    - primary symptomatic cysts, therapeutic aspiration/drainage, 60, 61
    - primary tumors
      - enlarged lymph nodes, 92
      - fever, 92

- principles (of ultrasound),  
1–3
- beam shape, 2
  - imaging artifacts, 8
- propagation (of ultrasound),  
1, 3
- propagation velocity, 2
- prostate gland, 30
- anatomy, 376, 377
  - carcinoma, 390–391, 391
  - – ureteral obstruction, 132
- prostate-specific antigen tests,  
394
- prosthesis infection, arteries,  
206, 206
- protein plug, pancreas, 306,  
306
- protuberant intraluminal  
atheromatous plaques, 201,  
201
- pseudocysts
- acute pancreatitis, 301, 302
  - pancreas *see* pancreas
  - therapeutic aspiration/  
drainage, 58, 59, 59, 60, 61
- pseudodiverticula, urinary  
bladder, 384, 384
- pseudoerosion (of bone), 33
- pseudomembranous colitis,  
368, 368
- pseudo-obstructions, 91, 91
- differential diagnosis, 88
- pubic symphysis
- female, 29
  - male, 30
- pulmonary abscesses, 409, 409
- pulmonary embolism, 67,  
67–68
- differential diagnosis
  - – fever, 92
  - – upper abdominal pain, 62
- pulmonary infarction, lung  
parenchyma, 410, 411
- pulsatility index, 193
- pulsed Doppler ultrasound, 4
- cervical vessels, 214, 215
  - – Doppler indices, 215
- purulent effusion, pleura, 406
- pus, urinary bladder, 386–387,  
387
- pyelectasis, 380, 380
- pyelitis, kidney, 286, 286
- pyelonephritis, 268, 268
- chronic *see* chronic  
pyelonephritis
- pyonephrosis, 132–133, 133
- differential diagnosis, 125
  - kidney, 286, 286
- Q**  
.....
- quadrate lobe, liver, 22
- R**  
.....
- rectal carcinoma
- gastrointestinal tract, 441
  - microcalcification, 444
- reflection, 1, 3
- refraction, 3
- regenerative nodules, hepatic  
cirrhosis, 246, 246
- regressive changes, tumors,  
443–444
- renal adenoma, 277, 277
- renal amyloidosis, 137, 269,  
269
- differential diagnosis, 126
- renal artery, 188, 376
- aneurysm, 200
  - anomalies, 194, 194
  - Doppler indices, 193, 193
  - embolism, 129–130, 130
  - – differential diagnosis, 126
  - right midabdominal  
transverse scan, 25
  - stenosis, 291
- renal calyceal, 288, 288
- renal cell carcinoma, 279, 279,  
287, 287
- cystic, 275, 276
  - halo, 444, 445
- renal colic, 65, 65
- differential diagnosis
  - – lower abdominal pain, 75
  - – upper abdominal pain, 62
  - evaluation, 388
  - renal pelvic stone, 65
  - ureteral stone, 65
- renal infarction, 73, 73, 281,  
281
- renal insufficiency, 124–138
- differential diagnosis,  
125–126
  - heart failure vs., 125
  - *see also* glomerulonephritis;  
*specific diseases/disorders*
- renal lithiasis, 137
- differential diagnosis, 125
  - renal colic, 65
- renal myeloma, 269, 269
- renal pelvis, 380–388
- abnormal findings, 380
  - – *see also specific diseases/  
disorders*
  - carcinoma, 287, 287
- renal sinus lipomatosis, 284,  
285
- renal veins, 28, 376
- right midabdominal  
transverse scan, 25
- renal vein thrombosis, 74,  
74–75, 268, 268
- CDS, 74
  - upper abdominal pain vs., 62
- resections, postoperative  
ultrasound, 433, 433
- residual urine determination,  
51, 51
- resolution (of ultrasound),  
1–2
- frequency, 1–2
- retroperitoneal fibrosis,  
arteries, 205
- retroperitoneum,  
documentation, 46
- reverberations, imaging  
artifacts, 14, 14–15
- rheumatoid arthritis
- elbow nodules, 172
  - pannus, 34
  - shoulder, 169
- Riedel thyroiditis, 179, 416
- goiter, 184–185
- right common carotid artery,  
216
- right external carotid artery,  
216
- right flank scan, 19, 25
- right heart failure
- differential diagnosis, 116
  - – ascites, 155, 160, 160
  - edema, 117
- right intercostal scan, 23
- liver, 23, 231, 232, 232, 233
- right internal carotid artery,  
216
- right longitudinal  
paramedian scan, 24
- right midabdominal  
transverse scan, 19, 25
- right subcostal oblique scan,  
19, 22
- liver, 22, 231
- right upper leg, blood vessels,  
192
- right vertebral artery, 216
- rotator cuff
- degenerative lesions, 165,  
165, 166
  - distance values, 45
  - lateral longitudinal scan, 39
  - lateral transverse scan, 39
  - osteoarthritis, 170
- S**  
.....
- saccular aneurysms, 204
- salivary glands, 425–430
- abnormal findings, 426
  - – *see also specific disease/  
disorders*
  - abscesses, 427
  - adenoid cystic carcinoma,  
429
  - – further testing, 430
  - anatomy, 425, 425

## saphenous incompetence

- anechoic changes, 427–428
- bacterial sialadenitis, 428, 428
- chronic sialadenitis, 428
- cystadenolymphoma (Warthin tumor), 429, 429
- cysts, 427
- hemangioma, 430
- hyperechoic changes, 430
- hypoechoic changes, 428–429
- lipoma, 430
- lymphangioma, 430
- lymphoma metastases, 429, 429
- mucoepidermoid carcinoma, 429
- normal findings, 425, 425
- oncocytoma, 429
- pleomorphic adenoma, 429
- sarcoidosis, 428
- scan planes, 425
- sialadenosis, 428, 428, 430
- sialolithiasis, 430, 430
- swelling
  - palpable masses vs., 100
  - parotitis, 103
  - tumors, 104
- viral sialadenitis, 427, 427
- *see also specific glands*
- saphenous incompetence, 209, 209
- sarcoidosis
  - liver, 237, 237
  - salivary glands, 428
- sarcoma, 97
  - fever vs., 93
- scan planes
  - abdominal sonography
  - *see abdominal sonography*
  - gastrointestinal tract, 352
  - genital organs, 375
  - liver examination, 231
  - salivary glands, 425
  - spleen, 313
  - stomach, 352
  - thorax, 400
  - thyroid gland, 412
  - ureter, 375
  - urinary bladder, 375
  - urogenital tract, 375
  - *see also specific scans*
- scars
  - kidney, 280, 280–281, 281
  - postoperative ultrasound, 431–432, 432
- scattering, 3
- sclerosing cholangitis
  - bile ducts, 324, 327, 327
  - ductal dilatation, 330, 330
  - further testing, 333
- sclerosis
  - aorta, 197, 197
  - arteries, 197
- secondary biliary cirrhosis
  - *see bile ducts*
- secondary cysts, kidney, 274, 274
- secondary osteoarthritis, shoulder, 170
- sector scanner, transducers, 5
- sediment, urinary bladder, 386–387, 387
- Seldinger technique, 58, 58–59, 59
- seminal vesicles, 30
  - anatomy, 376, 377
  - changes, 389, 389
- serous cystadenoma, ovaries, 397, 398
- serpentine aneurysm, 199
  - CDS, 199
- severe urinary stasis, 383, 383
- shock kidney, 136
  - differential diagnosis, 125
- shoulder, 36–41
  - ankylosing spondylitis, 169
  - anterior longitudinal scan, 36, 36
  - anterior transverse scan, 32, 37, 37
  - arthritis, 169, 169–170, 170
  - axillary longitudinal scan, 39
  - distance values, 45
  - lateral longitudinal scan, 38
  - posterior longitudinal scan, 37
  - posterior transverse scan, 38
  - rheumatoid arthritis, 169
  - secondary osteoarthritis, 170
  - *see also rotator cuff*
- shrunken (stony) gallbladder, 336, 336, 337, 338
- sialadenitis
  - bacterial, 428, 428
  - chronic, 428
  - viral, 427, 427
- sialadenosis, 428, 428, 430
- sialolithiasis, 430, 430
- side-lobe artifact, 9, 9, 10
- signal processing, 5
  - CDS, 7–8
- signs and symptoms, 62–187
  - *see also specific diseases/ disorders*
- simple atherosclerotic plaques, 202, 202
- siphon gallbladder, 337
- slice-thickness artifact, 12, 12–13, 13
- sludge *see bile ducts*
- small intestine, 353, 354, 360–366
  - abnormal findings, 360
  - *see also specific diseases/ disorders*
  - circumscribed wall thickening, 365–366
    - malignant tumors, 365, 365–366, 366
  - functional disorders, 361–362
    - diabetic autonomic neuropathy, 361, 361
    - gastroenteritis, 361, 361
    - sprue, 361, 361
  - hematoma, 365, 365
  - long segmental wall thickening, 363–365
    - acute febrile enterocolitis, 364, 364–365
    - amyloidosis, 365
    - Crohn's disease, 363, 363–364, 364, 364
    - enterocolitis, 364, 364–365
    - mesenteric vascular occlusion, 365
    - small-bowel hematoma, 365, 365
  - obstruction, 353, 353
- soft plaques, cervical vessels, 221, 221
- solitary parapelvic tumor, kidney, 284
- sound wave properties, 1
- spectral Doppler ultrasound, 4
- spectral waveform, common carotid artery, 216, 217
- spermatocoele, testis, 394, 394
- spinal column, upper
  - abdominal longitudinal scan, 22, 29
- spleen, 313–321
  - abscesses, 95, 316, 319, 320
  - anatomy, 313, 313
  - calcification, 319, 319, 320
  - cysts, 315, 315–316, 319
  - diffuse changes, 313, 314–315
  - documentation, 46
  - fine-needle aspiration biopsy (FNAB), 56
  - focal changes, 313, 314, 315–318, 318–319
  - further testing, 319–321
  - hemangioma, 318, 318, 320
  - infarction, 74, 317, 317, 320, 321
  - upper abdominal pain vs., 62
  - lymphoma, 316, 316–317, 320

- metastases, 318, 318, 320
  - normal, 313, 314
  - scan planes, 313
  - - high lateral intercostal scan (high left flank scan), 26
  - - left flank scan, 26
  - - left subcostal oblique scan, 27
  - small, 315, 319
  - splenoma, 318, 318, 320
  - trauma, 317, 317-318, 320
  - splenic artery, 189
  - non-Hodgkins lymphoma, 200
  - splenic vein
    - thrombosis, hepato-splenomegaly, 148, 151
    - upper abdominal longitudinal scan, 22
  - splenoma, 318, 318, 320
  - splenomegaly, 314, 314
    - further testing, 319
  - spot-like pattern, tumor vascularity, 446, 446
  - sprue, 361, 361
  - squamous cell carcinoma, thyroid gland, 421
  - staghorn calculus, 288, 288
  - stenosis, 198
    - carotid artery, 221
    - cervical vessels, 222, 222-223, 223
    - iliac artery, 198
    - internal carotid artery, 215
    - superior mesenteric artery, 85
  - stents
    - bile duct compression, 144
    - carotid artery, 223, 223, 224
  - sternoclavicular arthritis, 170-171, 171
  - stomach, 352, 354, 355-360
    - abnormal findings, 355
    - - *see also specific diseases/disorders*
    - circumscribed wall thickening, 357-359
    - - acquired pyloric stenosis, 357, 357
    - - benign tumors, 357-358
    - - congenital hypertrophic pyloric stenosis, 357
    - - gastric carcinoma, 358, 358
    - - gastric ulcer, 357
    - - malignant gastric lymphoma, 359
    - - malignant tumors, 358
    - - mesenchymal tumors, 359
    - - ulcerated carcinoma, 357, 358
    - - varices, 357
  - diffuse wall thickening, 355, 355-356
  - - inflammatory, 356, 356
  - - neoplasms, 356, 356
  - - documentation, 47
  - - evaluation, 359-360
  - - further testing, 359-360
  - - luminal changes, 359
  - - normal findings, 353
  - - scan planes, 352
  - *see also entries under gastric stones*
  - biliary obstruction, 142
  - urinary bladder, 387
  - *see also gallstones*
  - stony gallbladder, 337, 349, 349
  - subacute granulomatous thyroiditis, goiter, 184
  - subdeltoid bursitis, 166, 167
  - sublingual gland, 426
  - submandibular gland, 426
  - subphrenic abscess, 71-72, 72
    - upper abdominal pain vs., 62
  - superior mesenteric artery, 28, 188, 189
    - Doppler indices, 193, 193
    - stenosis, 85
    - upper abdominal longitudinal scan, 29
  - superior mesenteric vein, 29
  - suppurative thyroiditis, 103
    - palpable masses vs., 100
  - suprapatellar longitudinal scan, knee, 43
  - suprapatellar transverse scan, knee, 43
  - suprapubic bladder catheter, 60
  - synovial membrane, arthrosonography, 32
  - synovitis, 33
    - arthritis, 35
    - Doppler spectrum, 35
    - hip, 174
- T**  
 .....  
 techniques (of ultrasound), 3-6  
 - *see also specific techniques*
- tendons, arthrosonography, 32
  - tendovaginitis, 35
  - tenosynovitis, 33
    - malleolar region, 177, 178
  - testicular arteries, 188
  - testicular torsion, 80-81, 394
    - lower abdominal pain vs., 75
  - testis
    - anatomy, 377, 378
    - epididymitis, 393, 394, 394
    - hydrocele, 393, 393
    - spermatocele, 394, 394
    - tumors, 393, 393
    - varicocele, 393, 393
  - therapeutic aspiration and drainage, 58-61
    - alcohol instillation, 60
    - contraindications, 60
    - indications, 59-60
    - lesions, 59-60
    - materials, 58, 58
    - percutaneous nephrostomy, 60-61
    - procedure, 58, 58-59, 59
    - suprapubic bladder catheter, 60
  - thoracic sonography, pulmonary embolism, 68
  - thoracic surgery, postoperative ultrasound, 432
  - thorax, 400-411
    - anatomy, 400, 400
    - lesion evaluation, 401
    - normal findings, 400
    - scan planes, 400
  - 3D sonography, digital image processing, 5-6
  - thrombosis
    - cervical vessels, 229, 229-230, 230
    - common femoral vein, 121
    - femoral vein, 210
    - intraluminal changes, 210, 210
    - jugular vein, 229, 229, 230
    - luminal changes vs., 209
    - popliteal vein, 121, 210
    - tumors, 441, 441
    - vena cava, 211
  - thyroid gland, 412-424
    - abscesses, 419-420, 420
    - adenoma *see adenoma*
    - adenomatous hyperplasia, 418, 418-419
    - adenomatous nodules, 422
    - anatomy, 412, 412, 413
    - calcifications, 422, 423
    - circumscribed changes, 414, 417-424
    - - anechoic changes, 417-418
    - - hyperechoic changes, 418-421, 422-423
    - - isoechoic changes, 418-421
    - - *see also specific diseases/disorders*
    - colloid nodules, 419, 420
    - cystic transformation (pseudocysts), 418, 418
    - diffuse changes, 414-417
    - - hyperechoic changes, 416-417

- - hypoechoic changes, 414–416
- - *see also specific diseases/disorders*
- diffuse colloid goiter, 416, 416
- - further testing, 423
- documentation, 46
- evaluation, 423
- fine-needle aspiration biopsy (FNAB), 57
- further testing, 423–424
- goiter *see* goiter; goitrous nodule
- hyaline connective tissue, 419
- lymphoma, 416
- malignant tumors, 420, 421
- nodular goiter
  - - further testing, 424
  - - regressive changes, 422, 422
  - nodules
    - - differential diagnosis, 423
    - - further testing, 424
    - normal findings, 412, 413
    - oncocyoma, 420, 420
    - regressive fibrotic changes, 416–417, 417
  - scan planes, 412
  - true cysts, 417
  - tumors, 185–186, 186
    - - differential diagnosis, 179
    - - further investigation, 452
- thyroiditis
  - acute nonsuppurative *see* acute nonsuppurative thyroiditis
  - acute suppurative *see* acute suppurative thyroiditis
- time gain compensation (TGC), 5
- tissue harmonic imaging (THI), 5
- toes, 41
  - articular synovitis, 172–173
- topography, 20–31
  - bile ducts, 21, 21
  - gallbladder, 20, 20
  - pancreas, 21, 21
- tortuosity, aorta, 197
- toxic cirrhosis of the liver, 140, 140
  - differential diagnosis, 139
- toxic fatty liver, 238
- toxic megacolon, paralytic ileus, 83
- transducers, 4–5
- transesophageal echocardiography (TEE)
  - dissecting aortic aneurysm, 199
  - mitral valve endocarditis, 98
  - transmitted power, signal processing, 5
  - transrectal ultrasound (TRUS), 394
  - transudative effusion, pleura, 403, 404
  - transthoracic echocardiography (TTE), 98
  - transvaginal sonography, 80
  - transverse scans
    - abdominal sonography, 16, 17
    - cervical vessels, 220
    - external carotid artery, 220
    - internal carotid artery, 220
    - tendovaginitis, 35
  - trauma
    - arteries, 195–196
    - gallbladder wall changes, 340
    - spleen, 317, 317–318, 320
  - tributary compression, portal venous system, 258, 258
  - tributary dilation, portal venous system, 258, 258
  - tricuspid valve insufficiency, 209
  - true cysts, thyroid gland, 417
  - tubal rupture, 79, 79–80
    - lower abdominal pain vs., 75
  - tuberculosis, kidney, 275
  - tumors, 437–452
    - adrenal glands, 292
    - appearance, 443–445
      - - echogenicity, 443, 443
      - - halos, 444–445
      - - regressive changes, 443–444
      - - shape, 443
    - ascites, 439
    - benign
      - - small intestine wall thickening, 365
      - - stomach wall thickening, 357–358
    - bile duct compression, 144
    - calcification, 443
    - clinical manifestations, 437
    - - *see also specific signs/symptoms*
    - constipation, 440–441
    - diarrhea, 440–441
    - displacement, 449
    - evaluation, 449–450
    - fever, 438
    - fixation, 449
    - fluid accumulations, 447
      - - ascites, 447, 448, 448
    - functional impairment, 447
    - further testing, 450–452
    - infiltration, 449
      - - chest wall, 402, 403
      - - veins, 210, 210
    - laboratory tests, 442
    - macrocalcification, 443, 444
    - malignant
      - - small intestine wall thickening, 365, 365–366, 366
      - - stomach wall thickening, 358
    - - thyroid gland *see* thyroid gland
    - mechanical bowel obstruction, 82, 82
    - microcalcification, 443
    - night sweats, 438
    - organ changes, 447, 447
    - pain, 438
    - pleural effusions, 439, 439
    - salivary gland swelling, 104
    - sonographic criteria, 442, 442–449
      - - *see also specific criteria*
      - testis, 393, 393
      - thrombosis, 441, 441
      - vascularity, 445–446, 446
    - twinkling artifact, CDS, 8

**U**

- ulcerative carcinoma
  - large intestine, 370, 371
  - stomach, 357, 358
- ulcerative colitis, 89
  - differential diagnosis, 88, 373
  - large intestine wall thickening, 367, 367–368
- ulcers, perforated
  - *see* perforated ulcer
- ultrasound-guided therapeutic intervention, liver, 256
- unilateral renal agenesis, 264
- upper abdominal longitudinal scan, 19, 22, 29
  - aorta, 22, 29
  - celiac trunk, 29, 189
  - gallbladder, 22
  - liver, 22, 29, 189
  - pancreas, 22, 29
  - spinal column, 22, 29
  - splenic vein, 22
  - vena cava, 22
- upper abdominal pain, 62–75
  - differential diagnosis, 62–63
  - *see also specific diseases/disorders*

- upper abdominal transverse scan, 19
    - celiac trunk, 189
    - liver, 231, 232, 233
  - ureter, 376, 379, 380–388
    - abnormal findings, 380
    - - *see also specific diseases/disorders*
    - anatomy, 375, 376
    - left midabdominal transverse scan, 27
    - obstruction, 131–132, 132
      - - differential diagnosis, 125
    - postoperative obstruction, 435, 435
    - scanning protocols, 379
    - scan planes, 375
    - stones, 388
  - ureteral stone, renal colic, 65
  - ureterocele, urinary bladder, 386, 386
  - urethra
    - female, 29
    - male, 30
    - - obstruction, 138
    - - differential diagnosis, 126
  - urinary bladder, 380–388
    - abnormal findings, 380
    - - *see also specific diseases/disorders*
    - anatomy, 375, 376, 376
    - carcinoma staging, 386
    - evaluation, 388
    - female, 29
    - further testing, 388
    - intraluminal findings, 386, 386–388, 387, 388
    - lower abdominal longitudinal scan, 31
    - lower abdominal transverse scan, 30
    - male, 30
    - scanning protocols, 379
    - scan planes, 375
    - slice-thickness artifact, 13
    - wall changes, 384–386
      - - diverticula, 384, 384
      - - plaque-like carcinoma, 384, 385
      - - polypoid bladder tumors, 384, 385
      - - pseudodiverticula, 384, 384
      - - thickening, 384, 385
  - urinary bladder tamponade, 134, 134–135
    - differential diagnosis, 125
  - urinary retention, 78, 78
    - lower abdominal pain vs., 75
  - urinary stasis, 382, 383
  - urinary stone colic, 380, 381, 382
  - urogenital tract, 375–399
    - anatomy, 375
    - documentation, 47
    - scanning protocols, 379
    - scan planes, 375
    - *see also genital organs; specific organs*
  - uterus, 29
    - anatomy, 376, 377
    - carcinoma, 395–396
    - cervical carcinoma, 396, 396
    - endometrial carcinoma, 395, 396
    - endometriosis, 398, 398–399
    - endometriosis externa, 399
    - foreign bodies, 396, 396
    - lower abdominal longitudinal scan, 31
    - lower abdominal scan, 378
    - lower abdominal transverse scan, 30
    - myoma, 395, 395
- V**
- .....
  - vagina, 29
    - anatomy, 377
    - lower abdominal longitudinal scan, 31
    - lower abdominal scan, 378
  - varices, stomach wall thickening, 357
  - varicocele, testis, 393, 393
  - varicose veins, 121–122, 122
    - differential diagnosis, 117
  - vascular calcification, kidney, 283, 288, 288
  - vascularity
    - knee arthritis, 174
    - liver, 255
    - tumors *see* tumors
  - vascular occlusive disease, kidney, 270, 270
  - veins, 188–213, 208–213
    - anomalies, 208, 211
    - collapse, 209
    - compression, 211
    - computed tomography, 213
    - congestion, 208, 208
    - interpretation, 212–213
    - intraluminal changes, 208, 210
    - luminal changes, 208, 208, 208–209, 209
    - testing, 212–213
    - thrombosis, 209
    - tumor invasion, 210, 210
    - *see also specific veins*
    - velocity waveforms, 193
    - vena cava, 193
      - congestion, 208
      - duplication, 211, 212
      - extended right intercostal scan, 23
      - right longitudinal paramedian scan, 24
      - right midabdominal transverse scan, 25
      - thrombosis, 211
      - upper abdominal longitudinal scan, 22
    - vena cava syndrome, 122, 122–123, 123
      - differential diagnosis, 117
    - venography, 212
    - venous confluence, 189
    - vertebral artery, 218, 218, 219
    - vipoma, gastrointestinal tract, 441
    - viral sialadenitis, salivary glands, 427, 427

**W**

    - .....
    - wall filter, CDS, 7
    - wall thickening, arteries, 202, 202
    - weight loss, tumors, 437–438
    - wheel pattern, tumor vascularity, 445, 446
    - wrist, distance values, 45
    - written documentation, 46

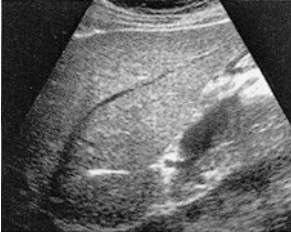**X**

    - .....
    - xanthogranulomatous cholecystitis, 344, 344
    - xanthogranulomatous pyelonephritis, 287

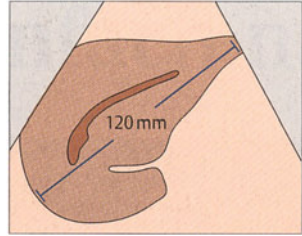
## Important Sonographic Dimensions\*

The values indicated are mean values drawn from the literature. It should be noted that organ dimensions may vary substantially from one individual to the next. Generally the values are not correlated with age, height, or constitution and therefore should be treated as **guidelines**. Vascular dimensions refer to **inside diameters**.

### ► Liver in longitudinal section

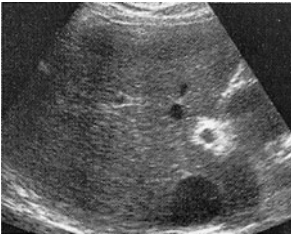


Craniocaudal < 130 mm

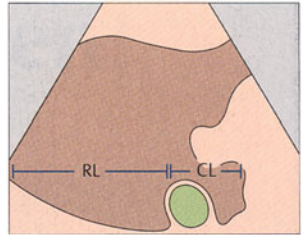


Inferior hepatic angle < 30° on left side,  
< 45° on right side

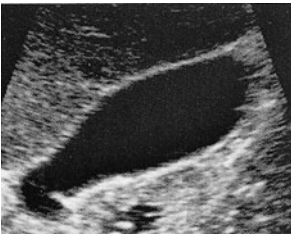
### ► Liver in transverse section



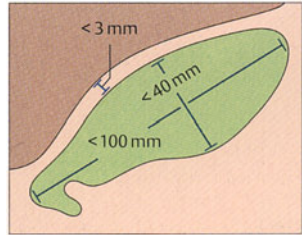
CL : RL < 0.55



### ► Gallbladder

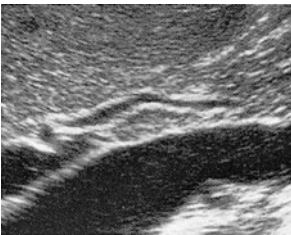


Longitudinal < 100 mm, anteroposterior < 40 mm

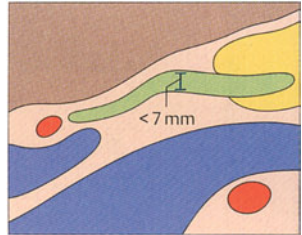


Wall thickness < 3 mm; volume < 100 ml

### ► Bile ducts

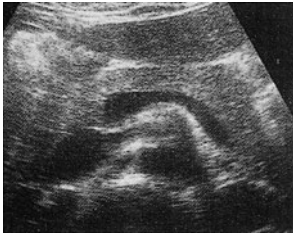

Extrahepatic < 5 (-7) mm (adults)

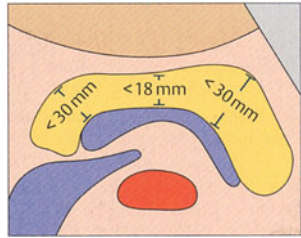


\* From Schmidt G, Course Book in Ultrasound, 4th ed. Stuttgart: Thieme; 2004.

► **Pancreas**

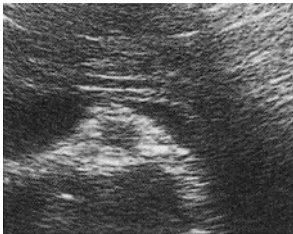


Head 25–30 mm, body < 18 mm

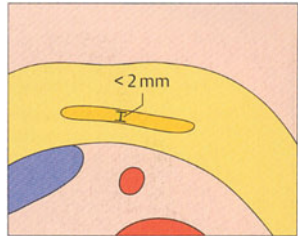


Tail 25–30 mm

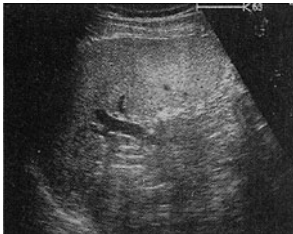
► **Pancreatic duct**



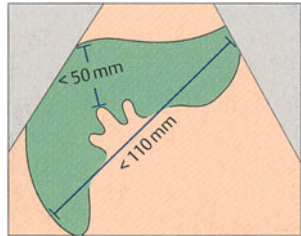
Pancreatic duct < 2 mm



► **Spleen**

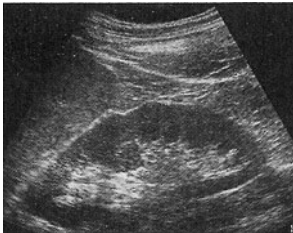


Longitudinal flank scan: length < 110 mm

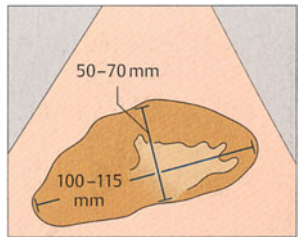


Width < 70 mm, thickness < 50 mm

► **Kidneys**



Length 100–115 mm, width 50–70 mm, thickness 30–50 mm



PP ratio: 1.7:1 up to 60 years of age, 1.1:1 over 60 years of age

See inside back cover for the prostate, bladder, thyroid gland, and major vessels.